Medical & Scientific

First of arts Without thy light

All the rest Would sink in night

FOUNDED 1844

MEDICA TYPOGRAPHIA

CIRCULATING LIBRARY

136 Gower Street & 24 Gower Place

LONDON, W.C.1.

Subscriptions from One Guinea per Annum

A SHORT PRACTICE OF SURGERY

BY HAMILTON BAILEY, F.R.C.S.

EMERGENCY SURGERY

VOL. I.—ABDOMEN AND PELVIS
VOL. II.—THORAX, SPINE, HEAD, NECK, EXTREMITIES, ETC.

With 754 Illustrations, many of which are in colour. Two Volumes. Large 8vo. 830 pp. 50s. net, postage 1s., or each Volume, 25s. net, postage 9d.

"A reliable guide, and the author merits praise for the high standard consistently maintained." — *Lancet.*

"The best that has been written in the English language."—*Medical Press and Circular.*

Fourth Edition. Fully Revised. With 335 Illustrations (some coloured). Large 8vo. 307 pp. 21s. net, postage 9d.

DEMONSTRATIONS OF PHYSICAL SIGNS IN CLINICAL SURGERY

"Mr. Bailey must be congratulated on the production of a work which gives just that assistance which is needed by the medical student. It has won deserved popularity, and we predict for it a long and successful life."—*Lancet.*

"An admirable book which we can recommend to all students."—*British Journal of Surgery.*

BRISTOL: JOHN WRIGHT & SONS LTD.
LONDON: SIMPKIN MARSHALL LTD.

BY R. J. McNEILL LOVE, M.S., F.R.C.S.

A SHORTER SURGERY

A PRACTICAL MANUAL FOR SENIOR STUDENTS

Third Edition. With 96 Illustrations. Demy 8vo. 421 pp. 16s. net, postage 9d.

"It is an achievement to have compressed in such a small compass a readable account of modern surgery."—*Lancet.*

"... the author is to be complimented on the excellence of his work ... the volume is to be commended as short, yet reliable." *Birmingham Medical Review.*

LONDON: H. K. LEWIS & CO. LTD.

A SHORT PRACTICE OF SURGERY

BY

HAMILTON BAILEY

F.R.C.S. (Eng.)

SURGEON, ROYAL NORTHERN HOSPITAL;
SURGEON AND UROLOGIST, ESSEX COUNTY COUNCIL;
LATE ASSISTANT SURGEON, LIVERPOOL ROYAL INFIRMARY;
SURGICAL FIRST ASSISTANT, LONDON HOSPITAL.

AND

R. J. McNEILL LOVE

M.S. (Lond.), F.R.C.S. (Eng.)

SURGEON, ROYAL NORTHERN AND METROPOLITAN HOSPITALS;
CONSULTING SURGEON, CITY OF LONDON MATERNITY HOSPITAL,
HUNTERIAN PROFESSOR, ROYAL COLLEGE OF SURGEONS;
LATE SURGICAL FIRST ASSISTANT, LONDON HOSPITAL.

SECOND EDITION

WITH 731 ILLUSTRATIONS,
OF WHICH 84 ARE COLOURED

LONDON
H. K. LEWIS & CO. LTD.
1935

MADE IN GREAT BRITAIN

PREFACE TO SECOND EDITION

In presenting the second edition of this survey of general surgery, we wish to convey our grateful appreciation to many friends who have helped us with welcome suggestions and kindly criticisms. Although only rather more than two years have elapsed since the completion of the first edition, surgery has made such rapid strides that all the chapters have required revision and some have been partially re-written. We have continued our efforts to include only such material as is completely up to date and yet generally acceptable, and we trust that time-honoured shibboleths have been excluded. Following the practice which we adopted in the previous edition, advanced surgery and rare conditions are relegated to small type, so that the candidate for a qualifying examination can rapidly review essential facts by confining himself to the material included in the larger print.

In view of our confirmed confidence in the value of illustrations in order to lighten and shorten the text, we have included over a hundred new figures which we believe will be appreciated by the reader.

We are very grateful to Messrs. H. P. Nelson, F R.C.S., N. M. Matheson F.R.C.S , L. E. Norrish, F.R.C.S., and Drs. D. A. Beattie and R. W. Cockshut for carefully reading the proofs. We are also under a great obligation to the Curator of the Museum of the Royal College of Surgeons, Professor John Beattie, for allowing us to reproduce illustrations of specimens.

For permission to use various blocks we are indebted also to the following publishers : Messrs. John Wright & Sons ; Cassell & Co. ; Oxford Medical Publications ; Oliver & Boyd ; J. & A. Churchill, Ltd ; Bale, Sons & Danielsson ; University

of London Press; W. Heinemann (Medical Books Ltd.); D. Appleton & Co.; Jackson, Wylie & Co.; P. Blakiston's Son & Co.; W. B. Saunders Co.; Lea & Febiger, and also to the Editors of *The Lancet*, *British Medical Journal*, *Practitioner*, *British Journal of Urology*, *British Journal of Surgery*, *British Dental Journal*, *Journal of the American Medical Association*, and *Surgery, Gynæcology and Obstetrics*.

Finally, we wish to express our indebtedness to the Publishers for their helpful co-operation and careful preparation of this volume for the press. They concur with us that probably most readers will prefer the new departure of issuing the work in a single volume. This also makes possible certain economies which have enabled this edition to be published at an appreciably lower price.

THE AUTHORS.

ROYAL NORTHERN HOSPITAL,
LONDON.
January 1935.

CONTENTS

		PAGE
	PREFACE TO SECOND EDITION	v
CHAPTER		
I.	NON-SPECIFIC INFECTIONS AND WOUNDS	1
II.	SPECIFIC INFECTIOUS DISEASES	11
III.	TUMOURS	38
IV.	ULCERATION AND GANGRENE	60
V.	BLOOD AND BLOOD-VESSELS	71
VI.	LYMPHATICS AND LYMPHATIC GLANDS	90
VII.	FACE AND JAWS, INCLUDING THE PALATE	98
VIII.	MOUTH AND TONGUE; FLOOR OF THE MOUTH	122
IX.	SALIVARY GLANDS	138
X.	NECK	147
XI.	THYROID	167
XII.	LARYNX AND PHARYNX	184
XIII.	ŒSOPHAGUS	197
XIV.	STOMACH AND DUODENUM	207
XV.	SPLEEN AND LIVER	236
XVI.	GALL BLADDER AND BILE DUCTS	263
XVII.	PERITONEUM	285
XVIII.	INTESTINES	308
XIX.	INTESTINES (*continued*) AND INTESTINAL OBSTRUCTION	330
XX	APPENDIX	347

CHAPTER		PAGE
XXI.	Rectum and Anal Canal	373
XXII.	Hernia	408
XXIII.	Kidneys and Ureters	440
XXIV.	Bladder and Prostate	481
XXV.	Urethra and Penis	511
XXVI.	Testes, including Spermatic Cords, Vesiculæ Seminales, and Scrotum	533
XXVII.	Head	560
XXVIII.	Spine	599
XXIX.	Nerves	636
XXX.	Special Nerves	643
XXXI.	Breast	672
XXXII.	Thorax	697
XXXIII.	Injuries to Bones	724
XXXIV.	Diseases of Bones	792
XXXV.	Injuries to Joints	837
XXXVI.	Diseases of Joints	856
XXXVII.	Muscles, Tendons, and Bursæ	888
XXXVIII.	Deformities	898
XXXIX	The Skin	929
XL	Infections of the Hand	939
	Index	947

A SHORT PRACTICE OF SURGERY

CHAPTER I

NON-SPECIFIC INFECTIONS AND WOUNDS

THE more important pyogenic organisms are :

1. **Staphylococcus pyogenes,** which commonly cause infection of the skin, e.g. boils and carbuncles, and are also responsible for some varieties of deep-seated suppuration, such as osteomyelitis or perinephric abscess. In these cases infection is probably carried through the skin to the deeper tissues by the blood-stream.

Staphylococci occur in characteristic clusters, are gram-positive, and are readily cultivated. Cultures vary in colour, and are named accordingly, e.g. Aureus, Citreus, Albus.

2. **Streptococci** are gram-positive organisms, which grow in chains, and comprise many different strains. Also members of the same strain often develop varying degrees of virulence. Two main groups of streptococci are hæmolytic and non-hæmolytic varieties, the former being the more virulent, and producing the spreading types of infection, such as erysipelas, cellulitis, lymphangitis, and occasionally gaining access to the blood-stream and causing ulcerative endocarditis or puerperal fever.

Non-hæmolytic streptococci are more commonly concerned with infection of the tonsils, gall bladder, etc.

3. **Pneumococci** are arranged in pairs, the individual coccus being oval in shape. These organisms are the

common cause of pneumonia, and are usually found either alone or in association with other organisms, e.g. in pus from empyemata. Acute arthritis, otitis media, and peritonitis, particularly in young girls, are also sometimes caused by pneumococci.

4. **Bacillus coli** are gram-negative, and normally inhabit the healthy intestine. They are distinguished from the typhoid group of bacilli by their action on various sugars. When pathological conditions arise, e.g. intestinal obstruction, the organisms are liable to become extremely virulent. Peritonitis, cholecystitis, and pyelitis are commonly due to B. coli.

5. **Bacillus typhosus** may cause acute periostitis or cholecystitis, sometimes years after the original infection. Some patients after recovery continue to secrete bacilli in the urine and fæces. These "carriers" occasionally cause epidemics.

6. **Bacillus pyocyaneus** was formerly common, but now only occasionally infects wounds as a secondary infection. The pus is bluish green, and emanates a musty odour.

7. **Gonococci** are gram-negative organisms arranged in pairs. Each coccus is kidney-shaped, and the two lie with their concave sides adjacent. When infected pus is examined, polymorphonuclear cells are commonly seen crowded with gonococci. The most characteristic lesion produced by gonococci is urethritis. Direct transmission may be responsible for conjunctivitis or prostatitis, while toxins or organisms in the blood-stream may cause arthritis, fibrositis, or endocarditis.

Acute Abscess.—Organisms which cause acute abscesses reach the infected part by direct infection from without, as in penetrating wounds, by local extension from some pre-existing focus, and by means of the blood-stream or lymphatic vessels. In the case of hæmatogenous infection, some predisposing factor may operate, e.g. a torn muscle is responsible for an extravasation of blood which forms a suitable nidus for pyogenic organisms, or debilitating disease

lowers the general resistance and allows infection, as in the case of the perinephric cellular tissue.

The bacteria, having gained access to the tissue, multiply and produce toxins, and acute inflammation follows. The vitality of the tissues is destroyed, and this area is surrounded by a peripheral inflammatory zone of acute inflammation, which is infiltrated with leucocytes and bacteria. The central necrotic mass undergoes liquefaction, and the tension within the cavity is raised by exudation of plasma, the resulting fluid containing leucocytes and bacteria. The abscess thus formed continues to spread along the paths of least resistance, usually towards the surface of the body, in which case œdema indicates its presence, to be followed later by fluctuation, and probably discharge of its contents.

Occasionally the resistance of the body is sufficient to destroy the bacteria before pus finds its way to the surface, in which case the fluid is absorbed, and either fibrosis follows, or a cavity remains containing inspissated pus. In some cases, as in staphylococcal abscesses of bone (Brodie's abscess), infection remains latent, but gives rise to exacerbations of inflammation consequent on injury or lowered resistance due to constitutional debility.

Symptoms.—The patient complains of malaise, the degree depending to some extent upon the size of the abscess and the tension within the cavity. Throbbing pain is characteristic of suppuration, the pain becoming more acute if the affected part is dependent.

Signs.—(*a*) *General.*—The signs of infection are present to a varying extent, and in severe cases rigors may occur.

(*b*) *Local.*—The signs of inflammation are present, the readiness with which they can be detected depending on the size of the abscess and its proximity to the surface. The swelling is at first brawny and œdematous ; later softening and fluctuation are manifest, in some cases increasing œdema is very characteristic of deep pus, as in acute mastitis. If untreated, an abscess tends to point, the skin or membrane covering it gives way, and the contents are

discharged, usually with marked amelioration of the signs and symptoms.

Treatment.—When an abscess threatens to form, it may sometimes be aborted by rest and elevation to the affected part, the applications of cooling lotions, and constitutional treatment, including vaccines.

If pus is suspected, steps are usually taken to evacuate the abscess by incision and drainage. In regions where incisions are fraught with danger to important anatomical structures, as in the parotid gland or axilla, the method of Hilton should be used. This consists in incising the skin and fascia, and opening the abscess by thrusting a pair of sinus forceps into the cavity. In separating the blades, a sufficiently large opening can be made to insert a finger, followed by a drainage tube. Pus from an abscess should be examined bacteriologically, and if considered advisable a vaccine is prepared.

If an abscess is opened incompletely, a sinus or fistula may result. A sinus is a narrow track lined with granulations which opens on the surface, whereas a fistula is an abnormal communication between two cavities, or between a cavity and the surface. Thus a perianal abscess may burst on the surface and lead to a sinus, erroneously termed a blind external "fistula." In other cases, the abscess opens both into the anal canal and on to the surface, resulting in a true fistula.

Sinuses and fistulæ often heal slowly, for the following reasons :

(i) A foreign body or necrosed tissue is sometimes present.

(ii) The walls become lined with epithelium.

(iii) Dense fibrosis prevents contraction.

(iv) Irritating discharges, e.g. urine and fæces, maintain a continuous inflammation.

(v) Inefficient or non-dependent drainage.

(vi) Absence of rest, such as constant sphincteric contraction in the case of fistula in ano.

(vii) Type of infection, e.g. tuberculosis or actinomycosis.

Treatment consists in removal of any cause, and provision

of adequate drainage, if necessary by counter openings. Packing with gauze moistened with suitable disinfectants will encourage healing from the bottom of the cavity. Disinfectants should occasionally be changed, as organisms appear to become partially immune to long-continued use of the same dressing. Rest is provided as efficiently as possible, and scraping or cautery is sometimes necessary to remove any downgrowth of epithelium.

General treatment includes vaccines and helio-therapy.

Amyloid Disease

This is the result of persistent suppuration, and is most commonly seen nowadays as a result of an empyema, or sinuses in connection with the hip joint. Amyloid disease is a misleading term, as the infiltration of tissues is not due to any starchy substance, but to chondroitin-sulphuric acid in combination with a protein. Infiltration commences in the walls of the smaller arterioles, and later spreads to larger vessels, and even to connective-tissue stroma. The substance is stained a mahogany brown by tincture of iodine, and microscopically, methyl violet stains the infiltrated tissues a rose pink, while normal structures are stained blue.

Affected organs show a regular, smooth enlargement. The first changes in the liver occur in the intermediate zone of the lobule. Polyuria is present owing to infiltration of the kidneys, which first commences in the glomeruli. Diarrhœa ensues owing to infiltration of the capillaries in the villi of the small intestine, and splenic enlargement occurs, the Malpighian bodies being chiefly affected. If the source of infection can be eradicated, early amyloid disease will disappear.

Cellulitis

Cellulitis is due to spreading inflammation of the subcutaneous and cellular tissue, which sometimes progresses to suppuration or gangrene.

The streptococcus pyogenes is usually the causative organism, and gains admission to the tissues through an accidental wound, often trivial in nature, such as a graze or scratch, or possibly as the result of an operation. If

the general resistance of the patient is undermined as by diabetes, alcoholism, renal inefficiency, cellulitis is likely to spread rapidly and widely.

The clinical features depend upon the virulence of the organism and the extent of infection. Itching or stiffness commences at the site of inoculation, to be followed by tenderness and induration. If the condition progresses, gangrene of the superficial fascia may supervene. The general features of infection are usually well marked, and septicæmia or pyæmia sometimes develops.

Treatment consists, in the early stages, in the application of warmth, and securing rest of the affected part. If inflammation spreads, free incisions are made in the axis of the limb, down to the deep fascia. Baths of hypertonic saline (5 per cent.), to encourage lymphatic drainage, alternating with disinfectant dressings, are useful.

The general health of the patient is maintained, and collosol manganese or mercurochrome may be given intravenously. A suitable serum should always be administered.

Cellulitis in Special Situations

Scalp.—This is due to infection of the sub-aponeurotic layers of the areolar tissue. Pus may extend to the attachment of the epicranial aponeurosis, so that the whole scalp is lifted off the calvarium. Necrosis of bone and thrombosis of emissary veins spreading to intracranial sinuses may follow. Early incisions are called for, parallel to the arteries.

Orbit.—This follows wounds or spread of infection from air sinuses in the vicinity. Proptosis and impairment of ocular movements follow, and infection may spread to the meninges, or thrombosis extend along the ophthalmic veins to the cavernous sinus. The eyeball itself occasionally becomes infected (panophthalmitis).

Owing to risk of cellulitis, all wounds of the orbit must be carefully disinfected, and enlarged, if necessary, to promote drainage. If infection supervenes, the wound is enlarged, or drainage is provided by incisions in the eyelids or conjunctival fornix. Panophthalmitis is treated by evisceration of the eye ; this procedure is safer than excision, which

is liable to be followed by meningitis, owing to infection extending along the divided sheath of the optic nerve.

Neck.—Complicates wounds, tonsillitis, or mastoiditis. Ludwig's angina is a term applied to submaxillary cellulitis.

The two main dangers of cervical cellulitis are œdema of the glottis and mediastinitis.

Pelvis.—Not infrequently follows lacerations of the cervix uteri, or less commonly follows disease or injury to any of the pelvic organs, such as extraperitoneal rupture of the bladder. Infection frequently creeps up the side of the pelvis, in which case an indurated swelling appears above Poupart's ligament. In the first two or three weeks, on rectal or vaginal examination, a firm, tender pelvic mass can be palpated, but by the time the swelling appears above Poupart's ligament the mass in the pelvis has frequently disappeared.

In the early stages, hypogastric fomentations and vaginal douches are useful. If the swelling appears above Poupart's ligament and deep œdema or softening is detected, the abscess is incised and drained extraperitoneally. Posterior colpotomy is sometimes useful.

Wound Infection

Infection of accidental wounds is often unavoidable, although early and thorough treatment frequently prevents the development of the infection. Surgical wounds in "clean" cases may become infected owing to some flaw in technique, or faulty sterilisation of instruments or material used at operation.

Local changes comprise those of inflammation, which, if superficial, manifests itself as cellulitis of varying extent. If infection is deep in a wound, swelling occurs, so that the stitches appear to be under tension; tenderness and induration follow. If suppuration occurs, the abscess may burst superficially, and perhaps a knot or ligature is discharged.

General evidence of infection is due to toxæmia, septicæ-

mia, or pyæmia, or a combination of two or all of these conditions.

Toxæmia is due to absorption of toxins, and a small collection of pus under tension, as in the mastoid antrum, often causes profound toxæmia. The general features of infection are present, although in severe cases the temperature may be subnormal, with increased pulse rate. Delirium, gastro-intestinal disturbances, and pulmonary symptoms are present according to the organs chiefly affected.

Septicæmia and **bacteræmia** are due to the presence of organisms in the blood. In the former condition the organisms are not only present in the circulation, but actually proliferate therein. Streptococci are the commonest organisms to be found by blood culture, and if of the hæmolytic variety, the prognosis is grave.

The features of the condition are those of severe infection, frequently preceded by rigor. The temperature is commonly intermittent, and rigors sometimes follow. Icterus sometimes occurs from hæmolysis, and leucocytosis is present as long as the resistance of the patient is maintained.

Treatment consists in dealing promptly and efficiently with the causative focus of infection. Anti-streptococcal or other suitable serum is given, and if the organism is isolated, immuno-transfusion should be considered, and a vaccine prepared. Intravenous antiseptics occasionally appear to give excellent results, and eusol, mercurochrome, or other preparation should be given a trial.

Pyæmia is due to the circulation in the blood-stream of infective emboli composed of masses of organisms, vegetations, or infected clot. Common causes of pyæmia include acute infective osteomyelitis, infection of an intracranial sinus, infective phlebitis, and ulcerative endocarditis.

When the infected embolus is arrested in a vessel, thrombosis occurs round it, and infection spreads into the adjacent tissues. If the embolus arises in connection with the systemic circulation, it is likely to be arrested in the lung, so that a wedge-shaped hæmorrhagic infarct results, which

breaks down to form an abscess. From these abscesses fresh emboli may arise and reach the left side of the heart, and thus be widely disseminated. If the focus of infection is in the portal area, the emboli are carried to the liver, giving rise to pylephlebitis.

Clinically, in addition to the features of infection, pyæmia is characterised by rigors, an intermittent temperature, and the formation of abscesses. Abscesses occur in any part of the body, and are commonly painless; thus an abscess in the back may be accidentally discovered as a swelling by a nurse while washing the patient. Joints are commonly affected, and sometimes become quietly disorganised. Death follows abscess formation in vital structures, such as heart or brain.

The treatment of pyæmia consists in endeavouring to prevent further emboli from reaching the blood-stream. Thus, in the case of pyæmia due to suppurative arthritis of the knee joint, amputation is indicated, or if the condition is caused by thrombosis of the lateral sinus, then ligature and division of the internal jugular vein may be successful in cutting off the stream of emboli. Otherwise, abscesses are dealt with as they occur. Joints are frequently inspected, and general treatment instituted as for septicæmia.

Treatment of Infected Wounds.—*Local.*—This depends upon the degree of infection present, and the nature of the wound. In the case of recent wounds, e.g. due to accidents, an emergency operation should be performed in order to eradicate infection as completely as possible. An anæsthetic is usually necessary, and the surrounding skin is purified. The edges of the wound are excised, and damaged tissue and foreign bodies removed. If deemed necessary, the wound is cleansed with an antiseptic, such as 1 in 20 carbolic lotion, alcohol, or flavine, and primary suture may be undertaken. In wounds more severely contaminated a temporary packing of gauze moistened in antiseptic can be inserted, and if infection does not develop, the wound is sutured three days later. In grossly contaminated wounds efficient drainage is provided so that when the inevitable infection

occurs, the pus will have an unhampered exit. Carrel-Dakin's continuous irrigation is sometimes useful (fig. 1).

Carrel–Dakin Method of Treating Wounds. The wound is opened up well, foreign bodies removed, severely damaged tissues excised, and Carrel's tubes introduced, so that every part of the wound will be subjected to the process. These rubber tubes have one blind end and perforated sides, are fixed in position by loosely packed pieces of sterile gauze, steeped in Dakin's solution, and are connected proximally to a reservoir of the solution above the bed. From this, the solution is allowed to flow two-hourly, any excess in the wound being taken up by the large aseptic cotton-wool dressing covering it. The surrounding skin is protected by vaseline, as the solution is somewhat irritating if the skin is continuously sodden. Eventually secondary suture or skin grafting may be undertaken.

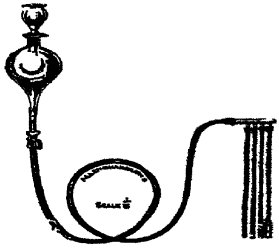

FIG. 1.—Apparatus for Carrel-Dakin irrigation.

In all cases in which tetanus might develop a prophylactic dose of A.T.S. must be given (p. 17). If tissues are lacerated, especially deep structures such as muscles, anti-gas gangrene serum should also be administered.

CHAPTER II

SPECIFIC INFECTIOUS DISEASES

ERYSIPELAS

ERYSIPELAS is a spreading inflammation of the skin and subcutaneous tissues, due to infection by one of the streptococcus pyogenes group (fig. 2). The organisms frequently gain entry to the tissues through a small or neglected wound, but in some cases no breach in the skin is discoverable. The general health of the patient is usually below par, and debilitating diseases, the extremes of life, and poor hygiene are prominent predisposing conditions.



(*Burroughs Wellcome & Co.*)

FIG. 2.—Streptococci.

Symptoms.—The patient notices that the skin in the vicinity of a scratch or abrasion has become irritable and feels stiff. After a few hours general symptoms of toxæmia supervene, which usually increase in severity until the patient is obviously ill or even delirious.

Signs.—If the infection commences in a wound this will exhibit an unhealthy appearance, and from the margins a rose-pink rash extends over the adjacent skin. The edge of the rash is definite, a feature which is often more easily appreciated with the finger than the eye. The colour of the rash and its definite edge are important points in distinguishing a true erysipelas from cellulitis. As the rash extends vesicles appear, which burst and discharge serum.

Considerable swelling occurs when lax tissues are involved, particularly the orbit and the scrotum, owing to

œdema of the subcutaneous layers. The scrotum is liable to become as large as a melon, and is often of a peculiar waxy colour. The rash gradually fades and for some weeks a brown discoloration of the skin remains, due to pigment set free as a result of destruction of red corpuscles. Adenitis invariably accompanies the infection, but suppuration of the glands is unusual.

In some cases the infection wanders about the body, perhaps for months (erysipelas migrans).

An uncommon but very troublesome form of the disease is the recurrent type which usually affects the face and head. Periodically, for no apparent reason, the patient suffers from an outbreak of the disease, in spite of every prophylactic measure. Lymphatic obstruction is likely to follow.

COMPLICATIONS

Severe toxæmia.—Which is liable to be fatal in debilitated subjects.

Gangrene.—Sloughing of skin and subcutaneous tissues occasionally occurs, particularly of lax tissues in patients of poor resistance. Septicæmia or pyæmia may follow.

Lymphatic Obstruction.—A severe attack of erysipelas is sometimes followed by fibrosis of the lymphatic vessels and glands, so that the lymphatic drainage is impaired. The eyelids are not uncommonly affected, greatly to the detriment of the patient's appearance.

Intercurrent Disease.—It is not uncommon, particularly in the elderly, for some fatal complication to develop during an attack of erysipelas. Pulmonary and renal complications are especially prone to occur.

Treatment.—Erysipelas is a contagious disease, and therefore the patient should be isolated or, at all events, removed from a surgical ward. Care must be taken during dressings to prevent contamination, and those who dress the wound must use gloves for their own, as well as others', safety. Surgeons and accoucheurs must be particularly careful, as organisms are apt to be conveyed to other patients even after every precaution, sometimes with tragic results.

General treatment is directed towards improving the health of the patient in every possible way. A suitable diet, mild aperients, adequate ventilation, and stimulants all receive due consideration. Antistreptococcal serum, pre-

pared against the specific streptococcus of erysipelas, is given at suitable intervals, either intramuscularly or intravenously. Collosol manganese injections are useful in recurrent or long-standing cases.

Local treatment appears to exert little effect upon the spread of the disease. Painting the circumference with tincture of iodine was formerly in vogue, in the hope that the resulting subcutaneous hyperæmia would tend to act as a barrier to the advancing streptococci. Ichthyol ointment is commonly used as a local application, and is useful for relieving pain and stiffness. We have found gauze soaked in a saturated aqueous solution of magnesium sulphate to be a very satisfactory dressing.

Incisions for the relief of tension are occasionally necessary, especially in lax tissues, and may obviate the onset of gangrene.

ANTHRAX

B. anthracis are large, rectangular organisms which tend to arrange themselves in chains (fig. 3). They are gram-positive anaerobes, and form spores which are very resistant to antiseptics. The disease causes epidemics in cattle, and is likely to occur in men who deal with cattle, carcases, hides, and hair. A few years ago many cases were traced to the usage of contaminated Japanese shaving brushes.

(*Burroughs Wellcome & Co*)

FIG. 3.—Bacillus anthracis, large rectangular bacilli in chains.

TYPES

Cutaneous.—This is the commonest human variety; the incubation period is from three to four days. The lesion usually commences on an exposed portion of the body, such as the face, forearms, or hands (p. 119). An itching papule occurs, around which a patch of induration soon becomes evident. The papule suppurates and is replaced by a black slough, and a ring of vesicles appears on the surrounding indurated

area. This stage comprises the typical "malignant pustule" (fig. 4). The induration extends subcutaneously, so that a brawny, congested patch develops around the site of inoculation. The regional lymphatic glands are invariably involved. Toxæmia is always in evidence, and an elevated temperature and raised pulse-rate are important evidences in the diagnosis of an early case of anthrax. The diagnosis is clinched by examining a smear of the fluid from a vesicle, as the organisms are easy to stain and recognise.

In a few cases œdema develops without any obvious primary focus. The œdema rapidly spreads, and somewhat

FIG. 4. Anthrax pustule, from the cheek of a man employed in skinning bullocks. (R.C.S. Museum, 801.1.)

resembles erysipelas, but toxæmia is more profound. This feature, in conjunction with the patient's occupation, should raise suspicion, which can be confirmed by the examination of fluid from a vesicle.

Pulmonary (*syn.* Woolsorter's Disease). Caused by the inhalation of spores, and characterised by a virulent bronchitis and bronchopneumonia, with toxæmia, dyspnœa, and blood-stained sputum. The organisms are found in the sputum, and death ensues.

Alimentary—Follows the ingestion of spores, provided they escape destruction by the acid in the stomach. Severe enteritis follows, which resembles cholera. The patient collapses and suffers from severe abdominal pain and blood-stained diarrhœa. This type is usually, but not necessarily, fatal.

Treatment.—Official regulations have done much to reduce

the incidence of the disease, and prophylactic measures should be followed rigidly.

Excision was formerly a favourite method of local treatment, but is liable to result in septicæmia. A protective barrier of serum injected subcutaneously around the pustule is a safer and more rational procedure. Ipecacuanha paste appears to be of decided benefit, but otherwise antiseptic compresses, such as 1 : 1,000 oxycyanide of mercury, should be used.

Serum therapy is of the greatest value, and many varieties are on the market. Mulford's serum is reliable, and 40–120 c.c. should be injected intravenously as soon as a diagnosis is made. This amount is repeated daily either intravenously or intramuscularly, or both, for as long as necessary.

Neo-salvarsan can be regarded as a specific for anthrax. It should be given intravenously in doses of ·6 gm. daily, or on alternate days, according to the severity of the infection. Neo-salvarsan or allied arsenical preparations are particularly valuable in that they are usually obtainable immediately, whereas some delay may inevitably elapse before serum is procurable. Neo-salvarsan is used extensively in South Africa, where anthrax is comparatively common, and we have used this preparation with excellent results.

TETANUS

This disease may be associated with any type of wound, but particularly those contaminated with cultivated soil, or of a punctured and infected nature.

The B. tetani is gram-positive and occurs as straight rods which develop a terminal spore, so that the name "drumstick" bacillus has been aptly applied (fig. 5). The bacillus is anaerobic, hence its partiality to deep or punctured wounds. In some cases the wound through

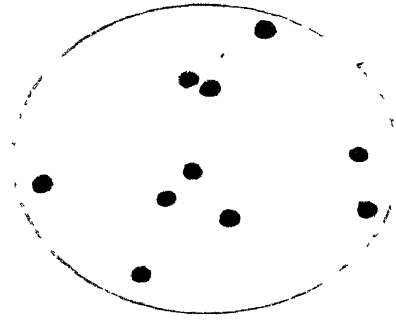

(*Burroughs Wellcome & Co.*)

FIG. 5.—Bacillus tetani showing spores.

which the organisms gained admittance has healed before symptoms are evident. The reopening of an old wound, even years after infliction, occasionally stimulates dormant organisms into activity.

Clinical Types

Acute Tetanus.—Occurs within fifteen days of inoculation, and the shorter the incubation period the more severe is the illness. The first symptoms are psychical. The patient becomes restless and uneasy, he is unable to concentrate or even keep still, and he experiences a dread of some impending evil. The temperature and pulse rate are above the normal. Within twenty-four hours muscular spasm supervenes, usually first affecting the muscles at the back of the neck, and then the jaw muscles. Risus sardonicus appears later, due to contraction of the facial muscles. Spasms follow, which extend to all the skeletal muscles, and during severe exacerbations the patient rests on his head and heels (opisthotonus). The psoas or rectus abdominis muscles are sometimes ruptured (fig. 6). The spasms are clonic as well as tonic, so relaxation is incomplete during the intervals. This feature distinguishes tetanus from strychnine poisoning, also in the latter case spasms commence in the extremities. Death occurs from cardiac failure following exhaustion, or occasionally from asphyxia

Fig. 6.—A torn rectus muscle from a case of tetanus, which followed a small wound of a toe. (R.C.S. Museum, 806.1.)

during a vice-like spasm of the respiratory muscles. A post-mortem rise of temperature follows.

Chronic Tetanus.—The incubation period is over fifteen days, and may be as long as six weeks. The symptoms are similar to those of acute tetanus, but much less severe. The prognosis is good.

Head tetanus follows a wound in the distribution of the facial nerve. The toxin reaches the central nervous system via the lymphatics in the sheath of a nerve, and so swelling of the nerve results. In the case of the facial nerve, which is enclosed in the unyielding stylo-mastoid foramen, swelling results in compression of the nerve and consequent paresis of the muscles of expression.

Delayed Tetanus.—Bacilli are capable of remaining latent in a wound for years, and cause tetanus when the wound is reopened. A prophylactic dose of serum must always be given if a potentially infected wound requires reopening.

Local Tetanus.—Occurs in the muscles around the initial wound. It is usually seen when the prophylactic dose of serum has counteracted general infection, but was insufficient to prevent local nerve involvement. This type was sometimes seen during the Great War.

Tetanus Neonatorum.—Is due to infection of the newborn child via the wound left after separation of the umbilical cord. This type is fatal.

Treatment

Prophylactic.—It is of the utmost importance that every patient with a potentially infected wound should receive an intramuscular injection of anti-tetanic serum. The usual dose is 500 U.S.A. units, but if the wound is extensive or delay has occurred a larger dose should be administered. A smaller dose may be repeated with advantage at weekly intervals for a month.

Also, should old wounds require reopening, as for the removal of a foreign body, an injection of serum is given prior to the operation.

Symptomatic.—The patient is isolated in quiet surroundings. Repeated anæsthetics are required to permit of nasal

feeding, catheterisation, and the injection of antitoxin. Chloretone, chloral, and bromides are given by the mouth or rectally, and avertin can be given by the latter route with advantage. Intrathecal magnesium sulphate (5 c.c. of 20 per cent. solution) temporarily reduces spasms by diminishing the conductivity of spinal nerves.

Curative.—Much depends on early recognition of the condition. Serum is disappointing when the disease is fully established, as toxins have already reached the central nervous system via axis cylinders and motor nerve endings. As soon as possible concentrated serum (20,000 units or more) should be injected intrathecally, intravenously, and intramuscularly. The dose is repeated in twelve hours, and again daily until spasms and rigidity have disappeared. The best results of serum therapy are obtained if the serum is introduced into the cisterna magna. A graduated lumbar puncture needle is inserted at the centre of a line joining the tips of the mastoid processes, and the cistern is reached at a distance of 4·5 to 6 cm. The needle should not be introduced to a greater depth for fear of injuring the medulla. About 20 c.c. of cerebro-spinal fluid are allowed to escape, and a slightly smaller quantity of serum slowly injected. The patient should be kept in a horizontal position so as to localise the action of the serum.

As much as 500,000 units of serum (150 units to 1 c.c.) are sometimes necessary for adequate treatment (i.e. to the value of about £20 !). Subcutaneous injections of 1 per cent. carbolic acid, in doses of 1 c.c., administered hourly, are alleged to destroy some of the toxins.

ACTINOMYCOSIS

This disease is alleged to affect those whose work brings them into contact with corn and grain, but accumulating statistics seem to indicate that the disease affects all members of the community equally, whatever their occupation may be. Probably the actinomyces are present normally in the mouth and alimentary canal, and become pathogenic when some local injury abrades or reduces the vitality of

the mucous membrane. The oral manifestations of the disease are certainly commoner in patients who neglect dental hygiene.

Small granules, which are sometimes sulphur coloured, are found in the pus. These are colonies of the streptothrix, and microscopically are seen to consist of masses of gram-positive filaments, or mycelium. These filaments radiate from the central part of the granule, this arrangement accounting for the term "ray fungus." These mycelial threads are sometimes seen to have an expanded end, or "club" (fig. 7). The clubs are gram-negative and are only found in the body, and not in cultures. The commonest type of streptothrix is anaerobic, but an aerobic form occasionally occurs.

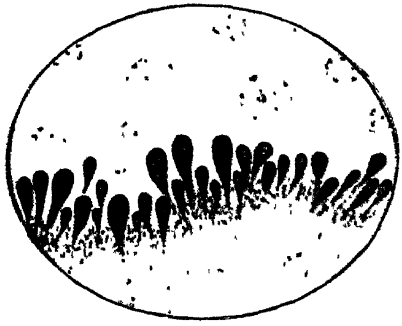

(*Burroughs Wellcome & Co*)

FIG. 7.—Actinomycosis of ox tongue showing the ray fungus.

Actinomycotic lesions are characterised by the formation of a firm, indurated mass, the edges of which are indefinite. Dense fibrosis follows, and the overlying skin resembles puckered leather. The infection spreads by direct invasion of adjacent tissues. Lymphatic glands are not affected, but if a vein is invaded pyæmic infection is likely to follow.

The following are the usual sites of infection :

(i) *Facio-cervical.*—The lower jaw is more frequently affected, often adjacent to a carious tooth. The gum becomes so indurated that it simulates a bony swelling. As extension occurs, nodules appear, which soften and burst. The overlying skin of the face and neck is indurated and bluish in colour, softening occurs in patches, and eventually abscesses burst through the skin (fig. 94). The characteristic features of the condition are chronicity, dense induration, and sinuses surrounded by bluish skin (see p. 153).

(ii) *Thorax.*—The lungs and pleura are infected either by aspiration of the fungus, or more commonly by direct

spread downwards from the pharynx or neck, or upwards through the diaphragm.

The disease extends through the lungs to the pleura and chest wall, which in the late stages is riddled with sinuses. An empyema is not uncommon, and the infection sometimes spreads through the diaphragm to the liver or subphrenic spaces.

Clinically, the condition resembles tuberculosis, and in the early stages is only distinguished by the discovery of mycelial threads in the sputum.

(iii) *Abdomen.*—The ileo-cæcal region is most commonly affected, owing to the considerable stasis which occurs in this part of the bowel. Possibly, for the same reason, the sigmoid colon is occasionally involved.

Ileo-cæcal actinomycosis usually occurs in one of two forms. Either an indurated mass forms in the iliac fossa, or the disease resembles appendicitis (see p. 371). The actinomycotic infection is usually unsuspected until the wound breaks down a few weeks or months later. In some cases the appendix shows no naked-eye evidence of inflammation.

The liver is not infrequently affected. In some cases the disease appears to be primary, but more often it arises as a pyæmic infection from the ileo-cæcal angle. Occasionally, infection spreads through the diaphragm from the pleura.

The liver becomes adherent to adjacent structures, and on section the abscesses present a "honey-comb" appearance due to interlacing strands of fibrous tissue.

Treatment.—Extirpation of the infected tissues should be attempted whenever possible, as in the case of early infection of the ileo-cæcal angle. Owing to the difficulty of excision, cervical infection is usually treated conservatively. Should sinuses occur they are scraped, and packed with gauze moistened with tincture of iodine.

Conservative measures include the administration of massive doses of potassium iodide, up to ʒii thrice a day. Iodised milk is especially beneficial, and is administered as described on p. 154. The injection of formaldehyde

(4 per cent.), copper sulphate (1 per cent.), or collosal copper along the edge of the indurated area is beneficial, but somewhat painful on account of the density of the tissues. If the streptothrix can be cultivated vaccine therapy should be tried.

A detailed description of syphilis and gonorrhœa is outside the scope of this work, and those requiring such should refer to one of the many textbooks on venereal diseases. We include here a general summary of these diseases, and affections of the various individual organs and structures are considered in their appropriate chapters.

SYPHILIS

The usual incubation period of acquired syphilis is from fifteen to twenty-one days, although variations of from seven to seventy days have been noted. Diagnosis has been revolutionised by the discovery in 1905, by Schaudinn, of the causative organism, the Spirochæta pallida. The spirochæte can be discovered in serum or scrapings from most surface lesions. If enlarged glands are present lymph can be aspirated with a fine needle, and examination will often reveal spirochætes.



(*Burroughs Wellcome & Co*)

FIG. 8.—Spirochæta pallida (corkscrew) and spirochæta refringens (spiral) Smear preparation from hard chancre.

By means of the dark-ground illumination a spirochæte is seen as a spiral organism resembling a corkscrew in appearance. On the average eight spirals are present, and the organism is about 8 microns in length (fig. 8).

The complement-fixation test, or Wassermann reaction, is usually positive in untreated cases, about three weeks after the appearance of the primary sore. Treatment should not be delayed until the test is positive, but commenced immediately the spirochætes are demonstrated. Treatment instituted while the serum is negative yields excellent prospects of permanent cure. In untreated late primary and secondary syphilis the W.R. is almost always positive. In the tertiary stage a positive result is obtained in about

80 per cent. of cases. If the central nervous system is affected the cerebro-spinal fluid may give a positive reaction, although the blood serum is negative. In some cases a doubtful reaction is rendered positive by a small "provocative" dose of arsenic. In addition to its diagnostic value the W.R. is also a valuable control regarding the efficacy of treatment.

Other conditions which render the serum definitely positive to the W.R. are yaws and leprosy. Weak reactions are sometimes obtained in scarlet fever, miliary tuberculosis, malaria, relapsing fever, and advanced malignant disease.

Precipitation tests are useful when elaborate technique is impossible, or curtailment of time is necessary. These tests depend upon the development of a flocculent precipitate when antigen and syphilitic serum are mixed and incubated. Although probably not quite as accurate as the W.R., this test is of great practical value.

Clinical Features.—Acquired syphilitic manifestations are roughly divisible into three stages.

Primary Stage.—In 96 per cent. of cases the primary sore or chancre is situated on the genital organs.

In the male the chancre is usually obvious, but in the female a primary sore on the inner aspect of the vulva is often unnoticed by the patient, and the infection is likely to progress well into the second stage before its real nature is recognised. Extragenital chancres occur on the lips (usually the upper, fig. 44), the tonsil, the anal margin, the nipple, the fingers, and rarely in other situations.

Primary sores on the lips usually result from kissing, and one case is recorded in which a gentleman with secondary ulceration of the mouth infected five young ladies at a dance, each of whom developed a chancre on the lip. Dental surgeons and accoucheurs are particularly prone to inoculation on the fingers, but "syphilitic onychia" are less common than formerly owing to the use of rubber gloves and more rigorous surgical cleanliness.

A primary sore is due to inoculation of an abrasion, and is first noticed as an indurated papule, which is somewhat irritable. Irritation or friction causes ulceration, and a typical Hunterian chancre develops. The ulcer presents a

definite margin, and fibrosis of the base leads to characteristic induration. In the case of vascular structures, such as the lip, considerable œdema of the underlying tissues is present. In about 20 per cent. of cases chancres are multiple, either as a result of infection of two or more abrasions, or owing to auto-inoculation of an apposing surface by the primary sore. The regional lymphatic glands become enlarged and firm, and are aptly described as "shotty." In the case of a penile chancre the dorsal lymphatic vessels can often be felt to be "wiry" when the subcutaneous tissue is rolled between the finger and thumb.

In some cases the initial papule disappears without ulceration, and the patient may be totally unaware of its presence. On the other hand, virulent secondary infection sometimes supervenes and the ulcer becomes acutely inflamed, with secondary acute lymphangitis and adenitis.

A primary chancre must be distinguished from a traumatic ulcer (which follows irritation of an abrasion), a soft sore (p. 529), an early epithelioma, and herpes, which is painful and commences as a crop of vesicles on an inflamed base.

Secondary stage, which commences when infection is disseminated by the blood-stream, and lasts for an arbitrary period of about six months. When blood infection occurs any organ or tissue in the body is liable to be affected.

The general manifestations of the secondary stage include malaise, anæmia, a varying degree of pyrexia, and generalised glandular enlargement. The epitrochlear, suboccipital, and posterior cervical glands are especially liable to enlarge. Alopecia is not uncommon.

Cutaneous eruptions, although varying widely in their natures, are usually characteristic. A syphilitic rash appears, as a rule, about eight weeks after infection, and is typically widely distributed in a symmetrical manner. The earliest manifestation is a roseolar rash due to hyperæmia of the cutaneous capillaries. Cellular infiltration and fibrosis may follow, with the formation of papules. If the infection

is virulent or the patient debilitated, pustules and ulceration are likely to develop. In some cases the rash exhibits a scaly appearance, somewhat resembling psoriasis, but differing from that condition in that the flexor surfaces are chiefly, if not entirely, affected.

The main characteristics of a syphilitic eruption are the dull red or coppery colour, the absence of irritation, the symmetrical distribution, and the polymorphic nature, i.e. two or three types of rash are often present simultaneously.

Muco-cutaneous junctions and mucous membranes are commonly affected during the secondary stage. Papules appear at such muco-cutaneous junctions as the anal margin, vulva, or angle of the mouth, or where cutaneous surfaces are constantly in apposition. As a result of their situation these papules become sodden, and frequently form large, foul, greyish masses, which are termed condylomata. Condylomata are intensely infectious, but disappear rapidly with general treatment and local cleanliness. The mucous membrane of the mouth is commonly affected. Moist papules or mucous patches are seen as circular raised areas, greyish in colour, and surrounded by hyperæmic mucosa. Ulceration occasionally occurs on the surface. Mucous patches are sometimes so large that they resemble condylomata, and if situated on the dorsum of the tongue, they were formerly described as "Hutchinson's warts."

"Snail-track" ulcers particularly affect the mucosa covering the soft palate and tonsils. These characteristic ulcers are shallow, greyish in colour, and exhibit well-defined edges. The mucous membrane of the nose is occasionally affected in a similar manner.

Warning.—The saliva in these cases is teeming with spirochætes. Gloves should always be worn, and tongue depressors rigorously sterilised.

At a later period of the secondary stage osteocopic pains or periosteal nodes are often in evidence. Transitory and usually symmetrical effusions may occur in the larger joints. Epididymitis occasionally develops and is sometimes

associated with nephritis and albuminuria. Iritis is not uncommon, and gives rise to pain, lachrymation, circum-corneal congestion, and a sluggish and irregular pupil. The colour of the iris may alter owing to œdema. At a later date such conditions as choroido-retinitis may develop. Perivascular infiltration and mesarteritis are likely to manifest themselves, especially in connection with the brain or cord, and neurological phenomena may result.

Rupia occasionally occurs as a late secondary manifestation, particularly in virulent cases. The discharge from cutaneous ulcers dries in successive layers, so that an excrescence of dried pus and debris gradually accumulates, and somewhat resembles a limpet.

Tertiary stage, which arbitrarily commences six months after infection, may last throughout the patient's lifetime. The characteristic pathological changes consist either of diffuse gummatous infiltration or local gumma formation, and almost any structure in the body is liable to be affected. In some organs both changes occur; thus a gummatous orchitis is sometimes associated with a local gumma, and a cirrhotic liver may harbour gummata.

A gumma is a mass of necrotic tissue, which is surrounded by a zone of cellular infiltration. Plasma cells, endothelial cells, giant cells, and fibroblasts are usually recognisable. Necrosis of tissue is partly due to toxins, and also to deficient blood supply resulting from endarteritis and surrounding fibrosis. If untreated, a gumma tends to enlarge and soften as the necrosis extends. If near the skin hyperæmia and induration are evident. The centre of the indurated area then softens and eventually breaks down. The gumma discharges, and typically a wash-leather slough is seen at the bottom of the cavity, or on the floor of the ulcer. The edges are characteristically sharply cut and circular in outline (fig. 9).

Under appropriate treatment a gumma usually absorbs with surprising rapidity, but occasionally it becomes walled-off by fibrous tissue, and eventually calcification may occur. In certain situations, notably the testis and bones, long-

standing gummata are resistant to medical treatment owing to the density of the surrounding fibrosis or sclerosis, which prevents remedial agents in the blood from reaching the diseased tissues. In these circumstances orchidectomy is advisable in the case of the testis, while guttering or tre-

FIG. 9.—Gummatous ulcers on the front of the left thigh. The edges are "punched out," and the margins typically circular or serpiginous.

phining of bone is necessary for the relief of pain caused by an endosteal gumma.

Gummatous ulcers, following subcutaneous gummata, are especially common in the upper portion of the leg, the backs of the thighs and forearms, and the face. A healed gumma leaves a typical "tissue-paper" scar which is pale and supple, and often surrounded by a pigmented area.

A gummatous ulcer of the leg has frequently been mistaken for a varicose ulcer (fig. 35). The following are the main points of distinction.

Varicose Ulcer	*Gummatous Ulcer*
Usually lower third of leg.	Upper part of leg.
Irregular shape, rounded edges, and granular base.	Circular or serpiginous in shape, sharply cut edge, and sloughing base.
Single and painful.	May be multiple and are painless.
History of years.	History of weeks or months.
Varicose veins present.	Other signs of syphilis present.

The surgical manifestations of parasyphilis are considered in their appropriate chapters.

Treatment.—Public Health Regulations of recent years have greatly reduced the incidence of syphilis. Clinics are available in all large towns for treatment, and laboratory facilities and salvarsan are at the disposal of medical practitioners, free of charge. In addition lectures, propaganda work, and increased self-respect which is engendered by better education, all encourage sufferers to avail themselves of facilities for treatment.

The treatment of syphilis falls into three groups—general, local, and specific.

(i) *General.*—As with any infection, the general resistance of the patient is an important consideration. Hygienic surroundings, adequate food, and suitable tonics are necessary. Iron is necessary in order to combat anæmia during the secondary stage. Alcohol interferes with specific treatment and must be avoided. Tobacco is allowed in moderation provided mercury or bismuth has not caused stomatitis or gingivitis.

(ii) *Local.*—No antiseptic of any description should be applied to a suspected chancre until the serum has been examined bacteriologically. Pending the examination a saline compress is applied. After the diagnosis is made the chancre is bathed twice daily with a weak antiseptic, and calomel ointment, 15–30 per cent., is applied. Circumcision is sometimes indicated, and if the chancre is situated on the

prepuce it is incidentally removed, but otherwise excision of the primary sore is not recommended.

Condylomata are treated by ordinary cleanliness and suitable dusting powders, such as one containing calomel, starch, and boracic acid. Oral manifestations require a mercurial gargle, or painting with perchloride of mercury in glycerine (1 : 2,000). Gummatous ulcers and sores are kept surgically clean and dressed with mercurial lotion.

(iii) *Specific.*—In 1909, Erhlich, at his 606th attempt, produced an arsenical preparation—*salvarsan*—suitable for intravenous injection. Subsequently neo-salvarsan (N.A.B. or "914") appeared and is more convenient than "606," as it can be given intramuscularly and in a more concentrated solution. Additional preparations are now available, which are more stable to exposure and less painful when injected. The therapeutic results obtained by arsenic are probably due to stimulation of increased resistance on the part of the tissues.

The patient should be carefully examined before embarking on a course of arsenical medication. Cardio-vascular lesions in particular are excluded, and the urine is examined for bile and albumin. An aperient should be taken the day before an injection, and alcohol forbidden. No vigorous exercise or food should be indulged in during two hours previous to or after an injection. Intramuscular injections are conveniently given into the upper and outer portion of the buttock, and must be injected sufficiently deeply to reach the muscle, as arsenic causes necrosis of the subcutaneous fat, with subsequent likelihood of an abscess (fig. 10).

(Burroughs Wellcome & Co.)

FIG. 10.—Intramuscular injection. The needle is inserted deeply into the upper and outer quadrant of the buttock.

Bismuth preparations are useful for patients who evince an intolerance to arsenic. Many preparations are available which may be injected intramuscularly. Dental hygiene is important before a course of bismuth is commenced, and the gums should be inspected at intervals.

Mercury is used in conjunction with arsenical preparations. It is most conveniently administered orally, commonly in the form of Hutchinson's pill, which contains gr. i of grey powder, and the same amount of Dover's powder (pulv. ipec. co.) is included in order to prevent diarrhœa and colic. Intramuscular injections are useful in that absorption of mercury is more certain, and the administration is under the direct control of the surgeon, also dosage can be recorded with precision. Various preparations are available, such as grey oil and calomel cream. The general principle is to administer the equivalent of gr. i of the metal weekly. Attention to oral hygiene is necessary during the course. Salivation and gingivitis indicate the onset of mercurialism, in which case injections are stopped, and magnesium sulphate and astringent mouth washes are prescribed.

Mercury inunctions and baths are but little used in this country.

Potassium iodide is indicated in the late secondary and tertiary stages. Its action is to stimulate the absorption of fibrous tissue, and thus expose infected areas to the influence of remedies previously mentioned. Potassium iodide (gr. x–gr. xx) should be combined with an alkali, such as bicarbonate of soda, in order to obviate gastric disturbance. Aromatic spirits of ammonia combats depression, and liquor arsenicalis is included if the patient evinces a tendency to iodide eruptions. The mixture should be well diluted, and taken after meals, in order to promote absorption.

Various " courses " of treatment are advocated, but no hard-and-fast rules are permissible—each patient should be treated individually and degrees of tolerance vary widely. For details regarding courses textbooks dealing with this speciality should be consulted.

CONGENITAL SYPHILIS

Congenital syphilis is arbitrarily divided into four grades of severity :

(i) Miscarriage during the early months

(ii) Birth of a stillborn and often macerated foetus.

(iii) The infant presents obvious syphilitic features, such as wasting, snuffles, skin eruptions.

(iv) The child is apparently healthy, but develops syphilitic stigmata during the ensuing weeks.

The following are the more important lesions in connection with inherited syphilis :

Mucous Membranes.—Inflammation of the muco-periosteum of the nose causes a purulent discharge known as "snuffles." Mucous patches, gummatous ulceration of mucous membranes and adjacent skin and condylomata

FIG. 11.—Ulceration of a few weeks' duration due to congenital syphilis. The nose has previously been partially destroyed. Hutchinson's teeth and interstitial keratitis are also present. (Sequeira's *Diseases of Skin.*)

occur. Radiating scars or rhagades (fig. 11) are sometimes left at the angles of the mouth.

Skin.—A roseolar rash is not uncommon in the early months, especially on the buttocks. Papular or pustular eruptions, usually arranged in circles or crescents, appear

on the flexor surfaces. Nodular infiltration of the skin, especially that of the face, sometimes occurs in older children, and resembles lupus vulgaris but extends with greater rapidity and is more destructive.

Teeth.—The milk teeth erupt late and are ill-formed. The permanent incisors are peg-shaped, so that the base is wider than the edge, and present a well-marked notch (fig. 655). The central part of the crown of the first permanent molar is maldeveloped, a feature more obvious in the lower jaw, and known as "Moon's turreted molar."

Eye.—Iritis, sometimes accompanied by cyclitis, occurs in young children. The most characteristic lesion is interstitial keratitis, which usually appears between the ages of 8 and 16 years. The first indication is a "ground-glass" appearance of the cornea, associated with photophobia and lachrymation. "Salmon patches" occur later, due to leashes of newly formed vessels. One eye only is affected at first, but the second eye is subsequently involved. Prognosis should be guarded, as although most cases gradually subside, yet opacities may remain in the cornea, or deeper-seated mischief, which cannot be recognised owing to corneal opacity, may have occurred.

Ear.—Acute otitis media may result from nasal infection. Nerve deafness sometimes develops about puberty, and is often associated with interstitial keratitis.

Bones.—Osteochondritis usually appears during the first six months and gives rise to pain and swelling of the large epiphysis, the "pseudo-paralysis" of infants. The epiphysis is broad and irregular, yellow in colour, and the adjacent periosteum is thickened. Separation of the epiphysis sometimes occurs.

From the sixth year onwards periostitis and sclerosis occur. The tibia is characteristically affected (p. 802). Parrot's nodes occur on the skull bones.

Breaking-down gummata lead to necrosis of the palate and nasal septum. In the latter case the typical depression of the bridge results.

Joints.—The characteristic affection is Clutton's joint,

which typically presents itself as a painless effusion into a large joint, most commonly the knee. It is usually bilateral (p. 861).

Central Nervous System.—Some degree of mental deficiency is common. At puberty juvenile tabes, or more rarely general paralysis, occasionally develops.

Other Organs.—A diffuse interstitial fibrosis occasionally destroys the lungs. Syphilitic cirrhosis of the liver and splenic enlargement are not uncommon. Orchitis may be bilateral, and if occurring before puberty results in impotence.

Treatment.—Prophylactic treatment is eminently desirable, and as a rule the mother is very tolerant to treatment during pregnancy. A comparatively healthy child is often the reward of efficient ante-natal treatment. Treatment of the child should be instituted immediately after birth. Intramuscular or intravenous arsenic is given twice a week. It is advisable to give the first few doses intravenously into the superior longitudinal sinus, via the anterior fontanelle. Treatment must be continued for at least two years, and the child should be kept under observation for a further period of two years.

GONORRHŒA

In 1879 Neisser discovered the specific kidney shaped coccus which occurs in pairs, and which is gram negative. On examination of suspected pus only a few polymorphonuclear cells are found to be affected (fig. 12). The probable explanation of this characteristic feature is that the cell has been killed by toxins and so the organisms have multiplied without hindrance. As a rule organisms are readily identified by the usual methods of staining, but in doubtful cases culture is necessary. The most appropriate medium is nutrient blood agar, and in forty-eight hours typical clear colonies resembling dewdrops appear.



(*Burroughs Wellcome & Co.*)

FIG. 12.—Gonococci.

The complement-fixation test is a valuable means of diagnosis when the actual gonococcus cannot be detected.

Acute Stage

In the Male.—The incubation period is from one to eight days. The early symptoms are itching and redness of the meatus, the lips of which are sticky. A viscid discharge appears which soon becomes thick and yellowish. Anterior urethritis develops within a day or two with the characteristic symptoms of scalding pain on micturition, a diminished stream, or even acute retention. Malaise and slight elevation of temperature are present during the acute stage. After ten to fourteen days acute symptoms abate, but the discharge persists.

Posterior urethritis is liable to occur at any time, either from extension of the infection or ill-advised treatment, such as inefficient irrigation or the passage of instruments.

Posterior urethritis is recognised by the frequency of micturition, with slight hæmaturia at the end of the act, aching in the perineum, and turbidity of a second specimen of urine after the first flow has washed out the anterior urethra. When the posterior urethra is first infected, symptoms of toxæmia are usually pronounced.

Local Complications.—*Anterior urethritis.*—Folliculitis following infection of glands of Littré is a common complication. Balanitis is sometimes troublesome, and chordee may result from œdema of the corpus spongiosum or corpora cavernosa. Cowperitis occasionally occurs on one or both sides. Œdema of the skin is liable to cause paraphimosis, and in some cases a lymphatic œdema persists.

Posterior urethritis.—Acute prostatitis causes rectal and perineal pain which is worse on defæcation. Retention of urine is likely to occur if suppuration ensues. The inflamed prostate is easily palpable per rectum. Acute vesiculitis causes frequent and painful emissions of purulent or blood-stained serum. Epididymitis usually occurs from the third to the fifth week, and is preceded by pain in the groin due to inflammation of the spermatic cord (funiculitis).

Basal cystitis is common and causes pain at the end of micturition.

Chronic or Latent Stage

The discharge is often very inconsistent and may only occur after such events as undue exercise or alcoholic excess. Typically a "morning dewdrop" appears, which is thick and whitish in colour. Massage of the prostate and vesicles and examination of any expressed fluid will probably reveal latent infection. Partial emptying of the bladder followed by prostatic massage and completion of the act is a valuable test for posterior urethritis and prostatitis. Any threads which appear can be examined bacteriologically.

Urethroscopic examination requires considerable experience, but readily exposes folliculitis, erosions, abscesses, and other abnormalities, and also allows the application of local treatment.

Local Complications.—Chronic prostatitis, with which is associated chronic vesiculitis, is a common cause of persistence of infection. Inflammation of the glands of Littré or lacunæ is also a frequent cause of relapse. Epididymitis is encouraged by the passage of bougies before the disappearance of symptoms of acute urethritis. Strictures, formerly common, are becoming increasingly rare. They are due to such conditions as local infiltration of the wall of the urethra, or chronic folliculitis, and are predisposed by undue zeal in treatment, such as irrigation with excessively strong antiseptics. Gonorrhœal warts occasionally occur on the glands or prepuce as a result of irritation from the discharge.

In the Female.—The early symptoms are much less acute than in the male, and the incubation period is shorter, being only two to four days. Infection usually commences in the urethra, and Bartholin's glands are commonly infected at the same time. A vaginal speculum should not be passed in the acute stage, otherwise an uninfected cervix is liable to be contaminated.

The symptoms of acute infection include a sensation of heat and discomfort of the vulva, and pain on micturition.

Should the cervix be infected a blood-stained discharge is noticed and backache follows.

Complications.—Vaginitis is common in children who are accidently infected, but adults usually escape. Cervicitis sometimes occurs spontaneously, or is encouraged by unwise instrumentation. Salpingitis, which is sometimes accompanied by ovaritis or peritonitis, is a dreaded complication which is apt to cause sterility. Proctitis occasionally occurs, and is commoner than in males owing to the greater ease of infection.

Chronic or Latent Stage

Chronic gonorrhœa is due to urethritis, cervicitis, or infection of Bartholin's glands, and any discharge from these organs must be meticulously examined in suspected cases. The symptoms accruing from chronic infection are very slight and the patient may merely notice an occasional yellowish discharge.

Complications.—Chronic endometritis is common, and results in menorrhagia, metorrhagia, and mild dysmenorrhœa, associated with backache. Salpingitis is often quiescent, but exacerbations are liable to follow sexual excess, debility, or labour. Warts are not uncommon and are sometimes large and numerous.

OPHTHALMIA NEONATORUM

Infection at birth is the cause of 50 per cent. of cases of blindness in infancy, and 16 per cent. of adult blindness. The incubation period is 24–48 hours, and is followed by chemosis, lachrymation, and discharge. Corneal ulceration and sloughing are liable to follow. Prophylactic measures include a vaginal douche at the onset of labour, and instillation into the infant's eyes of some preparation of silver, such as collosal argentum, or silver nitrate ($\frac{1}{4}$ per cent.).

Should infection occur the eye must be irrigated two hourly with 1 : 8,000 permanganate of potash in an ophthalmic irrigating flask, and when acute inflammation has subsided, the lids are everted and painted with 5 per cent. argyrol. In unilateral cases the child lies on the

affected side, the sound eye being protected by a Buller's shield.

Metastatic Complications.—Infection of joints and fibrositis are common (p. 860). Endocarditis occurs as a rare complication, and is associated with pyæmic abscesses. Iridocyclitis is not uncommon, especially in chronic cases, and necessitates repeated instillation of atropine.

Treatment.—Prophylactic treatment largely depends on better education and preventive measures. Inunction with 30 per cent. calomel ointment before exposure to infection, and subsequent washing with 1 : 2,000 potassium permanganate solution, is almost certainly efficient. Prophylactic outfits, with directions for use, are readily obtainable. For the female, antiseptic tablets or jellies are available and should be supplemented by a vaginal douche of permanganate after exposure.

Abortive treatment is only successful if applied before the appearance of the purulent discharge. Irrigations of permanganate or 1 per cent. silver nitrate are satisfactory. Irrigation of the mucosa by strong disinfectants is to be avoided.

Acute gonorrhœa requires careful and methodical treatment. If possible the patient should remain in bed for the first week, otherwise exercise is strictly limited. Plenty of bland fluids, a non-stimulating diet, and urinary antiseptics are prescribed. The patient is warned of the risks of conjunctivitis and transmission of infection. Some surgeons recommend irrigation of the anterior urethra only for the first fortnight, but urethro-vesical irrigation seems to add little to the risk of posterior urethritis and its complications. A solution of 1 : 10,000 permanganate of potash is suitable at first, and the strength is gradually increased as the inflammation subsides. If the patient is unable to attend for frequent irrigation, or cannot irrigate himself, then injection of silver salts, such as argyrol 1 per cent., or collosal argentum, are useful substitutes. After a fortnight's treatment prostatic massage assists in the expulsion of pus and infected mucus. Treatment is necessary for six weeks, after when

symptoms, discharge, and pyuria should have disappeared. The patient is then instructed to take vigorous exercise and possibly alcohol in moderation. After three days a provocative dose of vaccine is given, and a sound is passed the following day. If no discharge results examinations are made, including prostatic massage at intervals of three and six months.

Chronic gonorrhœa (*syn.* gleet) is treated by urethro-vesical irrigations, which can be self-administered after a little practice. Persistent posterior urethritis is combated by weekly instillations of silver nitrate ($\frac{1}{2}$–1 per cent.) into the prostatic urethra. Periodic dilatation by metal sounds, once or twice weekly, squeezes out infected material from the glands and crypts. Kollmann's adjustable dilator (fig. 13)

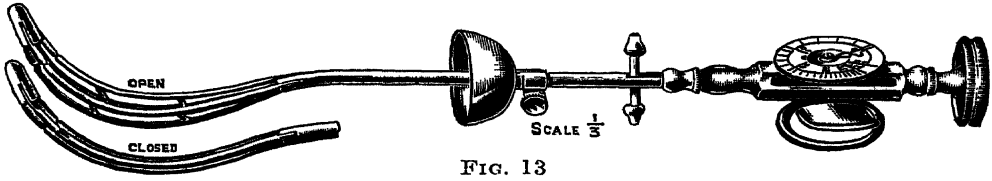

FIG. 13

is useful for dealing with the prostatic urethra. With the assistance of an operating urethroscope such local conditions as follicular abscesses and ulcers receive appropriate treatment. Rectal diathermy of the prostate is useful in skilled hands.

CHAPTER III

TUMOURS

A TUMOUR is a collection of cells of independent growth, which fulfils no useful function. The term "tumour" should be reserved for new-growths, and its loose application to such conditions as inflammatory swellings, or enlargement of an organ due to hypertrophy, is to be condemned.

CAUSATION

Over 300 years ago it was stated that "any kind of external irritation, whether from motion, heat or acrimony, may cause cancer," and in spite of an enormous amount of research work and expenditure of money we have added little to our knowledge. Many years ago it was observed that the natives of Kashmir were prone to develop carcinoma of the skin on the inner sides of the thighs and lower abdomen. This is due to their habit of endeavouring to keep warm by squatting and hugging earthenware pots which contain glowing charcoal (the pot being termed a kangri), with the result that the adjacent skin is irritated by heat. Also it is common knowledge that women can swallow in comfort fluids at a considerably higher temperature than men can tolerate, which fact probably explains the greater incidence of post-cricoid carcinoma in females.

"Chimney-sweeps'" cancer of the scrotum was due to the chronic irritation produced by soot, which collected in the rugæ of the scrotum. Owing to the growing custom of taking regular baths, this variety of cancer is nearly obsolete, but chronic irritation from chemicals, tar, etc., occasionally produces squamous-celled carcinoma of the exposed skin in those who work among these irritants. Again, carcinoma of the lower lip was formerly prevalent when clay pipes were popular, and carcinoma of the tongue is occasionally seen at the site where tobacco smoke continually impinges on the tongue.

Regeneration of tissue appears to encourage malignant changes in the newly formed cells, which are presumably in a state of instability. Primary carcinoma of the liver is sometimes seen in cases of cirrhosis, and apparently arises from the liver cells which are endeavouring to regenerate. Similarly, squamous-celled carcinoma occasionally occurs in a chronic ulcer, and a fibro-sarcoma arising in a scar is not uncommon (fig. 24). In some situations the site of fusion of embryonic elements constitutes a favourite position for the development of carcinoma. On the tongue, for example, carcinoma is prone to occur at the junction of the anterior two-thirds and the posterior third, also carcinoma is not uncommon at the junction of the anal canal and the rectum.

Tumours reproduce cells which are similar to those from which they arise, although if the tumour grows rapidly the resemblance becomes less obvious (anaplasia). It sometimes happens that the epithelium from which the tumour grows has already changed its characteristics. The gall bladder is normally lined by columnar epithelium, but the advent of cholecystitis may result in the epithelium becoming cuboidal or even squamous, in which case the new-growth is composed of these more primitive cells.

CLASSIFICATION

The classification of tumours is fraught with difficulty owing to their variety and sometimes atypical appearances. Following the suggestion of Adami, tumours can be subdivided into two groups, teratomata and blastomata.

Teratomata are composed of cells of one individual within the tissues of a second individual. These tumours

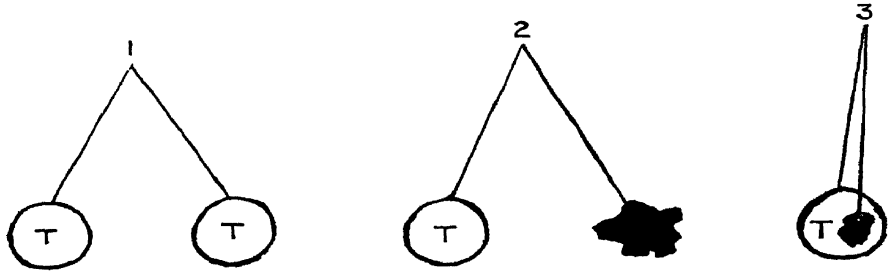

FIG 14.—Twins and Teratoma.

1. Normal twins. 2. One normal twin, the other an acardiac, anencephalic monster. 3. A teratoma—the twin brother's remnants are included in his normal brother.

may contain representative cells from all three embryonic layers, for example, a dermoid, which sometimes contains hair, teeth, muscle, gland tissue, etc. Included in this group is the chorion-epithelioma, which very occasionally occurs in the testicle, and is due to inclusion of placental remnants.

Teratoid tumours are a subdivision of teratomata. They are composed of cells of the same individual which apparently become displaced during development (fig. 14). Until recently the mixed parotid tumour was considered to be a teratoid tumour, but apparently it should be regarded as a new-growth of a parotid duct and therefore epithelial in

origin. Refinements of staining indicate that the substance formerly considered to be cartilage is in reality altered mucin secreted by the gland. Sequestration dermoids constitute a type of teratoid tumour, as does the exceedingly rare rhabdomyoma of the kidney.

Blastomata are produced by abnormal growth of component cells of the individual, and they may arise from any of the three embryonic layers.

From the clinical standpoint tumours thus formed are either innocent or malignant.

An innocent or benign tumour is usually encapsulated, and does not disseminate. Frequently they are multiple. The symptoms produced are due to its size and position.

Malignant tumours are usually single, and are liable to infiltrate surrounding tissue. They nearly always continue to grow, and prove fatal in the absence of adequate treatment. In a very small minority of cases they may disappear spontaneously, a termination which has been observed in the case of a carcinoma of the lip. The tumour is supposed to have disappeared in patients who succumb to malignant glands of the neck, when no primary growth is discovered at necropsy. Probably in most cases a very small growth in some obscure position, such as the naso-pharynx, has been overlooked. Very malignant tumours, such as secondary deposits of chorion-epithelioma, are apt to destroy adjacent blood-vessels with such avidity that they become surrounded by clot. They are then isolated from their source of nutriment, and consequently perish.

The commonest forms of malignant tumours are carcinoma, sarcoma, and melanoma malignum.

Methods of Spread of Malignant Tumours

(i) *Local Extension.*—Carcinomata and sarcomata both infiltrate adjacent tissues and spread by direct invasion. This feature is frequently the first evidence of malignancy when the tumour is examined microscopically. Tissues are not always invaded in a uniform manner. Invasion takes place most readily along connective-tissue planes, whereas

fascia or aponeurosis forms a temporary barrier. An avascular structure, such as articular cartilage, resists invasion to a remarkable extent. Other factors influence local extension ; thus it is alleged that the spread of a rodent ulcer is checked when the growing edge reaches an area of skin supplied by a different sensory nerve. Also a carcinoma of the pyloric end of the stomach rarely extends into the duodenum.

(ii) *Blood-stream.*—This is the most common method of dissemination of a sarcoma, as the venous clefts, so typical of a sarcoma, readily permit malignant cells to enter the blood-stream. The malignant emboli from a sarcoma are most likely to be arrested in the lungs, where they form secondary deposits, often accompanied by a blood-stained effusion. It is probable that in some cases the malignant cells grow along the pulmonary capillaries into the veins, and so reach the systemic circulation.

Dissemination by the blood-stream is usually a late feature of carcinoma, as the blood-vessels preserve their normal construction However, a carcinoma of the kidney not infrequently invades the renal vein, with the result that secondary deposits are found in the lungs.

(iii) *Lymphatics.*—The spread of carcinoma along lymphatics occurs both by permeation and by embolism. In the former case the malignant cells grow along the lymphatic vessels from the primary growth, sometimes in a retrograde direction. The presence of the cells in the lymphatics stimulates a perilymphatic fibrosis, which compresses and destroys the malignant cells, but this destruction does not keep pace with the rate of malignant cell growth. A few cells are always ahead of the fibrosis, and so reach the shelter of a lymphatic gland, where they multiply in safety. Other structures, notably bones, are sometimes affected by lymphatic permeation.

In some instances, notably melanoma malignum, occasional groups of cells overcome the surrounding fibrosis, and give rise to intermediate deposits between the primary growth and the glands (fig. 28).

In the case of embolism cancer cells invade a lymphatic vessel, and are carried by the lymph circulation to the corresponding gland, so that glands comparatively distant from the tumour are liable to be involved in the early stages.

(iv) *Inoculation.*—Inoculation of carcinoma has been observed in situations where skin or mucous membrane is closely in contact with a primary growth. Examples of this "kiss cancer" are carcinoma of the lower lip affecting the upper, and carcinoma of the labium major, giving rise to a similar growth on the opposite side of the vulva.

Recurrence after operation is, in some cases, due to infection of the wound by malignant cells. Examples of this mischance are the appearance of a papilloma in the bladder scar after suprapubic removal of a primary growth, and nodules of carcinoma in the scar of the incision after radical removal of the breast.

(v) *Gravity.*—Cells from a carcinoma in the upper abdomen sometimes become detached and gravitate to the pelvis or ovaries. This transcœlomic method of inoculation occasionally gives rise to malignant ovarian tumours (Krukenberg's tumour), which may mask the presence of the primary growth.

(vi) *Physiological propulsion.*—It is alleged that carcinoma cells from the stomach have passed along the alimentary canal and given rise to carcinoma of the rectum. Also a papilloma of the kidney is usually associated with similar tumours in the ureter and sometimes in the bladder.

PAPILLOMA

A papilloma consists of a central axis of connective tissue, blood-vessels, and lymphatics; the surface is covered by epithelium, either squamous, transitional, cuboidal, or columnar.

The surface of a papilloma may be merely roughened or composed of innumerable delicate villous processes, as in the case of the kidney and bladder. In these situations papillomata resemble malignant tumours, in that they

tend to recur after apparently complete removal, and secondary growths arise by implantation.

Also, as in the case of a papilloma, in a duct of the breast actual malignant changes are likely to supervene.

Common sites for papillomata are the colon, the tongue and cheek, the larynx and the walls of cysts, particularly in connection with the breast and ovary.

Papillomata are sometimes due to infection, as in the case of venereal warts, which affect the skin in the neighbourhood of the genital organs. Papillomata in special situations are dealt with in the appropriate chapters.

FIBROMA

Fibromata are apt to occur in connection with fascia, aponeurosis, muscle and nerve sheaths, or connective tissue of organs. They are therefore widely distributed throughout the body.

In some situations, notably the breast, glandular tissue is incorporated amongst the fibrous stroma, so that the tumour is in reality a fibro-adenoma.

Fibromata are occasionally multiple, as in the case of von Recklinghausen's disease, or neurofibromatosis (*vide* p. 50).

Clinically a typical fibroma presents itself as a smooth rounded swelling, either firm or elastic in consistency, according to whether it is of the " hard " or " soft " variety. It is painless, unless growing from a nerve sheath, in which case pressure affects the adjacent nerve fibres and causes pain. On section a fibroma shows whorls of fibrous strands, and is not unlike the cross-section of an onion.

Types of Fibromata

Hard.—These tumours grow slowly, and do not attain a large size. All grades of hardness exist, according to the relative proportion of fibrous and cellular tissue.

Soft, which may be so cellular that a section closely resembles a sarcoma, and as they occasionally become sarcomatous the innocent tumour imperceptibly undergoes malignant changes. The softer a fibromata is the larger

it is likely to grow, and the more likely it is to become sarcomatous.

Recurrent (*syn.* "Recurrent Fibroid of Paget"). - Examples of this type are the fibromata of muscle sheaths, the fibrous polyp of the nose, and the fibrous epulis (p. 110) The tumours presumably commence as true fibromata, but gradually become sarcomatous. This change is hastened by incomplete efforts at removal (fig. 15). The moral is that wide excision should be practised in all cases, so that the tumour will not be "recurrent."

FIG. 15. Fibro-sarcoma growing from the sheath of the erector spinæ muscle. Two previous attempts had been made to remove the tumour.

Desmoid.—This is an unusual type of fibroma occurring in the abdominal wall of middle-aged females, particularly in those who have borne children. The tumour is a typical fibroma, with the exception that it has no capsule and invades the abdominal muscles, so much so that islands of muscular tissue become incorporated in the tumour. X-rays usually cause regression of the desmoid, but if this is ineffectual, or should the growth recur, then excision should be performed with a free hand.

Keloid.—These tumours occur in scars, particularly those following burns. The tendency to develop a keloid is inherited, and is particularly in evidence in tuberculous and negroid families. In appearance a keloid is smooth, sometimes lobulated or even claw-like, and may invade the subcutaneous or subfascial tissues. Microscopically, the structure is similar to that of a soft fibroma. A keloid never becomes malignant, and though it may persist for years, the ultimate tendency is to disappear gradually.

Excision of a keloid should never be performed, as

recurrence is the rule. If unsightly, the application of radium or X-ray therapy causes a satisfactory diminution in the size of the tumour.

LIPOMA

DIFFUSE lipoma occasionally occurs in the subcutaneous tissue of the neck, from which it spreads on to the pre-auricular region of the face. It is associated with excessive beer drinking, and therefore is less common than formerly,

FIG. 16.—Calcification in a large pedunculated lipoma of the thigh which had been present for over twenty years.

owing to the rise in price and inferior quality of that commodity. The tumour is not obviously encapsulated, and gives rise to no trouble beyond being unsightly. Portions of the tumour should be excised if the patient wishes to improve his appearance.

MULTIPLE lipomata are not uncommon. The tumours remain small or moderate in size ; and are sometimes painful, in which case the condition is probably one of neuro-lipomatosis. Dercum's disease (*vide* p. 594) is an associated condition.

CIRCUMSCRIBED lipomata are among the commonest of tumours. The characteristic features are painlessness, the presence of a definite edge, and lobulation. If the proportion of fibrous tissue is not excessive a sense of fluctuation can be obtained. These tumours have a widespread distribution, as they can occur in any part of the body where

FIG. 17.—Erosion of the skull due to a sub-aponeurotic lipoma.

fat is found. As would be expected, a lipoma deeply situated is liable to be mistaken for other swellings, as difficulty arises in recognising the typical signs.

Should the lipoma contain an excessive amount of fibrous tissue it is termed a fibro-lipoma. Occasionally considerable vascularity is present, often with telangiectasis of the overlying skin, in which case the tumour is a nævo-lipoma. Myxomatous degeneration and calcification (fig. 16) sometimes occur in lipomata of long duration.

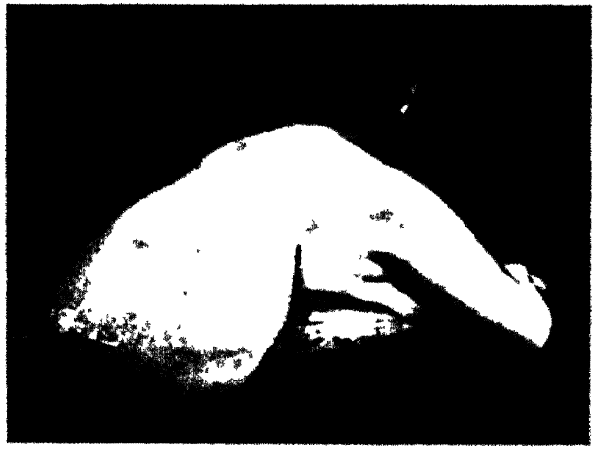

FIG. 18. A subcutaneous lipoma which weighed 30 lb. (Dr. Ward Cousins's case.)

Clinically, circumscribed lipomata are conveniently classified according to their situation:

(i) *Subcutaneous* are most commonly found in the shoulders or back (fig. 18), although no part of the body is immune. Usually the characteristic features are readily ascertained. It must be remembered that a lipoma is occasionally present over the site of a spina bifida. A careful examination should distinguish such conditions as a tuberculous abscess or a sebaceous cyst, which may superficially resemble a lipoma. Subcutaneous lipomata occasionally become pedunculated, or the influence of gravity may cause the tumour to gradually change its position.

(ii) *Subfascial.*—Lipomata occurring under the palmar or plantar

fascia are liable to be mistaken for tuberculous tenosynovitis, as the dense, overlying fascia masks the definite edge and lobulation of the tumour. However, the swelling is circumscribed, and wasting of muscles is negligible. Difficulty is encountered in complete removal as pressure encourages the tumour to ramify. Subfascial lipomata also occur in the areolar layer under the epicranial aponeurosis, and if of long duration they erode the underlying bone, so that a depression is palpable on pushing the tumour to one side (fig. 17).

FIG. 19.—Intramuscular lipoma of the forearm.

(iii) *Subsynovial* arise from the fatty padding around joints, especially the knee. They are apt to be mistaken for Baker's cysts, but their consistency is constant, whether the joint is in extension or flexion.

(iv) *Intra-articular.*—The term "lipoma arborescens" is somewhat misleading, as the condition is, strictly speaking, not neoplastic, but rather a fatty and fibrous infiltration of synovial tags.

(v) *Intramuscular.*—These occur particularly in the thigh or around the shoulder. Owing to transmitted pressure the tumour becomes firmer when the adjacent muscles are contracted. Weakness or aching results, owing to mechanical interference with muscular action. The condition is often difficult to distinguish from a fibro-sarcoma, and exploration is usually necessary in order to determine the actual nature of the swelling (fig. 19).

(vi) *Parosteal* occasionally occur under the periosteum of a bone, and are difficult to diagnose with confidence if deeply situated.

(vii) *Subserous* are not common, but are sometimes found beneath the pleura, where they constitute one variety of innocent thoracic tumour. A retroperitoneal lipoma may grow to enormous dimensions, and simulate a hydronephrosis or pancreatic cyst. A lipomatous mass is frequently found at the fundus of the sac of femoral hernia, but this is a condensation of retroperitoneal fat rather than a neoplasm.

(viii) *Submucous* occur under the mucous membrane of the respiratory or alimentary tracts. Very rarely a submucous lipoma in the larynx causes respiratory obstruction. A submucous lipoma occasionally occurs in the tongue. One situated in the intestine is

likely to cause an intussusception, which is the first indication of its presence (fig. 20).

(ix) *Extradural.*—A lipoma is a rare variety of spinal tumour. Owing to the absence of fat within the skull intracranial lipomata do not occur.

(x) *Intra-glandular.*—Lipomata occasionally arise from the fat within the lobules of the breast, and they have been described as occurring in the pancreas, under the renal capsule, and in connection with other organs.

TREATMENT. — If a lipoma is causing trouble on account of its site, size, or position, removal is indicated. Owing to its definite capsule and comparative avascularity, removal of a lipoma is usually accomplished without difficulty.

FIG. 20.—Intussusception caused by a submucous lipoma of the cæcum. (R.C.S. Museum, 1273.3.)

ADENOMA

Adenomata arise in connection with secretory glands, and resemble to a greater or lesser extent the structure from which they arise. They are encapsulated tumours, and with the possible exception of those occurring in the thyroid gland, fail to produce secretion. Occasionally a fibroma contains a large proportion of fibrous tissue, e.g. the hard fibro-adenoma in the breast, while in other situations, notably the

pancreas and thyroid gland, cystic degeneration is common. Adenomata arising from secretory glands of mucous membrane are liable to pedunculation, as in the case of a rectal "polyp." Simple enlargement of the prostate is due to a diffuse hyperplasia of glandular tissue, usually associated with multiple adenomata. Adenomata in certain situations tend to undergo malignant changes, especially those occurring in the prostate.

NEUROMA

True neuromata are rare tumours, and occur in connection with the sympathetic system. They comprise the following types :

(*a*) *Ganglioneuroma*, which consists of ganglion cells and nerve fibres. It arises in connection with the sympathetic cord, and therefore is found in the retroperitoneal tissue, or in the neck or thorax. It usually occurs in children, and is entirely innocent and causes symptoms merely by the size and position.

(*b*) *Neuro-blastoma*, which is less differentiated than the ganglioneuroma, the cells being of an embryonic type. The tumour somewhat resembles a round-celled sarcoma, and disseminates by the blood-stream.

(*c*) *Myelinic neuroma*, composed only of nerve fibres, ganglion cells being absent. The very few tumours which have been reported have arisen in connection with the spinal cord or pia mater.

False neuromata arise from the connective tissue of the nerve sheath. They are either localised single tumours, or diffuse.

(i) Local

A single neuroma is usually found in the subcutaneous tissue, although occasionally a "trunk neuroma" grows from a large cranial or peripheral nerve, the acoustic tumour being an example. The "painful subcutaneous nodule" forms a smooth firm swelling, which may be moved in a lateral direction, but is otherwise fixed by the nerve from which it arises. Pain is likely to occur from pressure of the tumour on the nerve fibres which are spread over its surface.

Cystic degeneration or sarcomatous changes occasionally occur.

The tumour should be removed with the minimum of damage to the nerve. If it is necessary to resect a portion of an important nerve, the cut ends are sutured.

(ii) Diffuse

(a) *Molluscum Fibrosum*

This condition consists of numerous soft fibromata, which grow from the terminal twigs of cutaneous nerves (fig. 21). They are usually distributed freely over the body, with the exception of the palms and soles. The tumours vary in

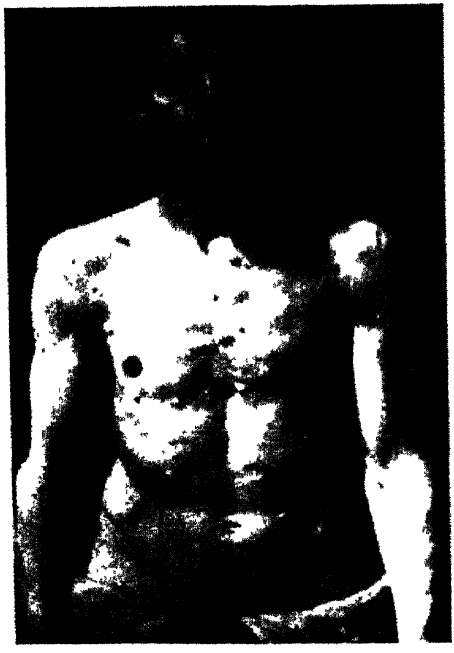

Fig. 21.—An early case of molluscum fibrosum.

Fig. 22. An advanced case of generalised neurofibromatosis. (R.C.S. Museum.)

size from a pin's head to a hen's egg. Pigmentation of the skin is sometimes present, and tumours are occasionally present on deeper nerves. Sarcoma may develop in connection with the tumour, or melanoma from the pigmented areas.

This condition is distinguished from molluscum contagiosum, in that the swellings are not confined to exposed surfaces, umbilication is absent, and the tumours of neurofibromatosis are usually pedunculated.

(*b*) *Generalised Neurofibromatosis* (*syn.* von Recklinghausen's Disease of Nerves)

Cranial, spinal, and peripheral nerves may all be diffusely or nodularly thickened (fig. 23). The overgrowth occurs in connection with the endoneurium. As in the case of molluscum fibrosum, pigmentation occurs and sarcomatous changes may develop.

(*c*) *Plexiform Neurofibromatosis*

This rare condition usually occurs in connection with branches of the fifth cranial nerve (fig. 23), although examples have been met with in the extremities. The affected nerves become enormously thickened as a result of myxo-fibromatous degeneration of the endoneurium. If occurring in the scalp the underlying skull may be eroded, and in other situations the involved skin sometimes hangs down in pendulous folds. Plexiform neurofibromatosis is sometimes associated with the generalised type of neurofibromatosis. Sarcoma rarely develops.

Fig. 23.—Plexiform neurofibromatosis in connection with the second division of the trigeminal nerve on the right side. The subcutaneous tissues are greatly thickened, and the patient was unable to open his eye. (Courtesy of J. R. M. Whigham.)

(*d*) *Elephantiasis Neuromatosa*

This rare condition is congenital in origin, and usually affects one leg. The skin and subcutaneous tissues become greatly thickened, so that the patient finds walking increasingly difficult. The skin is coarse, dry, and thickened, resembling an elephant's hide. Other types of neurofibromatosis are sometimes associated. Amputation is usually necessary.

Amputation

Fusiform swellings occur at the ends of divided nerves after amputation of a limb. These swellings consist of fibrous tissue and coiled nerve fibres. As they give rise to pain, their development should be discouraged by pulling down, crushing, and ligaturing all divided nerves before suturing the flaps after an amputation.

CARCINOMA

Carcinoma, the commonest form of malignant new-growth, is alleged to be increasing in frequency. This increase is probably apparent rather than real, and is explained by more accurate methods of diagnosis. In some situations, such as the alimentary canal and bronchi, an actual increase

has occurred during recent years. Greater petrol consumption, with consequent contamination of air by irritating fumes, is an alleged explanation of the frequency of bronchial carcinoma. Fortunately, owing to increasing avoidance of predisposing causes, other types of carcinoma are less frequent than formerly, notably that of the skin, lip, and tongue.

Carcinomata are conveniently classified according to the type of cell from which they arise, as, for example, glandular, squamous, or basal-celled.

(i) GLANDULAR is widely distributed, and commonly occurs in the alimentary tract, breast, and uterus, and less frequently in the kidney, prostate, gall bladder, thyroid, and other organs.

Glandular carcinomata not only arise from secreting epithelium, but also from ducts, in which case the cells are cubical. The three pathological types of glandular carcinoma are as follows :

Alveolar, in which the cells are arranged in circumscribed groups or alveoli, no glandular structure being recognisable. This type commonly occurs in the breast, and the majority of cells are spheroidal in shape.

Adeno-carcinoma, so called from the tendency of the cells to form acini, which resemble those of the gland from which they are derived. The alveoli are ductless, and the walls are composed of layers of cells which invade the surrounding tissues. This type is common in the stomach and colon. The cells of the primary growth, and even of the metastases, sometimes retain secretory powers (p. 180).

Colloid, which develops in tumours arising from cells which secrete mucin, and is a degenerative process. The mucin permeates the stroma of the growth, which appears as a gelatinous or semi-translucent mass. This type is not uncommonly seen in growths of the colon and gall bladder.

Glandular carcinoma is also subdivided into various types, e.g. encephaloid, scirrhus, and atrophic scirrhus. These distinctions depend clinically on their rate of growth, and pathologically on the relative proportions of fibrous tissue

and gland elements. They typically occur in connection with the breast, and are described in the chapter dealing with that organ.

(ii) SQUAMOUS—which arise either from surfaces covered by squamous epithelium, or as a result of metaplasia. Thus, prolonged irritation of the gall bladder by stones causes the normal columnar epithelium to revert to a less differentiated type, and cuboidal or squamous-celled carcinoma develops.

Squamous-celled carcinoma is particularly liable to occur as a result of chronic irritation (p. 38). The regional lymph glands are likely to be invaded, but blood-borne metastases are rare. The lymphatic glands occasionally undergo colloid degeneration, to which secondary infection from the primary growth may be superadded, so that if the skin gives way over the softened gland a glairy, semi-purulent fluid is discharged.

Microscopically, squamous-celled carcinomata are either papilliferous or ulcerative. On section solid masses of polyhedral cells are seen, which invade the deeper structures.

"Cell-nests" are usually apparent in slowly growing cases, and are due to deeper cells becoming flattened and undergoing keratinisation. "Prickle" cells are characteristic, and resemble the prickle cells present in the epidermis.

Squamous-celled carcinoma of different tissues are discussed in their appropriate chapters.

(iii) BASAL-CELLED (*syn.* Rodent Ulcer). *Vide* p. 933.

Biochemical Diagnosis.—At frequent intervals claims are made that cancer can be detected by examination of the blood or serum. Thus Bendien has recently asserted that the presence or absence of cancer can be determined by a flocculation test of the serum, combined with physical examination of the blood, but after the first wave of enthusiasm (fanned by the lay press !) this test is now discredited.

SARCOMA

Sarcomata occur in connection with structures of mesoblastic origin. Many tumours formerly labelled "sarcoma" are now very properly excluded from this group. Thus a "myeloid sarcoma" is more accurately described as a "giant-celled" tumour of bone, the "melanotic sarcoma"

becomes a melanoma, and most "sarcomata" of the testicle are in reality a carcinoma or teratoma.

Sarcomata differ from carcinomata, not only in their derivation, but also in their age incidence, as sarcomata are most common during the first and second decades. Moreover, sarcomata often grow with greater rapidity, and dissemination occurs mainly by the blood-stream. Microscopically, the cells of a carcinoma are arranged in masses or columns, whereas sarcoma cells are often separated from each other. In some cases a sarcoma develops in pre-existing benign tumours, such as a fibroma or uterine fibroid. In other cases, some metabolic condition predisposes to their occurrence, as in the case of von Recklinghausen's disease of nerves or Paget's disease of bones. A few instances are on record in which a sarcoma, usually of bone, followed directly upon an injury.

Sarcomata commonly originate in bones or periosteum. If the tumour grows slowly the sarcomatous cells reproduce tissue from which the tumour originated, and thus an osteo-sarcoma or chondro-sarcoma results. Fibro sarcomata are composed of spindle cells of varying lengths. In many cases it is difficult to distinguish with certainty, even microscopically, between a simple fibroma and a fibro-sarcoma of low-grade malignancy. It is probable that some fibromata imperceptibly become sarcomatous, particularly after incomplete attempts at removal, e.g. Paget's recurrent fibroid. A fibrous

FIG. 24.—A fibro-sarcoma of the scalp, originating in the parietal region. The tumour has extended into the temporal fossa, and ulcerated.

An excessive dose of X-rays, applied for ring-worm eleven years previously, resulted in a scar, from which the tumour developed.

epulis and a fibrous polyp of the nose are examples of fibro-sarcomata of low malignancy.

Fibro-sarcomata not uncommonly arise in scar tissue, sometimes many years after the scar was inflicted (fig. 24). Owing to the relative avascularity of scar tissue an associated sarcoma grows slowly, but eventually causes extensive destruction of adjacent structures (fig. 25).

FIG. 25.—Erosion and absorption of the vault of the skull, due to fibro-sarcoma of the scalp. (Same case as fig. 24.)

A lympho-sarcoma arises in lymphatic glands, tonsils, Peyer's patches, or lymph nodules in the intestines. Glands of the neck or mediastinum are most commonly affected. This variety of sarcoma grows rapidly, and gives rise to metastases in adjacent lymphoid tissues. The tumour is composed of small round cells which stain deeply, and which are highly radio-sensitive, but owing to early dissemination the prognosis is practically hopeless.

The terms round-celled, spindle-celled, etc., are applied to tumours which contain no differentiated cells.

The microscopic appearance of a sarcoma varies considerably. As the word implies, most tumours appear as a fleshy mass, but their consistency depends on the relative proportion of fibrous and vascular tissue. An avascular fibro-sarcoma appears as a hard, almost white tumour, whereas a sarcoma of the breast is frequently soft, hæmorrhagic, and often cystic, owing to mucoid degeneration. Hæmorrhage commonly occurs in a sarcoma, owing to the very thin walls of the blood-vessels, which in some places are even absent. The absorption of fibrin ferment from extravasated blood accounts for the irregularities of temperature which are so characteristic of a rapidly growing sarcoma.

Sarcoma of separate organs are considered in their appropriate chapters.

FIG. 26. A fungating melanoma of the choroid. (Auvert's Atlas, R.C.S.)

MELANOMA

Melanotic tumours usually arise in the skin or pigmented layers of the eye. They are either benign or malignant.

BENIGN

These occur as congenital pigmented nævi or moles, or as pigmented warts. These tumours usually remain unaltered, but occasionally malignant changes supervene.

MALIGNANT

A melanoma malignum most commonly is secondary to a benign pigmented tumour. In the case of a mole, the first evidence of malignancy is ulceration and tendency to bleed. The primary growth may remain quite small, and yet give rise to large secondary deposits. Occasionally a

melanoma malignum arises spontaneously, as in the case of the nail bed (fig. 27) or in the uveal tract (fig. 26).

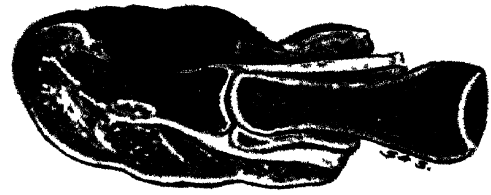

FIG. 27.—Melanoma malignum arising in the bed of the big toe nail. (R.C.S. 1813 1.)

As a rule a melanoma malignum is virtually a death-warrant, as these growths give rise to early and widespread dissemination. Tumours arising in the skin permeate lymphatics, and intermediate deposits commonly occur between the primary growth and regional glands (fig. 28). At a later stage bones and viscera are likely to be involved. Melanomata occurring in the uveal tract frequently give rise to visceral deposits, particularly in the liver, which may be enormous in size (fig. 60). After removal of an eye on account of a melanoma a latent period of many years may elapse, but secondary deposits inevitably appear.

FIG. 28. — Melanomatous deposits in subcutaneous lymphatics of the abdominal wall. (R.C.S. Museum, 2035.1.)

Histologically, melanomata arising in the skin usually show an alveolar arrangement. The pigment granules vary in colour from black to yellow, and are situated both in the cells and in the stroma. Secondary deposits are typically black, but sometimes contain very little pigment or even none at all. In advanced cases melanuria occurs.

The treatment of a melanoma consists of immediate and free removal of the primary growth and regional glands. The prognosis is very poor, as intermediate deposits are likely to

appear in the lymphatic vessels, or dissemination may have already occurred by the blood-stream. Radium is useless.

An unusual variety of melanosis is occasionally seen, in which the pigment from a congenital mole slowly spreads in the surrounding skin, with no immediate evidence of malignancy. After a period of months or even years malignant changes supervene. The pigmented patch should be excised freely so as to forestall malignant changes.

FIG. 29.—An endothelioma arising from the subcutaneous tissues.

ENDOTHELIOMA

The endothelial linings of blood-vessels, lymphatic spaces, and serous membranes occasionally give rise to neoplasms. Endotheliomata, therefore, enjoy a wide range of distribution (fig. 29). Although the original cells are flattened, they become spheroidal or cuboidal when neoplastic changes occur. Endotheliomata are not usually highly malignant, and dissemination occurs in a minority of tumours.

Endotheliomata arise from the pleura and rarely from the pericardium or peritoneum. The "endothelioma" of the dura mater is thought by some to arise from the arachnoid membrane, which is not an endothelial structure. Calcification occasionally occurs in these tumours, in which case it is termed a "psammoma."

FIG. 30. A typical "turban" tumour

Perithelioma are tumours aris-

ing in connection with the endothelial lining of small blood-vessels or lymphatics. Carotid body tumours are probably of this nature (p. 162).

Gaucher's disease of the spleen (p. 245) is considered by some authorities to be an endothelial neoplasm.

Cylindroma (*syn.* "Turban" tumour) is so-called from the arrangement of the stroma in peculiar transparent cylinders. It is considered by some to be a baso-cellular carcinoma, although other authorities classify the tumour as an endothelioma. The tumour gradually forms an extensive turban-like swelling extending over the scalp (fig. 30). Ulceration is uncommon, and the tumour is relatively benign.

Tumours arising in connection with special structures or organs are considered in their appropriate chapters.

CHAPTER IV

ULCERATION AND GANGRENE

ULCERATION

An ulcer is caused by destruction of surface tissue, cell by cell, rather than in macroscopic quantities.

Ulcers are classified as non-specific, specific, and malignant: the two latter groups are discussed in appropriate chapters.

Non-specific ulcers are due to infection of wounds caused by injury or physical irritants. Prolonged pressure and interference with the circulation, as in the case of varicose ulcers, are predisposing causes. Trophic ulcers are associated with derangement of vaso-motor control, and any debilitating condition predisposes to and hinders the healing of an ulcer.

The life-history of an ulcer consists of three phases, those of extension, transition, and repair. During the stage of extension the floor is covered with exudate and sloughs, while the base is indurated. The edge is sharply defined, and discharge is then purulent, and perhaps sanious. The transition stage is occupied in preparation for healing. The floor becomes cleaner and sloughs separate. Induration of the base diminishes, and the discharge becomes more serous. Small reddish areas of granulation tissue appear on the floor, and these link up until the whole surface is covered. The stage of healing consists in the transformation of granulation tissue, which gradually contracts to form a scar. The edge of the ulcer becomes more shelving, and epithelium gradually extends from it to cover the floor: this healing edge consists of three zones—the outer of epithelium, which appears white, the middle one bluish in colour, where

granulation tissue is covered by a few layers of epithelium, and the inner reddish zone of granulation tissue covered by a single layer of epithelial cells. Excessive granulations, commonly known as "proud flesh," need to be discouraged by scraping, or by the application of a caustic, e.g. silver nitrate stick.

Skin grafting is useful in hastening the healing of an extensive ulcer. The method recommended by Thiersch is most commonly used, although the pedicle graft is increasing in popularity. Thiersch's method consists in scraping away the granulations on the floor of the ulcer, and securing hæmostasis by pressure with hot saline pads. Areas of cuticle are removed from healthy skin, usually from the thigh, with a non-bevelled razor, the line of section just reaching the papillæ, which appear as tiny oozing spots on removal of the graft. The grafts are transferred by a spatula to the prepared ulcer, so that they overlap each other, and merely a protective dressing is necessary. The denuded areas are dressed with gauze moistened with 1 per cent. tannic acid.

Pedicle grafts are used to cover large raw surfaces, and scope for ingenuity exists in planning the precise method for individual cases. Thus a flap may be raised from the submaxillary region and turned upwards on to the face, the base of the pedicle being divided when the graft has taken. Allowance is made for shrinkage of the graft in these cases.

GANGRENE

Necrosis is a term indicating death of single cells or microscopic portions of tissue, although clinically the term is used to imply death of visible portions. Gangrene, on the other hand, is death of macroscopic portions of tissue combined with putrefaction.

The features of gangrene are as follows :

(i) Cessation of circulation, i.e. loss of pulsation, and pressure on the skin causes no alteration of colour, indicating absence of capillary circulation.

(ii) Loss of heat.

(iii) Loss of sensation in the affected part.

(iv) Loss of function.

(v) Change of colour, depending on the type of gangrene.

Gangrene is of two types, dry or moist.

Dry gangrene occurs when the tissues are desiccated by gradual decrease of the amount of blood entering them, and typically occurs as a result of arterial degeneration. The affected part becomes dry and wrinkled, discoloured from disintegration of haemoglobin, and greasy to the touch.

Moist gangrene occurs when venous as well as arterial obstruction occurs, or when the artery is suddenly occluded, as by a ligature or embolus. Infection and putrefaction usually follow, and the affected part becomes swollen, discoloured, and the epidermis may be raised in blebs. Crepitus can sometimes be detected on palpation, due to infection by saprophytic gas-forming organisms.

When gangrene occurs, the local changes depend on the size of the affected tissue and the degree of infection present. Small amounts of gangrenous tissue are absorbed; larger amounts, if aseptic, are cast off as a slough. This separation of the slough is accomplished by a layer of granulation tissue which forms between the dead and living tissue. These granulations extend into the dead tissue, until those which have penetrated farthest are unable to derive adequate nourishment owing to fibrosis occurring behind them. This defective nutrition results in ulceration, and thus a line of cleavage forms which separates the gangrenous mass from healthy tissue.

If the gangrenous tissue is infected, separation occurs as a result of inflammatory changes in the adjacent healthy structures. In addition to the toxins produced by infection, irritating chemical substances are formed by disintegration of the dead tissue, and the consequent inflammatory reaction in neighbouring living tissue results in suppuration. A layer of granulation tissue then forms on the surface of the healthy tissue, forming a line of separation. Infection may extend beyond the line of separation along lymphatic vessels or

cellular tissue into healthy parts, and extensive inflammation then results.

The general treatment of gangrene consists in dealing with any predisposing causes, e.g. diabetes, and in relieving pain, ordering nutritious diet and stimulants if necessary. Locally, when gangrene threatens, the part should be kept dry, aseptic, and warm, and in the case of a limb, elevation will encourage venous return. Treatment of different varieties is discussed later.

Varieties of Gangrene

The varieties of gangrene may be classified as follows :

i. *Symptomatic :*

(*a*) Raynaud's disease.

(*b*) Ergot.

(*c*) Senile.

(*c*) Thrombosis and thrombo-angiitis obliterans.

(*e*) Embolism.

(*f*) Diabetes.

ii. *Infective :*

(*a*) Gas gangrene.

(*b*) Phagedena and cancrum oris et noma.

(*c*) Carbuncles and boils.

iii. *Traumatic :*

(*a*) Direct, e.g. crushes, bedsores, the constriction groove of strangulated bowel.

(*b*) Indirect, due to injury of vessels at some distance from the site of gangrene, e.g. pressure on the popliteal artery by the lower end of a fractured femur, or the gangrenous contents of a hernial sac.

iv. *Physical*, e.g. burns, scalds, frost-bite, etc.

I. Symptomatic Gangrene

(*a*) **Raynaud's disease** is due to arterial spasm, and is predisposed to by anæmia or toxæmia.

It must be distinguished from chilblains, and the vascular disturbance sometimes caused by cervical ribs. The condition is discussed on p. 664.

Ergot is a common cause of gangrene among dwellers on the shores of the Mediterranean Sea, who eat rye bread infected with claviceps purpurea. The extremities, particularly the nose and ears, are affected.

Senile gangrene is predisposed to by arterial degeneration, the vessels becoming calcified and narrow. Myocardial weakness causes slowing of the circulation, and slight injury resulting in local thrombosis may determine the onset of gangrene. Constitutional conditions, e.g. albuminuria or glycosuria, lower the vitality of the tissues, and encourage the development of gangrene.

Treatment first consists in the prevention of minor injuries in patients who suffer from painful cramps and tingling in the legs, or other evidence of impaired circulation. Warmth, careful chiropody, and attention to the general health receive due consideration. If gangrene threatens, lumbar ganglionectomy is considered, but is unlikely to improve many cases, as actual degeneration rather than spasm of the arteries is the causative factor (see also p. 663). If gangrene develops amputation is usually necessary, and should be performed at a level where the blood supply is adequate. If there is no pulsation in the tibial arteries, it is necessary to amputate through the lower third of the thigh. Owing to the calcareous state of the vessels, hæmorrhage is controlled by digital pressure rather than by a tourniquet, and surprisingly little bleeding occurs. Flaps should be planned so as to be no longer than necessary and equal in length, as sloughing is otherwise encouraged. If calcification renders ligature of the main artery difficult on account of brittleness, some of the adjacent soft parts are included in the ligature.

Thrombosis is an uncommon cause of gangrene, but occasionally occurs as a complication of specific fevers. Thrombo-angiitis obliterans is a more common cause (p. 664).

Embolic gangrene arises either in connection with cardiac lesions, e.g. endocarditis or mitral stenosis, or follows separation of an atheromatous plaque. Emboli are arrested at the site of bifurcation of an artery, or where sudden narrowing

occurs owing to a large branch leaving the parent vessel. Sudden, severe pain is experienced, both at the site of impaction, and along the distal course of the vessel. Circulatory changes speedily follow, pulsation being lost, and the limb becomes cold and blue. Gangrene commences peripherally, and extends upwards until it reaches a level of adequate circulation, which usually coincides with a joint.

Treatment is, if possible, immediate embolectomy (p. 84).

Diabetic gangrene is due to three factors. These are: mesial calcification of the arteries, trophic changes resulting from peripheral neuritis, and the presence of sugar in the tissues, which lowers their power of resistance to infection. Gangrene occurs more commonly in chronic diabetes, and, as in the case of senile gangrene, is usually preceded by some slight trauma. Gangrene is either moist or dry. Several foci may occur, with accompanying toxæmia or septicæmia.

Treatment consists in combating the diabetes by means of insulin and diet, and as the blood-supply is probably not as seriously curtailed as in senile gangrene, less extensive surgical measures are often successful. Thus expectant treatment is adopted, and if the spread of gangrene is arrested, removal of dead tissues may be sufficient. If amputation is imperative, it can be carried out at a lower level than in the case of senile gangrene, e.g. at the site of election below the knee rather than through the lower third of the thigh. Spinal anæsthesia should be employed in preference to a general anæsthetic.

II. Infective Gangrene

Gas gangrene, although uncommon, is a regular contributory cause of death in the case of accidents. The accident is usually severe, e.g. extensive lacerations or compound fractures, especially if contaminated with soil. Excessive hæmorrhage and the use of a tourniquet predispose to this infection, and as in all cases of gangrene, the leg is more prone to be affected than the arm. The causative organisms fall into two groups—those which break down starch, and those which break down protein B. Welchii (aerogenes

capsulatus or perfringens) is the most important member of the saccharolytic group; it is a gram-positive anaerobe with a definite capsule. The proteolytic group include B. sporogenes, which splits protein into ammonia and sulphuretted hydrogen.

Clinical features of gas gangrene usually develop within forty-eight hours of infection. The early signs include rapid increase in the pulse-rate, a rise, or, in severe cases, a fall of temperature, and vomiting. It has been suggested that the toxins produced by the infection exert a selective and depressing action on the suprarenals, causing marked lowering of the blood-pressure and hence vomiting. On examination of the wound, stitches are seen to be under tension, and, from the pouting edges, thin bloodstained fluid exudes. The limb is tense and swollen, and palpation often reveals crepitus. In less acute cases yellowish staining of the skin is sometimes observed, due to haemolysis of red corpuscles.

Treatment is essentially prophylactic. In all lacerated and contaminated wounds excessive zeal in stitching is strongly to be deprecated. A wound tightly stitched may look neat and presentable on the operating table, but only too often the stitches are of necessity removed, or cut out later, when deep infection under tension has been encouraged to spread. Such wounds should be carefully purified, and dead or damaged tissue removed. Partial suturing is sufficient, and secondary suture can be undertaken at a later date. Anti-gas gangrene serum should be given, as well as the customary anti-tetanic serum. If infection becomes established, free incisions, local excision of groups of muscles, or amputation may be necessary, according to the extent and virulence of injection. Gas and foul fluid are found in the cellular spaces; contractility of the muscle is soon lost, and its colour changes successively from brick red to green and then black. If septicaemia occurs, gas is produced in many organs, notably the liver, which, at necropsy, drips with frothy blood, and is well-named a "foaming liver."

Cancrum oris et noma is the term applied to a virulent type of infective gangrene which sometimes occurs in children who are debilitated and possibly recovering from some exanthemata (p. 123).

Carbuncles and boils are considered in connection with diseases of the skin.

III. Traumatic Gangrene

This variety of gangrene follows either local injury or interference with the blood-vessels supplying the affected part, and thus is either direct or indirect.

(i) **Direct traumatic gangrene** is due to local injury of the affected tissue, and may arise as a result of crushes, or pressure as in the case of splints, plasters, or bedsores.

Gangrene following a direct and severe injury, e.g. a street accident in which a heavy vehicle passes over a limb, is of the moist variety, and if the affected part is divitalised removal without delay is indicated. As the tissues are presumably healthy, amputation is performed as close to the affected part as will leave the most useful limb.

Pressure sores are usually preventable, but if an elderly patient is confined to bed for a long period, or particularly in cases of paraplegia, sores may develop in spite of careful nursing.

Prophylactic measures consist in cleanliness, the use of spirit, eau de Cologne followed by dusting powders of which Dermatol (bismuth subgallate) is one of the most useful. Pressure on prominences is relieved by air rings or strips of elastoplast. A water bed is sometimes useful. Occasionally, in spite of all precautions and treatment, bedsores occur and cause extensive and deep necrosis, such as involvement of the sacrum.

(ii) **Indirect traumatic gangrene** is due to interference with blood-vessels, and some of the more important causes of this condition are as follows :

(*a*) Obstruction to artery and vein, as occurs in the loop of bowel contained in a strangulated hernia, or following pressure by a fractured bone on the main vessels of a limb.

(*b*) Thrombosis of a large artery, following injury or embolus.

(*c*) Ligature of the main artery of a limb, e.g. after division by injury. The likelihood of gangrene then depends upon the efficiency of the collateral circulation, the elasticity of the arteries, and whether the arm or leg is affected. It is now generally agreed that the accompanying vein should also be ligatured, as thereby the risk of gangrene is diminished, although this procedure is likely to be followed by prolonged œdema in the lower limb.

An analysis of cases during the Great War showed that gangrene occurred in 28 per cent. of cases in which the artery alone was ligatured, and in 19 per cent of cases if the accompanying vein was also tied (Sir George Makins).

Treatment in these cases is directed to the cause, thus embolectomy, or closed or open reduction of a fracture, will sometimes prevent the onset of gangrene. A divided artery may be temporarily united by a Tuffier's silver tube so that collateral circulation is allowed a few days in which to develop. In other cases, where gangrene is slow in its development, delay is sometimes advantageous in that a line of demarcation will indicate the level of vitality, but if moist gangrene rapidly spreads then amputation must be performed in order to safeguard healthy tissue.

IV. Physical and Chemical Causes

Frost-bite is rarely seen in this country; it naturally affects the exposed surfaces and extremities.

The affected part becomes waxy in appearance.

Treatment consists in gradually thawing the frozen portion, either by massage, or slowly raising the temperature of the surroundings. Oil of turpentine is highly recommended as a local application.

Chemicals sometimes cause gangrene, the most dangerous being carbolic acid, as anæsthesia occurs before gangrene supervenes. Carbolic compresses should never be used, and fingers have been lost by the application of compresses even as dilute as 1 : 80. Gangrene is due to local arterial spasm.

Burns and scalds commonly produce gangrene, burns being due to dry heat and scalds to moist heat. Dupuytren described six degrees of burns. The first consists of superficial congestion, whereas in the second degree the cuticle is raised by a blister. The third degree is the most painful, as the cuticle is destroyed, and the sensitive nerve terminals are exposed. In the fourth degree the whole skin is destroyed, the fifth degree includes muscles, and in the sixth degree the whole limb is charred.

Constitutional changes include shock, which depends upon the patient's susceptibility, the extent, and the part affected. Children readily succumb to burns, particularly if the face or trunk are affected. After six hours toxæmia or "secondary shock" becomes manifest, and reaches its maximum during the second day. The patient becomes restless and collapsed, with a rising pulse-rate and falling blood-pressure. The loss of serum from the damaged surface is a contributory factor in maintaining this toxæmia. Later, inflammatory reactions occur, and diarrhœa from toxic absorption may be fatal. Toxins are alleged to be excreted in the bile, and the irritating bile thus secreted is presumed to impinge on the second part of the duodenum and cause ulceration.

Treatment consists in combating shock and acidosis, and applying antiseptic treatment to the affected area. The dressing should be painless, and require the minimum of renewal. Tannic acid (1 : 40 in water, to which some surgeons add perchloride of mercury) meets these requirements, and in addition prevents further loss of serum. Also by fixing damaged tissue it hinders autolysis and further absorption of toxins. Under anæsthesia the skin is cleansed with ether, tannic acid sprayed over the wound, and the patient returned to bed with no dressings. The denuded area is protected by cradles, to which electric lamps are fixed, and at half-hourly intervals freshly prepared tannic acid is sprayed over the raw surface. After about twelve applications a brownish incrustation covers the whole wound. Tannic acid must not be sprayed on both sides of the fingers, as contraction of the coagulum may be sufficient to cause

gangrene of the finger tips. In the case of facial burns the eyes must be carefully protected. If owing to extensive burns the whole surface cannot be sprayed, then the remainder should be covered with gauze soaked in tannic acid

FIG. 31.—Contracture of the fingers following burns.

solution. Shock and acidosis are best combated by continuous intravenous infusion of saline and sodium bicarbonate. In one or two weeks the crust becomes loose and epithelium grows in from surrounding skin. Skin grafting is often necessary if the burn is deeper than the third degree.

Contractures (fig. 31) should be prevented by suitable splinting.

CHAPTER V

BLOOD AND BLOOD-VESSELS

Blood

The blood normally contains the following constituents :

Red Corpuscles.—The number varies between 5 to 6 million per c.mm. In conjunction with the number of red corpuscles present the proportion of hæmoglobin is usually estimated. The " Colour Index " is then obtained by dividing the percentage of hæmoglobin by the number of corpuscles expressed as a percentage of the normal, and should therefore be approximately 1.

Within a few hours of a severe hæmorrhage, the volume of the blood is restored by absorption of fluid from the tissues. The red cells are replaced more rapidly than the hæmoglobin, consequently the " Colour Index " is below 1. Hæmoglobin is replaced at an average rate of 1 per cent. each day.

Leucocytes.—Normally, 7,000 to 10,000 leucocytes are present per c.mm., and they comprise five different types :

(*a*) The Polymorphonuclear Leucocyte (63 to 72 per cent.) containing a lobed nucleus. It is formed in bone marrow, and is larger than a red corpuscle.

(*b*) The Lymphocyte (20 to 25 per cent.), with a single deeply staining nucleus smaller than a red corpuscle, and derived from lymphoid tissue.

(*c*) The large Mononuclear cell (2 per cent.), probably endothelial in origin.

(*d*) The Eosinophile Leucocyte (1 to 3 per cent.), derived from bone marrow, which has a bilobed nucleus and coarse granules.

(*e*) The Basophile, or mast cell ($\frac{1}{2}$ per cent.), constant in number and unknown in function.

Blood Platelets.—These minute bodies are formed in the

bone marrow, and their normal content is 250,000 per c.mm. If diminished in number, clotting is defective.

The Schilling Differential Blood Count consists in differentiating polymorphonuclear leucocytes according to their relative maturity. In 1891 Ehrlich described the myelocyte and the polymorphonuclear leucocyte, but Schilling recognises two intermediate cells, which he terms the "juvenile" and the "band" types. The appearance of the various cells is as follows:

Myelocyte, which is the largest of the cells, is spherical in outline and contains fine granules. The nucleus is spherical.

Juvenile, which contains a bean- or U-shaped nucleus, and the granules are coarser than those of the myelocyte.

Band, the nucleus of which resembles the letters T, S, or Y.

Segment, which is a mature polymorphonuclear cell, containing a lobed-shaped nucleus.

The differential cell count is described as shifting to the left or right according to the preponderance of immature or mature white cells. A shift to the left indicates active regeneration of white cells by the bone marrow, such as occurs in acute infections. A shift to the right occurs when infection is being overcome and conditions are returning to normal. With further experience it is possible that the Schilling differential count will prove of greater use than that of Ehrlich, and that it will be of considerable importance in diagnosis and prognosis.

Chemical Constituents.—Calcium, sugar, cholesterol, and urea are all present in definite quantities.

In pathological conditions the following investigations may be of surgical importance:

(1) **Cytological.**—(*a*) *Red Cells.*—The number of cells is increased in polycythæmia and diminished in many conditions, e.g. hæmorrhage or infection. The envelope of the cell normally withstands dilatation to ·47 per cent. saline. Excessive fragility is associated with acholuric jaundice.

(*b*) *White Cells.*—Increase of polymorphonuclear cells to an extent of 20,000 per c.mm. or more is strongly indicative of suppuration, and may be of diagnostic value. The examination should be made fasting, to avoid physiological leucocytosis associated with digestion. Leucopenia may be associated with typhoid fever and tuberculosis.

A relative lymphocytosis may occur in tuberculosis, and an absolute and sometimes enormous increase occurs in lymphatic leukæmia.

A relative eosinophilia may occur in parasitic infections,

e.g. trichiniasis, hydatid disease, certain skin lesions, and anaphylactic conditions.

(c) *Blood platelets* are diminished in hæmophilia, scurvy, and some types of purpura. In other types of purpura, the number may be increased, in which case the risk of thrombosis is present.

(2) **Colour Index.**—This is important in testing types of anæmia, e.g. it is increased in anæmia of the pernicious type and diminished in secondary anæmia.

(3) **Serological.**—This includes Widal's test, the W.R., and other complement fixation tests, and blood grouping in connection with blood transfusion.

(4) **Bacteriological.**—In septicæmic conditions, the organism may be detected in a film, or isolated from the blood by culture. In connection with the examination of films, the diagnosis of malaria and filariasis may be made.

(5) **Chemical.**—The percentage of urea is an indication of the renal efficiency, and the blood-sugar curve may distinguish the true diabetic from the renal glycosuria.

(6) **Coagulation Time.**—This is markedly prolonged in hæmophilia, and may be an important preliminary consideration when an operation is contemplated in the presence of jaundice.

Blood Transfusion.—The commonest indications for this procedure are hæmorrhage, and deficient coagulability of blood, e.g. hæmophilia, or as a preliminary to operation in cases of jaundice. Before the advent of liver treatment transfusion was repeatedly employed to combat pernicious anæmia. Occasionally transfusion is indicated in severe cases of secondary (aplastic) anæmia. The value of transfusion in cases of septicæmia is doubtful, although immunotransfusion may be of value. This procedure consists in inoculating a healthy donor with the appropriate vaccine. When reaction occurs a few hours later 500 or more c.c. of his blood is withdrawn and injected into the infected patient.

Human blood falls into one of four main groups, although other groups undoubtedly exist. Incompatibility may arise in one of the following ways :

(I) The red cells of the donor are agglutinated by the recipient's plasma.

(II) This agglutination is followed by haemolysis. This haemolysis is always preceded by agglutination, and advantage is taken of this fact in testing for compatibility.

Members of group I are universal recipients, and those of group IV are universal donors, but can only receive blood from their own group.

Technique of Grouping. Stock sera from group II and group III are necessary, and are stored in capillary tubes. They should not be more than six months old. The patient's finger is pricked and a drop of blood is mixed with six drops of sodium citrate solution (3·8 per cent.). Drops of this citrated blood are placed on each of three slides, on two of which is a drop of group II and group III sera respectively, while the third slide is a control against spontaneous agglutination. Within a few minutes any agglutination can usually be recognised, when it is obvious, with a magnifying glass or even with the naked eye, that the serum under the cover glass is clear, but contains reddish specks of agglutinated corpuscles. In order to exclude lesser degrees of agglutination the slides should be examined microscopically for a period of half an hour. The following results are then deduced: if both sera cause agglutination the patient belongs to group I; if group III agglutinates he belongs to group II; if group II agglutinates he belongs to group III, while no agglutination indicates that the patient is a member of group IV.

Cross-Matching. In all cases, whenever possible, a cross-matching test should be employed, as members of the same group sometimes show varying degrees of incompatibility. A few drops of the donor's serum is tested with the recipient's corpuscles, in the same manner as for grouping, and the donor's cells are tested against the recipient's serum. Even after the extra precaution of cross-matching incompatibility occasionally occurs, in which case the recipient experiences severe pain in the back, and a sensation of weight on the chest. The pulse becomes rapid and feeble, and pallor is evident. Should these features appear the transfusion is immediately stopped. Fatal results are almost eliminated if accurate cross-matching is practised.

Methods of Transfusion. (1) *Direct Transfusion.* A special syringe fitted with two nozzles is necessary. Each nozzle is connected by rubber tubing to needles in the donor's and recipient's veins respectively. Some type of two-way tap is necessary, or a special syringe can be obtained in which a half-turn of the piston puts the barrel into communication with the nozzle which leads to the vein of the recipient. Prior to use liquid paraffin is pumped through the apparatus in order to prevent coagulation. In order to transfuse directly it is necessary that the donor and recipient lie side by side, which is likely to impose a considerable mental strain on the donor, who is preferably blindfolded. Both donor and recipient should possess veins easy of puncture, as it is desirable to insert the needles at the same moment in order to diminish the risk of clotting.

(2) *Citrate Method.*—The use of anticoagulants has greatly simplified transfusion, and sodium citrate has proved to be efficacious in

preventing clotting, and innocuous to the patient. A solution of sodium citrate of 3·8 per cent. prevents clotting of six times the volume of blood, so that 80–100 c.c. is necessary for the transfusion of one pint of blood. The donor lies comfortably on a table, and a rubber tube is tied round the arm above the elbow, or a sphygmomanometer is applied. A large-bore needle is inserted into a suitable vein, and the desired quantity of blood is allowed to flow into a 1,000-c.c. flask, which contains the necessary amount of citrate solution. The flask is partially immersed in warm water, and an assistant agitates it in order to encourage thorough mixing. The blood can be transfused by means of a tube and funnel connected to a needle in the recipient's vein, but a more rapid method, and one applicable to small veins, is to expel the blood from the flask by means of a rubber blowing-ball (fig. 32)

Fig. 32.—Blood transfusion apparatus.

Untoward after-effects, e.g rigors, fever, etc., are alleged to be due to the citrate, but are probably caused by contamination of the distilled water, bacteriological examination of which will often supply unpleasant surprises.

Hæmorrhage

Hæmorrhage is arterial, venous, or capillary; the first variety is either primary, reactionary, or secondary in nature. If hæmorrhage is severe, the blood-pressure falls, although it is partially maintained by absorption of body fluids, and vasomotor constriction of the arterioles. A further result is loss of the oxygen-carrying hæmoglobin, so that tissues are deprived of oxygen. In severe cases the patient complains of thirst and impending suffocation (air hunger), and later of tinnitus and temporary blindness. The pulse is rapid and compressible, and increasingly dicrotic as the arteries empty.

Natural arrest of hæmorrhage is encouraged by increased coagulability of the blood, diminution in the force of the heart's action, and changes in the divided vessel. Thus, in the case of a completely divided artery, the elastic coat retracts within the sheath, and partially blocks the lumen, but if an artery is incompletely divided, or buttonholed, this retraction cannot occur. Clotting occurs in the empty arterial sheath, and extends within the lumen as

far as the nearest branch. Permanent occlusion follows organisation of this intravascular clot.

Arterial Hæmorrhage

Primary.—In cases of emergency, the external hæmorrhage can be temporarily arrested by direct digital pressure, and if from a limb, a tourniquet can then be applied. Arrangements are then made for transport to a hospital, where the wound is explored, and every effort made to ligature both ends of the divided artery.

Two exceptions to this procedure are:

(1) Punctured wounds of the hands and feet. If the bleeding artery cannot be found, or if the wound is contaminated so that extensive exploration would spread infection, then the brachial or superficial femoral arteries should be ligatured.

(2) Bleeding from deep branches of the external carotid artery e.g. a penetrating wound of the spheno-maxillary fossa. Exposure is impracticable, and the external carotid artery is ligatured between its superior thyroid and lingual branches.

Reactionary hæmorrhage occurs within twenty-four hours, and may be due to slipping of a ligature or separation of a clot in the mouth of a divided vessel, owing to rising blood-pressure concomitant upon recovery from shock. It probably arises from small vessels (as bleeding from large vessels has probably been adequately arrested), and usually responds to elevation and pressure. If persistent, the vessel must be sought and ligatured, otherwise the wound is cauterised or packed.

Secondary hæmorrhage is due to infection and sloughing of part of the wall of an artery. It is predisposed to by pressure of a drainage tube or fragment of bone, or excessive separation of the sheath of an artery during ligature. Internal secondary hæmorrhage occurs in connection with a chronic gastric or typhoid ulcer and phthisis.

In the case of an infected wound or amputation stump, "warning" hæmorrhages usually occur in the form of bright red stains on the dressing. Repeated moderate losses or a sudden severe hæmorrhage may prove fatal.

When a definite warning hæmorrhage occurs, the wound should be freely opened, sloughs removed, and an attempt made to recognise and ligature the bleeding vessel. Failing

this, the wound is packed with gauze soaked in flavine or moistened with turpentine. Should hæmorrhage recur, then the main vessel of the limb is ligatured (ligature in continuity), or amputation performed.

Venous bleeding is troublesome in certain situations, e.g. during dissection of glands of the neck, as the welling blood offers little guide to the precise source of hæmorrhage. It is therefore a wise precaution to divide no tissue under traction, which empties veins and renders them unrecognisable. If large veins are injured, a lateral ligature can sometimes be applied without occluding the whole lumen. The entrance of air into veins is a rare event, but can occur in connection with large veins, e.g. axillary, or where veins are attached to deep fascia, and consequently cannot collapse when divided, e.g. the external jugular. The aspiration of air may be audible, and is followed by collapse of the patient, as the air is churned up with blood in the right side of the heart, and hence impedes the circulation. Treatment consists in the immediate arrest of further entry by digital pressure, or flooding the wound with saline, and combating the collapse by posture and stimulants.

Arteries

Injury.—An artery is sometimes ruptured subcutaneously, e.g. as a complication of a dislocated shoulder, or divided in a penetrating wound.

In the former case a rapidly increasing swelling occurs, which may pulsate. The distal signs depend upon the degree of circulatory disturbance, and also pressure on nerves is liable to cause paræsthesia or pain.

If swelling increases, rupture may occur, or at a later date local infection or distal gangrene is liable to supervene. If coagulation occludes the rent, and collateral circulation is efficient, the extravasated blood may organise, and the limb retain its vitality.

In the case of injury to a large artery, operation should be performed, and the vessel exposed. A temporary ligature or a Crile's clamp controls the circulation, and if possible the

rent is sutured with fine vaselined silk. End-to-end suture has been successfully accomplished, relaxation being obtained by posture. If the laceration is extensive, a Tuffier's tube can be introduced into the two ends as a temporary measure, in order to allow collateral circulation to become established. If these measures are impracticable, the vessel is completely divided, and the ends are ligatured.

Aneurism

An aneurism is a sac filled with blood, which communicates with the interior of an artery. A *true* aneurism is due to dilatation of an artery, whereas a *false* aneurism is lined by condensed cellular tissue, and communicates with the artery through an aperture in its wall.

1. **True Aneurisms** are either fusiform, saccular, or dissecting.

A *fusiform* aneurism is one in which the lumen is more or less equally expanded, and is usually due to syphilitic mesarteritis.

A *saccular* aneurism is due to stretching of a patch of arterial wall, and is more commonly associated with injury than disease.

Dissecting aneurisms occur in the aorta, and are due to separation of an atheromatous plaque, which allows blood to insinuate itself between the inner and outer parts of the muscular coat. It is only discovered post-mortem, unless leakage causes symptoms suggestive of an abdominal catastrophe, when it may be discovered at laparotomy.

Clinical Features.—(*a*) *Intrinsic.*—A swelling exhibiting expansile pulsation is present in the course of an artery. The pulsation diminishes if proximal pressure is applied, and the sac itself is compressible, filling again in two or three beats if proximal pressure is released. A thrill may be palpable, and auscultation sometimes reveals a bruit.

(*b*) *Extrinsic.*—Neighbouring or distal structures are affected. Thus pressure on veins or nerves causes distal œdema or altered sensation, and the pulse is delayed or smaller in volume. Bones, joints, or tubes, e.g. trachea or

œsophagus, are sometimes affected, but structures which yield, e.g. intervertebral discs, often withstand prolonged pressure.

Differential Diagnosis.—(i) *Swelling under an Artery.*—An artery may be pushed forwards, e.g. the subclavian, by a cervical rib, and thus rendered prominent. Careful palpation distinguishes this condition.

(ii) *Swelling over an Artery.*—In this case transmitted pulsation is liable to be mistaken for that caused by expansion. However, proximal pressure does not reduce the size of the tumour, and posture may diminish pulsation, e.g. a pancreatic cyst examined in the genupectoral position falls away from the aorta, and consequently pulsation is less definite.

(iii) *Pulsating Tumours, e.g. Secondary Carcinoma of Bone.*—The swelling is irregular in consistency, and indefinite in outline.

(iv) *Other Causes of Deep-seated Pain.*—Cases of alleged intractable neuralgia, sciatica, etc., are occasionally due to aneurism.

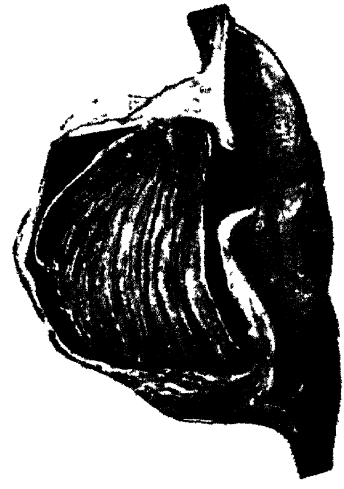

FIG. 33.—Aneurism of the aorta. Extensive clotting in the sac has almost resulted in spontaneous healing (R C S. Museum 5428 1.)

Natural Terminations.—1. *Spontaneous Cure.*—This may occur in cases of saccular aneurism, due to gradual clotting in the sac (fig. 33), or plugging of the mouth of the sac by an embolus.

2. *Infection.*—Sometimes follows operation, or arises from organisms in the blood-stream. Signs of inflammation supervene, and if untreated, suppuration and rupture follow.

3. *Rupture.*—This may occur slowly as a leakage, or suddenly, in which case death follows in a few moments.

TREATMENT.—*General.*—The patient's habits must be regulated, so as to avoid all physical and mental strain. A limited nitrogenous diet and minimum of fluid is allowed. Potassium iodide is given, as many aneurisms are associated with syphilis, and the drug frequently relieves pain associated with an aneurism. Calcium lactate is administered in the hope of increasing coagulability.

Local.—(*a*) Mata's operation. In selected cases of saccular aneurism, reconstruction has been attempted. The sac is opened, and the margins of the aperture approximated by stitches. Obliteration of the artery usually follows, but if the vessel remains patent, there is a risk that the weak fibrous suture line will subsequently yield, leading to recurrence.

In cases of fusiform aneurism, obliteration can be accomplished by opening the sac, ligating the main vessel above and below from within, and inserting purse-string sutures to approximate the walls.

(*b*) Excision of the sac. This is the most satisfactory method when access can be obtained. The artery is ligatured above and below, and the intervening sac dissected away. If adhesions cause difficulty, the sac should be opened in order to define its limits more clearly. Even if part of the accompanying vein is removed, gangrene is unlikely, as both venous as well as arterial collateral circulations are probably efficiently established.

(*c*) Encouragement of clotting. Deposition of fibrin within the sac and subsequent organisation will obviously result in cure of the aneurism. Intermittent proximal pressure was formerly much used, either digital or by a bag of shot, but this method is, naturally, uncertain.

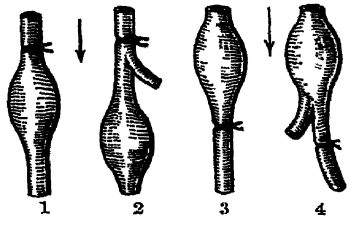

FIG. 34.—Operations on aneurisms. 1, Anel. 2, Hunter. 3, Brasdor. 4, Wardrop.

If practicable, proximal ligation is the common method now pursued if excision is unduly difficult. Anel's operation (fig. 34) consists in tying the artery immediately on

the cardiac side of the aneurism, whereas Hunter placed his ligature so that one branch intervened between it and the aneurism ; e.g. if the superficial femoral artery is tied in Hunter's canal, the anastomotica magna artery intervenes between the ligature and a popliteal aneurism. Hunter's operation necessitates the development of a second group of collateral vessels, i.e. one group to circumvent the ligature and a second to carry blood past the aneurism. This method therefore jeopardises the nutrition of the limb, and should not be used if gangrene threatens, or if marked arterial degeneration is present. On the other hand, the flow of blood through the aneurism is slowed more gradually than by Anel's method, and therefore the resultant clot should be firmer.

Distal ligature is practised for aneurisms anatomically situated so that proximal ligation is impossible, e.g. the vessels at the root of the neck. Brasdor's operation consists in ligaturing the artery close to the sac. In Wardrop's operation the ligature is placed so that one or more branches arise from the artery between the aneurism and the ligature (fig. 34).

After ligation the pulsation of the aneurism usually disappears. Temporary return in two or three days indicates establishment of collateral circulation. If the pulsation persists or appears at a later date, further operative interference will probably be necessary.

When the above methods are impracticable, the introduction of foreign bodies into the sac may be considered. Thus in cases of abdominal aneurism wire may be introduced through a special canula, and cœliac aneurisms have been cured by this method.

(*d*) Amputation may be required if infection or hæmorrhage occurs, or if gangrene supervenes. This procedure is also advisable if the function of the limb is seriously impaired by erosion of bones or joints, and amputation through the shoulder has been undertaken in the hope of curing an aneurism of the subclavian artery.

2. **False Aneurisms**

These are traumatic in origin, and the extravasated blood is enclosed in a false sac of condensed cellular tissue. In the case of large vessels, unless infection threatens, or the aneurism rapidly increases in size, palliative measures should be adopted temporarily, so that collateral circulation may have an opportunity of developing. Subsequently, the sac is opened, and the injured artery tied above and below the site of trauma.

Arterio-venous Aneurism.—This condition is usually due to a penetrating wound injuring an artery and vein lying in close contact, e.g. the common carotid artery and internal jugular vein. A communication between the internal carotid artery and the cavernous sinus sometimes follows a fractured base of the skull. Two conditions may result:

(*a*) *Aneurismal Varix.*—This consists of a communication between an artery and vein, the latter becoming dilated and varicose as a result of the abnormal intravenous pressure. On palpation a thrill is usually detected, and auscultation reveals a buzzing bruit. This condition often remains stationary.

(*b*) *Varicose aneurism*, which differs from the above in that a sac exists between the two vessels. This sac is merely composed of condensed cellular tissue and organised clot, so that it tends to enlarge and become diffuse. The physical signs resemble those of an aneurismal varix, with the addition that the intervening sac may be palpable. In both conditions some degree of tachycardia is usually present, owing to the mixing of venous with arterial blood.

As this condition is progressive, surgical treatment is indicated. The vessels are separated, and, if possible, repaired by suturing, the intervening sac being excised. More frequently quadruple ligature is necessary.

In the case of arterio-venous aneurism of the internal carotid artery and cavernous sinus, ligature of the internal carotid artery may diminish the pulsating exophthalmos and relieve the continuous buzzing, provided that these

features are improved by compression of the common carotid artery against Chassaignac's tubercle.

Embolism

An embolus is a foreign body which circulates in the blood-stream, becoming finally lodged in a vessel and causing obstruction. Their effects vary according to their size, type, efficiency of the collateral circulation, and the nature of the organ in which they are arrested, highly specialised structures being readily affected by circulatory changes. Emboli are simple, infective, malignant, or parasitic.

Simple emboli are due to blood-clot, vegetations from cardiac valves, air bubbles, or globules of fat.

Fat Embolism occasionally follows severe injury to bone marrow or adipose tissue. It is especially liable to occur after fracture of atrophic bones, as these bones contain more than the normal amount of fat. Symptoms are manifest a few hours after injury, and two more or less distinct types, cerebral and pulmonary, are recognised. In the cerebral type the patient becomes drowsy and then unconscious, the pupils are small and pyrexia ensues. The pulmonary type is ushered in with cyanosis, which increases, and signs of right heart failure.

In suspected cases the sputum should be examined for fat droplets, and later fat may be excreted in the urine. Petechial hæmorrhages sometimes occur. When the warning fat is found in the sputum 2 per cent. sodium carbonate should be given intravenously, so as to form a soluble soap. This is followed, if necessary, by further infusions and venesection.

Infective emboli consist of masses of bacteria, or infected clot, and may cause pyæmia. Malignant emboli are more commonly sarcomatous than carcinomatous, and give rise to secondary deposits, unless sufficient blood is extravasated to isolate the malignant cells from normal tissue, a phenomenon which sometimes occurs in connection with chorion-epithelioma. Parasitic emboli are due to the ova of Tænia echinococcus and Filaria sanguinis hominis.

In some situations the results of embolism are characteristic, e.g. :

Brain.—The middle cerebral artery is most commonly affected, resulting in hemiplegia, temporary or permanent.

Retina.—Occlusion of the central artery causes a momentary flash of light, followed by total and permanent blindness.

SPLEEN.—This organ is commonly affected, in which case local pain and enlargement follow.

KIDNEYS.—Resulting in pain in the loin and hæmaturia.

MESENTERIC VESSELS.—Causing engorgement and gangrene of the corresponding loop of intestine.

LUNG.—Pulmonary embolism is an ever-recurring catastrophe, which may fatally interrupt convalescence after operation. It is predisposed to by desiccation, such as follows excessive hæmorrhage or post-operative vomiting, and infection of the operative field. It is particularly common after pelvic operations, when large venous spaces are readily infected. The usual time of occurrence is 10 to 14 days after the operation. A single large embolus may become lodged in a branch of the pulmonary artery, causing the patient to sit up suddenly and gasp. A request for the bed-pan is frequently made, and death follows in a few seconds. In less severe cases sudden pain occurs, followed by a pleural rub, hæmoptysis, and temporary rise of temperature. Recurrent cases usually recover.

If time permits, oxygen and morphia are administered. Attempts to remove the embolus by operation have occasionally been rewarded with success. Increased knowledge and improved technique inspire hope in suitable cases, where facilities are at hand.

LIMBS.—An embolus is arrested at the bifurcation of a main vessel, causing severe pain referred down the limb, followed by circulatory changes, and probably gangrene. The brachial, femoral, and popliteal arteries are most commonly affected. Embolectomy should be attempted.

Embolectomy.—Local or spinal anæsthesia is to be preferred on account of the cardio-vascular condition of the patient. The artery is exposed and occluded above the site of the embolus either by a rubber clamp, or by a tape saturated in 2 per cent. sodium citrate. A half twist of the tape occludes the flow of blood, and traction on the tape steadies the vessel. A longitudinal incision is made just above the obstruction, care being taken not to injure the intima on the opposite wall. The embolus is removed by "milking" the artery upwards, and the incision is closed with fine needles threaded with vaselined silk. During the operation the surgeon's hands and instruments are frequently rinsed in citrate solution, and afterwards the limb is kept warm and at rest for a week. Operations in the first

four hours result in 62 per cent. of cures, the second four hours 50 per cent., but the third four hours only 24 per cent. Embolectomy gives better results in the arm than in the leg.

Veins

Thrombosis of veins is predisposed to by :

(1) Change in the vessel wall, causing desquamation of endothelium, e.g. injury or inflammation.

(2) Diminished rate of blood flow, as in debilitating conditions, such as typhoid fever.

(3) Increased coagulability of the blood, such as occurs in infective conditions, or after hæmorrhage.

The *results* of thrombosis are as follows :

(1) *Locally.*—The clot may organise into fibrous tissue, which may later become canalised. Suppuration may occur, forming a localised abscess, or giving rise to pyæmia. Calcification occasionally follows, resulting in the formation of a phlebolith.

(2) *Distally.*—Œdema may occur, the degree depending on the size of the vessel affected. The collateral circulation is soon established, and may give rise to widespread varicosity of the superficial veins.

(3) *Proximally.*—Thrombosis may extend upwards to larger veins. A portion of clot is liable to become detached, particularly if infected. The resultant embolus may cause obstruction to a pulmonary vein, with attendant urgent symptoms, or if the portal area is affected, multiple foci of infection will riddle the liver.

Varicose Veins

A vein is stated to be varicose when it is dilated, lengthened, and tortuous. The condition commonly occurs in connection with the veins of the leg, the spermatic veins, and the hæmorrhoidal veins. The two latter conditions are dealt with elsewhere. Varicose veins of the leg are due to a congenital deficiency of the valves or muscular coat, the condition often occurring early in life, and involving the same group of veins in members of the same family. Varicosity is predisposed to by any condition which hampers venous return, e.g. garters, tumours, and pregnancy.

Sudden or unaccustomed physical exercise is alleged to stretch or even rupture venous valves.

The condition may be widespread in both legs, or a single ampulla may be present. If this is situated close to the saphenous opening, it may be readily distinguished from a femoral hernia on account of the obvious thrill when the patient coughs.

Clinically, the condition gives rise to a sensation of weight and fatigue. Eczema, ulceration (fig. 35), phlebitis, and perio-

FIG. 35.—Varicose ulcer, with pigmentation of the surrounding skin.

stitis may supervene. If infective phlebitis occurs, softened clot may become detached, and give rise to embolism.

Treatment.—(i) *Palliative* treatment consists of removing any possible cause. The veins are supported by crêpe or elastic bandages; rubber bandages interfere with the evaporation of perspiration, and predispose to eczema. If ulceration occurs, Elastoplast bandages should be applied.

(ii) *Injection.*—The eminently successful results obtained by the injection treatment of varicose veins have established it as the method of choice in the large majority of cases, and the double advantage of an ambulatory and non-surgical treatment, moreover, commends itself to patients. Suitable injections cause damage to the endothelial lining, leading to the production of a firm, adherent thrombus. Swelling of the wall of the vein with proliferation of its cell elements occurs, and is quickly followed by organisation. The artificial thrombus formed is remarkable for its

tenacity, so that the possibility of fragments becoming detached to form emboli is extremely remote, and also in varicose veins the direction of the flow of blood is reversed when the patient is standing.

General Technique of Injection.—The usual position for the patient is standing. If veins are large or the patient is nervous, injections may be given in the sitting or recumbent position. As a rule the initial injection should be made in the most distal part of the affected vein, each succeeding injection being made at a higher level. The surgeon is thus able to distinguish easily the veins which are still patent from those that are thrombosed. The whole of the saphenous tract may be treated to within 4 inches of the saphenous opening.

An ordinary 5-c.c. Record syringe with a No. 16 needle may be used, or special syringes are now obtainable. Having sterilised the skin over the selected vein with spirit, the needle is inserted obliquely from below upwards in the line of the vein. The plunger is withdrawn slightly, and if blood enters the syringe, the needle is in the vein. Should air bubbles appear, this indicates that the needle has gone through the vein and lies in the perivenous tissue. The position of the needle must be altered until it is positively in the lumen of the vein. During injection the point of the needle should be held perfectly steady in the vein. The injection should be made slowly at the rate of about 1 c.c. in 15 seconds. After injection the needle is withdrawn quickly, and firm digital pressure applied with a sterile swab for two minutes. The patient can then carry on with his normal occupation. Further injections are given at weekly intervals, as necessary. The following solutions are commonly used for injection:

1. Sodium salicylate, 20 to 40 per cent.
2. Quinine hydrochloride 4 grammes, urethrane 2 grammes, water 30 c.c.
3. Sodium morrhuate 5 to 10 per cent., which is less irritating to perivenous tissues than the two former preparations, but relapses are prone to occur if the veins are tolerant.

Sequelæ of Injections.—(*a*) *Immediate Local Effects.*—The vein may collapse or dilate, it may become hard at once, or there may be no change. After the prick of the needle the process should be painless. Severe pain at the time of injection usually indicates that fluid is entering the perivenous tissue. Thrombosis generally occurs, and a satisfactory result ensues.

(*b*) *Immediate General Effects.*—There may in some cases be collapse or fainting. When quinine is employed there may be temporary buzzing in the ears, headache, etc.

(*c*) *Late Local Effects.*—After about twelve hours the vein becomes somewhat swollen and tender, and may ache for a few days. A certain amount of bruising sometimes occurs along the course of the vein. After a few days the vein begins to decrease in size. Complete fibrosis takes from 3 to 12 months to occur. It is slower over bony surfaces and quicker in the veins of the thigh.

Complications.—(*a*) *Injection Ulcer.*—This is the most common accident, and is due to the escape of the solution into the perivenous

tissues. It is always the result of carelessness, and should never occur. If the operator is in doubt as to the position of the needle when injecting, the plunger should always be withdrawn to see if blood enters the syringe. The injection ulcer is serious, being very painful, and taking from three to six months to cure. Sloughs occasionally develop at a point some inches from the site of injection, and are due to a thin atrophic state of the wall of the vein, which is unable to react to the artificial phlebitis.

(*b*) *Embolism.*—That the danger of embolism is remote is shown by the relatively exceedingly few cases reported. In one series of 53,000 cases, only 7 deaths were recorded. This compares favourably with the operative mortality, which is 0·4 per cent. The chief cause of death in the cases recorded was the presence of phlebitis when the injections were undertaken.

Contra-indications to Injection Treatment. (*a*) *Acute Infective Thrombo-phlebitis.*—At least three months should be allowed to pass after this has cleared up before injecting.

(*b*) *Deep thrombosis*, due to any cause.

(*c*) *Pregnancy.*—It is not advisable to inject, especially in the later months. Veins will disappear, or their condition improve after delivery.

(iii) *Operation.*—Trendelenburg's operation should be undertaken if a definite thrill is palpable in the veins on coughing. One inch of the internal saphenous vein is removed immediately below the saphenous opening. An oblique incision should be used, as the vein may be duplicated.

Thin-walled pouches or localised bunches of veins are cured more expeditiously by removal than by injection.

HÆMANGIOMA

Angiomata are tumours composed of blood-vessels, and are congenital in origin. They sometimes remain insignificant for a prolonged period, but are apt to enlarge in size at any time.

Capillary nævi are composed of dilated capillaries, and are most common on the face and scalp. Occasionally they are submucous, in which case bleeding often occurs. The term "spider" nævus is applied when portions of the tumour radiate into surrounding tissues. Applications of carbonic snow is efficacious in destroying small capillary nævi, but larger ones sometimes require radium or excision.

Cavernous angiomata consist of masses of dilated veins into which arteries open more or less directly. They

occasionally occur in viscera, but are more commonly submucous or subcutaneous. Frequently capillary nævi are found in the overlying skin (fig. 36). Submucous nævi are prone to hæmorrhage, which is sometimes alarming (fig. 78). A characteristic feature of a cavernous angioma is its compressibility. If possible the tumour should be excised with the help of an electric cautery. Otherwise diathermy, or electrolysis, causes thrombosis of vessels and consequent shrinkage.

FIG. 36 —Cavernous hæmangioma of the tongue and gum, with capillary nævus of the skin of the cheek (From a drawing in the R.C S. Museum.)

Plexiform angiomata consist mainly of arteries, and consequently pulsate. The usual form is referred to as a cirsoid aneurism (p. 561). Very rarely similar tumours are found in bones, in which case a pulsating tumour appears when the compact bone is eroded.

CHAPTER VI

LYMPHATICS AND LYMPHATIC GLANDS

Acute lymphangitis is due to infection of lymphatics from a wound in the area drained by the involved vessels. The infection is usually limited by the glands immediately proximal to the site of infection; these glands become inflamed, but occasionally infection "jumps" a group of glands and affects those at a higher level. As a result of an infected wound of the leg, the external iliac glands occasionally become inflamed, and form a mass in the corresponding iliac fossa. Errors in diagnosis are likely to arise, especially as the wound is often healed by the time the mass appears.

Acute lymphangitis is characterised by the appearance of subcutaneous red streaks, which correspond to the inflamed lymphatics. If large trunks are affected they are sometimes palpable as tender cords. Toxæmia may be severe, and depends upon the virulence of the causative organism. Local suppuration may occur in the course of the inflamed lymphatics. Permanent occlusion sometimes follows lymphangitis, leading to persistent lymphatic œdema.

TREATMENT consists in dealing with the wound, unless, as is frequently the case, it is insignificant or already healed. If a limb is affected, it must be kept at rest, slightly elevated, and fomented or immersed in a hot saline or antiseptic bath. General measures are taken to combat infection.

Chronic lymphangitis may follow acute lymphangitis, or is more commonly due to repeated subacute attacks of infection. The wiry lymphatics passing along the dorsal aspect of the penis are characteristic of a primary chancre, and may be associated with œdema of the prepuce. Tuberculous lymphangitis occasionally occurs, notably in the peri-

ureteric lymphatics ; the resulting fibrosis and contraction leads to the characteristic " golf-hole " ureteric orifice.

Lymphatic Obstruction

1. **Congenital,** giving rise to lymphangiectasis.

2. **Trauma,** as a result of removal of glands, e.g. lymphatic œdema of the arm, following dissection of the axillary glands, or due to division of lymphatics, as by an incision along the lower and outer margin of the orbit, which divides lymphatics passing to the preauricular glands, and leads to œdema of the lower eyelid.

3. **Inflammation,** due to fibrosis of lymphatics, which may follow an acute lymphangitis, such as erysipelas, or result from persistent chronic infection.

4. **Neoplasm,** as typified by the " peau d'orange," due to permeation of lymphatics by carcinoma, and resultant obstruction.

5. **Parasites**—the Filaria sanguinis hominis, following the bite of an infected mosquito. The legs and scrotum are chiefly affected and enormous thickening of the subcutaneous tissue may result.

As a result of lymphatic obstruction, a solid œdema occurs, the subcutaneous tissue becomes brawny, and shows little pitting on pressure. At a later stage the skin becomes coarse and rough, and lymphatic vesicles appear, which tend to rupture, leading to ulceration and recurrent infection.

Treatment.—Lymphatic obstruction is usually an unsatisfactory condition as regards surgical treatment. Elevation and elastic pressure may relieve early cases. The introduction into the subcutaneous tissues of sterilised silk (lymphangioplasty) sometimes gives temporary relief in the arm, but is useless in the leg on account of gravity. Excision of long strips of deep fascia (Kondoléon's operation) has been performed with occasional success, the object being to remove the fascial barrier between superficial and deep lymphatics, so that lymph is returned by the latter channel. Amputation is occasionally necessary if the patient is anchored to the bed by the weight of the limb, or if ulceration and infection supervene. Filariasis has been benefited by removal of the parent filariæ when their situation has

been recognised. Usually the condition progresses, and removal of the scrotum or affected limb is eventually necessary.

Dilatation of Lymphatic Vessels

Congenital types include the following varieties:

(*a*) Capillary Lymphangioma.—When this condition occurs in the skin it is known as lymphatic nævus, and consists of brownish papules or wart-like excrescences. On examination with a lens small vesicles may be seen.

(*b*) Cavernous Lymphangioma is often associated with the preceding variety (fig. 37), and consists of masses of lymphatic cysts, particularly in the neck or axilla, the condition being termed a cystic hygroma. An ill-defined spongy mass results, the skin over which may be semi-translucent, a condition which was formerly described as "hydrocele of the breast" when occurring in that organ. These lymphatic cysts and spaces ramify freely, so that complete removal is impossible. Recurrent attacks of inflammation are common, and result in subsequent fibrosis and diminution in size.



Fig. 37.—Cavernous lymphangioma of the tongue, the surface of which is covered with lymphatic nævi.

(*c*) Lymphangiectasis usually occurs as a congenital condition, and gives rise to enlargement of different parts, e.g. tongue (macroglossia) or lip (macrocheilia). The condition occasionally affects the subcutaneous lymphatics of a limb (Milroy's disease), and amputation may then be required.

Acquired lymphatic dilatation is due to obstruction of main lymphatics. Thus, pressure on the thoracic duct may cause engorgement of the alimentary lymphatics, and even chylous ascites, and cases of chylous hydrocele have been described, presumably due to obstruction of lymph drainage.

Lymphatic Glands

Acute lymphadenitis follows infection of the appropriate lymphatics, although, as already mentioned, a group of lymphatic glands may escape obvious infection, whereas a more proximal group may evince a marked reaction. The affected glands become enlarged, firm, and tender. Resolution, fibrosis, or suppuration follows.

Treatment consists in dealing with any cause, and applying fomentations to the affected glands. If suppuration occurs, pus is evacuated. Tonics and aperients are given as necessary.

Chronic lymphadenitis is either simple or specific :

1. *Simple*, or non-specific adenitis, is due to intermittent or prolonged infection of low virulence, e.g. tonsils or pediculi, or sometimes follows incomplete resolution of acute adenitis. The glands become enlarged, firm, and slightly tender, and occasionally quietly suppurate. This condition probably predisposes to tuberculous adenitis, the simple infection preparing the soil for the seed.

Treatment consists in removal of any local focus of infection and attention to the general health.

2. *Specific adenitis.*

(*a*) Tuberculous infection of glands is common in children and adolescents, particularly among those who live in unhygienic surroundings, or who inherit a predisposition to tuberculosis. Some chronic or intermittent focus of infection is commonly present, e.g. tonsils, teeth, or scalp, and chronic simple adenitis gradually becomes tuberculous. The cervical glands are the commonest to be affected, at least as far as clinical evidence is concerned, although the bronchial or mesenteric glands are commonly invaded. The axillary or inguinal glands sometimes suffer, particularly

if there is some tuberculous focus in the area of lymphatic drainage, e.g. lupus verruca.

Tubercle bacilli most commonly reach the gland by lymphatics, tubercles first forming in the cortex, but blood-borne infection sometimes occurs, in which case the medulla of the gland is the first part to be affected.

Clinically, the affected glands enlarge, and become characteristically matted together owing to periadenitis. Caseation may follow, to be succeeded by suppuration. Pus is no respecter of fascia, and often burrows through the deep fascia, so that the pus is superficial and the causative gland deep to this structure, forming a "collar-stud" abscess (fig. 92). If the condition progresses, the skin becomes blue and thin, eventually giving way, a tuberculous sinus resulting. Occasionally, and especially with the assistance of appropriate treatment, caseous material may be absorbed and replaced by fibrous tissue or calcification, this latter change particularly affecting the mesenteric glands.

TREATMENT consists in dealing with any possible source of infection, combined with care of the general health. If improvement does not occur within one month, then accessible glands should be removed, otherwise suppuration is likely to supervene. Thus, in the case of cervical glands, collar incisions are made, and glands, often surprisingly large, are removed. This is a tedious operation, needing patience and a good light. Normal anatomy is distorted, and no tissue should be divided under traction, as veins are thus rendered unrecognisable and liable to injury. The welling blood obscures the actual site of hæmorrhage, and groping with artery forceps is likely to damage important structures. The hypoglossal and spinal accessory nerves are commonly embedded in a mass of glands, and are therefore particularly prone to injury.

If abscesses are present they are aspirated, and possibly iodoform emulsion is injected. If suppuration persists, then operation should be undertaken, as otherwise the skin will give way, and sinuses and secondary infection follow. On opening the superficial abscess pus is evacuated, and

granulation tissue gently curetted ; the track through the deep fascia is then enlarged so that the deeper glands are explored and removed. The operation field is smeared with iodoform paste, and a glove drain inserted for twelve hours on account of the oozing.

If sinuses are already present, general treatment is instituted, and if the results are disappointing the sinuses are enlarged, and the underlying glands removed as efficiently as possible with a sharp spoon. The wound is packed, and should be daily painted with malachite green and corrosive sublimate, 1 per cent. of each, in S.V.R., an application which gives particularly gratifying results with most tuberculous sinuses.

The ideal treatment, which in our opinion should be followed more frequently, is to remove tuberculous glands if a short course of general treatment results in no improvement. Early removal diminishes the risk of sinuses and resulting scars, prolonged convalescence, and dissemination from an active focus.

When the diagnosis of tuberculous adenitis is definitely made, vaccines, judiciously used, often cause improvement. At all stages of the condition, as for most forms of tuberculous disease, ideal surroundings are found in the Swiss sanatoria.

(*b*) Syphilitic adenitis can occur in any stage of the acquired infection. "Shotty" glands associated with a genital chancre are characteristic. During the secondary stage a generalised enlargement of glands occurs, especially those above the internal epicondyles and along the posterior border of the sterno-mastoid (glandulæ concatenatæ). In the tertiary stage a gumma may occur in a lymphatic gland, but is rare, or more commonly the glands enlarge as a result of secondary infection of a broken-down gumma.

Chronic Enlargement of Lymphatic Glands

Chronic enlargement is due to the following causes :

(i) Inflammation.

(ii) Blood diseases.

(iii) Lymphadenoma.

(iv) New-growth.

(i) **Inflammatory** causes have already been discussed.

(ii) **Blood Diseases.**—(*a*) *Lymphatic leukæmia* is of little surgical interest except from the point of view of differential diagnosis. Cytological examination is diagnostic—the leucocytes are enormously increased, and may number 150,000 per c.mm., of which 90 to 99 per cent. are lymphocytes. Splenic enlargement is more characteristic of chronic lymphatic leukæmia than of Hodgkin's disease. Splenectomy has been performed for this condition, but the results are disappointing.

(*b*) *Still's disease* is an infective condition occurring in children. The predominant clinical features consist of an irregular temperature, osteoarthritis commencing in the smaller joints, enlargement of the spleen and lymphatic glands, and a lymphocytosis. Treatment involves a thorough search for any source of infection, and the prevention of deformity of joints.

(iii) **Lymphadenoma** (*syn.* Hodgkin's disease) is of doubtful pathology, but is probably infective in origin. It is commoner in males, and usually affects young adults, but cases vary widely as regards age incidence and virulence. Occasionally, and especially in children, the course of the disease is merely a matter of weeks, the associated irregular and often high temperature leading to errors of diagnosis. More commonly the patient first notices a painless swelling in the supraclavicular region, associated with malaise and an irregular temperature. Pressure effects, due to deep glands, especially mediastinal, may follow, or occasionally cause the first symptoms. On examination the glands are discrete, painless, and rubbery in consistency. The spleen is enlarged, but rarely enough to be palpable. The enlargement may be diffuse, or whitish nodules may project from the surface, the organ then bearing some resemblance to toffee studded with almonds, known as "hard-bake." In the late stage of the disease most organs in the body become affected, and periodic bouts

of temperature occur at intervals of two or three weeks (Pel-Ebstein).

Blood examination reveals a secondary anæmia, with occasionally slight lymphocytosis, but serves to distinguish other conditions, e.g. lymphatic leukæmia. Excision of an appropriate gland clinches the diagnosis. Macroscopically the distinction between cortex and medulla is lost, and a variable amount of fibrous tissue is noticed. The microscope reveals an increase of endothelial cells and the presence of giant cells which are oval in shape and contain several overlapping nuclei in the centre of the cell. Occasionally a prominent feature is a marked increase in eosinophil cells.

Treatment consists in the administration of arsenic to combat anæmia. Intravenous injections of such preparations as salvarsan have a much more potent effect than oral administration. X-rays cause a temporary reduction in the size of the glands. Excision should only be considered when pressure symptoms are caused by glands which have become tolerant to X-rays. The disease is characterised by remissions and exacerbations, but inevitably runs a fatal course.

(iv) **New-growth.**—(*a*) *Primary lymphosarcoma* may commence in any adenoid tissue, e.g. glands, tonsils, or Peyer's patches. When affecting the glands, those most commonly involved are the cervical group. Rapid, steadily progressive enlargement occurs, which later becomes tender, and infiltrates surrounding structures. Dissemination occurs to other lymphoid tissue in the neighbourhood.

Excision is sometimes practicable in early cases. Radium causes retrogression, but unfortunately dissemination is only too likely to have occurred already.

(*b*) *Secondary Growths.*—Carcinoma and melanoma typically disseminate to lymphatic glands. Lymphosarcoma, e.g. from lymphatic glands or the tonsil, is likely to spread along lymphatics to other glands. Sarcomata of the testis and thyroid are alleged to disseminate to glands; probably earlier observers confused different types of testicular neoplasms. Sarcoma of the thyroid gland must be regarded as a curiosity.

CHAPTER VII

FACE AND JAWS, INCLUDING THE PALATE

EMBRYOLOGY OF THE FACE

For the proper understanding of congenital deformities in this region we must refer for a moment to its development. A depression appears in front of the head about the sixth week of fœtal life. Around this depression, called the stomodæum or primitive mouth, a number of buds appear. These grow into processes and coalesce to form the face. This process of budding and cohesion is a rapid one, for it is commenced and completed in the brief space of three weeks. Thus every congenital deformity of the face has existed from

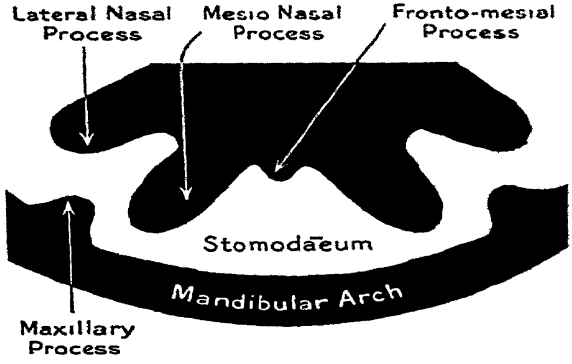

Fig. 38. Diagram of the five processes which develop around the stomodæum.

the ninth week of fœtal life. The processes are shown in fig. 38. They are :

1. The fronto-mesial process.
2. The mesio-nasal process, or processus globularis.
3. The lateral nasal process.

} All derived from the trabeculæ cranii (notochord).

4. The mandibular process derived from the first branchial arch.
5. The maxillary process derived from 4.

Failure of union of the mesio-nasal process with the maxillary process and/or the maxillary process with its fellow accounts for most of the congenital facial abnormalities, which are :

1. Hare-lip.
2. Cleft-palate.
3. Facial cleft.
4. Macrostoma.

Too much union results in microstoma. Facial cleft, micro- and macrostoma are so rare that they need no further consideration in this work.

Hare-lip and Cleft-palate

Clinical Features.—Lateral hare-lip (fig. 39) is the most frequent of all the congenital facial deformities, and it occurs once in 2,500 births. It is to some extent familial. Hare-lip is nearly always lateral, and in about 15 per cent. it exists

Fig. 39.—Lateral hare-lip.

Fig. 40.—Bilateral hare-lip associated with a premaxilla.

on both sides (fig. 40) Cases of true median hare-lip are exceedingly rare, and are due to an absence of the fronto-mesial process.

There are three degrees of cleft-palate—the tripartite, the bipartite, and the intermaxillary cleft (fig. 41 A, B, C).

Hare-lip and cleft-palate occur more often in males (3–2) An infant with a large opening between the mouth and the nose cannot suck properly, for sufficient negative pressure cannot be established. If, as is often the case, there is a hare-lip in addition, sucking is impossible. At first sight this would seem a serious matter, but it is overcome by a simple expedient. If the puncture in the rubber teat of a feeding bottle is enlarged, or an ether dropper is substituted, milk can be made to drip evenly into the babe's open mouth, and in a few days he learns to receive his nourishment at regular intervals in this way.

We have seen that the ætiology of hare-lip and cleft-palate is largely a matter of understanding elementary embryology ;

it is obvious that the diagnosis will present no difficulty: the immediate preservation of the child's life is a matter of

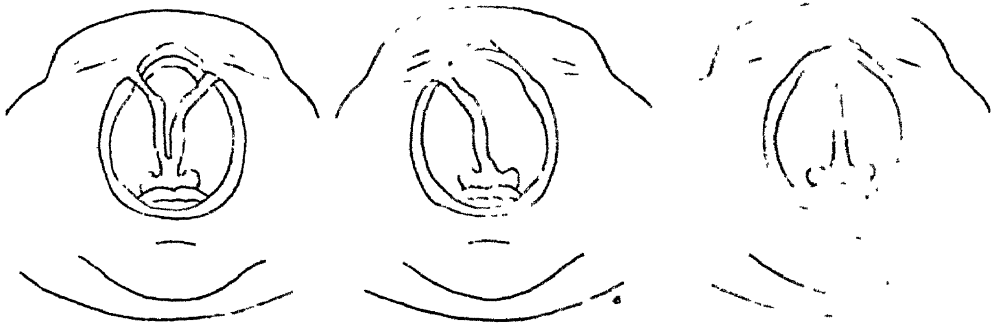

A. Tripartite cleft-palate. B. Bipartite cleft-palate. C. Intermaxillary cleft.
FIG. 41.

attention to methods of feeding it, and so our whole efforts must be directed to a discussion of treatment.

Treatment.—The first consideration is to remedy the deformity. In the tripartite, and to a lesser extent the bipartite, varieties of cleft-palate (fig. 41 A, B, C) the premaxilla, which is derived from the processus globularis, and which is morphologically the prognathian or snout of lower animals, juts out, causing a hideous deformity. Such a deformity is a constant source of mortification to a sensitive mother. The second important factor is to close an opening between the nose and mouth before the child talks, or he will never learn to speak distinctly. There still exist sharp differences of surgical opinion both as to the best method of repairing a cleft-palate and the age at which the operation should be performed. In the case of hare-lip opinion is more stereotyped.

PRINCIPLES IN THE OPERATIVE TREATMENT OF CLEFT-PALATE

For many years there have been three schools of practice, and lately a fourth has entered the field. As a "memoria technica" it is sufficiently accurate to state that—

Lane's operation is performed in the **3rd** week.
Brophy's operation is performed in the **3rd** month.
Langenbeck's operation is performed in the **3rd** year.

For the actual technique of these operations the reader must be referred to works on operative surgery. General principles only will be considered here.

Lane's Operation.—Flaps of muco-periosteum from the roof of the mouth are used to cover the median defect in the palate. Sir Arbuthnot Lane was wont to describe this operation as a life-saving operation, for it enabled the child to suck, and justified the very early operation. In the opinion of many this argument is not clear, for the child may be fed artificially. To-day this operation is seldom performed, and we do not know of any of Lane's pupils who carry on his method. Many excellent results were obtained by the originator, but the principal criticism was that the soft palate was inclined to become fibrous and immobile.

Brophy's Operation.—Brophy pierces the maxillæ above the alveolus in two places, one behind the other, and inserts two silver wires. After somewhat freeing the bones and freshening the edges of the cleft the maxillæ are forced together. The wires are then tightened and twisted over a lead plate. Brophy's pupils carry on his work, and the operation has a number of enthusiastic adherents, especially in America. In Britain it is unpopular. Shock, and the possibility of necrosis of the jaw, are stated to be its great disadvantages.

Langenbeck's Operation has received the approbation of the majority of surgeons throughout the world. It is still by far the operation most frequently performed. The principle is shown in fig. 42. By making lateral cuts the muco-periosteum is raised from the hard palate, carrying within it the posterior palatine artery which nourishes both the flap and the soft palate. The soft palate is freed thoroughly from its attachment to the hard palate, and if necessary the hamular processes are broken to further this end. The edges of the cleft are then freshened, and if the process of freeing has been done properly, they may be sutured together without undue tension.

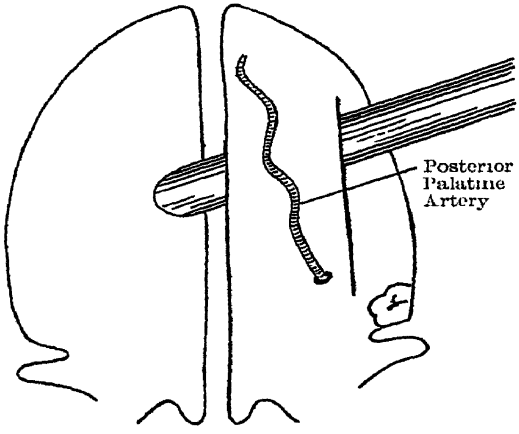

FIG. 42.—Langenbeck's operation.

The Gillies-Fry Operation has had a certain following in recent years. The principle is to close the hard palate with a removable dental plate in earliest infancy. This is followed by an operation for uniting and elongating the soft palate before speech commences.

In all operations for cleft-palate certain precautions must be taken The child should not be operated upon when there are any coughs or colds in the ward. It is of great advantage for the child to get used to its nurse, who teaches it to be spoon-fed before the operation. Anæsthesia is induced with chloroform, and maintained by a Junker's inhaler. During the operation Rose's position with the head fully extended is adopted in order to prevent blood accumulating in the throat. The mouth is kept open with a special gag. After-treatment is all-important. The infant must be spoon-fed, and after each feed the mouth is gently syringed with a weak antiseptic solution. Arm splints are applied to prevent the child interfering with the stitches.

THE LIPS

Hare-lip

Repair is usually undertaken early. About the second month is the popular time. The two main operative measures are Rose's and Edmund Owen's. Rose's operation consists of freshening and uniting the edges of the cleft. In Owen's one side of the cleft is used to make the vermilion border of the newly constructed lip.

Double Hare-lip Associated with the Premaxilla. The premaxilla (fig. 40) must not on any account be removed, for the subsequent deformity is hideous. When the premaxilla juts out considerably a V-shaped piece can be removed from the front of the nasal septum, to which the premaxilla is attached. This allows the protuberant process to be pressed back sufficiently for the lip to be reconstituted.

In all cases of complete hare-lip it is important to observe the nostrils, and if, as is commonly the case, the nares of the affected side is flattened, this should be corrected by a plastic operation at the same time as the lip is repaired.

A well-performed hare-lip operation should render the patient's lips in after-life indistinguishable from normal, even on close inspection.

CONGENITAL FISTULÆ OF THE LOWER LIP

Congenital fistulæ of the lower lip is a condition unexplained by embryology. It occurs in certain families. There are two blind pits, one on either side of the middle line of the lower lip.

MACROCHEILIA

Chronic enlargement of the lip, usually the lower, may be due to inflammatory causes, but true macrocheilia is due to a lymphangioma, akin to lymphangiomatous macroglossia (p. 132). Its treatment is similar to that condition.

FIG. 43.—Syphilitic ulceration at the corners of the mouth. The Wassermann reaction was strongly positive, and the condition healed with anti-syphilitic treatment.

CRACKED LIPS

Chapping of the lips is very common, and a definite crack in the middle of the lower lip is a frequent complaint in cold weather. The crack is deep and bleeds readily. It is liable to be associated with an infection which produces a degree of swelling of the lip.

Treatment consists of strapping together the two halves of the lip for several weeks. In obstinate cases excision of the crack followed by suture should be considered. Cracks at the *corner* of the mouth may be due to a simple infection, but they are also a recognised manifestation of tertiary or congenital syphilis (fig. 43). Radiating scars at the corner of the mouth should arouse at once a suspicion of previous syphilitic ulceration.

FIG. 44.—Chancre of the lip.

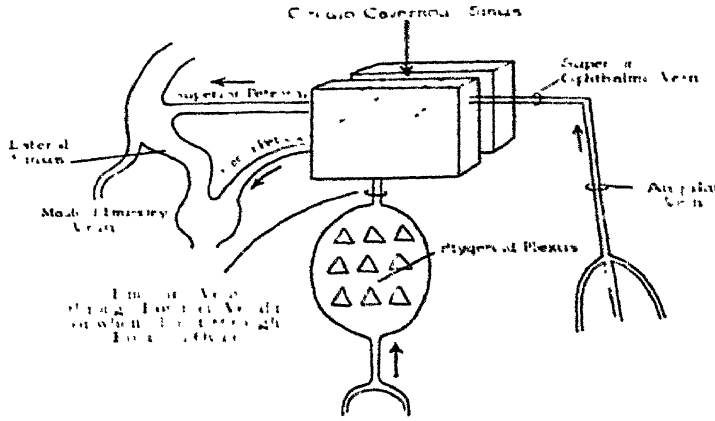

FIG. 45.—The cavernous sinus and its connections (diagrammatic)

CHANCRE OF THE LIP

A Hunterian chancre may appear on the lip, and unlike a similar lesion on the genitals, the neighbouring lymphatic glands become *greatly* enlarged (fig. 44).

CARBUNCLE OF THE LIP

Carbuncle of the face has a sinister reputation, and the upper lip is the most frequent site of this dreaded lesion. The public should be warned not to prick, squeeze, or otherwise tamper with a pimple in this area, for such a practice favours this dangerous condition. It is particularly dangerous, because infection can, and often does, spread along the angular vein to the ophthalmic plexus, and thence to the cavernous sinus (fig. 45). Thrombophlebitis of the cavernous sinus is nearly always fatal.

FIG. 46.—Carbuncle of the upper lip. The angular vein has just been ligatured.

Once a carbuncle of the lip has developed we consider it unwise to incise it, but rather trust in hot applications of gauze soaked in a saturated solution of magnesium sulphate until the slough separates. When the infection is threatening to spread, the eyelids of the more affected side tend to become suffused (fig. 46). It is at this stage that ligature of the angular vein under local anæsthesia may be undertaken, and the path of the cavernous sinus thereby blocked. In necessary cases both angular veins can be ligatured.

New-growths of the Lip

The existence of lymphangioma in this situation has been referred to under "Macrocheilia." Cavernous hæmangioma is another rare, innocent neoplasm in this region.

Cancer of the lip is usually seen in men of advanced years who have followed an outdoor occupation, and it has earned the name of "countryman's lip." Now that the yokel has abandoned the short clay pipe the condition is less frequent than formerly. The carcinoma, which usually takes the form of a shallow ulcer with the typical everted edge, is nearly always found on the lower lip. In its typical form it is a comparatively slow-growing and particularly favourable carcinomatous lesion to treat. Rutherford Morison was the first to point out that a carcinoma occurring at the angle of the mouth and involving *both* lips, however slightly, is far more malignant than the foregoing variety.

Treatment with radium is very satisfactory when combined with subsequent excision of the submaxillary and submental glands.

THE TEETH

The occurrence of supernumerary teeth is fairly common. Occasionally clusters of them are present.

Impaction of a Tooth

A tooth is prevented from normal eruption by the presence of other fully erupted teeth (fig. 47). Much the

commonest tooth to be affected in this way is the third lower molar. Dental impaction usually culminates in an acute, painful attack, in which trismus is a leading symptom. Indeed, this is the most usual cause of trismus.



FIG. 47.—Radiograph showing impacted tooth (Pitts).

Unless the impacted tooth is removed infection is liable to occur. In order to accomplish extraction it may be necessary to sacrifice one of the teeth immediately adjacent. In cases of extreme difficulty the bony alveolus must be chiselled away before the impacted tooth can be removed.

DENTAL CARIES

Necrosis of a tooth begins, as a rule, in the enamel, and extends through the dentine to the pulp. As it reaches the nerve endings within the pulp the familiar pain of toothache is produced.

Untreated, infection is liable to pass into the tooth socket, when an acute or chronic abscess results.

ALVEOLAR ABSCESS

Alveolar abscess is rather more common in the lower jaw, and is usually the result of an infection carried to the tooth socket by the process described above. Throbbing pain, swelling of the cheek, redness and œdema of the gum in the neighbourhood of the tooth which is the seat of the trouble, are the leading symptoms. The general reaction to the infective process may be considerable, and a tender enlargement of the cervical glands is usual. The pus may break through the gum or burrow under the periosteum. In the upper jaw it may enter the antrum. In either jaw, if it is not properly drained, some degree of necrosis of the alveolus is to be expected. Osteomyelitis of the jaw occasionally results.

Treatment.—Hot fomentations and poultices of all kinds should be avoided, for they tend to favour the pointing

externally of an alveolar abscess which is the very thing to be prevented. Hot antiseptic mouth-washes are ordered, and Dover's powder will relieve pain and induce sleep. When a local swelling can be palpated the abscess is opened into the mouth either by removing the offending tooth, or by incising the mucous membrane and the underlying periosteum, or both.

Root Abscesses

While alveolar abscesses are usually acute, root abscesses are nearly always chronic. They arise by penetration of infection from the pulp through a root. Only too often there are no external signs of a root abscess, which is only revealed by a dental radiograph (fig. 48). The causative bacteria are for the most part non-suppurative streptococci, and the absorption of their toxic products is often the cause of ill-health. Examples of brilliant cures of certain peripheral joint troubles by drainage of these pus cavities are now fully established.

Fig. 48.—Dental radiograph showing root abscesses of the lower incisor teeth.

Odontomes

An odontome is a tumour composed of dental tissue in varying proportions and different degrees of development arising from the teeth germs or from teeth still in the process of growth. There are seven varieties:

1. **Epithelial odontome** arises from the enamel organ, and occurs, as a rule, in the mandible. It has a firm capsule enclosing a number of cysts separated by fibrous septa (fig. 49), and may grow to an enormous size.

Fig. 49.—Epithelial odontome. (R.C.S. 1243.1.)

2. **Follicular odontome** arises in connection with a non-erupted permanent tooth, and consequently tends to expand the jaw. The tumour consists of a tooth, often well developed except for a truncated root, lying obliquely in a cavity filled with viscid fluid, viz. :——

3. **Fibrous odontome** is identical with the above, except that the unerupted tooth is surrounded by fibrous tissue instead of fluid, viz. :——

4. **Cementome** occurs usually in horses, and only rarely in man. Around the unerupted tooth there is cement, viz. :—

5. **Compound Follicular Odontome.**—The capsule surrounding the tooth ossifies sporadically, and contains cement, dentine, and enamel in varying proportions. Sometimes these dental elements are so well formed and arranged as to be dignified by the name of denticules, or tiny teeth, viz. :

6. **Composite Odontome.**—The three dental elements—dentine, enamel, and cement—are mixed in a conglomerate fashion within the capsule, which contains no recognisable tooth, viz :

7. **Radicular odontome** occurs in connection with the root of an *erupted* tooth, and causes difficulty in extraction . . . viz. :——

It is probable that certain odontomata can become malignant, and they are referred to in connection with malignant upper jaw (p. 113). Before leaving this subject, which is really not difficult, it is necessary to clarify our minds as to the meanings of two confusing terms. A *dentigerous* cyst is but another name for a follicular odontome, while a *dental* cyst occurs in connection with the root of a carious erupted tooth. The latter give rise to a cyst which expands the jaw and is filled with a glairy fluid, which sometimes contains cholesterol.

Treatment of Odontoma consists of removing the tumour—

excision of a portion of the jaw is not indicated. In the follicular variety it is usually sufficient to remove one bony wall, scrape out the contents, lightly pack the cavity, and mould the expanded jaw with the fingers. It is advisable to have a radiograph before one during the operation (fig. 50).

FIG. 50.—Dental radiograph showing both a composite odontome and an uncrupted tooth.

THE GUMS

HYPERTROPHY OF THE GUMS

Hypertrophy of the gums is occasionally met with in children and young adults. The patients are usually mentally defective. The gum almost buries the teeth, and large polypoid masses form.

Treatment consists of removing the hypertrophied gum and teeth and chiselling away the affected alveolus.

GINGIVITIS

Inflammation of the gums is usually associated with general stomatitis. The gums are swollen, spongy, and bleed readily. Fœtor ovis is often extreme. The teeth become loose and sometimes fall out. These symptoms are in evidence in scurvy and in chronic mercurial poisoning. In chronic lead and also iodoform poisoning there is a characteristic narrow line of black dots on the gums near the dental margin.

Treatment consists of removing the cause, and of dental hygiene. The administration of fresh lime juice is very beneficial in the case of scurvy.

PYORRHŒA ALVEOLARIS

Pyorrhœa alveolaris is a very chronic form of gingivitis. The fundamental cause of the condition is an excessive deposit of tartar. Unless this is removed regularly it tends to push the gum away from the teeth. Consequently, the gum recedes more and more, until the periodontal membrane is broken through. Once this has occurred particles of food can accumulate between the gum and the tooth, and suppuration ensues. The gums bleed when touched, and in

advanced cases beads of pus can be expressed by pressure. Once the condition is fully established treatment is difficult, if not impossible, without removing the teeth. In dirty mouths clearing the jaws of teeth is not to be undertaken lightly, for myriads of virulent bacteria are released both into the mouth and possibly into the circulation, also bronchopneumonia is liable to follow. The teeth should be removed a few at a time, and if a major surgical operation—for instance, a laparotomy for gastric ulcer—is contemplated, this should, if possible, be postponed until the gums have healed.

Tumours of the Alveolus

It is customary to aggregate these under the general heading of "Epulis," an ancient term which has no pathological significance, merely signifying that such swellings are "situated on the gum." There are four varieties of epulides:

1. **Granulomatous Epulis.**—A mass of granulomatous tissue forms around a carious tooth.

Treatment consists of extraction of the tooth and scraping away the granulation.

2. **Fibro-sarcomatous Epulis.**—The majority of epulides belong to this group. They vary greatly in malignancy. At one end of the scale the fibromatous element predominates, and the tumour is practically benign. At the other end the tumour is almost a pure sarcoma. The more sarcomatous element present the softer does the tumour feel and the more readily does it bleed.

Treatment.—After removal of the tooth or teeth in the immediate neighbourhood, a wedge of alveolus containing the growth is excised. If preliminary histological examination, which is often advisable, reveals much sarcomatous tissue, treatment by radium, with or without excision, is undertaken.

3. **Myelomatous Epulis.**—Giant-celled growths occur in the alveolar margin, particularly in the upper jaw.

Treatment.—Local excision, swabbing out the cavity with antiseptics, followed by packing, is usually satisfactory.

4. **Carcinomatous epulis** is a particularly undesirable term,

for it is but another way of expressing that the carcinoma begins on the gum. Its treatment follows that described for the tongue and the floor of the mouth, unless it has invaded the jaw. See p. 133.

THE JAWS

Osteomyelitis of the Jaws

Acute osteomyelitis of the jaw is not common.

In the upper jaw it is decidedly infrequent, except in infants. The first sign is a puffiness of the face under the eyes. Fortunately sinuses usually develop spontaneously into the mouth, but abscesses may require opening. As a rule these children recover with surprisingly little deformity.

In the lower jaw acute osteomyelitis is not so rare. It affects particularly children between the ages of 5 and 10, but is liable to complicate an alveolar abscess at any age. Necessary incision should be made, if possible, within the mouth, and carious teeth within the inflamed area must be removed. Mouth-washes are then ordered until the sequestrum separates. These sequestra are often comparatively large (fig. 51). Involucrum formation in the jaws is decidedly poor, but it does occur when the patient is young. After middle life there is practically no regeneration.



Fig. 51.—Sequestrum from the mandible following a case of acute osteomyelitis in a boy of 5½ (Pitts).

Chronic osteomyelitis (*syn.* **necrosis of the jaw**) is seen particularly in the lower jaw, and it occurs in a number of ways :

1. *Following a fracture,* for fractures of the jaw are so commonly compound (into the mouth).

2. *As an extension of an alveolar abscess.*

3. *Tuberculous, syphilitic, and actinomycotic necrosis* of the jaws can occur. The well-known clinical entity of a hole in the hard palate following a gumma is an example of syphilitic necrosis.

4. *Chemical necrosis* is now exceedingly rare. "Phossy jaw" was common in match-workers in days gone by, when yellow phosphorus was used. Mercurial necrosis was said to occur when massive doses of mercury were administered in the treatment of syphilis. To-day chemical necrosis is seen occasionally after arsenic has been used injudiciously in dental practice to kill the nerves of teeth.

Necrosis of the jaw is often very chronic. Mouth-washes are ordered, external sinuses are kept clean, and removal of sequestra are undertaken when loose. Radiography is helpful particularly in indicating the time for operation, i.e. when the sequestrum has separated.

MEDIAN MENTAL SINUS

Median mental sinus (fig. 52) is a clinical entity which is so often incorrectly diagnosed and treated that it seems desirable to call attention to it here. The patient has a discharging sinus on, or less frequently just below, the chin, but always in the middle line. He usually states it has been scraped and packed many times. X-ray of the bone in the immediate neighbourhood reveals nothing, but an X-ray of the lower incisor teeth, which on clinical examination often appear to be sound, shows an area of rarefaction around the roots. The case is one of paradental abscess, and the pus has tracked between the two halves of the lower jaw to the point of the chin. After extraction of the affected teeth the sinus heals within a fortnight.

Fig. 52. Median mental sinus.

Malignant Disease of the Upper Jaw

The clinical diagnosis of "malignant upper jaw" embraces a number of pathological conditions:

1. *Sarcoma.*

2. *Squamous-celled carcinoma*—derived from a tooth socket or the gum.

3. *Columnar-celled carcinoma*—arising from the maxillary antrum or nasal cavities.

4. *Malignant odontome*—according to Eve, not a few cases of malignant upper jaw belong to this group.

5. *Invasion of the upper jaw by a sarcoma of the ethmoid or a naso-pharyngeal tumour.*

Sarcoma of the Upper Jaw

While neither sex nor age is exempt, curiously, this disease has a distinct predilection for women about the age of 45 (fig. 53). When of the periosteal variety—and this is the more usual—it is the *anterior* aspect of the jaw which is maximally affected, but it soon shows itself on the inferior or palatal wall. Until perhaps the terminal stages of the disease, there is no nasal obstruction and no epiphora (blockage of the tear-duct).

FIG. 53.—Sarcoma of the upper jaw (Macewen, *Text-book of Surgery*).

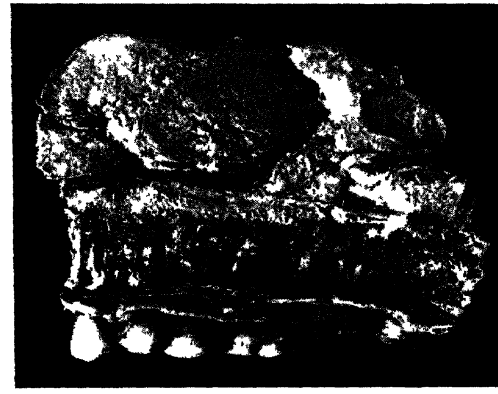

FIG. 54.—Malignant growth of upper jaw invading antrum.

Growths arising from within the Antrum or its Walls

Growths arising from within the antrum or its walls (fig. 54), which include both cases of carcinoma and endosteal sarcoma, are, in contradistinction to the above, characterised by early unilateral nasal obstruction. Sometimes the latter is accompanied by foul or blood-stained discharge from one nostril. Epiphora is common, and trigeminal neuralgia may be a symptom.

DIFFERENTIAL DIAGNOSIS OF MALIGNANT UPPER JAW

Cysts, especially large follicular odontomata and myelomata, present difficulty. Much help can be derived from an X-ray examination. A closed empyema antri with polypi must also be excluded. The bilateral character of leontiasis

ossea (p. 816) makes the segregation of this condition tolerably simple.

Treatment of Malignant Upper Jaw.—Complete excision of the upper jaw (fig. 55) has been practised for centuries. Since the introduction of intratracheal anæsthesia the operative mortality is low. There is surprisingly little deformity after this formidable operation, especially if a prosthesis is constructed by a dental expert as soon as the wound has granulated. Such treatment offers a hope of a cure in comparatively early cases, but recurrences are only too common.



FIG. 55. Incision[1] for removal of the upper jaw.

The use of surgical diathermy has not only improved the end result, but has allowed extirpation to be carried out in cases which would previously have been considered inoperable. It can be used in conjunction with radium. The upper jaw is exposed by a plastic flap, and the growth excised until apparently healthy bone is reached. A cavity is left beside the nose through which the radium can be implanted when the slough separates. Successful cases can be followed by various plastic procedures.

NASO-PHARYNGEAL TUMOUR

Naso-pharyngeal tumour is peculiar to patients in their teens. It is a sarcoma arising from the mucoperiosteum of the under-surface of the body of the sphenoid. It grows into, and plugs, one or both nasal fossæ, and is liable to produce epistaxis. The three leading symptoms are deafness (usually unilateral), neuralgia from pressure on the second division of the fifth cranial nerve, and displacement downwards of the soft palate. Although naso-pharyngeal tumours are very malignant, at their point of origin they are essentially pedunculated. This makes them both removable and curable by a bold surgical operation, comprising temporary resection of the upper jaw (which is swung outwards) and erasure of the pedicle from the under-surface of the body of the sphenoid. After the tumour has been removed the jaw is replaced and the skin sutured. This operation is accompanied by torrential hæmorrhage, but if skilfully performed the patient usually recovers and is cured.

SARCOMA OF THE ETHMOID

Sarcoma of the ethmoid is rare. As it expands it greatly widens the space between the orbits and flattens out the nasal bones, pro-

[1] The outer third of the infraorbital incision should curve downwards slightly to avoid division of the lymphatics draining the lower lid.

ducing that well-known clinical entity, the "frog-faced man." Still later the superior maxillæ are invaded. Attempts have been made to remove the growth, but usually without success (see also p. 162).

Cysts about the Orbit

From the point of view of clinical surgery it is convenient to group together certain conditions which have but one

Fig. 56.—External angular dermoid.

Fig. 57.—A Meibomian cyst (Mayou).

Fig. 58.—A mucocele of the lachrymal sac (Mayou).

point in common—they form cystic swellings in the neighbourhood of the orbital margin. Passing latero-medially (figs. 56, 57, and 58) we may recognise :

1. **An External Angular Dermoid.**—This is perhaps the commonest situation for a dermoid cyst (fig. 56), and its position is so constant that it allows the diagnosis to be made with irrefutable accuracy. The treatment is excision.

2. **A Meibomian cyst** usually occurs in the upper eyelid (fig. 57). It is due to a staphylococcal infection of a Meibomian gland, the swelling being, for the most part, retained Meibomian secretion.

Treatment consists of making an incision into the cyst from its conjunctival aspect, and scraping out the sac wall with a small spoon.

3. **A mucocele of the lachrymal sac** (fig. 58) is the result of lachrymal obstruction with distension of the sac and secondary infection of its walls.

Treatment consists of washing out the sac by means of a

lachrymal syringe and removing the cause of the obstruction.

A Median Cyst over the Root of the Nose.—A cyst in this situation which does not empty with pressure is most likely a dermoid. If it can be made to empty a meningocele is probable, but a sinus pericranii, connected with one of the intracranial venous sinuses, must receive due diagnostic consideration.

Tumours of the Orbit

Clinical Features.—Proptosis is the cardinal symptom. The eye is seldom pushed directly forward except when the tumour is growing from the optic nerve or its sheath (fig. 59). Visual disturbances are complained of, and the lids are prone to become œdematous. In advanced cases the cornea becomes inflamed because it is exposed unduly.

Fig. 59. Tumour of the optic nerve (Werner).

Classification.—Tumours of the orbit may be primary or secondary. The principal primary tumours are :

1. **Osteoma.**—It will be recalled that ivory osteomata grow from membrane bones, particularly the lachrymal bone.
2. **Carcinoma** from the lachrymal gland.
3. **Glioma** from the optic nerve.
4. **Melanoma** from the uveal tract.
5. **Sarcoma.**

While it is undesirable here to enter into the particular features of each of these tumours, in a general way they may be divided into two important clinical groups :

(*a*) Those occurring in children ;

(*b*) Those occurring in adults.

In the child glioma is the commonest. It is frequently bilateral, and occurs before the age of 4 years. Proptosis is considerable, and early blindness the rule. This tumour is highly malignant, and it soon breaks down and bleeds. The prognosis is hopeless.

In the adult melanoma is the principal primary tumour.

It commences in the posterior part of the choroid, and it is always unilateral. It generally occurs in individuals between 40 and 60 years of age. An orbital melanoma shows little tendency to spread into the cranium, but blood-borne metastases are carried to the liver, lymphatic glands, and bone. If the globe is removed early in the course of the disease this dissemination may be postponed, but rarely is the expectation of life more than three years. Sometimes, after early diagnosis and excision of the globe, the dissemination of metastases is postponed for many years, and there arises a classical pitfall for the unwary diagnostician. Wherefore it has been remarked, with much wisdom, that the clinician should " beware the patient with a large liver and a glass eye " (fig. 60).

FIG 60.—Patient with a greatly enlarged liver, who for many years had worn a glass eye.

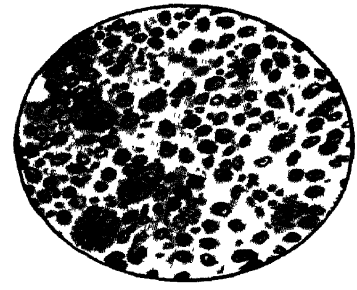

FIG. 61.—Section of the liver from patient in previous fig , showing secondary melanoma.

PULSATING EXOPHTHALMOS

Unilateral pulsating exophthalmos is a rare condition which always excites clinical interest. The principal causes are as follows :

1. An arterio-venous aneurism between the internal carotid artery and the cavernous sinus ; invariably traumatic in origin.
2. An aneurism of the ophthalmic artery.
3. A cirsoid aneurism involving the orbit.
4. Thrombosis of the cavernous sinus. However, pulsation is not a usual feature of this condition.
5. Rapidly growing vascular intraorbital neoplasms.

Subjective Symptoms.—In the first three conditions the patient notices a buzzing noise in the head and failing of vision.

Treatment.—The first variety, which is the commonest, is the

most amenable to treatment. Ligature of the orbital veins may be tried, and is successful in 42 per cent. of cases. When this fails, ligature of the internal carotid artery is resorted to, the combined operation curing a further percentage. For the other varieties of aneurism the reader is referred to p. 78.

Orbital Cellulitis

Cellulitis of the orbit gives rise to proptosis, œdema of the eyelids, and œdema of the conjunctiva (chemosis) (fig. 62). The constitutional symptoms are often severe. There are two outstanding dangers of infection of this space. Firstly, thrombophlebitis of the cavernous sinus may follow via the ophthalmic plexus of veins, and secondly, the globe of the eye may become infected. It is therefore imperative to drain the space at the earliest possible moment. This is done through an incision following the lower orbital margin.

Fig. 62.—Orbital cellulitis. Note the chemosis. An incision has just been made.

Injuries of the Eye

Injuries of the eye belong properly to the domain of Ophthalmology. It is necessary here to call attention to a peculiar danger of perforating wounds of the globe. After a penetrating wound of the eye, particularly when a portion of the uveal tract prolapses, there is always the danger of sympathetic ophthalmia, in the event of which the sight of both eyes may be lost. The only certain way of avoiding sympathetic ophthalmia is to remove the injured eye promptly.

EXCISION OF THE EYEBALL

In addition to the above, excision of the eyeball is undertaken for neoplasms, and in blind, painful eyes.

The Operation.—The speculum is introduced between the lids, and opened. The conjunctiva is picked up with tooth forceps and divided completely all round as near as possible to the cornea. Tenon's capsule is entered, and each of the rectus tendons is hooked

up on a strabismus hook and divided close to the sclerotic. The speculum is now pressed backwards and the eyeball starts forwards. Blunt scissors, curved on the flat, are insinuated on the inner side of the globe, and these are used to sever the optic nerve. The eyeball can now be drawn forward with the fingers, and the oblique muscles, together with any other strands of tissue which are still attaching the globe to the orbit, are divided. A swab moistened with a little adrenalin and pressed into the orbit will control the hæmorrhage.

EVISCERATION OF THE EYEBALL

Owing to the danger of opening up lymph spaces at the back of the globe and thus favouring meningitis and sympathetic ophthalmia, evisceration is much to be preferred to excision in panophthalmitis. The sclera is transfixed with a pointed knife a little behind the corneo-sclerotic junction, and the cornea is removed entirely by completing the encircling incision in the sclera. The contents of the globe are then scraped out by means of a spoon, care being exercised to remove all the uveal tract. At the end of the operation the interior must appear perfectly white.

THE FACE

Wounds

Thanks to its abundant blood-supply, wounds of the face heal readily. Very accurate approximation of the skin edges is desirable to prevent an unsightly scar.

Acute Infections of the Face

Boils are more dangerous in this area than similar lesions elsewhere. A furuncle or carbuncle of the lip or nose is particularly dangerous, and the former has been referred to in some detail on p. 104.

Fig. 63.—Cutaneous anthrax (Hodgson).

Anthrax.—While cutaneous anthrax can occur in any part of the body exposed to infection, the face is the commonest site for the so-called "malignant pustule" (fig. 63), prompt recognition of which is so important. A differential diagnosis must be made between

anthrax and two conditions easily mistaken for it. The first is a virulent furuncle, and the second accidental vaccinia. The contagion in accidental vaccinia often takes place in the following way. The recently vaccinated child with the cutaneous lesion on its arm in full activity, while being carried by its mother or nurse, abuts the vaccinated area against her cheek. Final and absolute diagnosis of anthrax rests in demonstrating the anthrax bacillus.

FIG. 64.—An early rodent ulcer (Paul)

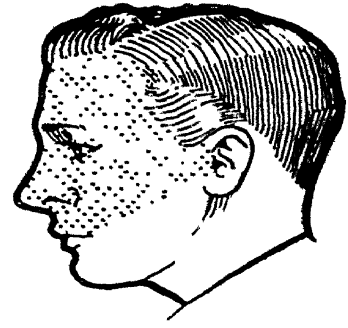

FIG. 65. Rodent ulcer usually occurs above an imaginary line joining the angle of the mouth to the external auditory meatus.

NEW-GROWTHS

Simple nævi (cutaneous hæmangiomata) are often found on the face. Small tumours can be satisfactorily removed by an application of carbon-dioxide snow. Larger ones may yield to treatment by radium, but the very extensive variety call for the highest efforts of plastic surgery.

Pigmented and Hairy Moles.—The face is a common situation for pigmented or hairy moles, and one for which the patient seeks relief on account of the disfigurement. Their removal is also to be urged on account of the danger of the development in the pigmented area of a melanoma. Hairy moles are successfully treated by the Italian method, which consists of excising the mole and filling the defect with a graft raised from the arm. The arm is fixed by plaster of Paris in the desired position as long as is necessary for ensuring the nutrition of the flap of skin.

Rodent Ulcer (Basal-celled carcinoma).—Rodent ulcers are almost confined to that portion of the face situated above

a line joining the external auditory meatus with the angle of the mouth (fig. 65), the site of election being near the inner canthus. The patient is always elderly, and the ulcer appears as an irregular sclerotic scar surrounded by an area of small grey elevations, traversed here and there by a fine capillary vessel. Rodent ulcer is essentially very chronic, but usually steadily progressive. In process of time it does, as its name implies, eat into muscles, cartilage, and bone, producing ghastly disfigurement, the interior of the orbit, nose, and even the brain being exposed by the ulcer. Death releases the victim by erosion of a large artery, or by inhalation broncho-pneumonia. *Even in advanced cases metastases are almost unknown.*

Treatment, in the early stages, by X-ray is on the whole satisfactory, but recurrences are rather frequent. Radium and treatment by excision also yield good results under similar conditions. In advanced cases diathermy excision is probably the most effective method of attempting to arrest the progress of the disease

CHAPTER VIII

THE MOUTH IN GENERAL. THE TONGUE. THE FLOOR OF THE MOUTH, AND THE CHEEK

INFECTIONS

STOMATITIS is a general term which embraces all infections of the mouth. A few of these can be distinguished as specific disorders.

1. **Acute Catarrhal Stomatitis.**—The mucous membrane is swollen, of a dusky red colour, and there is an increased secretion of mucus. Eating is painful, and small superficial ulcers frequently occur. Acute stomatitis may be associated with the cutting of teeth in infancy, with carious teeth in later life, with abuse of spirits or tobacco, or poisoning by iodides, lead, or mercury.

The treatment consists of removal of the cause and the use of a simple alkaline mouth-wash.

2. **Aphthous stomatitis or thrush** occurs in infants. It is due to the oidium albicans, which is found in sour milk. The disease appears as spots on the buccal mucous membrane, varying in size from a pin's head to a pea. They are at first red, and later become covered with a yellow exudate. Pain and salivation are constant accompaniments. The condition gradually subsides without treatment, but the mouth should be kept sweet with boroglycerol, and precautions taken to see that the milk is fresh and the utensils in which it is served scrupulously clean.

3. **Vincent's angina or trench mouth** is, at any rate in part, due to infection by Vincent's spirillum. Essentially a disease of young adult life, it is exceptional to find it after the age of 35. The mouth, tonsils, and gums become inflamed, and covered with grey patches surrounded by a red

zone. Trench mouth is resistant to treatment, but the eventual prognosis is good. Removal of carious teeth should be undertaken, and permanganate mouth-washes are helpful. Painting the affected area with a 10 per cent. solution of novoarsenobenzol in glycerol brings about a cure more quickly than any other form of medication.

FIG. 66 —Cancrum oris. (R.C.S., 5919.1.)

4. **Cancrum oris.**—This very fatal condition is now seldom seen. It was perhaps related to the now extinct "hospital gangrene," and it attacked children debilitated by acute infectious fevers. Various bacteria have been isolated, but there is no conclusive proof that cancrum oris is due to any one organism. The lesion first appears as an indurated area on the under-surface of a lip. This soon becomes an ulcer, and is followed by a gangrenous process destroying the lips, cheeks, and gums (fig. 66). In a few days the whole face sometimes becomes a black, putrefying mass. The only treatment is to excise the area in the early stages with an actual cautery, and to paint the edges with 10 per cent. formalin. The resulting mutilation can be improved later by plastic surgery.

CYSTS

Retention cyst of the buccal mucous glands occurs from time to time in any part of the mucous surface of the mouth. It forms a translucent globular swelling (fig. 67), which should be dissected out under local anæsthesia.

FIG. 67.—Retention cyst of a buccal mucous gland.

Ranula

A ranula implies a *transparent* cystic swelling in the floor of the mouth, mainly, if not entirely, unilateral.

Simple Ranula.—The patient may state that the swelling has come up before and burst, perhaps several times. If the swelling is observed closely (fig. 68) tortuous veins are seen

Fig. 68.—A large ranula invading both sides of the floor of the mouth, but mainly confined to the left. Wharton's ducts can be seen traversing over the swelling.

Fig. 69.—Myxomatous degeneration of the gland of Blandin and Nuhn.

traversing over it, and at one point towards the apex the buccal mucosa seems deficient, as though the cyst was bursting through its covering. An opaque strand can often be made out coursing over the wall; this is Wharton's duct, which is displaced, but takes no active part in the pathological process. Before concluding the examination the possibility of a deep prolongation must be excluded by palpating beneath the jaw. The diagnosis of simple ranula is, as Butlin remarked, "plainly written on the face of the tumour."

Pathologically a simple ranula is to be regarded as a myxomatous degeneration of a mucous gland. The gland at fault may be the sublingual, the gland of Blandin and Nuhn, or one of the solitary glands studded over the buccal mucous membrane. The gland of Blandin and Nuhn is a

variable structure, which is sometimes situated farther down the inferior surface of the tongue (fig. 69).

Treatment.—*Complete Excision.*—A difficulty in ideal treatment is that the cyst bursts before dissection can be completed. If some of the fluid within the cyst can be aspirated before commencing enucleation, complete dissection is usually possible. Often, however, the contents are of the consistency of jelly, and will not flow through a hollow needle.

Partial Excision with Marsupialisation.—A portion of the cyst wall is removed. The free edge of the resulting cavity is united by fine catgut suture to the buccal mucous membrane throughout its circumference. This operation is frequently practised in this country. In addition, some operators swab out the cavity of the cyst with phenol or iodine.

Whichever method is practised, it is necessary to preserve the integrity of Wharton's duct.

Deep or Plunging Ranula

There still remains a group of cases which from the mouth appear to be typical ranulæ, but if the neck is examined a cervical prolongation will be found continuous with the intrabuccal one. Thompson seeks to explain the riddle of these cysts by stating that they are derived from the cervical sinus—an embryological structure. At any rate, his hypothesis furnishes a logical basis for adequate surgery. This type of ranula must always be attacked through the neck. Usually by this route complete dissection is possible. Very occasionally the depths to which the deep ranula plunges are forbidding.

Sublingual Dermoid

A "sublingual dermoid" (fig. 70) is situated mainly to one side of the middle line, and may attain considerable dimensions. The swelling, which is a thin-walled cyst filled with sebaceous material, is probably derived from the mesobranchial field of His. There is a projection in the floor of the mouth, and at the same time often a fullness

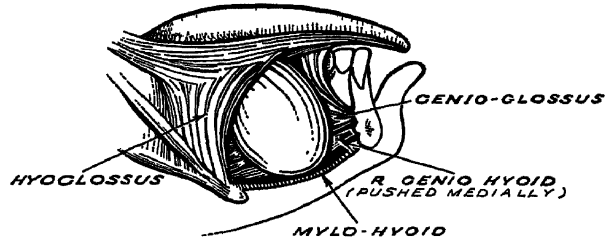

Fig. 70.—Relationships of a sublingual dermoid (after Warren and Cooper).

beneath the jaw. Whereas a ranula is transparent, this swelling is opaque. A sublingual dermoid must also be distinguished from a supra-hyoid thyroglossal cyst, which occupies a strictly median plane.

The treatment is removal by dissection through an external incision beneath the jaw.

Hæmangioma sometimes occurs under the mucous membrane of the cheek and the floor of the mouth.

Tumours

Carcinoma may arise in any part of the mucous lining of the mouth. It is often the aftermath of some form of chronic irritation. Thus, in those Eastern races who indulge in chewing the betel-nut and store the quid thereof in their cheek, carcinoma of the mucous aspect of the cheek is a common occurrence. In Western races carcinoma of the mouth usually attacks the tongue and the floor of the mouth, and it will be considered fully in that section (p. 133).

Mixed Tumour of a Molar Gland.—The molar glands are four or five in number. They lie on the outer side of the buccinator, their ducts piercing that muscle to open into the vestibule of the mouth. Cysts and mixed tumours, morphologically akin to the well-known mixed parotid tumour, occasionally occur in these glands. This is a convenient point to discuss briefly the differential diagnosis of other localised swellings of the cheek not arising in the integument or the mucous membrane.

Fig. 71.—Well-developed sucking pad.

A Lipoma developing in the Sucking Pad of the Infant.—The sucking pad is a ball of fat situated between the masseter and the buccinator. Well developed in infancy (fig. 71), it atrophies during childhood. On occasions a lipoma arises in the vestige which remains.

Adenitis of the Facial Lymph Gland.—Few individuals possess a facial lymph gland; consequently infection coursing along the lymphatics of the cheek usually passes direct to the submaxillary nodes. When a facial lymph gland is present its enlargement will perplex the diagnostician unaware of its existence.

THE TONGUE

TONGUE-TIE

is really very rare, though nearly every mother fears that her first-born is tongue-tied. A former generation of surgeons must have agreed with the mothers ; for witness, the grooved director (fig. 72) is even to-day fitted with a guard for use when dividing the frænum linguæ. This shield is held against the uplifted tongue and the frænum snipped near the floor of the mouth, the better to avoid the frænal artery. The operation must be done with prudence, for if the frænum is divided too far the over-mobile tongue may be "swallowed" and asphyxia results.

FIG 72.—Director with guard and frænum slit.

MUSCULAR MACROGLOSSIA

is practically confined to idiots and cretins (see p. 168). The large tongue protrudes from the mouth, and is liable to become dry and cracked. It is constantly being bitten, and there is no doubt that if the patient has attained the age of 3 the protruding portion should be excised.

Macroglossia may also be due to acute inflammation, syphilis, lymphangioma, and chronic mercurial poisoning. The first three of these will receive consideration in their appropriate sections.

INJURIES

Anæsthetists are familiar with the possibility of the unconscious patient biting his tongue, and so commonly does this accident occur in epileptics that attendants are provided with rubber bits to put between the patient's teeth when a seizure is heralded. The most common deep wound of the tongue follows a blow or a fall while the patient is smoking a pipe, which breaks and is driven into the musculature of the tongue.

As a means of checking severe hæmorrhage from the posterior part of the tongue, Heath recommends passing the finger as far back as possible and hooking the tongue forward on to the jaw.

Wounds of the tongue heal readily, and an almost completely divided segment, if sutured into position, will often remain viable and unite.

ACUTE SUPERFICIAL GLOSSITIS

may follow scalds or other injuries. Under this heading may be included herpes of the tongue. Healing occurs

readily under treatment by weak antiseptic alkaline mouth-washes. Acute superficial glossitis may also be due to an infection by Vincent's spirillum (fig. 73).

Acute Parenchymatous Glossitis

In well-marked cases the tongue swells enormously, protrudes from the mouth, and threatens life by asphyxiation. The patient often becomes extremely toxic. The condition, which is rare, arises in a number of different ways.

Fig. 73.—Acute glossitis. Vincent's spirillum isolated from a specimen of serum removed from one of the vesicles.

1. Classically, a wasp inserts its sting into the tongue of a holiday-maker who is quaffing ginger-beer from a bottle which has been left open.

2. From pyogenic infection of a deep lingual wound.

3. As a part of Ludwig's angina (see p. 149).

In severe cases it is necessary to be prepared for tracheotomy, which, however, is seldom actually required if the patient is treated as follows. Ice is applied to the tongue, oxygen inhaled as required, and the patient is reassured. In ultra-acute cases the œdematous tongue must be incised.

Chronic Superficial Glossitis (*syn.* Leukoplakia Glossitis)

Ætiology.—90 per cent. of patients with well-marked leukoplakia glossitis have a positive Wassermann reaction. This, in addition to some local irritation, is the predisposing cause. The ætiological factors can be well summarised as Smoking, Syphilis, Sharp tooth, Sepsis, Spirits, and Spices.

Clinical Features.—Smoker's patch is an early manifestation. In this, and in the more widespread varieties of

chronic superficial glossitis, the tongue is red and glazed, for its epithelium has been shed. Unless treatment is adopted, the second stage becomes apparent in a few weeks, and it is in the second stage that the patient usually presents himself. Now the tongue is "as though covered with white paint which has hardened, dried, and cracked" (Butlin) (fig. 74). Later the thickened epithelium becomes still thicker in places, while in others it peels off. Warty projections, fissures, and ulcers appear. Leukoplakia is an established precancerous condition, and by the time the last stage has appeared the development of a carcinoma in one of the diseased areas is not far distant. Except in the later stages, when the tongue is denuded of epithelium, there is no pain.

Treatment.—Remove the cause. Institute thorough anti-syphilitic and dental treatment in necessary cases. Stop pipe smoking altogether. Spirit drinking must be given up. A mild antiseptic alkaline mouth-wash is prescribed, and

FIG. 74.—Leukoplakia glossitis.

FIG. 75.—Butlin's operation, showing the portion of tongue to be removed.

the patient is advised to smear some white vaseline over his tongue before he retires. "Touching up" the patches with caustics of any kind should be rigorously eschewed, as the development of carcinoma is thereby encouraged. It is essential for the patient to report once a fortnight, when the clinician reviews the case, watching for the possible development of malignancy. If, after a reasonable time, the condition is not improving, or if it is getting worse, **Butlin's**

operation should be advised. This operation is an excellent one, which is not performed sufficiently often. The principle is to remove a slice of the dorsum, including the diseased area (fig. 75), and to unite the resulting raw edges with sutures.

GEOGRAPHICAL TONGUE OF CHILDREN

Red rings with a yellow border are characteristic. The distribution is, as the name implies, irregular, and the disease runs a very chronic course. Itching and salivation are the leading symptoms. The treatment follows general lines.

Lingual Tuberculosis

The only tuberculous lesion of the tongue which is at all common is **tuberculous ulceration.** These shallow ulcers, often multiple and situated on the edges of the tongue, are extremely painful. In the majority of cases the patient has advanced phthisis, and the infection is carried to the tongue by the sputum. The main object of treatment is to relieve the intense pain, and orthoform powder (a local anæsthetic) is useful in this respect. The powder is blown on to the ulcerated surface, and quickly renders the area insensitive for about an hour. Painting the ulcers with a 50 per cent. solution of lactic acid sometimes improves matters, but as long as infected sputum is coughed up, the condition is liable to recur.

Very rarely, tuberculous nodes are present on the dorsum.

Another exceptional tuberculous manifestation is an ulcer of considerable dimensions, which is difficult to distinguish from a gumma or carcinoma without histological aid.

Fig. 76 Hutchinson's wart.

SYPHILIS OF THE TONGUE

Primary Syphilis.—An extra-genital chancre can occur on the tongue. The submaxillary and submental glands become greatly enlarged, as in the case of a similar lesion on the lip.

Secondary Syphilis :

1. *Multiple shallow* ("*snail track*") *ulcers* may be present on

the sides and under-surface, and they have to be distinguished from tuberculous ulcers (*vide supra*).

2. *Mucous patches* occur on the tongue as well as on the fauces.

3. *Hutchinson's wart* (fig. 76), really a condyloma, is a strictly median "wart," and it has to be distinguished from an ordinary simple papilloma which happens to occupy the middle line.

Tertiary Syphilis :

1. *Gumma of the tongue* nearly always occupies the middle line. It possesses the characteristics of gummata elsewhere and does not tether the tongue.

2. *Parenchymatous Gummatous Infiltration.*—The whole tongue becomes enlarged—indeed, it may be called syphilitic macroglossia.

3. The frequency of chronic superficial glossitis in syphilitic patients has been noted already.

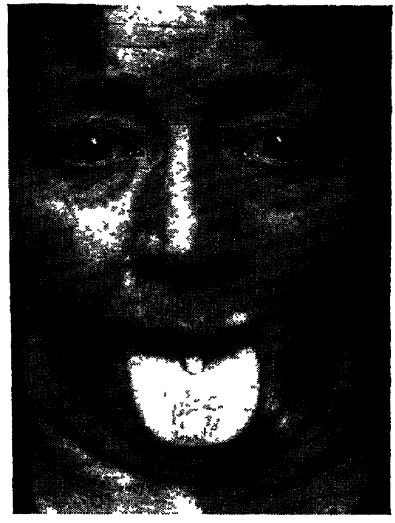

FIG. 77.—Gumma of the tongue.

ULCERS OF THE TONGUE

It is advisable at this stage to review briefly the more common types of ulcers of the tongue, as their differential diagnosis is so important in the practical application of clinical surgery.

Non-specific.—**Dyspeptic ulcer** is a small, rounded painful erosion with a white centre. It often occurs near the tip of the tongue, and is more common, not in the "chronic dyspeptic individual," but during adolescent life.

Dental ulcer occurs always at the side of the tongue. It is inclined to be rather elongated, after the nature of a scratch or crack. It is usually painful, but not necessarily so. A decayed or broken tooth, or the hook of a denture, will be found to be the causative agent.

Post-pertussis ulcer is seen at the frænum linguæ. Of necessity, this occurs only in children after whooping-cough.

Specific.—**Tuberculous ulcers** are multiple, and situated at the edges of the tongue. The leading characteristic is that they are agonisingly painful.

Syphilitic Ulcer.—The most typical is the gumma situated in the middle line of the dorsum rather nearer the base than the tip of the tongue.

Malignant.—**Carcinomatous ulcer** has typically the clinical features of a squamous-celled carcinoma—viz. an indurated, everted edge.

If doubt exists as to the nature of an ulcer—and it is sometimes difficult to be certain when dealing with cases of early carcinoma—a fragment should be removed under local anæsthesia and submitted to histological examination. It should be noted particularly that a positive Wassermann reaction is not of so much value in establishing a confident diagnosis as is the case in other situations. It is not uncommon for a patient with carcinoma of the tongue to have a positive W.R.

Neoplasms of the Tongue

Benign neoplasms are comparatively rare. They are completely over-shadowed by the appalling frequency of carcinoma of this organ. Lipomata, fibromata, plexiform neuromata, and even osteomata are described, but all are pathological curiosities.

Papilloma is the commonest benign tumour of the tongue. It may be sessile or pedunculated. To ensure non-recurrence, it should be excised, preferably with a diathermy knife, together with a small wedge of normal tissue about its base.

Lymphangioma.—When noticed soon after birth there is usually only a small circumscribed patch of dilated lymph-vessels. This may remain stationary in size for long periods, but more often increases rapidly. Attacks of inflammation occur at irregular intervals. At last the swollen tongue permanently protrudes from the mouth—lymphangiomatous macroglossia. Treatment by radium has given encouraging

results. When this fails partial glossectomy must be resorted to.

Angioma in this situation is usually venous (fig. 78). The veins which form the tumour are liable to become wounded and bleed. Such hæmorrhage may be so persistent as to render the patient severely anæmic, as we have witnessed.

FIG. 78.—Venous hæmangioma of the tongue in a woman of 23. She complained of blood appearing in her mouth.

FIG. 79.—Carcinoma originating near the frænum linguæ (Fitzwilliams).

The treatment is excision of the tumour : a diathermy knife is particularly useful in this instance.

Lingual thyroid (see p. 167).

MALIGNANT TUMOURS

Carcinoma of the Tongue is somewhat less frequent than it was a generation or two ago. More thorough treatment of syphilis, the passing of the clay pipe, the welcome activity of our dental colleagues, and possibly a decrease in the consumption of spirituous liquors, are the chief reasons for this decline. Notwithstanding, the disease is still very common.

Clinical Features.—The patient is usually a middle-aged or elderly man. If he is observant, he seeks advice because of the actual lesions on his tongue. The carcinoma, which is squamous-celled, may take the form of—

1. An ulcer.
2. A warty outgrowth (fig. 79).
3. A fissure.
4. An indurated mass, which has been likened to the woody tongue of cattle (actinomycosis). This last is exceptional.

It is a sad fact that a large number of patients fail to notice or disregard the lesion in its early stages, and report because of one or more of the later symptoms, which are :

Pain.—This may be in the tongue or referred to the ear. The latter is not unusual, and many a patient with carcinoma of the tongue comes with a wad of cotton-wool in his ear, complaining solely of earache. The explanation of this phenomenon is that the lingual nerve is irritated, and the pain is referred to another branch of the third division of the fifth cranial nerve, to wit, the auriculo-temporal.

Salivation.—Profuse salivary secretion is common in lingual carcinoma. It is well known that if an elderly man, sitting in the surgical out-patient department, is seen to be constantly spitting into his handkerchief, it is highly probable that his case is one of carcinoma of the tongue. In late stages the saliva is blood-stained.

Ankyloglossia.—The tongue cannot protrude fully. This bespeaks extensive carcinomatous infiltration of the lingual musculature or the floor of the mouth.

Dysphagia.—The patient experiences difficulty in swallowing. This symptom is more pronounced when the growth is in the posterior third of the tongue.

Inability to Articulate Clearly.—Factors 1, 2, and 3 all may play a part.

Fœtor.—The patient becomes offensive to his associates because of the secondary bacterial stomatitis.

A lump in the neck, due to secondary deposits in the cervical lymphatic glands.

A growth situated right at the back of the tongue may not unreasonably escape the notice of an intelligent patient and even of his careful medical adviser. Early alteration of the voice is often a feature of these cases. Palpation of the posterior part of the tongue and laryngoscopic examination are cardinal methods in arriving at the diagnosis.

Before leaving the subject of clinical features of carcinoma of the tongue, the reader's attention is drawn to the importance of precarcinomatous conditions, particularly chronic superficial glossitis (p. 128), chronic dental ulcer (p. 131), and papilloma (p. 132), the thorough treatment of which would doubtless prevent many cases of lingual carcinoma.

Spread of the Disease.—Carcinoma of the *anterior two-thirds of the tongue* tends to invade the floor of the mouth. The submental and submaxillary glands soon become invaded, first on the side of the lesion in comparatively early cases. There is often microscopical evidence of carcinomatous infiltration in the upper jugular chain of lymphatic glands. In a case of some standing the stony-hard enlargement of this glandular group is found only too often. Carcinoma of the *posterior third of the tongue* tends to spread to the soft palate and the pharynx. Glandular involvement of the jugular chain on either side occurs early.

Carcinoma of the tongue is a disease which is essentially confined to the mouth and neck. Untreated, it runs a variable, but inevitably fatal, course. Death occurs usually in one of the following ways :

1. *Inhalation broncho-pneumonia*, from the superadded oral sepsis.

2. *Combined cancerous cachexia and starvation.*

3. *Hæmorrhage*, from the primary growth, or secondary glands, eroding an artery.

4. *Asphyxia*, which is due either to secondary carcinomatous cervical glands pressing upon the air passages or from œdema of the glottis. The latter is rare, and occurs as an extension of lymphatic œdema around a growth at the back of the tongue.

Treatment.—Absolute agreement has not yet been reached.

The tendency is to employ radium for the destruction of the primary growth. In the hands of many surgeons diathermy excision has proved satisfactory. These two measures have largely supplanted older operations. No matter which method is employed to destroy the primary growth, experience shows that the surest measure of eradicating secondary deposits in the neck is by careful dissection.

Radium.—Treatment by radium has proved of lasting benefit in the case of carcinoma of the tongue.

Technique.—The patient is rendered edentulous, and antiseptic mouth-washes are prescribed. As soon as the gums have healed, an anæsthetic is given, and needles containing an equivalent of ·6 mg. of radium element, screened by ·5 mm. of platinum, are inserted around the growth. These needles are pushed into the tongue 1 cm. apart, until their butt ends are just beneath the surface. Here they are anchored in the following way. One end of the silk thread which is attached to each radium needle is threaded on a curved needle, which is passed through an adjacent portion of the tongue and knotted. The radium is left in position for from six to eight days. Owing to the danger of necrosis of the jaw following radium treatment of the tongue and floor of the mouth, it is a wise precaution to have dental tooth plates screened by lead in position during the tenancy of the radium.

In cases of carcinoma of the posterior part of the tongue, difficulties are experienced in maintaining radium needles in position, and various ingenious methods have been employed, details of which will be found in technical works on the subject. When the carcinoma is situated near the epiglottis, lateral pharyngotomy is necessary to give access to the growth before the radium can be inserted (see also Pharynx, p. 193).

Diathermy Excision.—The growth is excised with a diathermy knife. When possible the excision should include ¾ in. of healthy tissue upon all sides of the neoplasm. Preliminary ligation of the external carotid artery is usually advisable. It is convenient to dissect the glands of the neck and at the same time tie this artery before removing the primary growth.

Older Operations.—Candidates for examination are occasionally asked the classical operations for excision of the whole or part of the tongue.

Whitehead's Operation.—As a preliminary measure the external carotid artery is tied. Through the open mouth, with a pair of scissors, the necessary portion of the organ is removed. The object in view is to excise the growth with three-quarters of an inch of

healthy tissue on each and every side. The resulting raw surface is obliterated by suturing the cut edges together.

Syme's Operation.—After making a vertical incision from the red margin of the lip to the point of the chin, in the middle line holes are bored on either side of the proposed line of bone section, which is half an inch to one side of the middle line. The mandible is now divided with a saw. After the tongue has been dealt with in the manner described in Whitehead's operation, the two halves of the jaw are united by silver wire passed through the drilled holes. Splitting the jaw gives good access to the floor of the mouth.

Kocher's operation consists of removal of the tongue through an incision under the jaw, enabling the glands of the submaxillary region to be extirpated at the same time.

The Cervical Glands in Relation to Treatment of Carcinoma of the Tongue.—Vital as is the early and adequate destruction of the primary growth, this is of little avail unless secondary deposits are ablated Long before secondary malignant cervical glands are palpable microscopical examination shows the presence of carcinoma cells. For secondary deposits in the neck treatment by radium is equivocal. Indeed, when the sufferer is comparatively hale, it is advisable to undertake a complete **block dissection of the neck** (p. 165) whenever possible. Immediately after the dissection, before closing the wound, radium needles can be implanted in the depths of the neck with a view to killing stray cancer cells possibly released from the divided lymphatics. In debilitated and old patients a block dissection of the neck is out of the question, and reliance must be placed in radium, which can be applied by external application, the needles being embedded in a collar of Columbia paste.

SARCOMA OF THE TONGUE

Sarcoma of the tongue is very rare, and almost invariably fatal. An example came under our observation. The patient was a man of 28, who complained of a lump in the left side of the tongue. Deep X-ray therapy caused the lump to disappear, and the glands of the left side of the neck were removed. Two months later enlarged glands appeared in the right side and a block dissection was carried out. A few months later sarcoma became widely disseminated, and death resulted.

CHAPTER IX

THE SALIVARY GLANDS

PAROTITIS

Acute Parotitis.—Acute inflammation of the parotid gland is now comparatively rare.

In the early days of abdominal surgery the importance of oral hygiene was not appreciated; furthermore, after laparotomy the patient was forbidden to drink for several days. These circumstances favoured an ascending infection from the parched infected mouth along Stenson's duct to the parotid gland, and *acute post-operative parotitis* became a frequent and dreaded complication of abdominal operations.

Acute parotitis is usually, but not necessarily a complication of some intercurrent debilitating disease, e.g. typhoid. In contradistinction to epidemic parotitis (mumps), only one parotid is affected as a rule, and suppuration is frequent (fig. 80). The causative organism is often a staphylococcus. Ascending infection from the mouth is usual, but metastatic suppurative parotitis undoubtedly occurs.

FIG. 80.—Acute parotitis.

Treatment.—If parotitis threatens, no effort should be spared to cleanse the mouth in order to prevent reinfection of the duct. Boroglycerol is a useful adjunct in this respect. A sialogogue, in the form of chewing-gum, is also valuable. W. Meyer has found that parotitis responds to artificial hyperæmia. This is induced by the patient wearing an elastic band

around his neck for ten hours per day, or even more. Such treatment is sometimes rewarded by resolution of the inflammation. If acute suppurative parotitis is suspected, it is important *not to wait for fluctuation*, for pus often lies deeply beneath the parotid fascia and gangrene may ensue.

If the symptoms do not abate quickly, if the swelling increases, if overlying tissues become œdematous, or the temperature becomes high, incision is indicated whether fluctuation can be obtained or not.

Operation.—If it is fairly certain that pus is present, a transverse incision should be made over the point of greatest prominence, having due regard to the situation of the branches of the facial nerve and Stenson's duct

In fulminating cases Blair's method should be used. An incision is made just in front of the ear from the zygoma to the angle of the jaw down to the capsule, and the flap forcibly drawn forward with retractors. In this way nearly the whole gland can be exposed. The capsule is then incised transversely. If pus does not flow, the gland can be explored at several points by inserting blunt forceps.

In rare cases where a parotid abscess bursts spontaneously, pus sometimes discharges through the external auditory meatus via an opening between the cartilaginous and bony ear.

Sub-acute and chronic parotitis are rather more common conditions. Inspection of the orifice of Stenson's duct while gentle pressure is exerted over the gland often causes a gush of purulent saliva to be ejected, and the diagnosis, which up to that time is often in doubt, becomes indisputable. Parotid calculus (p. 141) must be eliminated.

Treatment.—Cases which do not respond quickly to the usual remedies—oral hygiene and tonics—to which may be added artificial hyperæmia, are, in our experience, benefited, often dramatically, by catheterising Stenson's duct with a fine ureteric catheter and injecting a bland antiseptic fluid such as 1% mercurochrome.

SALIVARY CALCULI

Composition.—By chemical analysis it has been demonstrated that salivary calculi and the " tartar " which collects upon teeth are almost identical.

Submaxillary Salivary Calculi

The submaxillary salivary gland and Wharton's duct are the most common sites for a salivary calculus (fig. 81).

Indeed, they are more than fifty times more frequent here than in the parotid and its duct. These stones vary greatly

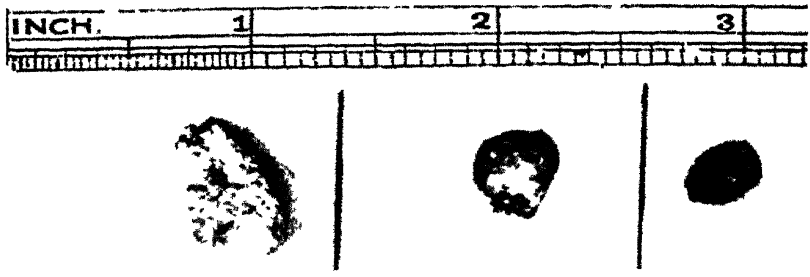

FIG. 81.—Typical examples of salivary calculi removed from Wharton's duct.

in size. One no larger than a millet seed may give rise to troublesome symptoms. At the other end of the scale relatively enormous ($1\frac{1}{2} \times 1$ in.) specimens have been recorded.

Clinical Features.—Males are three times more commonly affected than females.

A swelling in the submaxillary triangle is often a leading feature. Enlargement of the gland before or during meals is pathognomonic of the condition.

Salivary colic occurs typically at the commencement of a meal. The pain is often severe, and is described by the patient as "like tooth-ache." On this account he is liable to be referred to the dentist.

The patient complains of "something under the tongue."—When the offending object is a calculus it usually means that the stone is impacted in the ampulla of Wharton's duct, or is partially extruding therefrom.

FIG. 82.—Enlargement of the submaxillary salivary gland due to a calculus in Wharton's duct.

As a cause of lingual

neuralgia.—The lingual nerve passing to the tongue hooks around Wharton's duct. Consequently the pain caused by a stone is sometimes referred. The pain is described by the sufferer as "shooting down the side of the tongue."

Enlargement of the submaxillary gland (fig. 82) can often be seen in these cases when the patient sucks a lemon, and the orifice of Wharton's duct should be examined in a strong light, comparing the two sides. If the stone is in Wharton's duct it can be detected by direct palpation.



FIG. 83.—Radiograph of stone in Wharton's duct.

Radiology.—Submaxillary calculi, being rich in mineral salts, usually cast a good X-ray shadow (fig. 83), but their density varies. Stones, particularly in the gland itself, are sometimes difficult or impossible to demonstrate by X-rays.

Treatment.—A stone in Wharton's duct can be removed by slitting up the duct from within the mouth. This is better than incising over the stone, for unless the incision is exactly in the long axis of the duct a stricture is likely to follow.

For cases of calculi within the gland, extirpation of the submaxillary gland through an incision beneath the mandible is to be advised, and it will be found best to undertake the latter measure in all cases of recurrent submaxillary stones. The patient is in no way affected by the loss of one submaxillary salivary gland.

PAROTID CALCULI

Compared with submaxillary salivary calculi, parotid calculi are of great rarity. The symptoms are as one would expect—a painful swelling of the parotid gland at meal-times. The diagnosis of a small calculus may be difficult. An X-ray before and after sialography (see below) is helpful in this respect. The treatment is removal of the stone from within the mouth by slitting up Stenson's duct.

Salivary Fistula

A salivary fistula may be internal or external. As an internal fistula does not give rise to symptoms, and as external fistulæ of the submaxillary gland are both rare and readily cured by removal of that gland, the subject resolves itself into a consideration of that troublesome condition *external fistula of the parotid*.

Symptoms.—Every time the patient has a meal, smells, or even thinks of food, there is an outpouring of parotid secretion on to the cheek. Apart from the annoyance of such a phenomenon, the skin in the neighbourhood soon becomes excoriated. In addition, the patient experiences dryness of the mouth. These fistulæ usually follow a badly placed incision for a parotid abscess, but may be an aftermath of a penetrating wound.

Sialography is an important method of investigation. With a fine sterile ureteric catheter the punctum of Stenson's

Fig. 84A.—Sialogram in a case of chronic parotitis.

Fig. 84B.—Sialogram in a case of a parotid tumour.

duct is entered and the duct catheterised. A diluted solution of lipiodol can be injected easily through the catheter and an enlightening X-ray picture of the parotid tree is often obtained thereby (figs. 84 A and B). A sialogram will indicate also whether the main duct has been

severed, or if it is a ductule which is communicating with the surface.

Treatment.—A salivary fistula which has persisted for several weeks hardly ever closes spontaneously. From the information gained by sialography we can formulate the proper course to adopt :

1. *The Fistula is connected with a Ductule.*—Electro-cauterisation of the walls of the fistula, repeated if necessary, will result in its closure.

2. *The Fistula is connected with Stenson's Duct in front of the Anterior Border of the Masseter.*—The "twisted wire



FIG 85.—An operation for an external fistula of Stenson's duct in front of the masseter muscle. The wire is twisted on the mucous surface.

operation" usually is attended by good results. A piece of wire is placed as shown in fig. 85. The cutaneous edges are then freshened and firmly closed by sutures. The parotid saliva now finds its way into the mouth alongside this wire, and by the time the wire has cut out into the mouth the skin has united.

3. *The Fistula is connected with Stenson's Duct behind the Anterior Border of the Masseter.*—These are difficult cases. The following procedure is probably the best. From the bottom of the fistula a tenotome is driven obliquely so that the point penetrates the buccal mucosa half an inch in front of the masseter. A rubber tube is passed along this tract. After a week the skin edges are freshened and brought together, the tube, or rather a fresh one, being kept in place, this time only from the mucosa to beneath the united skin.

In very obstinate cases an endeavour is made to destroy the secreting activity of the gland. This can be partially or wholly achieved by the application of radium, or by avulsion of the auriculo-temporal nerve as it lies in front of the condyle of the jaw.

Mixed Tumour of the Salivary Glands

"Mixed parotid tumour" is a well-known clinical entity. A hard, somewhat rounded, slowly growing neoplasm, nearly always commencing in that part of the parotid gland overlying the angle of the jaw (fig. 86), renders the diagnosis tolerably simple. Usually benign for a varying period from several months up to ten or twenty years, it sooner or later breaks its confines, and exhibits characteristics of malignancy. It now tends to invade the upper part of the neck and the pterygoid fossa (fig. 87), and sometimes causes facial paralysis from involvement of the seventh nerve. When first seen in a comparatively advanced state it is difficult to diagnose from other malignant tumours of the region.

Fig. 86.—Mixed parotid tumour.

While, as its name implies, the tumour is usually of the parotid gland, mixed tumours of the submaxillary are not excessively rare, and there should not be that undue hesitation in diagnosing a mixed tumour in the latter situation which appertains at present. Cases of mixed tumour of the buccal[1] and palatal glands are also seen from time to time.

The varying histological characters of these tumours—they are found to contain from time to time fibrous, myxomatous, epithelial, and cartilaginous tissue—have brought them into much prominence, but unfortunately the fascination of hypothesising upon their origin, which is still un-

[1] These are sometimes called molar glands.

FIG. 87.—Mixed parotid tumour. Malignant recurrence two years after removal.

known, has tended to obscure necessary attention to the more important matter of treatment.

Treatment.—While it is true that a few cases remain benign for long periods, it is our experience that a larger proportion become malignant in a comparatively short time, and unless thorough enucleation is performed at an early period, recurrence often takes place. Recurrent and advanced cases seem to be little, if at all, improved by radium and X-rays, hence the importance of urging the patient to have the tumour extirpated while it is still encapsuled. Radon seeds or radium implanted into the tumour bed after early enucleation should help to improve the end results.

Mixed tumour of the *submaxillary gland* is satisfactorily treated by total removal of the gland.

Other tumours of the salivary glands are exceedingly rare, as may be judged by the fact that up to 1924 there were only 20 cases of carcinoma of the submaxillary salivary gland on record.

MIKULICZ'S DISEASE

All the salivary glands become enlarged and the lachrymal glands participate also (fig. 88). Mikulicz's disease is a rare condition, the cause of which is still



FIG. 88.—Mikulicz's disease. (Fisher.)

obscure. There is no pain, and the condition does not endanger life. X-ray treatment is sometimes beneficial. To minimise the deformity, the affected submaxillary glands can be removed, but the lachrymals, and particularly the parotid (danger to the seventh nerve), are better left alone.

CHAPTER X

THE NECK

Cut Throat

In more than half the cases of cut throat which reach surgical aid the wound does not involve any vital structure—only the skin, platysma, and perhaps the sternomastoid or other muscles are severed. Even the external jugular vein does not often come under the category of a vital structure in this respect The treatment of these superficial injuries follows elementary surgical principles

Serious Cases.—Self-inflicted wounds of the neck are usually perpetrated with the head extended, the wound being more or less transverse In this extended position the great vessels of the neck are protected by the sternomastoids and the larynx So it comes about that the great vessels of the neck are comparatively rarely injured, while the air passages bear the brunt

Treatment.—Attention is directed first to ligaturing bleeding vessels, secondly to dealing with the wounded air passage, and thirdly to the repair of other structures

In individual cases various moderate-sized arteries and veins will be found severed, and are ligated Hæmorrhage from an accessible branch of the external carotid is best dealt with by ligaturing that trunk near its origin It has been stated already that injury to the main vessels is comparatively rare, and when it occurs death usually supervenes before surgical aid is forthcoming

The principal sites of wounds of the air passages are indicated in fig 89.

Wounds above the Hyoid Bone —After cleaning up the area the wound is explored with a finger Quite often it will be found that the cavity of the mouth has been entered The epiglottis is often partially divided near its base This should be repaired with catgut

sutures. The mucosa of the pharynx is trimmed and united. The muscles are approximated in appropriate layers, and the wound closed with drainage.

Wounds of the Thyrohyoid Membrane.—Again the epiglottis is often damaged. The severed thyrohyoid membrane can usually be sutured. If there is respiratory distress, it is advisable to perform laryngotomy.

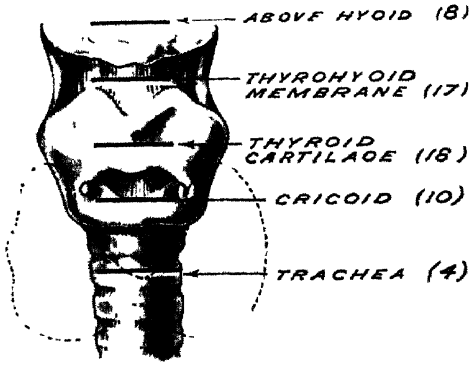

FIG. 89.—Position of the wound into the air passages of 57 cases of suicidal cut throat with a deep wound.

Division of the Thyroid Cartilage.—The thyroid cartilage can be repaired with sutures, providing these are not tied tightly, for a stitch through cartilage tends to cut out. Laryngotomy is usually indicated.

Wounds about the Cricoid Cartilage.—After the wound has been trimmed, a laryngotomy tube can be inserted via the artificial opening in the windpipe, and the tissues approximated around it.

Division of the Trachea.—Wounds of the trachea are comparatively rare. It is usually necessary to divide the thyroid isthmus between clamps, and it is often a good practice to pass a tracheotomy tube into the gaping trachea and proceed to repair the wound around the tube, as in wounds above the cricoid cartilage.

NERVES

It is remarkable how rarely important nerves are injured in self-inflicted wounds. In stab wounds any nerve may be involved. In one of our patients, a sailor, the most inaccessible nerve in the neck, the cervical sympathetic, was divided in this way, the assailant's weapon being a small penknife.

COMPLICATIONS OF CUT THROAT

1. **Loss of Blood.**—If the hæmorrhage has been severe, an immediate intravenous infusion of gum saline is necessary. Blood transfusion may be called for later.

2. **Infection of the Wound.**—This is not very frequent, but these wounds should always be drained, as they have been inflicted with a potentially infected instrument. Cellulitis sometimes supervenes, and this may spread to the mediastinum.

3. **Pneumonia.**—Pneumonia is a frequent and lethal complication, especially in those cases where the air passages have been opened.

4. **Stenosis of the Larynx or Trachea.**—Due to cicatrisation, it may necessitate permanent tracheotomy.

5. **Œsophageal Fistula.**—Œsophageal or pharyngeal fistula is a very rare occurrence, and it tends to heal spontaneously.

6. **Surgical emphysema** is another rare complication, and it usually occurs when a laryngotomy or tracheotomy tube has been omitted in the treatment of the case.

7. **Aerial Fistula.**—A persistent communication between the air passages and the exterior is likely to occur when there has been actual loss of substance of the larynx or trachea. In certain cases a plastic operation may be undertaken.

8. **Aphonia** may follow injury to the vocal cords, or division of the recurrent laryngeal nerve.

Cellulitis of the Neck

It is important to distinguish this condition from Ludwig's angina (see below). The cellulitis may be superficial or deep to the deep cervical fascia. The latter is rare, and requires very prompt incision, whereas the former is common, and its treatment follows that of cellulitis elsewhere.

The Woody Phlegmon of Réclus.—One side of the neck becomes swollen and extremely indurated ; the supple integument of the neck becomes like a hide. There may be pitting on pressure, and some erythematous blush in the overlying skin. Woody phlegmon, which is probably due to an infection by an attenuated staphylococcus, runs a chronic course, is almost painless, and produces little or no constitutional symptoms. The condition has to be distinguished from actinomycosis and advanced malignant disease.

Treatment by fomentations is followed by suitable incisions. Once a flow of pus has been established, the neck regains its suppleness and the condition clears up.

Ludwig's Angina

Ludwig described a clinical entity characterised by a brawny swelling of the submaxillary region combined with inflammatory œdema of the mouth. It is the *combined* cervical and intrabuccal signs which constitute the characteristic feature of the lesion (fig. 90).

Fig. 90.—Ludwig's angina. The brawny swelling beneath the jaw and the œdema of the floor of the mouth are characteristic features of the condition.

The essential pathology of the condition is virulent infection of the cellular tissues about the submaxillary salivary gland.

Course of the Disease.—Unless tension is relieved, certain cases rapidly assume a grave aspect. The swollen tongue is pushed towards the palate and forwards through the open mouth, while the cellulitis extends down the neck in that most dangerous plane—deep to the deep fascia. Only too often, within twelve to twenty-four hours, the patient's life is threatened or lost.

Peculiar Dangers of Ludwig's Angina.—We are confronted with infection of a fascial space walled in on all sides by dense fasciæ and muscles, a space where clinical experience and experimental injection demonstrate that inflammatory exudate can, and does, pass via the tunnel occupied by the stylohyoid to the submucosa of the glottis.

FIG. 91.—Incision for decompressing thoroughly the space beneath the mylohyoid muscle.

Treatment.—Early in the disease a deep incision is made along the middle two-thirds of a line joining the symphysis menti with the centre of the hyoid bone. It is probable that more thorough decompression of the space would reduce the mortality of the condition, which at the present time is about 30 per cent. More elaborate decompression is imperative when simple incision fails to give relief. An incision is made at the base of the submaxillary triangle following the lower border of the jaw (fig. 91). Often pus will be found under the mylohyoid muscle around the deep prolongation of the submaxillary gland.

Tracheotomy instruments should be at hand until the acute inflammation has subsided.

Cervical Lymphadenitis

Inflammation of the glands of the neck is exceedingly common, far commoner than any other group of lymphatic glands in the body. Infection occurs from the oral and nasal cavities, the ear, the scalp, or face, and the source of infection must be sought for systematically.

Acute Lymphadenitis.—The affected glands are enlarged and tender. The treatment, in the first instance, is directed to the focus of infection, the neck itself being simply protected by a bandage over wool. If pain continues or certain glands appear to be getting larger, fomentations are applied locally. Abscess formation calls for incision by Hilton's method.

Chronic Lymphadenitis.—In the early stages it is impossible to distinguish chronic tuberculous adenitis from chronic non-tuberculous adenitis, except by microscopical examination, but clinical experience shows that the chronically inflamed glands which do not resolve in the space of a few weeks are nearly always tuberculous.

Tuberculous Cervical Adenitis.—Usually one group of cervical glands are at first affected. Thus the patient presents himself with a lump in the upper jugular chain, the submaxillary region, or the supra-clavicular triangle, the first and second situations being exceedingly common. Rarely, there is widespread cervical glandular enlargement, and in these cases particularly, periadenitis or matting of the glands is in evidence.

When a tuberculous gland breaks down, the pus is at first confined by the deep cervical fascia. This soon becomes eroded at one point, and the pus flows through the small opening into that more commodious space beneath the superficial fascia. This is the stage of collar-stud abscess (figs. 92 and 93). Unless skilful treatment is adopted at once the skin will soon become reddened over the centre of the fluctuating swelling, and a discharging sinus, with its attendant evils, is at hand.

Differential Diagnosis

Tuberculous glands must be distinguished from—

1. *Hodgkin's Disease.*—The firm, perfectly discrete glands

of lymphadenoma usually render diagnosis possible. If the case is complicated by the fact that one group of glands are alone involved, a single gland should be removed under local anæsthesia and submitted to microscopical scrutiny.

2. *Lymphosarcoma* is uncommon, and resembles Hodgkin's disease. The remarks regarding microscopical confirmation of the diagnosis also apply here.

3. *Gummata.*—Gummata of lymphatic glands are rare. If there is no other

FIG. 92.—Tuberculous collar-stud abscess connected with the upper jugular lymphatic glands.



FIG. 93.—Diagram of a "collar-stud" abscess.

evidence of syphilis, the diagnosis is difficult. Absolute symmetry is a feature of the condition, and in such cases the Wassermann reaction should be taken.

Branchial cyst.—A branchial cyst is usually confused with a "collar-stud" abscess of the upper jugular chain (see p. 157).

TREATMENT OF TUBERCULOUS LYMPHADENITIS

The Importance of General Treatment.—Everyone is agreed that the patient should be put under the best hygienic conditions possible, the most important being sunlight. No matter what line of treatment is adopted, infected tonsils and carious teeth must receive appropriate attention; this is to be regarded as essential.

Operative Treatment.—In the majority of cases the tuberculous process is limited strictly to one group of glands.

For this type of tuberculous adenitis removal of the affected glands through an oblique incision following a crease of the neck gives rapid and eminently successful results. Even the presence of a collar-stud abscess does not jeopardise healing of the wound by first intention if the glands beneath the deep fascia are dissected carefully and completely, especially if the overlying skin is healthy.

When operative treatment is undertaken no effort should be spared to preserve:

The spinal accessory nerve;
The mandibular branch of the facial nerve;
The hypoglossal nerve;

which are the nerves above all others most likely to be injured.

Contra-indications to Operative Treatment.—When there is active tuberculosis of another system, e.g. pulmonary tuberculosis, removal of tuberculous glands of the neck is, of course, not logical. In cases where enlarged glands are not confined to one region of the neck, where there is much periadenitis or many discharging sinuses, operative treatment is best avoided, at any rate for several months, during which time heliotherapy, if possible in a solarium, is advised.

Repeated aspiration of a collar-stud abscess cannot be recommended unless the patient is under constant supervision under ideal conditions.

From time to time tuberculin, X-rays, and heliotherapy are advocated for all cases, to the entire exclusion of surgery. We consider the best results are obtained from heliotherapy plus surgery in selected cases, as indicated above.

Actinomycosis of the Neck

Two-thirds of all human cases of actinomycosis occur in the neck and face. There is increasing evidence that the ray fungus gains entrance through a wound of the buccal mucosa, particularly after tooth extraction. A sinus or sinuses about the upper part of the neck, particularly indurated sinuses, should arouse suspicion immediately (fig. 94). The skin about the sinus may appear somewhat blue and mottled. On palpation each burrow feels hard, like a strand of whipcord. Usually enlarged glands are absent. There is no pain unless the disease is advanced and nerves

become implicated in fibrous tissue. As the disease progresses the patient becomes increasingly anæmic. The discharge is thin and watery. Finding the characteristic "sulphur granules" in this discharge is the key to the diagnosis.

FIG. 94. Actinomycosis. Indurated sinuses extend from the mandible into the neck.

Modes of Spread.—The disease spreads by direct continuity. It burrows upwards towards the scalp and downwards into the supraclavicular region, when the mediastinum is endangered. Spread by the lymphatic stream is practically unknown, and it is truly remarkable that this favourite channel for the dissemination of all other infective processes should enjoy such a degree of immunity in the case of the ray fungus. Late in the course of the disease blood-borne metastases are not very rare, the liver and the brain being the two regions most commonly invaded in this way. Untreated, the disease runs a rather chronic but surely fatal course. To recognise it early is to be enabled to cure it regularly.

Treatment.—The dental surgeon attends to carious teeth, erring on the side of extraction rather than repair. Forty-eight hours later the surgeon lays open the sinuses along their course, and packs with narrow strips of gauze soaked in iodine.

Intensive iodine therapy is then commenced. Thrice daily the patient drinks half a pint of iodised milk prepared in the following way: 5 drops of fresh 2 per cent. tincture of iodine are stirred into a cupful of milk to which, if possible, a tea-

spoonful of cream has been added. The iodine forms a colourless organic compound with the cream. The dose is gradually increased until 10 minims are taken t.d.s. Under this regime the sinuses heal, except in a few very long-standing cases, where in addition the application of radium is said to be beneficial.

FIG. 95.—Fœtus, showing branchial grooves and arches.

ANOMALIES OF THE BRANCHIAL APPARATUS

In a fœtus approximately thirty-five days old, four grooves can be seen in the side of the neck. These are the branchial clefts, and the intervening bars are the branchial arches (fig. 95). The clefts in human embryos are, more correctly speaking, grooves—grooves on the outside and on the pharynx separated by a layer of mesoblast. The first cleft persists as the external auditory meatus, the second, third, and fourth clefts normally disappear. The whole, or a portion of one of these vestigial structures, may persist and give rise to one of the following anomalies:

BRANCHIAL FISTULA

Branchial fistulæ may be unilateral or bilateral. The orifice of the fistula is nearly always to be found in the lower third of the neck near the anterior border of the sternomastoid (fig. 96). Branchial fistulæ are lined by columnar ciliated epithelium, discharge mucus, and are often the seat of recurrent attacks of inflammation. When complete the internal orifice of the fistula often opens into the posterior tonsillar recess (fossa of Rosenmüller). More usually the tract is incomplete and ends blindly in the region of the lateral pharyngeal wall. The extent of the fistula can be determined by injecting lipiodol followed by a radiograph.

Treatment.—Branchial fistulæ should be removed completely by dissection. In fistulæ without an internal opening dissection is facilitated by inserting a subcutaneous ligature about the external orifice prior to the lipiodol injection. After the X-ray examination, which determines the extent of the fistula, the pent-up lipiodol serves to distend the tract during the operation which follows immediately; the distended tract is more easily followed in the depth of the wound.

FIG. 96.—Bilateral branchial fistulæ; left side inflamed.

BRANCHIAL CARTILAGE

A small, elongated piece of cartilage connected to the deep surface of a cutaneous dimple in the position of an external orifice of a branchial fistula is occasionally met with. The patient usually finds it accidentally, and thinks that it is a foreign body.

CERVICAL AURICLE

So named because of its morphological significance, this cutaneous projection is almost invariably found in the position of the external orifice of a fistula (fig. 97). Cervical auricles were common in the days of the Romans, and are represented in some of the statuary of that period.

FIG. 97.—Cervical auricle.

BRANCHIAL CYST

This is the most common and most important of these vestigial

anomalies. The cyst usually makes its first appearance between the twentieth and twenty-fifth years, but may be postponed until the patient is over 50. Its position is very constant, viz. in the upper third of the neck beneath the upper third of the sternomastoid, protruding around its anterior border (fig. 98). Nearly always lined by squamous epithelium, its contents bear a striking resemblance to tuberculous pus. If, however, a few drops of branchial fluid are examined in a fresh state under the microscope with a one-sixth power lens, an abundance of cholesterol crystals (fig. 99) can often be seen.

FIG. 98.—Typical branchial cyst

There is a rare variety of branchial cyst in close relation to the pharynx, lined by columnar epithelium, and filled with mucus. Small cysts of the latter type are sometimes found at necropsy, having given rise to no symptoms during life.

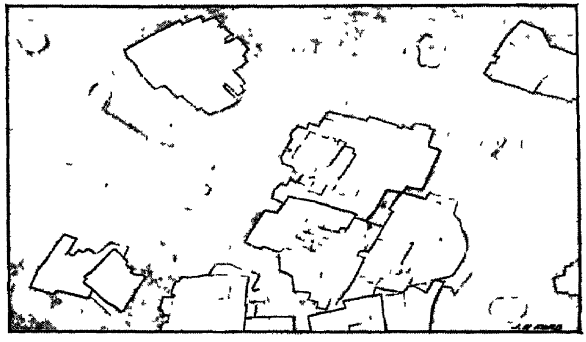

FIG. 99.—Branchial fluid. Note the abundance of cholesterol crystals.

BRANCHIOGENETIC CARCINOMA

Branchiogenetic carcinoma undoubtedly occurs, but such a diagnosis is unjustifiable until every possible source of a primary growth in the mouth, pharynx, and external auditory meatus has been scrutinised with a negative result (p. 162).

CERVICAL RIB

Extra ribs usually spring from the seventh cervical vertebra (fig. 100). They are more common in women, to some extent familial, and are bilateral more often than unilateral. Cervical ribs are quite often discovered

unexpectedly during an X-ray examination, and it is quite certain they can be present throughout a long lifetime without giving rise to symptoms. At other times symptoms pointing to cervical rib cannot be confirmed by a radiograph. In such cases it is necessary to X-ray the whole thoracic spine, and to ascertain if there are twelve or thirteen pairs of ribs present.

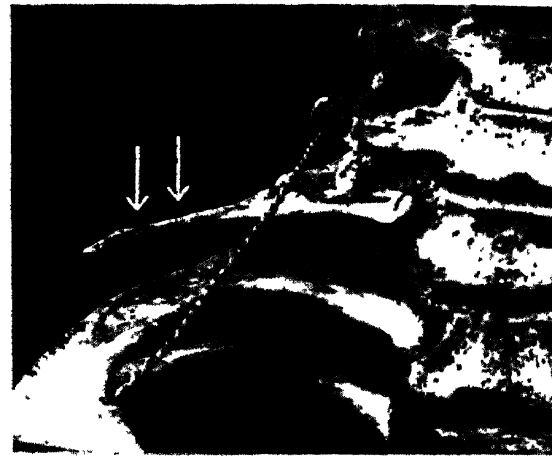

FIG. 100.—Cervical rib. (R.C.S. Osteological Collection 70.1.)

Five main varieties of cervical rib exist (fig. 101):

(*a*) A complete rib articulating anteriorly with the manubrium.

(*b*) A rib ending in a tapering point, which is connected by a fibrous band to the scalene tubercle of the first rib.

(*c*) A fibrous band alone is present. This variety, of course, cannot be demonstrated by X-rays.

(*d*) The free end of rib expands into a large bony mass.

(*e*) The whole series of ribs is "prefixed," that is, each articulates with one vertebra higher than normal. In this variety symptoms are produced by the normal first rib.

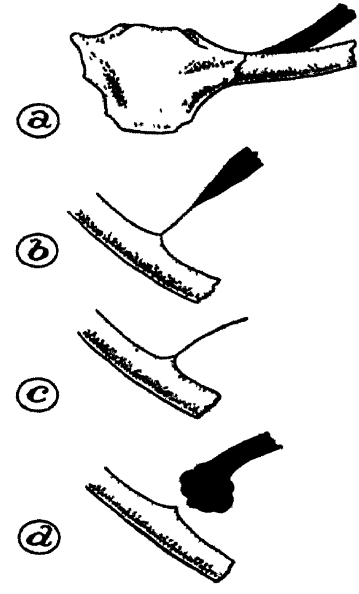

FIG. 101.—Diagram of the main varieties of cervical rib. (For explanation see text.)

Symptoms.—Symptoms usually come on in early or middle adult life, and are no doubt due to sagging of the musculature of the shoulder girdle. Some temporary relief is effected by bracing the shoulders.

The symptoms may be divided into two categories. Usually one set alone is in evidence:

1. *Nerve Pressure Symptoms.*—These are due to angulation of the first dorsal nerve by the abnormal rib. They are divided into sensory and motor.

Sensory.—There is pain, tingling, or numbness over the ulnar border of the forearm. Temporarily relieved by elevation of the arm.

Motor.—The muscles of the thenar eminence are first affected, and wasting is often limited to the abductor and opponens pollicis, a distribution which is in contrast to progressive muscular atrophy. In long-standing cases a claw hand can result.

2. *Vascular symptoms* are those of increasing circulatory impairment in the affected limb, and eventually this may go on to gangrene. When gangrene develops the index finger is maximally affected. Formerly these vascular symptoms were attributed to kinking and compression of the subclavian artery by an abnormal rib. Telford (1931) has shown that such a view is absurd, for even in the elderly, ligature of the subclavian artery is not followed by gangrene. The vascular symptoms are no doubt due to pressure-irritation by the rib on sympathetic nerve fibres going to supply the brachial artery and the arteries of the forearm. These sympathetic nerve fibres form an isolated bundle between the plexus and the bone. The symptoms are quickly and permanently relieved by removal of the rib. If a patient presents vascular symptoms with no X-ray evidence of cervical rib, a normal first rib may be the cause (Telford).

Treatment of Cervical Rib with Symptoms.—The rib should be excised, together with its periosteum. If necessary, the operation can be done under local anæsthesia. There are two main avenues of approach:

The Anterior Route (Stiles's incision, fig. 102).—The approach is

through an L-shaped incision. The vertical limb follows the lower third of the posterior border of the sternomastoid. The horizontal passes outward along the base of the supraclavicular

Fig. 102. Stiles's incision.

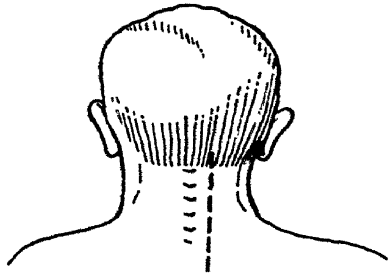

Fig. 103. -Bankart's incision.

triangle. Division of the scalenus anticus near its insertion helps to make the deeper dissection less difficult.

The Posterior Route (Bankart's incision, fig. 103).—With the patient prone, a vertical incision is made through the back of the neck 1 in. lateral to the spinous processes. The muscles are separated until the seventh cervical transverse process is isolated. This is removed. The neck of the cervical rib is divided, and the rib is removed by dissection from behind downwards. This approach has two advantages: (1) the scar, being at the back of the neck, is inconspicuous; (2) the most fixed portion of the rib being freed at the commencement, it is easier to dissect out the mobile rib.

Sternomastoid Tumour

Formerly this swelling was incorrectly considered to be a hæmatoma. The lump is not present at birth, and is usually noticed about the third week of life (fig. 104). Histologically it is composed of white fibrous tissue, and Middleton has shown that it arises on account of thrombosis of certain of the veins draining the sternomastoid. This thrombosis is the direct result of injury to the infant's neck during parturition, and a history of difficult labour is nearly always obtainable in these cases.

Fig. 104.—Sternomastoid tumour

Treatment.—There is no immediate treatment ; the lump gradually disappears, but the clinician has an important duty, and that is to warn the parents that the child will probably need an operation for the correction of torticollis at the age of 4. Although manipulation can be tried in order to avoid the necessity for this operation, sternomastoid tumour is a precursor of torticollis. Taken in time, the handicapping deformity and facial asymmetry which follows neglected torticollis can be prevented.

Cystic Hygroma

Cystic hygroma is a condition practically confined to infants (fig. 105). Unnoticed at birth, the swelling usually attracts attention during the first or second year of life. The swelling is translucent, multilocular, and often occurs in the supraclavicular region, but it may invade the axilla. Cystic hygromata are subject to recurrent attacks of inflammation, which subside under expectant treatment, and sometimes result in the disappearance of the tumour. The diagnosis presents no difficulty, for these cysts are translucent.

Fig. 105.—Cystic hygroma. The swelling is brilliantly translucent.

Treatment.—Rapid enlargement is a contraindication to operation. Left alone, when the swelling reaches a certain size it bursts subcutaneously and may disappear in a short time, perhaps in forty-eight hours. When a hygroma remains stationary in size and is circumscribed, complete excision can be undertaken with good results.

In large tumours which are not coming "to a head," treatment by X-rays should be tried. Owing to the multilocular nature of the swelling treatment by injection is out of place.

SOLITARY LYMPH CYST

is a condition akin to the foregoing, but unlike it, it is nearly always first seen in adult life. As its name implies, it is a single cyst filled with lymph, and it is usually found in the supraclavicular triangle.

Treatment by excision is eminently satisfactory.

DEEP CAVERNOUS HEMANGIOMA OF THE NECK

Like lymphatic cysts, haemangiomata can be emptied by pressure, but of course are non-translucent.

Excision may be a difficult and dangerous undertaking. Porter's treatment (injecting boiling water into the veins) and kindred measures are not very satisfactory.

PHARANGEAL POUCH

When large, a pharangeal pouch causes a swelling in the lower part of the neck, usually on the left side. Pharangeal pouch is discussed in the chapter on the pharynx, p. 194.

Malignant Glands of the Neck

Malignant disease in the neck is only too common. In the majority of instances it is secondary to carcinoma elsewhere, particularly the buccal cavity. When a patient presents himself with a cervical glandular enlargement which is suspiciously indurated a search for a primary growth should commence. Among the sites which are likely to be overlooked are the extra-laryngeal recesses, the external auditory meatus, and the testicle.

Fig. 106.—Ptosis, ophthalmoplegia, and a mass of secondary malignant glands of the neck signifies the primary growth lies in the ethmoid.

Sometimes the primary growth lies buried in the depths of the naso-pharynx. *Carcinoma of the ethmoid* is a case in point. By the time the glands of the neck are involved the primary growth has usually invaded the sphenoidal fissure and impleated the nerves which pass through that fissure (fig. 106).

When the lump in question is undoubtedly malignant, but in spite of a thorough search, no primary can be discovered, the possibility of *branchiogenetic carcinoma* (p. 157) can be entertained. In early favourable cases the primary neoplasm is encapsulated and can be totally removed by dissection.

Carotid Body Tumour

The carotid body, situated at the bifurcation of the carotid artery, is a moiety of the chromaffin system. Tumours thereof

are usually classified as endotheliomata. They are rare and difficult to diagnose. Clinically there are two types :

(*a*) 80 per cent. remain benign for many years, slowly increase in size (fig. 107), but eventually take on a malignant change. They are usually noticed first during adult life, although the youngest recorded case was at 7 years (Bevan). The mass is movable, and as it enlarges it takes on transmitted pulsation from the carotid artery.

FIG. 107.—Tumour of carotid body. (O'Shaughnessy.)

(*b*) 20 per cent. are malignant from the commencement. This variety gives rise to an irregular, very hard lump, and it was called by Sir Jonathan Hutchinson "the potato tumour."

Treatment is removal by dissection. If the growth cannot be separated from the fork of the carotid artery it is questionable whether it is justifiable to proceed in an elderly patient, for ligature of the common carotid artery in a patient past the meridian of life is often fatal. Some success has been recorded with radium and X-rays.

HODGKIN'S DISEASE (*syn.* LYMPHADENOMA)

The pathology of this condition, which was described by Hodgkin in 1832, is still unknown. Because it so often commences in the glands of the neck and behaves like a malignant process, it is necessary to include it here (see also p. 96).

Clinical features have been summarised piquantly as

discrete enlargement of lymphatic glands (fig. 108), a tendency to hæmorrhage, and a bad prognosis. It usually attacks young adults, especially males. The cervical lymphatic glands are not necessarily the first to become enlarged, and the glands of the axilla and groin must be examined in all cases. Later the spleen is involved (hard-bake spleen). The enlargements are progressive, though temporary remissions occur. A severe secondary anæmia accompanies the disease. The early diagnosis can only be made conclusively by removing an enlarged gland and submitting it to histological examination.

FIG. 108. Lymphadenoma (A. Edmunds).

Treatment.—In early cases when the disease is confined to one group of glands an attempt to eradicate by excision is justified. X-ray treatment should always follow, and this is the only hope in later cases. Radium has been tried, but without much success.

LYMPHOSARCOMA (see also p. 55)

Again the neck is a common site for this fortunately rare condition. It usually appears as a rapidly growing tumour. In its early stages the affected glands are discrete and movable, but soon it spreads beyond the confines of the gland capsules (fig. 109) and infiltrates surrounding structures. So rapid is the cellular activity that it is sometimes difficult to differentiate between subacute lymphadenitis and lymphosarcoma. In such cases the centre of the tumour softens, and ultimately the skin gives way, producing deep sloughing ulcers which bleed freely.

FIG. 109. Lymphosarcoma. (A. Edmunds.)

Treatment.—The remarks concerning the treatment of Hodgkin's disease apply to lymphosarcoma.

BLOCK DISSECTION OF THE NECK (CRILE'S METHOD)

A wide excision of lymphatic glands of the neck is indicated in order to eradicate a malignant process. The operation is

usually undertaken in conjunction with removal of a primary growth, e.g. carcinoma of the tongue.

A wide incision, such as that shown in fig. 110, is used. The skin flaps having been dissected up, the sternomastoid is divided about 1 in. above the clavicle. The muscle is freed and retracted upwards. Next the internal jugular vein is divided between ligatures low down in the neck. The dissection proceeds upwards methodically and the fascia, fat, lymphatic glands, the internal jugular vein, together with the submaxillary salivary gland, are dissected *en bloc*. Attention must be directed to clearing that space between the parotid and great vessels, and also the submental triangle between the genio-hyoglossi, for it is in these areas that a lymphatic gland can be easily overlooked. Bleeding vessels are ligatured as they occur. When completed the carotid artery is laid bare, and lying with it is the vagus nerve which has been preserved carefully. The operation aims at removing the whole of the lymphatic-bearing tissues on the affected side of the neck. Radium needles can be implanted in the depths of the neck with a view to killing stray cancer cells possibly released from the divided lymphatics. The skin flaps are approximated and the wound drained. There is comparatively little shock and when the wound has healed surprisingly little deformity follows this extensive dissection.

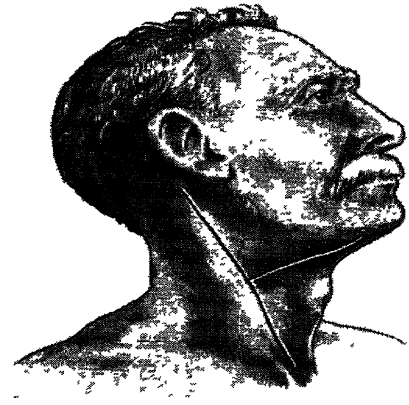

FIG. 110.—An incision for block dissection of the neck.

SURGERY OF THE THORACIC DUCT

Wounds of the thoracic duct are rare, and occur usually during the dissection of glands in the supraclavicular region. When the accident is not recognised at the time, chyle pours from the wound, as much as two or three pints in twenty-four hours and, as a result, the patient wastes. If an excessive serous discharge from a wound in this region makes it probable that the thoracic duct or a main branch thereof has been divided, a feed of cream will settle the diagnosis, for, after its ingestion, the clear fluid becomes opaque.

Treatment.—If the accident is recognised at the time, an endeavour to restore the continuity of the duct is made. Failing this, its proximal end has been implanted into a vein successfully. Ligature of the duct is not necessarily harmful, for there are many anastomotic channels; nevertheless, in the present state of our knowledge, ligature should be avoided, if possible.

In later cases, when attention is drawn to the injury by chylorrhœa, firm pressure by a pad and bandage may be tried, and this simple expedient is sometimes successful. More often it fails, and the wound must be reopened. If the patient is given cream to

drink an hour before the operation, there is no difficulty in finding the cut thoracic duct, which is about the size of a straw, and an immediate external relation to the last 1½ in. of the left internal jugular vein. In a case of ours, serious chylorrhœa commenced again four days after ligature of the duct. The wound was reopened and firmly packed with gauze moistened with flavine. Repacking was adopted every other day until the wound granulated. This method proved successful.

Temporary drainage of the thoracic duct was recommended as an adjuvant to the treatment of general peritonitis a few years ago, but the method has been abandoned.

CHAPTER XI

THE THYROID GLAND AND THYROGLOSSAL DUCT. THE PARATHYROIDS AND THYMUS

THE thyroid gland is developed mainly, if not entirely, from the thyroglossal duct. The lateral pouches of the third and fourth branchial clefts give origin to the parathyroids and thymus.

Ectopic and Aberrant Thyroids.—The whole thyroid gland may be situated in some part of the thyroglossal tract, **lingual goitre** being the commonest of these abnormalities (fig. 112). Here the thyroid

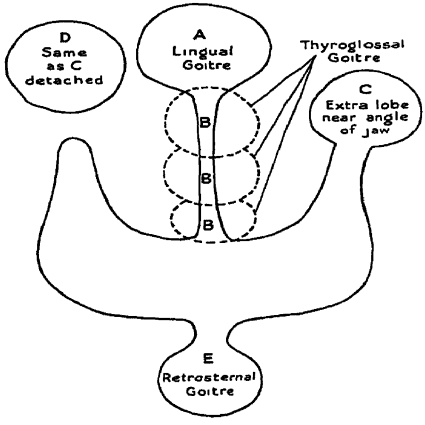

FIG. 111.—Ectopic and aberrant thyroids. A and B are ectopic thyroids, C, D, and E are aberrant thyroids.

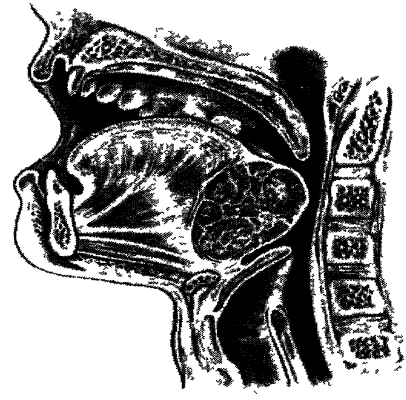

FIG. 112.—Lingual thyroid (after Mayo).

gland gives rise to a rounded swelling at the back of the tongue beneath the foramen cæcum. Other abnormalities are represented in fig. 111. Removal of a lingual goitre is often followed by myxœdema, for the abnormally situated gland is the only thyroid present. To obviate this sequel it has been recommended that some portion of the excised gland should be grafted, for instance into the medulla of the tibia.

Before studying diseases of the normally placed thyroid gland it is well to tune up, as it were, by tabulating the conditions which we must consider :

Deficient Secretion .	Cretinism. Myxoedema.
Simple Goitre . .	Colloid goitre of puberty. Adeno-parenchymatous goitre
Thyrotoxic Goitre .	Primary Graves's disease. Secondary Graves's disease.
Neoplasms . .	Benign. Malignant.
Inflammations .	Acute. Chronic.

Inflammations are put last purposely because of their rarity and comparative unimportance.

FIG. 113 —An infant cretin Note the protruding tongue (De Quervain.)

FIG. 114 —A cretin girl aged 22 (J Thomson.)

CRETINISM (INFANTILE HYPOTHYROIDISM)

In this country cretinism is sporadic. It appears in healthy families, the other children being normal and the mother presenting no thyroid aberration. The condition is due to absence of the thyroid gland, or to its complete, or

almost complete, destruction *in utero*. Cretinism as exhibited in *adolescent and adult life* (fig. 114) can hardly be mistaken. The patient is a dwarf; the skin is dry, redundant, and wrinkled; pads of fat are often found in the supraclavicular region. The cretin's mentality is usually below normal, but not necessarily so. *In early infancy* (fig. 113), when it is so necessary to diagnose the condition if it is to be remedied, it is easily overlooked. The principal features at this time are a protuberant tongue and a listless infant who seldom cries and is disinclined to take nourishment. The face is pale, puffy, and somewhat wrinkled. The child snores when asleep. On examination the hands seem thick and short. The anterior fontanelle is widely open. The temperature is subnormal, and, what is most important, the rings of the trachea can be palpated easily.

Treatment consists in administering some preparation of thyroid—$\frac{1}{16}$ to $\frac{1}{8}$ of a lobe of fresh sheep's thyroid gland finely chopped twice per week cannot be bettered; 1 to $2\frac{1}{2}$ grains of gland extract (Burroughs Wellcome & Co.) twice per week, increasing the dose as necessary, gives good results. Medical supervision is necessary throughout life, for the patient must always take a correct amount of thyroid extract.

FIG. 115—Facies of myxœdema. Plaster cast. (R.C.S. 7140.8)

MYXŒDEMA (HYPOTHYROIDISM IN THE ADULT)

Myxœdema commonly arises idiopathically, but the same train of symptoms follow extirpation of too much of the thyroid gland. The idiopathic form usually affects women between 30 and 45. Its onset is slow, and the patient becomes mentally and physically

inert. She puts on weight, but the fat has abnormal distribution; for instance, there is often a "hump" over the seventh cervical and first dorsal vertebræ. The breasts themselves do not enlarge, but there are deposits immediately below them. The facies coarsens (fig. 115), and the complexion becomes sallow. Much of the hair falls out, and that which remains is dry, lustreless, and prematurely grey. On palpation the skeletal muscles seem hard, and the mucin-laden subcutaneous tissues feel adherent to them. The symptoms can be completely ameliorated by appropriate and continued doses of thyroid extract.

Colloid Goitre of Puberty (*syn.* Adolescent Goitre)

Although usually a simple and transient affection, adolescent goitre is of surgical interest for two reasons: (1) it occasionally persists and gives rise to thyrotoxic symptoms at about 40 years of age (see p. 177); (2) many adults with adeno-parenchymatous goitre give a history of enlargement starting at puberty.

Fig. 116. A large colloid goitre of puberty.

Symptoms.—The only symptom is the swelling in the neck. Girls are more frequently affected than boys. The thyroid is evenly enlarged and comparatively soft to the touch. Sometimes the deformity is considerable (fig. 116). Usually the enlargement gradually subsides, and has all but disappeared by the twentieth to twenty-second years.

Treatment.—The adoption of hygienic measures, the elimination of septic foci, and the administration of a harmless iodine preparation, such as Syr. Ferri Iod. ʒj t.d.s., is all that is necessary. The use of thyroid extract and Lugol's solution is discouraged, for not a few examples of Graves's

disease have been produced by their exhibition in these cases.

ADENO-PARENCHYMATOUS GOITRE (*syn.* ENDEMIC GOITRE)

The principal regions in which endemic goitre occurs are the great watersheds — the valleys of the Alps and Pyrenees, the Himalayas, the Andes, and the Rocky Mountains. The term "Derbyshire neck" is familiar in England. Dwellers near the sea are relatively immune. The condition is in some way related to an iodine deficiency in food and water. Its ætiology is still unknown. There are three main theories .

FIG. 117.—Adeno-parenchymatous goitre.

The Earth and Water Theory (Kocher).—Ascribes the origin to chemical substances in the water which are dependent upon the geological character of the soil through which the water percolates.

The Toxic-infective Theory (McCarrison).—Assumes the existence of specific intestinal flora, the toxic products of which exert their mischief on the thyroid gland.

The Theory of Iodine Deficiency.—That the condition is due to a deficiency of iodine in food and water.

There is a tendency at present to combine the last two theories. It is suggested that, although there may be an adequate amount of iodine in the food and water, the iodine is rendered unassimilable by the presence of specific intestinal flora.

FIG. 118.—An enormous cystic goitre in an infant. The child died on the third day. A rare, but interesting specimen. (R.C.S. 1544.1.)

Clinical Features. — The deformity of the neck produced by the goitre is the leading complaint (fig. 117). The gland is enlarged, often asymmetrically. In a young subject, to the palpating fingers the surface of the thyroid feels firmly elastic

and tolerably even; as years advance it becomes hard and nodular, due to an increase in fibrous tissue and to the formation of false adenomata (fig. 119).

Pressure upon the trachea may develop. When the goitre is mainly unilateral the degree of tracheal displacement is sometimes fantastic. Nevertheless, it is not so much this type which produces dyspnœa as the bilateral, deep, but not necessarily seemingly great, enlargement. Here the continuous compression of the sides of the trachea decreases its transverse diameter, and if unrelieved a time comes when this portion of the airway is but a mere antero-posterior slit. Specimens showing advanced tracheal compression are much favoured in pathological museums, and are known as "scabbard" trachea.

FIG. 119. Section (macroscopic) of an adeno parenchymatous goitre. (De Quervain.)

Treatment.—*Prevention.* In communities where the disease is common, the provision of a pure water supply and of table salt containing iodine[1] to school-children has reduced the total number of cases. Kocher's advice to "boil all water" applies forcibly to goitrous country districts. The progress of the disease is said to be arrested by the administration of thymol and other intestinal antiseptics.

Surgical treatment is advised when there is much deformity or symptoms of dyspnœa are in evidence. In the latter a good radiograph is most helpful in showing the amount of

[1] *Warning.*—As will be shown presently, iodine, especially in the form of Lugol's solution, is extremely useful in toxic goitres. It is, however, sometimes dangerous in non-toxic goitres. It has the peculiar property of turning a non-toxic goitre into a toxic goitre.

tracheal displacement. The gland is exposed freely by a collar incision and a wedge ("melon slice") resection (fig. 120) is performed on each lobe enucleating any of the larger pseudo-adenomata encountered. Hæmostasis is accomplished and the lobes reconstituted by a continuous suture approximating the cut edges.

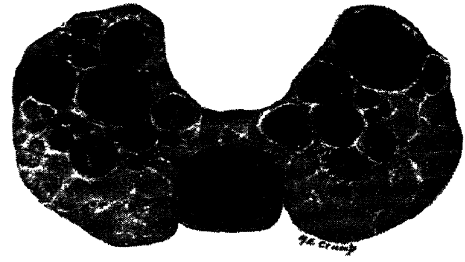

FIG 120.—"Melon slice" or wedge resection of the thyroid.

THYROTOXIC GOITRE

Although many of the symptoms of thyrotoxic goitre may be produced by excessive doses of thyroid extract, the disease is probably due to an abnormal rather than to an excessive normal secretion. As has been shown on p. 168 there are two conditions to be considered under this heading, namely: Primary and Secondary Graves's Disease.

PRIMARY GRAVES'S DISEASE (*syn.* EXOPHTHALMIC GOITRE)

The symptoms often appear in the third and fourth decades of life, but may occur earlier or later. Females are affected six times more often than males. The onset in a large number of instances dates from a crisis in the patient's life—a mental shock, pregnancy, or some intercurrent illness. The disease progresses by acute exacerbations and remissions. It is well to remember that the exophthalmos or the goitre may be absent, but seldom both. Curiously, the associated exophthalmos is sometimes mainly or entirely unilateral; in a typical case the protuberant eyeballs giving a startled look are unmistakable (fig. 121).

FIG. 121 —Primary Graves's disease (T P. Dunhill.)

The thyroid gland is enlarged evenly, and a "thyroid thrill" is obtained readily. The patient wastes, and is subject to attacks of diarrhœa. Muscular weakness progresses as the

disease advances, and this applies to the myocardium as well as to the skeletal musculature.

Cardiovascular Disturbance.—Tachycardia is a leading symptom. In an acute exacerbation the pulse is very rapid. The blood-pressure is usually raised, and the slightest excitement accentuates the circulatory turmoil. Eventually the heart weakens, and auricular fibrillation is a frequent accompaniment of advanced cases.

Nervous Symptoms.—The patient is restless and highly strung. The extended hands shake, and the protruded tongue is tremulous. Insomnia is the rule, and hysterical weeping without provocation is one of the least of many mental abnormalities which may complicate the situation.

Metabolic Changes.—Metabolic activity is raised. The skin is warm and moist. The temperature during a crisis is slightly above normal.

Treatment.—While it cannot be said that there is yet uniform agreement, the majority of physicians entertain the advisability of partial thyroidectomy when medical treatment has failed after six months, or when the patient relapses soon after apparent improvement. Opinions regarding the value of X-ray treatment are very varied, but it may be tried in conjunction with the medical regime. The results of surgical treatment are exceedingly good if sufficient thyroid tissue is removed, and a notable decrease in operative mortality has come about during the past few years. The latter is largely due to :

1. Adequate pre-operative rest and preparation.
2. Pre-operative administration of Lugol's solution.
3. Local anæsthesia.
4. Refraining from operating during hot weather, as far as it is possible.

Operative Treatment.—*Pre-operative Regime.*—The patient should be confined to bed for at least three weeks before operation. A light, almost vegetarian diet with copious fluids is prescribed. Nervous symptoms are benefited by sedatives, Luminal gr. ½ b.d. being useful in this respect. Lugol's solution ♏x is given three times per day.

Lugol's Solution.—In 1920 Dr. Plummer showed the great importance of pre-operative administration of Lugol's solution, which causes the thyroid to store temporarily its perverted secretion. Lugol's solution is 5 per cent. of iodine dissolved in 10 per cent.

potassium iodide. In an average case 10 minims are given t.d.s. for ten days before the operation, when its maximal effect is reached. In the crises of Graves's disease as much as 50 minims are prescribed. Lugol's solution is best given in milk or orange juice, either of which masks its taste and colour. It should be noted that Lugol's solution does not cure Graves's disease. Its effect is temporary, and if it is administered for a long period this beneficial effect is lost.

CRILE'S METHOD OF "STEALING" THE THYROID

This is a method which is successfully employed by many surgeons. All knowledge of the day of the operation is kept from the patient. A bandage is placed around the neck when she first enters hospital. During the last days of the preparatory period the hypnotic, or a small percentage of it, is given hypodermically each morning, just as though the patient was being prepared for the theatre.

Preliminary Ligature of the Superior Thyroid Arteries.—In very toxic cases operative measures are occasionally first confined to ligature of the superior thyroid arteries. After these arteries, the main blood-supply to the gland, have been tied there is often considerable, but temporary, improvement. Modern pre-operative treatment has rendered this step an unusual procedure.

The Operation.—A suitable dose of morphia is given to render the patient tranquil. Local anæsthesia in the form of ½ or 1 per cent. novocaine is injected so that the whole of the front of the neck from the hyoid to the manubrium is infiltrated. Some operators employ avertin or gas and oxygen in addition, but the tendency is more and more to rely upon local anæsthesia entirely. The well-known collar incision is made, and this flap is dissected up to the level of the hyoid. A vertical median incision is now made through the infiltrated fascio-muscular planes from the hyoid bone to Burns's space. By suitable retraction it is possible to expose the lateral lobes. Only occasionally, when the goitre is large, is it necessary to divide the pretracheal muscles. Commencing usually on the right side, the superior pole is freed and the superior thyroid vessels ligatured. The middle and inferior thyroid veins are then secured and divided After suitable dissection the lobe can be delivered into the wound. A special dissection for the inferior thyroid artery is now seldom employed. When all is in readiness the portion, about two-thirds to seven-eighths of one lateral lobe, is resected (fig. 122). The cut surfaces of the stump, which it should be noted protects the parathyroids and recurrent laryngeal nerve, is whipped over with a running suture.

Providing the patient's condition remains good, subtotal lobectomy is repeated on the other side. The wound is closed with drainage. In exceptional circumstances the second lobe may be left until the patient has had a further course of medical treatment. Removal of the major part of one lobe, or even a small portion of the other in addition, is seldom sufficient to bring about a complete cure.

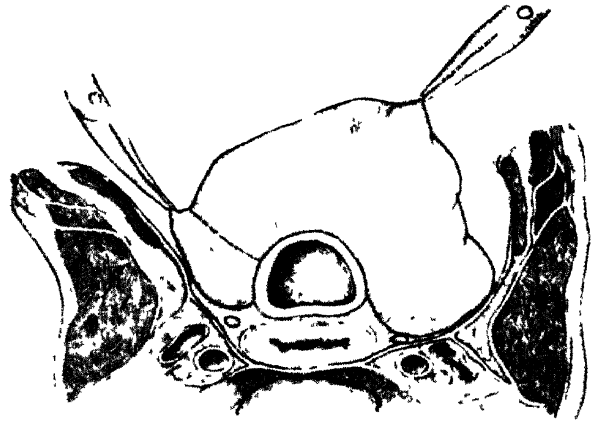

FIG. 122 Diagram showing the relative amount of a lateral lobe which is removed in exophthalmic goitre, and the portion which remains protecting the parathyroid glands and the recurrent laryngeal nerve

Post-operative Treatment.—The patient is propped up in the sitting position. The pulse must be watched closely. Glucose solution is given rectally, subcutaneously, or intravenously, according to the needs of the patient: it is of the highest importance that the total fluid intake should be in the neighbourhood of six pints per day. One drachm of Lugol's solution in cream is given per rectum a few hours after operation. Minims 10 of Lugol's solution are given t.d.s. in fruit juice for five or six days. It is then usually discontinued.

Post-operative Complications. Hæmorrhage.—The nurse should be instructed to watch for excessive hæmorrhage, particularly at the back of the dressing, for the blood tends to trickle posteriorly. Hæmorrhage may be concealed owing to clotting. Any undue bulging of the neck must be reported immediately.

Dyspnœa.—Urgent dyspnœa may result from blood-clot pressing upon the trachea. Under such circumstances it is necessary to re-open the wound and ligate the bleeding vessel.

Acute post-operative hyperthyroidism may come on suddenly immediately after operation, or it is sometimes delayed for several hours. The symptoms are increasing pulse-rate, restlessness, and vomiting. **Treatment.**—When the temperature is above 103, ice packs should be ordered. The patient should be placed immediately

on continuous intravenous saline and glucose, to the first pint of which is added 50 to 100 minims of Lugol's solution. In desperate cases opening the wound and packing the centre lightly with saline-soaked gauze sometimes benefits the patient remarkably. This procedure evacuates toxic serum spilled from the cut surface of the thyroid.

Tetany.—When this complication supervenes it is usually about twenty-four hours after the operation. It is due to parathyroid insufficiency, and its frequency has been greatly diminished by modern operative technique.

Treatment consists in giving calcium, parathyroid extracts, and copious saline.

Damage to the recurrent laryngeal nerve may result in hoarseness, partial or total loss of voice. It should be noted that nearly all patients after an extensive thyroid operation speak in a whisper for a few days to spare undue movement in the region of the wound.

SECONDARY GRAVES'S DISEASE (*syn.* TOXIC ADENOMA)

is usually seen in women over 40 who have had a simple goitre or multiple adenomata for years—often since their teens. Although symptoms are less severe than in primary Graves's disease, the condition is steadily progressive, and remissions are absent. Cardiovascular symptoms (see p. 174) are most in evidence, and many of these patients have myocardial degeneration. Exophthalmos is always absent. Toxic adenomata may be single or multiple. The neoplasms are inclined to occupy the lower poles, and are often wholly or partially retrosternal.

Treatment should be always surgical. The same careful pre-operative treatment as detailed for primary Graves's disease is necessary. Local anæsthesia is advisable. The adenomata are removed by enucleation-resection, that is, removal of all adenomatous tissue with, in multiple cases, part of the surrounding normal gland tissue.

NEOPLASMS

Adenoma

Clinical Features.—True adenomata are frequently solitary, although it is not rare for two or three to be present. When the whole gland feels studded with rounded projections, the pseudo-adenomata of adeno-parenchymatous

goitre must be suspected. The favourite site for a solitary adenoma is at the junction of the isthmus with one lateral lobe (figs. 123 and 124). An adenoma in the lower part of the thyroid is inclined to invade the thorax (retrosternal goitre) as it enlarges.

Deformity.—The projection produced by the neoplasm when it has reached a certain size is the most common symptom which brings the patient to seek advice.

Dyspnœa is complained of when an adenoma presses upon the trachea. This is the second most common complaint, and by far the most important. Dyspnœa is noticed in the early stages only upon exertion ; later it worries the patient at night. *Urgent dyspnœa*, threatening life, may result from a sudden hæmorrhage into an adenoma ; it also occurs without a demonstrable hæmorrhage in cases of large retrosternal goitre.

Thyrotoxic symptoms may develop in old-standing cases. This subject has been dealt with under the heading of secondary Graves's disease.

Alterations in the Voice.—Very occasionally a simple adenoma may be accompanied by alterations in the voice due to pressure on the recurrent laryngeal nerve. It was formerly considered that such symptoms were clear evidence of a carcinomatous change, but quite definitely this is not necessarily the case.

Pathology.—From a histological point of view these encapsulated tumours are divided into (1) fœtal adenoma, and (2) adult adenoma. Such a classification depends entirely upon the type of cell present. Adenomata of the thyroid frequently undergo cystic degeneration, and in old-standing cases calcification may occur in the walls of the tumour, especially in retrosternal adenomata.

Radiology as a help in Diagnosis.—It has just been mentioned that the walls of an adenoma may be calcified, in which case an excellent radiographic shadow will be cast. This is particularly valuable in retrosternal goitres, the walls of which are fortunately often calcified. Expert radiologists can demonstrate clearly the amount of tracheal

deformity produced by an adenoma. Such information is interesting and instructive.

Treatment.—Removal of the adenomata should be undertaken in all cases. There is a certain justification for a preliminary course of iodine therapy, for in a very few cases the lump apparently disappears. On the other hand, there

FIG. 123.—A large adenoma of the thyroid.

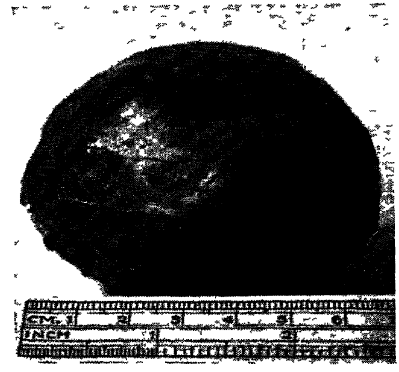

FIG. 124.—The adenoma enucleated.

are risks—true, they are small—in leaving an adenoma of the thyroid for even a few months. First there is a possibility of a malignant change (see p. 180); secondly, there is the risk of thyrotoxic complications at about the age of 40 (see p. 177), and thirdly, there is the danger of suffocation. In one of our patients, a girl of 18, a preliminary course of medical treatment was desired by her parents in order to see if operation could be avoided. Fourteen days later she died in the street from a sudden hæmorrhage into the adenoma. This brings us to the important question of what to do in a case of impending suffocation from this cause. The treatment must be immediate. Aspiration of a cyst with a wide-bore needle is often effective, but in less favourable circumstances, or when such a measure fails, an incision over the swelling, *dividing the deep cervical fascia* and allowing the adenoma to bulge into the wound (instead of pressing upon the trachea) has proved a life-saving measure.

Carcinoma

The rule that metastases of a malignant growth are functionless is broken in the case of secondary deposits of malignant disease of the thyroid, for after extirpation of the parent gland such deposits, which often occur in bone, may and do function to an extent adequate for the body's need.

Three main varieties of carcinoma of the thyroid are recognised :

1. Malignant adenoma (90 per cent.) (fig. 125).
2. Papilliferous adenocarcinoma.
3. Schirrous carcinoma.

Carcinoma of the thyroid usually commences in pre-existing benign adenomata. If for no other reason, the possibility of a malignant change is a clear indication that simple adenomata of the thyroid should be enucleated at a reasonably early stage. As in the case of the prostate gland, a few apparently benign thyroid tumours, when subjected to microscopical examination, will be found to be already malignant. If upon a clinical examination a malignant change is tolerably certain, operation should still be undertaken, providing there are no demonstrable secondary deposits. All, or as much as possible, of the growth is removed, and as soon as the wound has healed X-ray treatment is instituted. As yet, treatment by radium is not satisfactory in this region. Except in early cases, the ultimate prognosis is poor, but not hopeless, a few quite advanced cases surviving many years after a combined surgical and X-ray attack upon the growth.

FIG. 125.—Carcinoma of the thyroid.

Inflammation of the Thyroid

It has been indicated already that inflammations of the thyroid are uncommon. When a previously normal thyroid is affected, the condition is one of **thyroiditis**, which must be distinguished from strumitis, a term denoting inflammation in a goitre.

Acute thyroiditis is sometimes primary, but more often secondary to such conditions as tonsillitis and pneumonia. Suppuration is rather infrequent. Treatment follows orthodox lines of local inflammation.

Chronic Thyroiditis.—Tuberculous, syphilitic, actinomycotic, and other chronic inflammations have been reported. There is one chronic inflammatory lesion peculiar to the thyroid which must be mentioned:

Ligneous Thyroiditis (Riedel's Disease).—According to Ewing, this is essentially a granuloma. Riedel himself called it "iron-hard strumitis," which indicates the clinical features of the condition.

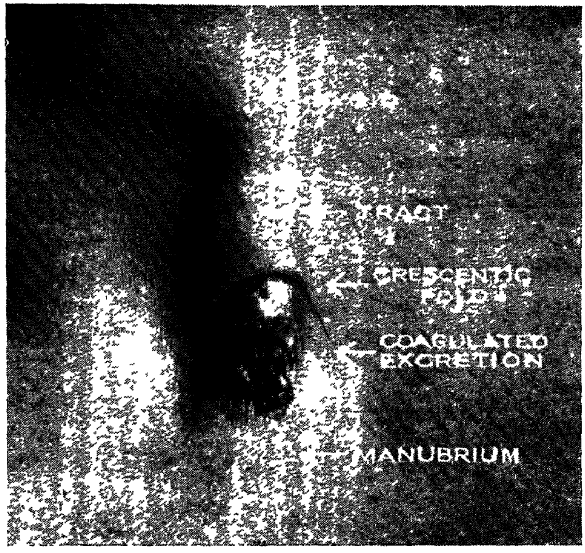

Fig. 126.—A long-standing thyroglossal fistula The semilunar fold is characteristic.

Anomalies of the Thyroglossal Tract

Thyroglossal fistula is rarely congenital. It most often follows local extirpation or incision of a thyroglossal cyst. Long-standing fistulæ are inclined to be situated low down in the neck, and fig. 126 shows an example present for twenty years. The hood of skin with its concavity downwards (due to uneven rates of growth of the neck as a whole and the thyroglossal tract) is characteristic. The tract is

lined by columnar epithelium, discharges mucus, and is the seat of recurrent attacks of inflammation.

Thyroglossal cyst may be present in any part of the thyroglossal tract (fig. 127). The common situations are beneath the hyoid, and in the region of the thyroid cartilages. Such a cyst occupies the middle line, except in the region of Adam's apple, where the thyroglossal tract is pushed to one side, usually to the left.

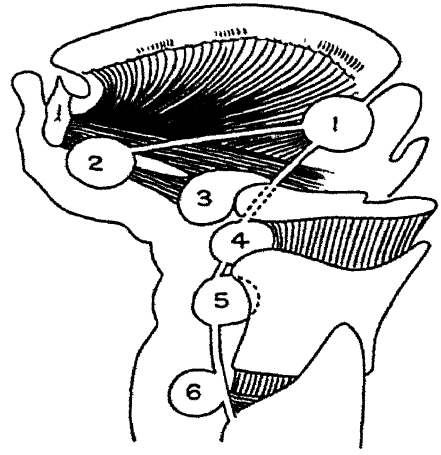

FIG. 127. Possible sites of a thyroglossal cyst: (1) Beneath the foramen cæcum. (2) In the floor of the mouth. (3) Suprahyoid (4) Subhyoid. (5) On the thyroid cartilage. (6) At the level of the cricoid cartilage.

Thyroglossal cysts are the seat of recurrent attacks of inflammation, and when inflamed they are mistaken for abscesses and incised. This is one way in which a thyroglossal fistula arises.

The treatment of a thyroglossal cyst or a thyroglossal fistula is essentially the same. Every vestige of the thyroglossal tract must be removed right up to the foramen cæcum, otherwise a discharging fistula is almost inevitable. Because of difficulty in defining the tract in the region of the hyoid bone, a wedge from the centre of this bone is removed in the course of the dissection. Before embarking upon the removal of a supposed thyroglossal cyst, it is well to make sure that there is a thyroid gland present in the normal position, for the swelling in question may be an ectopic thyroid (see p. 167).

THE PARATHYROIDS

These small glands, brownish red in colour and usually four in number, control calcium metabolism. They are normally placed outside the thyroid capsule, but one or more of them may be embedded in the thyroid gland. Indeed, in 8 per cent. of thyroidectomies a portion of parathyroid tissue is found in the extirpated material.

Extirpation.—The fatal result which follows complete removal of the thyroid is largely due to the inevitable concomitant loss of the parathyroids. Tetany is the leading symptom, and it is liable to follow the loss of two out of the four parathyroids. Tetany, for some obscure reason, also sometimes occurs in the new-born idiopathically, and more rarely still in adults after operation upon the stomach and testis. Tetany due to parathyroid loss is rapidly fatal unless treated actively. The treatment consists of administering parathyroid extract and calcium salts, combined with infusion of saline.

FIG. 128.—Generalised osteitis fibrosa. Tumour of right superior parathyroid body (*actual size*). (D. Hunter.)

Tumours of the Parathyroids.—Generalised osteitis fibrosa is due to hyperparathyroidism. Enucleation of the parathyroid tumour, or tumours (fig. 128), which are invariably associated with this bone disease, results in the arrest of the osseous changes (p. 813). The enlarged parathyroid is seldom palpable upon a clinical examination, and it can be found only by exploration when the whole thyroid has been displayed at operation.

THE THYMUS

Status lymphaticus is a condition in which sudden death occurs from an apparently trivial cause. At necropsy the thymus and lymphatic glands are found to be enlarged, the former being often six or eight times its normal size. This rare condition is confined to children and young adults. A few years ago deaths under anæsthesia were often attributed to status lymphaticus. To-day the consensus of opinion is that a moderate enlargement of the thymus cannot be accepted as sufficient reason for this unfortunate occurrence.

Thymic Asthma.—There are recurrent attacks of laryngeal spasms and the larynx is usually under-developed. It occurs in babies and young children, and can be looked upon as the clinical manifestation of status lymphaticus, which is a post-mortem finding.

DuBois's "abscesses" sometimes occur in congenital syphilis. The thymus becomes vacuolated. The spaces are filled with turbid fluid which is not true pus.

Tumours of the Thymus.—When it enlarges sufficiently to press upon the larynx and the great veins, a tumour of the thymus gives rise to pressure symptoms. Such a tumour may cause fatal asphyxia. The most common thymic neoplasm is a lympho-sarcoma. Innocent tumours are very rare.

Thymic Cysts.—Simple cysts of the thymus have been reported in the literature.

CHAPTER XII

THE LARYNX AND PHARYNX

THE LARYNX

Acute Œdema of the Glottis

Ætiology.—*Inflammatory.*

1. Scalds and corrosives.
2. Extension of acute inflammation, especially Ludwig's angina and acute streptococcal tonsillitis.

Non-inflammatory.

1. Local dropsy (renal or heart failure).
2. Extension of carcinoma of the tongue.
3. Pressure on great cervical veins.
4. After massive doses of potassium iodide (rare).
5. Angio-neurotic œdema.

The œdema is an exudation into the submucosal tissue of the rima glottidis. The patient complains of pain "as though he had a foreign body in the throat." The œdema is liable to spread to the ary-epiglottic folds and the gut-glottic region, and cause urgent dyspnœa. If laryngoscopic examination is possible the entrance to the larynx can be seen presenting an appearance not unlike a cervix uteri. Digital examination will reveal swelling of the parts. In obscure and not very urgent cases, the urine should be examined for albumen and casts.

Treatment.—Inhalation of medicated steam and spraying with a dilute solution of adrenaline afford relief in early and mild cases. When dyspnœa is urgent, laryngotomy should be performed forthwith.

The Relief of Urgent Obstructive Dyspnœa

The two emergency measures to be considered are tracheotomy and laryngotomy—tracheotomy for children, laryngotomy for adults (fig. 129).

Laryngotomy.—As a temporary measure for relieving sudden laryngeal obstruction in adults laryngotomy is unsurpassed.

Operation.—The patient's head is extended and held in the middle line. A transverse incision is made at the upper

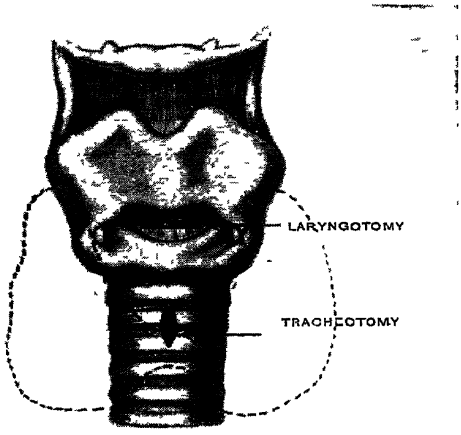

FIG. 129.—Emergency openings into the windpipe.

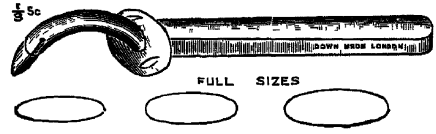

FIG. 130.—Butlin's laryngotomy tube.

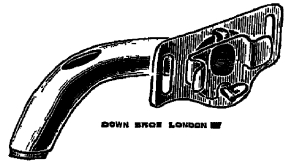

Cubley's tracheotomy tube. Outer and inner tubes assembled.

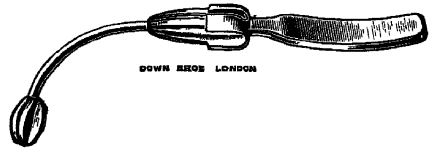

Pilot for use in introducing the tube at the operation.

FIG. 131.

border of the cricoid cartilage. The crico-thyroid membrane is opened and a laryngotomy tube (fig. 130) inserted.

Tracheotomy.—The child should be pinned in a blanket, and a small sandbag insinuated between its shoulders. An assistant holds the head in a fully extended position. The cricoid cartilage is palpated, and exactly in the middle line an incision is made from the upper border of the cricoid downwards for 1½ in The isthmus of the thyroid is divided between hæmostats, thereby exposing the trachea. Through the second, third, and fourth rings of the trachea, a vertical incision is made into the windpipe. The edges of the tracheal incision are picked up with dissecting forceps and

trimmed, so as to make an oval window through which a tracheotomy tube is inserted.

Dividing the isthmus of the thyroid does away with the "high" and the "low" operations. There is but one operation—tracheotomy, applicable to all cases.

The usual indications for tracheotomy are as follows:

1. Acute inflammation of the larynx, causing urgent dyspnœa. The most notable example in this category is diphtheria in children.

2. Laryngeal stenosis, following inflammations or new-growths.

3. Bilateral abductor paralysis, when the cause, e.g. irritation of the recurrent laryngeal nerves, cannot be removed.

4. Foreign bodies in the air passage, when facilities for peroral laryngoscopy and bronchoscopy are not available.

5. As a preliminary to certain operations, particularly extirpation of the larynx.

SUBSTITUTES FOR TRACHEOTOMY AND LARYNGOTOMY IN CERTAIN CIRCUMSTANCES

(*a*) **Intubation.**—In fever hospitals, where cases of laryngeal diphtheria are frequently encountered, intubation is rightly popular. O'Dwyer's apparatus is generally employed. A small vulcanite tube with a shoulder is passed through the mouth and glottis upon a special introducer. The tube is so placed that the shoulder rests against the false vocal cords and the lumen of the tube provides the airway.

(*b*) **Intra-tracheal Catheterisation.**—Experience gained by intra-tracheal anæsthesia has popularised intratracheal catheterisation as a method of overcoming dyspnœa in certain cases of temporary laryngeal obstruction.

Foreign Bodies in the Air Passages

Various objects held in the mouth are accidentally inhaled; the accident is particularly prone to occur in children and the unconscious. Occasionally the foreign body is arrested in the larynx, but in most instances it passes down the trachea, and thence into one of the bronchi, usually the right.

Symptoms.—The first symptoms are those of laryngeal obstruction; they are usually transient, and very rarely

does death from asphyxia result. These symptoms are succeeded by those of irritation. There is retrosternal pain, persistent cough, and often expectoration of blood-stained mucus. From time to time paroxysms of dyspnœa, with a terrifying sensation of impending dissolution, occur. When the foreign body becomes impacted in some portion of the lower air passages the symptoms largely pass off, but inflammation proceeds, and the development of a lung abscess is not far distant.

Treatment.—Radiography will be indispensable in the case of foreign bodies opaque to the rays. Immediate tracheotomy is the correct treatment in urgent cases with obstructive symptoms. When possible, direct laryngoscopy should be used if the foreign body is arrested in the larynx, and by its aid the object can be seized and removed through the natural passages. In cases where the foreign body is in a bronchus, the services of a skilled bronchoscopist should be obtained. The bronchoscope can be passed along the natural passages (high bronchoscopy), and by means of the instrument the foreign body is located and removed. Low bronchoscopy, that is, the introduction of a bronchoscope through a tracheotomy opening, requires less skill, and permits a larger endoscope to be used.

LARYNGEAL TUBERCULOSIS

The larynx is rarely the seat of primary tuberculosis. In the majority of cases the primary focus is in the lungs, and the laryngeal mucosa becomes infected by the sputum. The mucous membrane appears œdematous and semi-translucent. Ulceration follows, and in many instances necrosis of the cartilage occurs eventually. The prognosis is poor, and the treatment is directed to the primary lesion. In rare instances tracheotomy may be called for.

LARYNGEAL SYPHILIS

Secondary syphilitic manifestations are sometimes noted in the larynx. The mucous membrane becomes congested and mucous patches form. The voice is husky. Syphilitic laryngitis clears up under anti-syphilitic treatment.

Tertiary Syphilis.—The usual lesion is a gummatous infiltration, which attacks the epiglottis, and may implicate all the structures of the larynx. Necrosis of cartilage is liable to follow. The pathological process is arrested by anti-syphilitic treatment, but subsequent cicatricial contracture is liable to cause laryngeal stenosis. For severe contractions permanent tracheotomy is the only remedy.

Neoplasms of the Larynx

Innocent.—*Papillomata* are the commonest simple tumours of the larynx. These wart-like growths spring from the posterior third of the false or true vocal cords, usually the latter (fig. 132). They are soft and often pedunculated, and occasionally grow until they nearly fill the larynx.

The patient complains of hoarseness and aphonia. Later dyspnœa is a symptom which is liable to become urgent. Laryngeal papillomata are relatively frequent in children. They have been known to disappear spontaneously. More

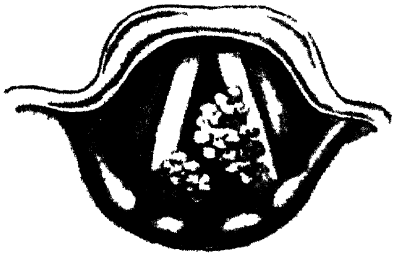

Fig 132.—Papillomata of the vocal cords. (Tilley.)

Fig. 133. Intrinsic carcinoma of the larynx. (Irwin Moore.)

frequently they multiply, and tend to recur after removal. The diagnosis is made by laryngoscopic examination.

Treatment consists of removing the growths endoscopically with a snare. In recurrent cases thyrotomy is performed, and the growths are excised with a diathermy knife.

Malignant.—*Carcinoma of the larynx* usually attacks males between 40 and 60. Clinically it is important to recognise two varieties: the *intrinsic* and the *extrinsic*.

Intrinsic carcinoma arises from the interior of the larynx, usually from the anterior half of one vocal cord (fig. 133). The first symptom is huskiness. For many months the disease remains localised, and, for so long as the growth remains confined to the larynx, metastasis is uncommon The diagnosis is made by laryngoscopic examination. In doubtful cases a portion of the growth is removed for microscopy. The huskiness is progressive, and the patient

can only speak in a low whisper, which finally gives place to aphonia. About this time the growth breaks through its cartilaginous confines, and secondary deposits occur in the cervical glands and elsewhere.

Treatment.—If the diagnosis can be established in time, thyrotomy (*syn.* laryngo-fissure) and excision of the growth is often successful. Later in the disease, complete laryngectomy has given excellent results (fig. 134), especially when combined, after an interval, with dissection of the cervical glands of both sides of the neck.

FIG. 134.—Patient after complete laryngectomy. (Jackson and Babcock.)

Extrinsic carcinoma is relatively more malignant. It attacks the epiglottis, the ary-epiglottic fold, or the posterior surface of the cricoid cartilage. The voice is "thick." Dysphagia and dyspnœa are early symptoms. The cervical glands are affected early; indeed, it is the secondary deposits in the neck which sometimes first call attention to the presence of the disease.

Treatment.—Radical surgery is often impossible. Radium is frequently the only course. On the whole the prognosis of this form of carcinoma is gloomy.

Tumours of the naso-pharynx are considered on p. 114.

HYPERTROPHY OF THE TONSILS

Hypertrophy of the tonsils is usually associated with adenoids. Because in early childhood the lymphatic system is in full activity, it is children who are most often affected. In the adult the tonsils, together with other lymphoid tissue, tend to undergo a process of involution. When hypertrophied the whole tonsil is enlarged (fig. 135) and its mucous membrane thickened. Crypts can be often seen,

and when chronically infected, pus and debris can be expressed. In suitable instances suction of the tonsils enables a bacteriological examination to be made.

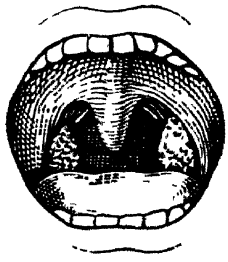

Fig. 135.—Hypertrophied tonsils.

Clinical Features.—The hypertrophy is usually bilateral. Occasionally the tonsils are so enlarged that they almost meet in the middle line. During early childhood they are usually soft, but as puberty is reached they frequently become indurated, due to recurrent attacks of inflammation and subsequent fibrosis. The tonsillar lymph gland of the jugular chain is usually palpable. Considerable tonsillar hypertrophy causes the patient to snore loudly at night and to breathe through the open mouth, giving that well-known vacant expression. Added to this, hearing is impaired by the hypertrophied adenoids obstructing the orifice of the Eustachean tubes.

Treatment.—While indiscriminate extirpation of tonsils and adenoids is to be deprecated, there can be no question that removal of hypertrophied and diseased tonsils and adenoids confers enormous benefits upon the individual. In children particularly, when this source of recurrent infection and respiratory obstruction has been removed, the child's general condition improves remarkably.

Tonsillectomy.—The ideal method of removing the tonsils is by complete dissection. The operation is somewhat time-consuming. With the head well extended and the mouth kept open widely with a special gag, such as Davis's, the tonsil is dissected from its bed and bleeding points are ligatured.



Fig. 136 Tonsil guillotine.

Tonsils can also be enucleated satisfactorily by the guillotine (fig. 136). This is the most practical method of dealing with a large number of cases, and it has proved satisfactory, especially in children. Adenoids are usually removed with a curette

(figs. 137 and 138), and often immediately after the tonsils have been dealt with.

When the tonsils have been removed with the guillotine considerable hæmorrhage occurs. This soon ceases when the pharynx has been cleared with swabs upon a holder, and ice-cold water, which should always be in readiness, is applied to the face. The patient is kept in the operating theatre until the bleeding has ceased and the air-way is clear.

After-treatment.—Until the patient has recovered consciousness he should be kept with his head low and well over to one side. On no account should he be permitted to lie on his back or be left unattended.

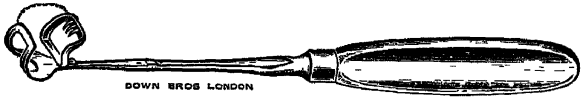

FIG. 137.—Adenoid curette.

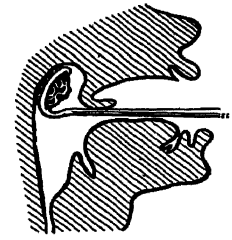

FIG. 138.—Curettage of adenoid vegetations

Hæmorrhage after Tonsillectomy.—The main disadvantage of the guillotine operation is that occasionally serious renewed hæmorrhage occurs from the tonsillar bed. In such cases prompt measures are necessary. Among the most important of the immediate measures are the application of pressure by means of a swab on a holder, or preferably by a special tonsillar-bed clamp. When the bleeding point cannot be ligated satisfactorily coaptation of the pillars of the fauces with sutures will arrest the hæmorrhage. The usual methods of replenishing the circulation after loss of blood must be invoked.

PERITONSILLAR ABSCESS (*syn.* QUINSY)

Peritonsillar abscess is nearly always an extension of acute suppurative tonsillitis. The general symptoms are often severe. Locally, in addition to the signs of the preceding tonsillitis, there is a diffuse swelling of the soft palate, most in evidence near the superior border of the affected tonsil. Early evacuation is the only satisfactory treatment.

A scalpel is prepared by winding a strip of strapping around the blade so that only 1 cm. of the tip projects. An incision is made in the position shown in fig. 139, which is usually described as midway between

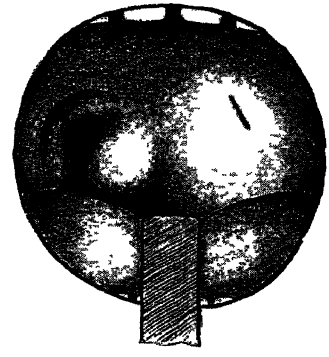

FIG. 139.—Peritonsillar abscess showing site of incision.

the base of the uvula and the third upper molar tooth. Dressing forceps are now pushed firmly *directly backwards*. As soon as pus is encountered the forceps are widely opened and withdrawn.

Parapharyngeal abscess is similar to the above, only the maximal swelling is behind the posterior faucial pillar, and there is little or no œdema of the palate. The abscess is opened with a really blunt instrument, such as a tongue depressor. Often the gloved finger will suffice (Watson-Williams).

Retropharyngeal Abscess

Two forms exist :

Acute.—*Between* the prevertebral fascia and the pharynx.

Chronic.—*Behind* the prevertebral fascia.

Acute retropharyngeal abscess is most commonly seen in children under the age of 4. It is the result of suppuration of the lymphatic glands which occupy the space. In infants the condition is sometimes very acute, and accompanied by rigors, convulsions, and vomiting. The neck is held rigidly, usually on one side, and saliva dribbles from the child's mouth. Its feeds are regurgitated, and dyspnœa is an important feature. The posterior wall of the pharynx is swollen. This is sometimes only visible when the base of the tongue has been firmly depressed. A localised projection may be felt digitally. The only condition with which acute retropharyngeal abscess is likely to be confused is laryngeal diphtheria.

A less acute form is seen in older children as a complication of middle-ear disease.

Treatment.—The anæsthetised child is held upside down, a pair of dressing forceps guided by the finger is thrust into the abscess cavity, the contents of which are evacuated before the patient is laid prone.

Chronic retropharyngeal abscess is almost always an extension of Pott's disease of the cervical vertebræ (fig. 140). When the collection of pus is large, in addition to the retropharyngeal swelling, there is a fullness behind the sternomastoid on one side. The pus is evacuated by an incision behind the sternomastoid. The dissection towards the retropharyngeal space is conducted carefully until the

abscess is opened. The cavity is then mopped dry and the wound closed. The treatment of the tuberculous process must then receive attention.

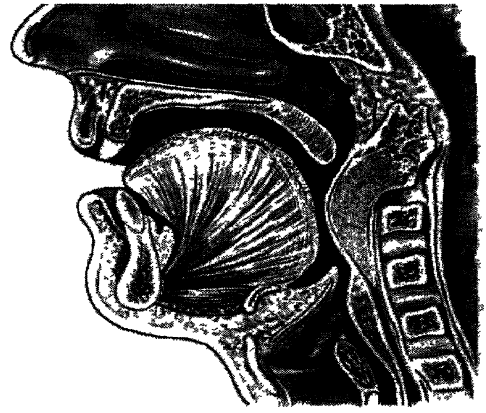

FIG. 140 — Chronic retropharangeal abscess secondary to tuberculous cervical caries.

MALIGNANT TUMOURS OF THE TONSIL

Both carcinoma and sarcoma occur in the tonsil. The diagnosis in many instances is not easy. Any unilateral enlargement of the tonsil occurring in adult life should be regarded with suspicion. After a Wassermann reaction to exclude syphilis a fragment of tissue is removed for histological scrutiny.

Carcinoma of the tonsil presents features akin to those of carcinoma of the tongue or floor of the mouth, and the treatment is similar.

Sarcoma of the tonsil is rare, and has the reputation of being very malignant. While this is true if it is allowed to grow beyond the peritonsillar bed, the condition is by no means hopeless in its early stages. The patient, who, it should be noted, is usually between 50 and 60 years of age, complains of a lump in the throat, which in the early stages is painless. Thick speech is a common symptom, and the tonsil appears large and pale.

Treatment.—If the whole tonsil is removed before the peritonsillar capsule has been invaded, the expectation of a cure is high. Later the growth spreads, and often forms a swelling of the palate, which many times has been mistaken for a peritonsillar abscess, and incised. Later still, bleeding, dysphagia, and dyspnœa are leading features. The cervical glands become palpably involved. The victim is now beyond the reach of surgery, or indeed of any curative treatment, though radium or Coley's fluid may be tried.

Diverticulum of the Pharynx

Congenital lateral diverticulum is really a blind internal branchial fistula (p. 155) opening into the fossa of Rosenmuller. Occasionally such a fistula becomes greatly distended and food lodges within it.

Pharyngeal pouch (*syn.* Pulsion diverticulum; pressure diverticulum; œsophageal pouch). The last synonym is incorrect, for the diverticulum commences in the posterior wall of the pharynx 1 cm. above the commencement of the œsophagus. At this point is situated the pharyngeal dimple

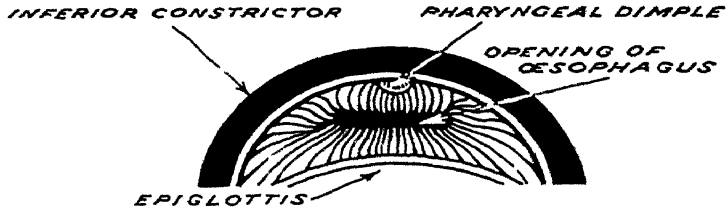

Fig. 141.—Showing the pharyngeal dimple.

(fig. 141). After middle life, behind this dimple, some separation of the musculature of the inferior constrictor (Killian's dehiscence) is apt to occur, and the mucous membrane tends to herniate when a bolus of food is swallowed. So commences a pharyngeal pouch. As time goes on the sac becomes larger and fills with food at every meal. Unable to expand posteriorly because of the resistance of the spinal column, the pouch turns outwards, usually to the left, and obtrudes itself into the side wall of the neck. In about one-third of cases the pharyngeal pouch is large enough to form a visible swelling. Sometimes the pouch can be seen to enlarge when the patient drinks water. The condition occurs principally in elderly men whose main complaint is dysphagia, for when the sac becomes full its lower part presses upon the œsophagus (fig. 142). Regurgitation of undigested food often occurs. An irritable cough and gurgling noise in the neck may also be

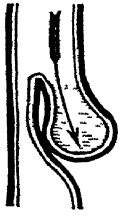

Fig. 142.—Showing how a pharyngeal diverticulum causes dysphagia.

symptoms. Some intelligent patients acquire a knack of overcoming their disability. It is recorded that Lord Jeffrey, a Scottish nobleman, was in the habit of emptying his pouch with a large silver spoon after every meal. Other sufferers have found that they can swallow their food better if the pouch is full, and accordingly take porridge as a first course. Notwithstanding these ingenious devices eventually there is progressive loss of weight, due to semi-starvation, and cachexia is sometimes extreme.

The patient should be investigated by X-ray examination after the ingestion of a barium meal. Quite often the fundus of the pouch will be seen invading the mediastinum.

Treatment.—Whatever the age and condition of the patient, operation should be undertaken, for progressive symptoms are inevitable. The preoperative treatment should be directed to washing out the sac, which can be accomplished by encouraging the patient to drink water at frequent intervals. The operation should be conducted

FIG. 143.—First stage completed of an operation for removal of a pharyngeal diverticulum.

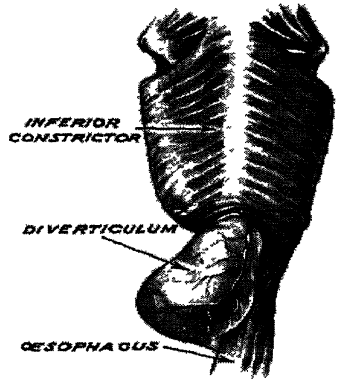

FIG 144.—Pharyngeal diverticulum viewed from the posterior aspect.

under local anæsthesia, and what is exceedingly important, it should be performed in two stages.

At the first stage a longitudinal incision is made in front of the sternomastoid over the lower front of the neck, and the pouch is

freed and its fundus is brought to the surface. The wall of the sac is stitched carefully to the muscles in such a way that its opening into the pharynx inclines downwards rather than upwards. The skin is then closed about the unopened sac. If the patient is starving, at the end of the operation, when the wound has been duly protected, a catheter may be sewn into the protruding fundus of the sac. The eye of the catheter should be well down the œsophagus, and nourishment is given by this route.

The second stage is undertaken about fourteen days later. The pouch is cut off level with the skin. The mucosa is dissected up for a short distance and the wound closed in two layers.

Performed in this way, the operation is highly satisfactory and even a life-saving procedure. The dreaded complication of mediastinitis, formerly the bugbear of removal of an œsophageal pouch, has been banished by the two-stage method. Protective adhesions are formed before the pouch, the interior of which is always grossly infected, is opened.

CHAPTER XIII

THE ŒSOPHAGUS

As measured from the incisor teeth in the average adult :

At 7 *inches*—the pharynx ends and the œsophagus commences.

At 11 *inches*—the œsophagus is crossed by the left bronchus.

At 17 *inches*—the cardiac orifice is situated and the œsophagus ends.

These figures, 7, 11, and 17, are of great importance in the surgery of the œsophagus. They represent the situations of anatomical narrowing, and consequently the points where ingested foreign bodies are likely to be arrested, and where difficulty may be experienced during the passage of instruments. Furthermore, these points are the seats of election for malignant disease, the commonest affection of the œsophagus.

Investigation of the Diseases of the Œsophagus

The œsophagus is very inaccessible, and as a consequence clinical methods of examination are of little avail.

Until the twentieth century one of the chief methods of examining this organ was by inserting bougies blindly down the gullet. Aneurisms were frequent in those days, and it happened occasionally that an aortic aneurism escaped detection until a bougie was passed. The terrifying hæmorrhagic cascade through the victim's mouth clarified the diagnosis, but brought " blind " œsophageal instrumentation into disrepute. Another, and probably more frequent, accident of this nature, is perforation of the œsophageal wall in the neighbourhood of a carcinomatous stricture. We have seen fatal cases of mediastinitis from that cause.

Barium meal and X-rays are of great value in detecting an œsophageal stricture. An X-ray examination in the case of an ingested foreign body is authoritative and absolute, providing that the foreign body is opaque to the rays.

Œsophagoscopy.—Sir John Bland-Sutton was wont to remark that it required the instincts of a sword-swallower combined with the eye of a hawk to use successfully the œsophagoscope. The instrument has been improved, and instructions for its use have been so clearly laid down by that prince of œsophagoscopists, Chevalier Jackson, that there is now no especial difficulty in learning to use the instrument.

FIG. 145. Chevalier Jackson's position for œsophagoscopy. The head of the patient is supported entirely by the hands of the seated assistant.

An essential point in œsophagoscopy is to adopt Jackson's position for the examination (fig. 145). The head of the table is let down completely, and the patient's head and neck are supported by a seated assistant. During the passage of the instrument the assistant keeps the head well flexed, and only when the œsophagoscope is within the thoracic portion of the organ is the head lowered. The instrument is passed entirely under vision and once its beak has passed the cricoid it can be moved down the œsophagus with comparative ease.

ŒSOPHAGEAL OBSTRUCTION

The causes of œsophageal obstruction can be classified as follows :

Extrinsic.

1. Aneurism of the aorta.
2. Mediastinal tumours.
3. Enlarged mediastinal glands.
4. Mediastinal abscess.

Intrinsic.

1. Foreign bodies (acute obstruction).
2. Carcinoma.
3. Cardiospasm.

4. Cicatricial contracture—corrosive burns, syphilitic, tuberculous.
5. Congenital stricture.

Acute Œsophageal Obstruction

Foreign Bodies in the Œsophagus.—All manner of foreign bodies have been swallowed and arrested in the œsophagus. Coins, sets of false teeth, and pins head the list of these miscellaneous articles. With the possible exception of a coin in the upper œsophagus, the intruder should be extracted by forceps introduced through an œsophagoscope (fig. 146). In all cases an X-ray is essential, and the patient should be screened immediately before œsophagoscopy is attempted, otherwise the position of an opaque foreign body cannot be guaranteed.

Fig. 146.—Œsophagoscope with the œsophageal forceps *in situ*.

The coin-catcher (fig. 147), if used with discretion, and under the vision afforded by a fluorescent screen, is not a dangerous instrument Coins in the pharynx and upper end of the œsophagus, especially in children, can be extracted safely and easily by its agency.

Scale $\frac{1}{5}$

Fig. 147.—A coin-catcher.

Chronic Œsophageal Obstruction

Carcinoma of the Œsophagus.—Carcinoma of the œsophagus is a common condition, one out of twenty of all cases of cancer being situated in this organ (Clayton). There is no known predisposing cause, and the condition is almost inevitably fatal.

Pathology.—*Situation of the Growth* :

Opposite the cricoid (7 in. from the front teeth) . . .	18%
Opposite the bifurcation of the trachea (11 in. from the front teeth)	47%
At the cardiac orifice (17 in. from the front teeth) . .	35%

(A. L. Abel.)

Macroscopically three types can be recognised :

1. An annular constriction.
2. A papilliferous mass (fig. 148).
3. A carcinomatous ulcer.

The first variety is usually found at the cardia.

Microscopically, when derived from the mucosa of the upper two-thirds of the organ, the growth is squamous-celled, while in the lower third it is often of the columnar type.

The disease, which remains virtually confined to the œsophagus and its immediate environs, kills the patient in one of the following ways :

1. Starvation.
2. Pneumonia from perforation into the air passages. An acquired tracheo-œsophageal fistula is common in this disease (Bland-Sutton)
3. Mediastinitis from an extension of peri-œsophageal suppuration.
4. Erosion of the aorta (very rare).



Fig. 148. Carcinoma of the œsophagus, papilliferous type, as viewed through an œsophagoscope.

At necropsy one often marvels at the comparative absence of metastatic deposits.

Clinical Features.—Men between 45 and 70 are the usual victims. The disease is distinctly rare in women ; when it occurs it is usually situated at the commencement of the organ. The first symptom is a feeling of "weight," "heavi-

ness," or oppression behind the sternum. If this could be appreciated by the profession, some cases of œsophageal carcinoma might be diagnosed early enough for a hopeful issue. Later, the leading symptom is dysphagia. In surgical out-patient practice the patient usually presents himself when he can no longer swallow milk puddings and such-like semi-solids; by this time the disease is far advanced. Regurgitation of food (œsophageal pseudo-vomiting) is also a common symptom. The regurgitated material is alkaline, mixed with mucus and saliva, and possibly streaked with blood. Pain is conspicuous by its absence until complications have arisen.

Diagnosis.—In this instance clinical methods of examination are peculiarly impotent. Early cases can be diagnosed

FIG. 149.—Radiograph showing obstructive carcinoma of the œsophagus.

FIG. 150.—Radiograph of a case of carcinomatous tracheo-œsophageal fistula. The growth has eroded the trachea and the barium has filled a bronchial tree.

with certainty only by œsophagoscopy. When the disease is more advanced stenosis can be demonstrated by X-rays after a barium meal has been swallowed (fig. 150).

Treatment.—*Palliative treatment*—to avert starvation:

1. *Gastrostomy.*—To be of value gastrostomy should be performed before the patient is actually commencing to starve.

2. *Dilatation of the Stricture.*—Dilatation with bougies under vision with the œsophagoscope serves its purpose.

3. *Intubation.*—*A Symond's tube* (fig. 151) can be inserted. The expanded end of this short gum-elastic œsophageal catheter tends

FIG. 151.—Symond's tube

to prevent it slipping past the growth. The tube can be worn for months, and its lumen allows well-masticated soft food to pass through it. Occasional removal for cleansing is advisable. In modern practice the tube is inserted through an œsophagoscope, and the attached silk thread need not be worn.

Souttar's tube (fig. 152) is a modification of the foregoing. It consists of a tube of coiled German silver wire. As the illustration depicts, it has a flange, and its contour is irregular, which helps to prevent it becoming displaced. Nevertheless, in a fair proportion of cases, the tube does drop into the stomach. Its extreme flexibility renders its passage through the alimentary canal uneventful.

FIG. 152.—Souttar's tube.

4. *Radium.*—It is doubtful if radium has cured any case of

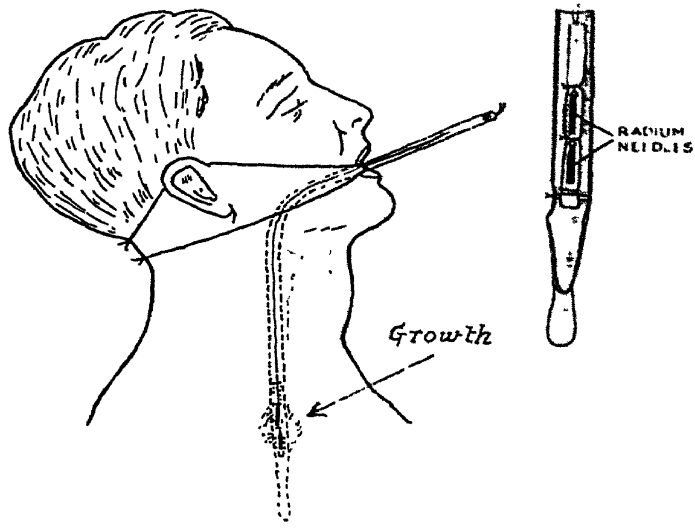

FIG. 153.—Showing a method of applying radium to an œsophageal carcinoma. (After Guisez.)

Inset.—The radium in an œsophageal catheter.

œsophageal carcinoma, but it has certainly brought about regression of the growth, and it is a method which should be tried. Of several

methods of applying the radium the one shown in fig. 153 is self-explanatory, and the most generally applicable.

5. *Deep X-rays.*—Some success has been reported recently following the application of deep X-rays, but permanent cures are as yet unproven.

6. *Diathermy* has been used ; and especially in the papilliferous type of growth, it is a good form of treatment. It is not without danger, for the growth may be perforated. Secondary hæmorrhage is a possible complication.

Radical Treatment.—On theoretical grounds, removal of that portion of œsophagus containing the growth should be a practicable undertaking, for the neoplasm is essentially circumscribed. If the diagnosis could be established earlier, no doubt surgical enterprise would be rewarded. The operation is seldom undertaken, and cases of successful partial œsophagectomy are uncommon. Torek's patient was alive and well in New York twelve years after a carcinoma in the mid-œsophagus had been excised, and a few similar cases (e.g. Grey Turner's case, 1933) serve as beacon-lights to the surgery of the future.

SPASMODIC STRICTURE OF THE ŒSOPHAGUS (*syn.* GLOBUS HYSTERICUS)

Paroxysmally the circular fibres of some part of the gullet pass into spasm. The condition is essentially intermittent—comes on suddenly, passes off abruptly, only to return. Regurgitation of food may occur. The condition is seen particularly in young, hysterical women, but as hysteria is far less common than formerly, spasmodic stricture is hardly ever seen. Œsophagoscopy is the only method of verifying that this is no organic stricture.

We have seen spasmodic stricture of the cardia associated with carcinoma of the stomach, and other observers have noted this occurrence. This, of course, is a condition quite apart.

CARDIOSPASM (*syn.* ACHALASIA OF THE CARDIA)

Definition.—A condition of dilatation and hypertrophy of the œsophagus where, on post-mortem examination, no obstruction can be found distal to the dilatation (Walton).

Pathology.—The œsophagus is greatly dilated and hypertrophied. It is also lengthened. When slit longitudinally its flask-shaped contour is clearly shown (fig. 154). The circumference of the distal portion sometimes measures up to 7 in. As a rule there is no trace of hypertrophy of the cardiac sphincter.

Ætiology.—The normal neuro-muscular mechanism of the cardiac sphincter is upset. Adrian Stokes, as a result of histological investigations, states that in cases of cardiospasm the whole of Auerbach's plexus in the neighbourhood of the cardiac sphincter is destroyed and replaced by fibrous tissue.

Clinical Features.—It is important to emphasise that cardiospasm is not a disease of young women, for it is so

often confused with hysterical spasmodic stricture. Cardiospasm is usually found in men about 50 years of age. The general history is one of dysphagia, but there are several special features.

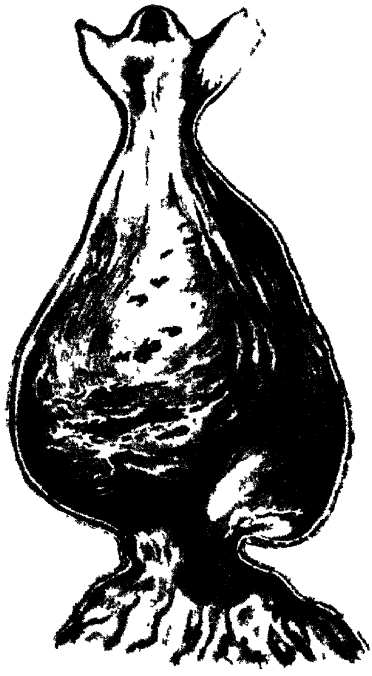

FIG. 154. — Cardiospasm. Necropsy specimen, showing the typical flask-shaped dilatation (after Irwin Moore).

The onset is very gradual, and the patient sometimes only seeks relief after the symptoms have been present for many years. Curiously, not a few sufferers complain that the dysphagia is more marked after taking fluids. There is a painful type of cardiospasm which simulates a gastric lesion, and a more common painless type which resembles carcinoma of the œsophagus. In both vomiting is a feature ; it can hardly be designated as regurgitation, for the immense œsophagus will hold a whole meal. Mucus and froth are brought up in considerable quantities. In advanced cases too much reliance should not be placed upon the reaction of the ejected material, for decomposed food may give an acid reaction.

As a result of the obstruction the patient fails to obtain sufficient nourishment, and if unrelieved death from starvation is a possible termination.

Investigation. — The X-ray appearance is characteristic (fig. 155). The enormous dilatation of the œsophagus is seen in no other condition.

Œsophagoscopy.—Once the instrument has passed the cricoid it appears to enter a gaping cave partially filled with dirty water, which laps to and fro with respiratory movement. When the fluid has been aspirated the cardiac orifice is located with difficulty, owing to its contracted state.

Treatment.—Dilatation of the sphincter can be undertaken by rubber tubes loaded with mercury.

The tubes vary in size from gauge 28 to 34, and each contains 1 lb. 5 oz. of Hg. It is best to pass the mercury-loaded tube under the X-ray screen on the first occasion. A mark should be made on the bougie at the level of the teeth, when its lower 2 in. are in the stomach. Successively longer tubes are passed, and the patient

learns to pass this himself before meals. After a varying period he can dispense with the bougie. This treatment has been successfully employed in a number of cases.

Mikulicz's Operation.—In cases where the weighted rubber tubes fail, operative measures are to be recommended, and the results are permanently gratifying. With the patient in the semi-Trendelenburg position, laparotomy is performed. After the area has been meticulously packed off, the stomach is opened, and very slowly the cardia is stretched, first one finger then a second and a third are inserted. No force must be used, otherwise the card a may be split. The end of an œsophageal tube passed by the anæsthetist is drawn into the stomach, which is closed. There is rarely any further difficulty with swallowing, but the dilatation of the œsophagus remains through life.

FIG. 155.—X-ray in a case of cardiospasm. The enormous dilatation of the œsophagus is characteristic. (A. J. Walton.)

SIMPLE STRICTURE OF THE ŒSOPHAGUS

Simple stricture of the œsophagus is comparatively rare. A few cases are congenital in origin. Most are due to cicatricial contracture following corrosive burns, but in the absence of such a history syphilis must be excluded. The diagnosis is established by X-ray examination and œsophagoscopy. The treatment consists of regular dilatation with bougies under vision through an œsophagoscope. When the stricture has a very small lumen a special guide, to the end of which a larger bougie is attached by a screw, is passed. By these means nearly all simple strictures can be kept patent, and various operative measures which have been described are hardly ever necessary.

CONGENITAL ABNORMALITIES OF THE ŒSOPHAGUS

1. Total absence.
2. Œsophageo-tracheal fistula.
3. Congenital stricture.

A complete congenital membranous stricture has been treated successfully by division of the membrane through an œsophagoscope (Abel). The condition, which is very rare, is sometimes associated with congenital pyloric stenosis.

INJURIES OF THE ŒSOPHAGUS

Injuries of the œsophagus are also uncommon. Rupture of the organ has occurred during the passage of instruments and from

swallowing sharp-pointed objects. The great danger is the development of mediastinitis, which is frequent and often fatal.

Œsophageal Diverticulum

Œsophageal diverticula are usually classified as:

Pressure diverticulum.

Traction diverticulum.

Pressure diverticulum occurs through Killian's dehiscence, and we consider that it is a *pharyngeal* diverticula, and have accordingly dealt with them on p. 194.

Traction diverticulum is of pathological interest only. It usually occurs from cicatrisation around a para-œsophageal tuberculous gland (fig. 156). The diverticulum passes upwards. Food does not enter its open mouth, consequently it gives rise to no symptoms.

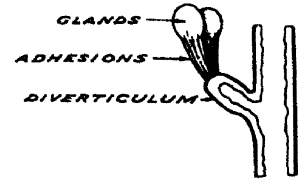

Fig. 156 Traction diverticulum

Œsophageal Varices

The lower end of the œsophagus is one of the principal regions where the portal and systemic venous systems anastomose. Dilatation of these anastomotic channels occur in portal obstruction, notably hepatic cirrhosis. The engorged veins are liable to burst, and the copious vomiting of blood which results must be distinguished from other forms of hæmatemesis.

Bleeding from œsophageal varices tends to cease spontaneously. We have seen a fatal hæmorrhage from these engorged veins in a case of Banti's disease (p. 241). Similar cases have been reported.

SIMPLE TUMOURS OF THE ŒSOPHAGUS

Simple tumours of the œsophagus are exceedingly rare and unimportant. Polypi need mentioning. They are often solitary, and occur in the upper end of the organ. Diathermy excision through an œsophagoscope is a satisfactory method of treatment

PARALYSIS OF THE ŒSOPHAGUS

The passage of food along the gullet is dependent entirely upon involuntary muscular peristalsis. When the neuro-muscular mechanism of deglutition is paralysed, as occurs occasionally, notably as a complication of diphtheria, ingested material is regurgitated. In established cases the difficulty has to be overcome by feeding through a stomach tube.

CHAPTER XIV

THE STOMACH AND DUODENUM

Pyloric Stenosis of Infants (*syn.* Congenital Pyloric Stenosis)

The ætiology is quite unknown. The popular explanation is that the condition arises from an inco-ordination of the neuro-muscular mechanism of the stomach, or that there is achalasia (meaning that there is a primary failure of the sphincter to relax), but such statements leave us unenlightened.

Pathology.—The muscle coats of the stomach are hypertrophied, especially the circular fibres in the region of the pylorus. This hypertrophy terminates abruptly at the

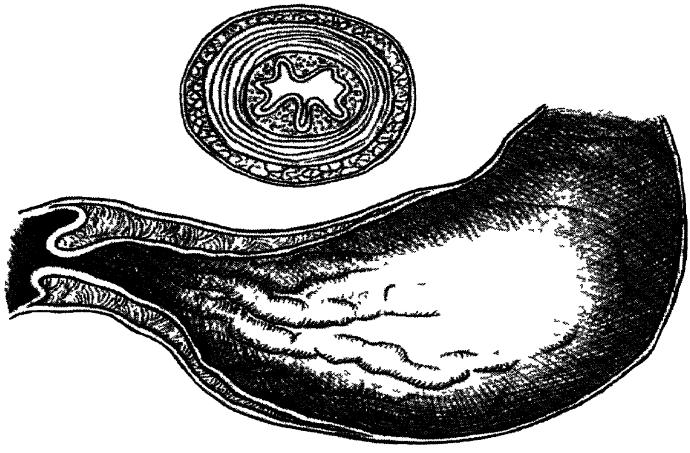

Fig. 157.—Pyloric stenosis of infants Longitudinal and transverse sections of the stomach to show the enormous muscular hypertrophy. Note the abrupt termination.

pylorus, the duodenum being normal. The pylorus, when observed from the duodenal side, has the appearance of a cervix uteri (fig. 157). The mucosa in the pyloric antrum is thrown into many folds ; on transverse section two main longitudinal folds can often be made out. At necropsy the stomach shows mucous catarrh and petechial hæmorrhages,

which are no doubt secondary to the stasis and vomiting. The muscular hypertrophy persists after symptoms have been cured by Rammstedt's operation.

Clinical Features.—The infant, who in 80 per cent. of cases is a male and often the first-born, shows no tendency to vomit until it is *three or four weeks of age*. The vomits are large, and evidently consist of more than the last feed. Within two or three days the vomiting becomes projectile. Constipation and loss of weight naturally follow, and it is not long before the infant begins to look shrivelled. On abdominal examination visible peristalsis can be seen (fig. 158), and there is a palpable tumour (the thickened pylorus) in the right hypochondrium.

FIG. 158.—Visible peristalsis. Pyloric stenosis in an infant.

Treatment.—Rammstedt's operation has proved to be a notable advance. Formerly, under medical treatment, about 80 per cent. of cases died. At the present time nearly 70 per cent. of infants subjected to operation recover. The recovery rate is likely to be still higher when the benefits of early operation are better appreciated.

Rammstedt's Operation.—*Preliminary preparation.*—The stomach is washed out several times, finally one hour before operation. Subcutaneous infusion of 5 per cent. glucose should be given. The infant's body is encased in wool, the upper abdomen alone being accessible.

Operation.—Local anæsthesia supplemented by/or gas and oxygen are the only anæsthetics recommended. The abdomen is opened by a right paramedian incision. An anterior incision is made into the hypertrophied muscle (fig. 159), and separation of the muscle coat is completed with Kocher's dissector until the mucous membrane appears white and glistening in the bottom of the wound. Great care is taken not to penetrate the mucosa, an accident which is liable to occur at the duodenal "fornix" (see fig. 157).

After-treatment.—Further glucose infusions, and in desperate cases blood transfusion, should be given. The feeds must be very small and well-diluted, not more than ʒi being given at a time. The most troublesome and the most fatal post-operative complication is persistent diarrhœa, which is minimised by thorough preparation and very careful after-feeding.



FIG. 159.—Rammstedt's operation.

CONGENITAL OCCLUSION OF THE DUODENUM

There is a septum, usually complete, across the duodenum. This occurs at the point of fusion of the fore and mid-gut, and consequently lies in the neighbourhood of the ampulla of Vater. The infant vomits *from birth*, and daily rapidly loses weight. Laparotomy should be undertaken without delay. Gastro-jejunostomy is theoretically the correct treatment, but it is a formidable procedure in an attenuated infant. Perforation of the septum in the manner illustrated (fig. 160) would probably prove effectual.

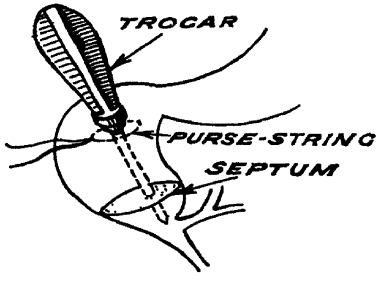

FIG. 160.

FOREIGN BODIES IN THE STOMACH

A variety of ingested foreign bodies reach the stomach. Fortunately, for the most part they are opaque to X-rays. Sharply pointed or large objects are best removed promptly by gastrotomy. Rounded, smaller foreign bodies may be left to pass along the natural passages. Suitable doses of "Normacol" form a gelatinous pabulum, in which the article becomes embedded during its transit along the alimentary tract. That the journey is being accomplished can be verified by periodic examinations under the fluorescent screen.

Hair-ball of the stomach is accorded a prominent place among museum exhibits. The condition has always been rare, and now that most women wear their hair shorter than formerly, gastric hair-ball is exceptional, even among the feeble-minded.

The treatment is removal of the mass by gastrotomy.

ACUTE DILATATION OF THE STOMACH

Acute dilatation of the stomach is not common. It occurs unexpectedly, sometimes after gastric operations,

and at other times after a shock, as might be occasioned with a fractured femur. Occasionally the condition arises idiopathically.

Ætiology.—The stomach suddenly loses its tone, and its musculature becomes paralysed. It is thought by some that the third part of the duodenum becomes compressed and obstructed by the superior mesenteric vessels, but such an explanation is not satisfying.

Clinical Features.—The symptoms, which come on with dramatic suddenness, are those of profound shock accompanied by enormous, effortless vomits. In a well-established case gallons of fluid like dirty water are brought up. It is not always easy to make out the dilated stomach by percussion and palpation, for the greater curvature often extends into the pelvis.

Treatment.—Prompt action is imperative. The patient should be rolled over on to his face, a pillow placed under the pelvis, and the foot of the bed raised on blocks. The correct position is illustrated in fig. 161. Large quantities of saline are then administered rectally or subcutaneously. As soon as a stomach tube can be passed (a small stomach tube is all that is necessary), the contents of the organ are evacuated by aspiration. The tube should be left *in situ* and aspiration repeated at regular intervals. A dose of pituitrin is of value in the early stages, and as the pulse improves the patient may have morphia. The prone position should be maintained for many hours after the crisis has apparently passed.

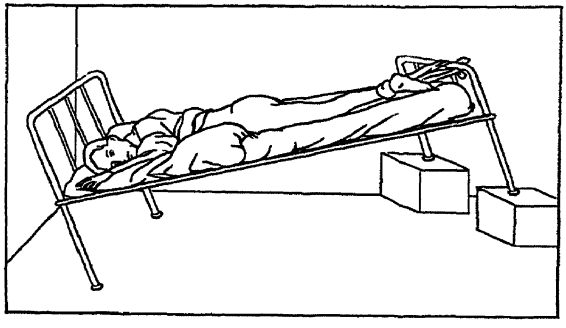

FIG. 161.—Acute dilatation of the stomach. The position to be adopted at the earliest possible moment.

GASTRIC TETANY

Gastric tetany sometimes complicates chronic dilatation of the stomach, and it has been observed on rare occasions after gastric

operations. The spasms are usually confined to the extremities, and attacks are accompanied by dyspnœa and cyanosis. If the stomach is dilated it should be emptied by a stomach tube. Subcutaneous saline is administered. The exhibition of parathyroid extract and calcium salts is also believed to be beneficial.

Gastric Lavage

In nearly all cases in surgical practice where washing out the stomach is imperative the contents of the organ are watery, and consequently they can be aspirated through a tube of

Fig. 162.—Aspirating the stomach.

small calibre. This is far more humane and efficient than employing the usual stomach tube. The patient is instructed to swallow a Ryle's small stomach tube. If he experiences difficulty in so doing the back of his pharynx is cocainised. Once the stomach tube is in place the contents of the stomach are aspirated (fig. 162), and the interior of the organ can be irrigated by way of the tube.

Fig. 163.—Ryle's small stomach tube.

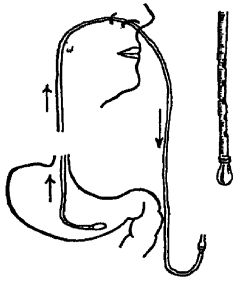

Fig. 164.—Mechanism of continued gastric aspiration. (Inset, Jutte's tube.)

Continuous drainage of the stomach can be performed by using a Jutte's tube (fig. 164), which is introduced through the nose and

held by strapping to the cheek with adhesive plaster. The free end of the tube is connected to some form of suction apparatus. With this tube in place the patient is able to drink copiously without vomiting.

GASTRIC ULCER

Gastric ulcers are of two distinct varieties, acute and chronic. Chronic ulcers are the more common.

Acute Gastric Ulcer

Pathology.—There are multiple small ulcers involving the mucosa only and barely visible to the naked eye. Often it requires the microscope to confirm their presence (fig. 165). They are circular, with sharply cut edges, and situated anywhere in the stomach, but are inclined to be in the fundus.

Fig. 165.—Microscopical appearance of a section through an acute gastric ulcer. Note.—Only the mucous membrane is involved.

Two clinical varieties of *acute* gastric ulcers exist:

(*a*) *As a Special Disease of Young Women* (*syn.* Gastrostaxis, Gastralgia).—While not as frequent as it was twenty years ago, acute gastric ulceration of young women presents a typical clinical picture. There is a history of weeks or months of *constant* dyspepsia. Pain comes on shortly after food, and is localised in the epigastrium. Vomiting is frequent, and affords no relief. Hæmatemesis is a regular accompaniment and the most dangerous symptom. The appetite is poor. The patient is pale, thin, and often presents signs of visceroptosis.

Treatment is medical. Blood transfusion may be required for hæmatemesis. As improvement sets in attention must be directed to the elimination of infected foci, particularly of dental origin.

(*b*) *As a Complication of Disease elsewhere.*—This type of acute ulceration occurs in either sex and at any age. Any severe pyogenic infection, located even far distant from the stomach, for instance, an infected compound fracture, on rare occasions is complicated by acute gastric ulceration. By far the commonest focus is purulent appendicitis. Severe and sometimes fatal hæmatemesis is the leading, if not the only, symptom. We have seen at necropsy an adult male subject who died of hæmatemesis with no demonstrable macroscopic lesion in the stomach or duodenum. In this instance the appendix was full of pus.

Treatment.—The immediate treatment is blood transfusion. When possible the infective focus should be removed.

Chronic Gastric Ulcer

Ætiology.—The cause is usually regarded as an infective focus, possibly associated with thrombosis in the gastric wall, the devitalised area being digested by the gastric juice.

Pathology.—The ulcer-bearing area is shown in fig. 166. The ulcer is frequently situated towards the pylorus or near the lesser curve. Outside this area ulcers are comparatively rare. A chronic gastric ulcer invades the muscular coats of the stomach (fig. 165), which it tends to penetrate. It varies in size, but usually admits the tip of one finger only (fig. 167). On the lesser curvature, ulcers tend to spread from the posterior surface to the anterior surface, giving rise to what is known as the "saddle-back" ulcer.

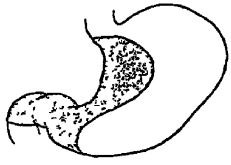

Fig. 166.—The ulcer-bearing area of the stomach and duodenum.

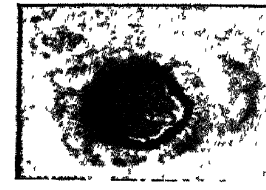

Fig. 167.—A chronic gastric ulcer seen from within. (By permission of Petrolagar Laboratories, Ltd.)

Pathology of the Living.—When viewed at operation that part of the stomach containing a chronic gastric ulcer differs

greatly from what is seen at necropsy. Induration, often extensive, surrounds the ulcer. When rubbed gently, the peritoneum overlying the ulcer becomes speckled as though sprinkled with cayenne, a characteristic phenomenon due to minute petechial hæmorrhages (fig. 169). Delicate vascular adhesions, salmon pink and fluffy in appearance, can often be observed in the immediate neighbourhood of the peritoneal aspect of the ulcer.

FIG. 168.—Portion of a stomach containing a large ulcer removed from a woman of 35, the wife of a bargee. Five years later the patient was in perfect health, following her vocation on the barge.

FIG. 169.—Petechial hæmorrhages around the peritoneal aspect of a chronic gastric ulcer. These become very apparent after gently rubbing the surface with gauze.

Diagnosis.—The diagnosis of chronic gastric ulcer is often difficult. Physical signs are seldom helpful, and reliance must be placed upon a careful history, which in turn is reinforced by an X-ray examination and a fractional test meal. It is not over-stating the case to say that the history is the most important means of arriving at the diagnosis. A barium meal is exceedingly helpful, but the X-ray findings are not always conclusive. Ulcers, particularly on the posterior surface of the stomach, are sometimes not demonstrable with the opaque meal, and we have had numerous cases where a definite ulcer has been reported by the radiologist, but laparotomy showed the stomach and duodenum to be entirely normal.

History.—The patient is usually between 30 and 50 years of age, and men are a little more often attacked than women, the proportion being 3 : 2. By reason of their restricted diet they are usually thin, and he or she is often anæmic. On

careful enquiry certain features of the dyspepsia become manifest. Typically there is :

1. *Periodicity.*—The attacks last from 2 to 6 weeks, and are followed by intervals of freedom from 2 to 6 months. The attacks are more in evidence in the spring and autumn.

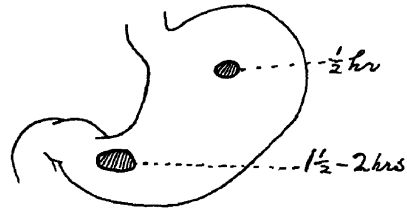

2. *Pain* is epigastric and severe. It bears a definite relationship to the ingestion of food, which varies with the position of the ulcer, viz. :

The longer the ulcer has existed the more does the pain radiate.

3. *Vomiting.*—In over 50 per cent. of cases vomiting is a notable symptom. It relieves the pain, and may be self-induced.

4. *Hæmatemesis and Melæna.*—Approximately 30 per cent. of cases have had hæmatemesis some time during the course of the disease. Melæna is unusual in *gastric* ulcer.

5. *Appetite* is good, but the sufferer is afraid to eat.

6. *Diet.*—The patient avoids meat and certain other foods, which vary with the individual. Milk and fish are the staple diet.

7. *Weight.*—Usually by the time the surgeon is consulted there has been some loss of weight.

It is under these seven headings, preferably in tabular form, that a gastric history should always be recorded.

Radiography after the Barium Meal.—The most characteristic finding is a niche or crater filled with barium (figs. 180 and 182), with spasm of the circular fibres of the stomach in the greater curvature opposite the ulcer. There is a tendency to hypermobility of the organ in uncomplicated gastric ulcer.

The Test Meal.—The nearer the ulcer to the pylorus the higher the free hydrochloric acid gastric content. Although fractional test meals in cases of chronic gastric ulcer show

wide variations, free hydrochloric acid is typically somewhat increased (figs. 170 and 171).

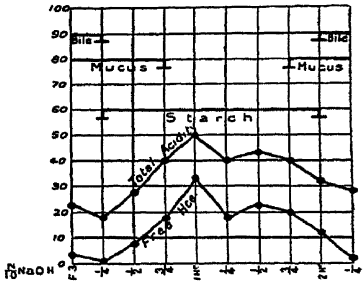

FIG. 170.—Normal fractional test meal.

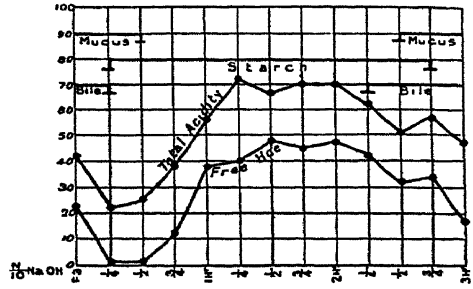

FIG. 171.—Fractional test meal in a case of gastric ulcer. (Muriel Henderson.)

Summarising the findings of a series of test meals it may be stated that :

	Normal.	Gastric Ulcer.
Free HCl	·08–·12	·12–·16
Total acidity	40–60	60–80

Gastro-photography.—The patient swallows a special stomach tube fitted with an ingenious little camera attachment which takes six simultaneous photographs of different aspects of the stomach wall. The photographs of the gastric mucosa thus obtained are at first a little difficult to interpret, but there seems to be no reason why the method should not take an important place in the diagnosis of chronic gastric ulcer (fig. 172).



FIG. 172.—Gastro-photograph of carcinoma of stomach. A, Edge of ulcer; B, Base of ulcer; C, Mucus; D, Papillomatous area. (J. R. M. Whigham.)

Treatment of Gastric Ulcer.—All are agreed that the treatment, in the first instance, should be medical. The indications for surgical treatment of gastric ulcer have undergone variations during the past few years. These indications, apart from acute complications, may be summarised as follows :

1. Frequent relapses after efficient medical treatment.

2. A large penetrating gastric ulcer demonstrable radiologically.

3. Mechanical stenosis to the lumen of the stomach.

4. Considerable hæmatemesis occurring more than once.

The Surgical Treatment of Chronic Gastric Ulcer.—The technique employed varies widely with the position and character of the ulcer and also with the individual operator. Experience has shown that gastro-jejunostomy without attacking the ulcer is seldom effective in the case of chronic gastric ulcer, unless the symptoms are due to a mechanical stenosis of the pylorus. Very briefly, the methods which are employed are as follows :

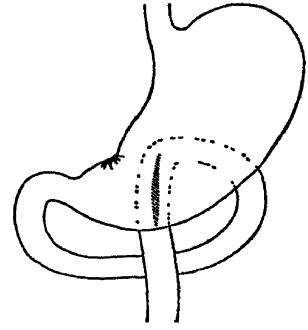

FIG. 173. — Posterior, retrocolic, vertical, isoperistaltic, no-loop gastro-jejunostomy of Mayo (after Sherren).

Gastro-jejunostomy is the operation *par excellence* for cicatricial obstruction of the pylorus. The vertical, no-loop, posterior, isoperistaltic operation is the one usually performed when circumstances permit (fig. 173).

Balfour's Operation.—The ulcer is destroyed with the actual cautery, and the resulting perforation sutured. Gastro-enterostomy is then performed.

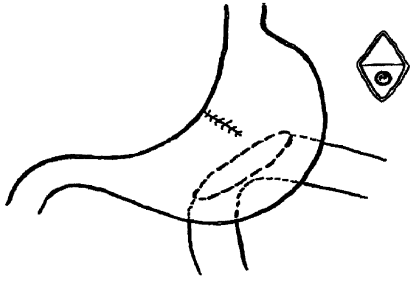

FIG. 174 —Walton's method (Inset) The wedge removed.

Walton's operation is applicable to ulcers on the lesser curvature. After clamps have been applied, a wedge-shaped portion of the lesser curve containing the ulcer is resected. The resulting defect is made good by uniting the cut edges of the stomach. Transverse gastro-jejunostomy is then performed below this line of suture (fig. 174).

Partial gastrectomy is employed almost exclusively in many Continental clinics. It is unquestionably a good method of treating large ulcers in the distal third of the stomach, and it is a method which should always be employed when there is a possibility of a carcinomatous change having taken place in any gastric ulcer, providing always the condition of the patient permits. There are several methods of performing partial gastrectomy.

(*a*) *The Anterior Polya Operation.*—The duodenum is divided in its first part and the distal end is closed with sutures. The necessary portion of the stomach is resected. The continuity of the alimentary

canal is restored by uniting the side of a loop of the commencement of the jejunum to the cut surface of the stomach. The loop of jejunum is brought *in front* of the colon.

(*b*) *The Posterior Polya Operation.*—Similar to the above but instead of the jejunum being brought in front of the colon the loop is made to pass through an incision in the mesocolon (fig. 175).

(*c*) *Billroth No* 1.—It is partial gastrectomy with gastro-duodenal end-to-end anastomosis. This method has been revived by Schoemaker. The duodenum is divided between forceps immediately beyond the pylorus. Schoemaker's or Morley's twin crushing clamp is then applied to the lesser curve (fig. 176), and the portion



FIG. 175.—Partial gastrectomy. The posterior Polya operation nearing completion.

FIG. 176.—Schoemaker's operation with Morley's clamp. (Morley.)

of the stomach "A" is removed. One pair of blades of this dual clamp having been removed, the cut edges of the lesser curve are easily repaired with sutures, while the portion of the stomach at "B" is anastomosed with the cut edge of the duodenum by the end-to-end method. The reconstruction of the stomach in this operation is very anatomical.

(*d*) *Old-type Billroth No.* 2 is resection of the necessary portion of the stomach with closure of the duodenal stump and the cut surface of the stomach respectively. Gastro-jejunostomy is then performed.

Cholecyst-gastrostomy.—The fundus of the gall-bladder is anastomosed to the anterior wall of the stomach, and bile pours into it, neutralising the free hydrochloric acid. The operation, which should be combined when possible with destruction of the ulcer, is useful in inaccessible ulcers, such as those high in the stomach, and when the general condition is poor.

Temporary Jejunostomy.—For large, inaccessible ulcers in enfeebled patients jejunostomy is warmly advocated by some. The patient is fed through the jejunostomy tube, which permits physiological rest of the stomach. The measure is hardly to be looked upon as curative, but as a preparation for more radical treatment.

Complications of Gastric Ulcer

Acute. { **Perforation.**
Severe hæmatemesis.

It has been estimated that 5 per cent. of patients with chronic gastric ulcer die of severe hæmatemesis, and another 15 per cent. succumb to perforation.

Intermediate. Perigastric abscess.

Chronic. { **Stenosis** < Pyloric stenosis. / Hour-glass contraction.
Penetration into neighbouring viscera, notably the pancreas.
Carcinoma.

ACUTE COMPLICATIONS OF A CHRONIC GASTRIC ULCER

Perforated Gastric Ulcer

The floor of the ulcer gives way (fig. 177); the stomach content gushes forth into the peritoneal cavity. At this moment the victim cries out in agony, and at any rate if the perforation is a large one and the stomach is full, he is riveted temporarily to the spot where the perforation felled him. Examination shortly after this catastrophe reveals a pale, anxious individual obviously in great pain. The temperature is somewhat subnormal, and *the pulse-rate frequently in the neighbourhood of* 80 *or* 90; although there are exceptions, we are satisfied that in a large number of instances during the first six hours the pulse-rate is comparatively unaltered. The upper abdomen of a thin subject will be seen to be scaphoid, and it moves little or not at all with respiration. The palpating hand at once recognises an abdominal rigidity which is general and board-like. The whole abdomen is tender and inclined to be dull to percussion. In a small percentage of cases, where there is an escape of

Fig. 177.—Perforated gastric ulcer (mucosal aspect). (R C.S. 6221.1.)

gas from the stomach into the peritoneum, the normal liver dullness in the mid-axillary line is diminished. A rectal examination sometimes reveals tenderness in the recto-vesical pouch.

After six or eight hours the physical signs change gradually to those of general peritonitis. The abdomen slowly distends and the intense rigidity may pass off. By this time enough free fluid has collected in the peritoneum for shifting dullness to be elicited. Just *before* the sixth hour there is sometimes a period of temporary improvement in the general condition. This has been termed "the period of illusion." After the sixth hour the pulse-rate gradually increases, and with each passing hour, and later still even with each passing quarter of an hour, the chances of recovery grow more slender.

Treatment.—Immediate operation is the only course. Laparotomy is performed, and the perforation sutured (fig. 178). In large perforations it is well to reinforce the suture line with a patch of omentum. Suprapubic drainage of the peritoneum is usually advisable. The immediate after-treatment consists of saline infusions, and as soon as the patient awakens from anæsthesia he should be placed gradually in Fowler's position. See also perforated duodenal ulcer, p. 226.



FIG. 178.—Closing the perforation in a perforated gastric ulcer. The first stitch is often placed a little away from the perforation in order that it may get a good hold.

SEVERE HÆMATEMESIS AND MELÆNA

Chronic gastric ulcer is a common but by no means the only cause of severe hæmatemesis. To avoid repetition the whole question of severe hæmatemesis and melæna will be briefly outlined here.

Severe hæmatemesis can arise :

1. From acute gastric erosions, which are considered under the heading of acute gastric ulcer (see p. 212).

2. From erosion of a vessel in the wall of a chronic gastric ulcer, or (rarely) a carcinoma.

3. From rupture of an œsophageal varix (p. 206).

Type 2 is more commonly seen in men.

Severe melæna is a frequent accompaniment of chronic duodenal ulcer. The patient evacuates almost black stools.

In each of these conditions the patient often faints, and shows signs of a considerable loss of blood.

Treatment.—Everything by mouth is withheld. Morphia is administered in suitable doses, and tap-water given slowly per rectum. Arrangements for blood transfusion should be made, so that this measure can be undertaken immediately if necessary. In hæmorrhage occurring **from acute gastric ulcers,** operation is never indicated. Trust is placed entirely in blood transfusion, if necessary repeated. This is nearly always successful.

The immediate treatment of severe hæmorrhage **from a chronic ulcer** is a difficult problem. In most instances it is wise to follow the medical regime, combined with blood transfusion, but in individual cases, where the symptoms point to an erosion of a large vessel, it is sometimes advisable to operate soon, or even immediately. The type of operation which is likely to prove the means of saving most lives is a direct attack upon the ulcer in the shape of opening the stomach and inserting sutures so as to obliterate the ulcer and thus compress the bleeding vessel.

For a severe melæna **from duodenal ulcer** the same conservative attitude is always adopted, but operation is advised a week or ten days after the critical stage has passed.

INTERMEDIATE COMPLICATIONS

PERIGASTRIC ABSCESS

Perigastric abscess is nearly always due to perforation of the stomach or duodenum. A tender swelling appears in the epigastrium, and an elevation in temperature is usual. All that is necessary in the first instance is to drain the abscess, but a gastric or duodenal fistula not infrequently results.

CHRONIC COMPLICATIONS (SYN. SECONDARY CHANGES) OF A CHRONIC GASTRIC ULCER

Pyloric Stenosis

There is a history of pyloric ulcer, with the following modifications:

Periodicity is lost, and pain becomes constant.

Pain comes on immediately after food, and remains as a constant heavy discomfort, with attacks of colic due to excessive peristalsis.

Vomiting.—Very large vomits are characteristic. They usually occur once a day, commonly in the evening. Classically the patient recognises currants ingested one or more days previously. Vomiting does not entirely relieve the discomfort.

On Examination.—In thin subjects with considerable stenosis of the pylorus the outline of the full, dilated stomach can sometimes be observed. Visible peristaltic waves passing from left to right are characteristic, but indicate that surgical treatment has been postponed already too long.

X-ray.—The stomach is large and low, and takes hours to empty.

The test meal is inclined to register an increased total acidity due to fermentation. There may be a decrease in free hydrochloric acid.

Treatment.—After adequate preparation with gastric lavage a well-performed gastro-jejunostomy gives entirely satisfactory results.

Hour-glass Stomach

is practically confined to women, and it occurs from cicatricial contracture around a saddle-shaped lesser-curve ulcer. In extreme cases the stomach is divided into two compartments, united by a channel which barely admits a pencil. The condition is sometimes associated with pyloric stenosis.



Fig. 179.—Hour-glass contracture of the stomach in a woman of 60. Gastro-gastrostomy performed successfully.

History.—*Periodicity* is lost. The symptoms have become practically constant.

Vomiting is more frequent, and gives no relief to the pain.

The *appetite* becomes poor.

Weight.—Loss may be so great that carcinoma is suspected.

The X-ray is often very characteristic (fig. 179). We have known cases of hour-glass stomach reported as pyloric stenosis, owing to failure of the

second pouch to fill. True hour-glass stomach must be distinguished from gastric spasm of the hour-glass type, which is sometimes associated with an uncomplicated ulcer on the lesser curvature.

The test meal shows a very low acidity.

Treatment.—Surgical treatment is eminently satisfactory, and any operation which relieves the mechanical interference to the passage of food cures the patient. The simplest of these is gastro-gastrostomy, which, if there is associated pyloric stenosis, must be combined with a gastro-jejunostomy into the second pouch. Partial gastrectomy, with removal of the second pouch and the isthmus, also gives good results, but no better than the less severe procedure just indicated.

Adherence of the Ulcer to the Pancreas (fig. 180) and Penetration into It

is a common complication of ulcers on the posterior wall of the body of the stomach. It appears to be more common in England than in America.



Fig. 180.—Large penetrating ulcer on the lesser curvature. It had penetrated into the pancreas. Successful resection.

History is one of chronic gastric ulcer with the following modifications:

Periodicity tends to be less definite, in that the intervals of freedom are short or absent.

Pain passes to the back or the left shoulder.

X-ray.—If there is a definite filling defect in this region the diagnosis is certain.

Treatment.—Partial gastrectomy is usually recommended. We have had considerable success in a number of cases by dissecting the adherent stomach free from the pancreas. This leaves a perforation on the posterior stomach wall. The perforation is sutured, and an oblique or transverse gastro-jejunostomy performed (a vertical stoma is usually impracticable).

Development of Carcinoma in the Ulcer

Cancer undoubtedly develops in some long-standing cases of chronic gastric ulcer.

The frequency of this complication has been so variously estimated as to bring ridicule upon surgical statistics. We do not know what percentage of chronic gastric ulcers eventually

become carcinomatous, but we do know that in the long run this complication is second to none as a menace to life.

History.—*Periodicity.*—The last attack has continued much longer than usual, and there was no remission.

Pain is constant, but not so severe as formerly, and it is unrelieved by any form of treatment.

Vomiting does not relieve the pain, and sometimes takes the form of regurgitation of foul material, or "coffee grounds."

Appetite is lost.

Weight.—The patient tends to lose weight rapidly.

X-ray shows nothing characteristic until the case is hopelessly advanced.

Test meal tends to have a low free hydrochloric acid content. Absence of free hydrochloric acid is a frequent finding in advanced cases.

Carcinoma of the stomach is discussed on p. 230.

Chronic Duodenal Ulcer

In men, duodenal ulcer is considerably more common than gastric ulcer, the proportion being about 7 to 1. In women the incidence of the two types of ulcer is about equal. Gastric and duodenal ulcers can exist concomitantly.

Pathology.—The ulcer is always situated in the supra-papillary portion of the duodenum, and very frequently on the anterior surface of the first inch of the duodenum, which accounts for the great liability of these ulcers to perforate. It is sometimes difficult to say if a given ulcer is gastric or duodenal. The veins of Mayo (fig. 181) are a helpful landmark: an ulcer situated to the right of these veins must be a duodenal ulcer.

Fig. 181.—The veins of Mayo.

Ætiology.—The ætiology is closely allied to that of gastric ulcer. Recurrent or chronic appendicitis, dental sepsis, and excessive cigarette smoking are clearly associated with chronic duodenal ulceration.

History.—*Periodicity* is usually well-marked. Attacks last from 2 to 6 weeks, with intervals of freedom from 1 to 6 months.

Pain is severe, and may double the patient up. It occurs 2 to 2½ hours after food. As it is often relieved by

food, the pain is known as "hunger pain," and classically the patient carries biscuits, which he eats at frequent intervals to prevent this gastric torment. The pain, which is also relieved by alkalis, often awakens the patient at night or in the early hours of the morning.

Vomiting is *very rare* in duodenal ulceration unless stenosis has occurred.

Melæna is one of the most dangerous complications; hæmatemesis occurs rarely.

Appetite is exceptionally good, but the patient often refrains from eating meat.

Weight.—There is usually no loss of weight; indeed, the patient often tends to become plump.

On examination it is not unusual to find localised deep tenderness in the right hypochondrium.

The X-ray shows the stomach to be normal. There is a tendency to hypermobility. The duodenal cap may be distorted, and a filling defect is good evidence of an ulcer.

The test meal shows hyperchlorhydria.

Treatment of Duodenal Ulcer.—The difficulties of treating chronic duodenal ulcer are not less than those of the sister lesion in the stomach. Again, medical treatment is always



FIG. 182.—Duodenal ulcer giving rise to pyloric stenosis. There is also an ulcer on the lesser curve of the stomach. (M. Jupe.)

advised in the first instance, and treatment with intensive alkali medication, with the patient in bed, is often very successful. Appendicectomy, in addition to medical treatment, sometimes aids the latter by eliminating a contributory cause. Surgical treatment is indicated :

1. In long-standing cases where there is delayed emptying of the stomach (fig. 182).
2. Where serious melæna has occurred.
3. When there have been frequent relapses after efficient medical treatment.

The Operative Treatment of Duodenal Ulcer.—Unanimity of the type of operation is not universal. The following procedures are advocated and practised by various exponents :

Gastro-jejunostomy is the most popular method of treatment in Britain. A well-performed gastro-jejunostomy gives excellent results. Its chief drawback is the occasional occurrence of gastro-jejunal ulcer. The appearance of this troublesome complication occurs in not more than 2 per cent. of cases, and usually in those patients with a very high free hydrochloric acid gastric content with hypermobility of the organ. If medical treatment were persisted in to its utmost limit in such cases, the occurrence of gastro-jejunal ulcer would probably be less.

Gastro-duodenostomy.—The first and second parts of the duodenum are mobilised, and the second part of the duodenum is united to the anterior part of the stomach. There are several variations in technique, for details of which the reader must be referred to works on operative surgery.

Partial duodeno-gastrectomy is performed in some Continental clinics as almost the routine for duodenal ulcer. It is claimed that excision of that portion of the stomach which contains the majority of the oxyntic cells is curative.

Duodenectomy.—Excision or resection of the supra-ampullary portion of the duodenum is advocated by a small group of surgeons. The technical difficulties of this method have prevented its general application.

Perforated Duodenal Ulcer

Perforated duodenal ulcer (fig. 183) is much more common than perforated gastric ulcer. The initial symptoms are identical with those of perforated gastric ulcer. When a perforation is a comparatively small one the escaping fluid is often directed to the right iliac fossa by the ascending colon, which acts as a watershed. The symptoms then simulate closely those of acute perforated appendicitis.

Treatment is immediate operation and suture of the perforation. In cases where there is stenosis and the patient's condition is good, an immediate gastro-jejunostomy is sometimes advisable. In most cases it can be deferred.



FIG. 183.—Colour photograph of a stomach removed shortly after death from perforated duodenal ulcer. The patient collapsed in the street and died a few minutes after admission to hospital. The intense congestion is due to chemical (gastric juice and food) peritonitis. It is most exceptional for the patient to die shortly after perforation of a peptic ulcer. He usually recovers from the initial shock and, unless the perforation is sutured, dies from *bacterial* peritonitis 3 or 4 days later.

In all but very early perforations the peritoneal cavity should be drained, and, especially in perforations of over twelve hours' duration, an additional drainage tube coming out in the right flank, designed to drain Rutherford Morison's pouch, is sometimes required.

CONDITIONS WHICH MIMIC CHRONIC PEPTIC ULCER

1. Gastroptosis.
2. Appendicular Dyspepsia.

Gastroptosis is the great imitator of chronic gastric ulcer. In contradistinction to the latter, periodicity of attacks is usually lacking. The symptoms tend to be constantly present week in and week out; also the appetite is inclined to be

poor. In spite of these differences, it must be admitted that in some cases the symptoms which gastroptosis produces are identical with those of chronic gastric ulcer.

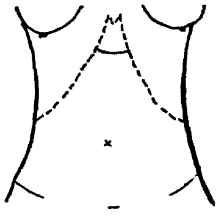

FIG. 184.—Narrow subcostal angle as found in cases of gastroptosis.

On Examination.—Gastroptosis should be suspected if the patient has a narrow subcostal angle (fig. 184). In suspected cases, Rovsing's sign should be applied. The epigastrium is viewed tangentially. If the beating aorta can be seen to cause epigastric pulsation, the sign is positive. Visible pulsation signifies that that cushion-like structure the stomach has slipped down, and has left bare the aorta beneath the abdominal wall. Rovsing's sign is one in which we place the greatest confidence.

Test meal usually shows hypochlorhydria. Especially in gastroptotic females there is sometimes complete absence of free hydrochloric acid.

Barium meal reveals the ptosed state of the stomach. It is not unusual for the lesser curvature to be well below the level of the umbilicus (fig. 185).

Treatment.—A well-fitting abdominal belt is often helpful. In a few cases, in order to eliminate definitely the possibility of a gastric ulcer or carcinoma, laparotomy must be undertaken. In others, where the symptoms are pronounced and a neurasthenic element can be eliminated, laparotomy is undertaken with the sole idea of a corrective operation, which is often followed by amelioration of symptoms. Many methods of suspending the stomach have been devised. Pauchet's operation is simple and effective.



FIG. 185.—Profound gastroptosis. From an X-ray.

Pauchet's Operation.—The round ligament of the liver is divided near its attachment to the abdominal wall. Its connection with the falciform ligament having been freed, the free end of the round ligament is attached by sutures to the lesser curvature of the stomach. Later the patient is ordered an abdominal belt which can be expected to hold up a solid organ like the liver, which in turn now supports the stomach.

Appendicular dyspepsia is another great imitator but this

time of chronic *duodenal* ulcer. Many of the symptoms of appendicular dyspepsia are clearly due to an associated duodenitis, and bleeding from the duodenal mucosa sometimes occurs in these cases. The patient is often cured entirely by the removal of the appendix, which in genuine cases is demonstrably diseased, and often contains pus.

The Complications of Gastro-jejunostomy

A cynical French observer wrote on "Gastro-enterostomy—a disease!" That there have been too many complications following this operation there can be no doubt. Notwithstanding the hypercritical attitude of some towards gastro-jejunostomy, this operation has brought much relief to large numbers of suffering mankind.

The following are the leading complications of gastro-jejunostomy:

Recent	1. Post-operative hæmorrhage. 2. Acute dilatation of the stomach. 3. Vicious-circle vomiting.
Remote	4. Gastro-jejunal ulcer. 5. Jejunal ulcer. 6. Gastro-jejunal-colic fistula. 7. Retrograde intussusception.

POST-OPERATIVE HÆMATEMESIS

The bleeding usually comes from a vessel in the posterior line of suture. This complication has been almost completely circumvented by loosening the clamp, and observing the posterior suture line before completing the anastomosis. On rare occasions the post-operative hæmatemesis can arise from the ulcer.

The treatment closely follows that of severe hæmatemesis of the usual variety. It is sometimes necessary to reopen the abdomen to suture the bleeding vessel.

VICIOUS-CIRCLE VOMITING

During the first forty-eight hours after gastro-jejunostomy there is often a certain amount of regurgitant vomiting of bile, no doubt due in part to the local paresis set up by the operative trauma. After forty-eight hours repeated vomiting suggests mechanical obstruction, and if it persists into the third day a serious view must be taken of the case. Vicious-circle vomiting was frequent in the days of the long-loop anterior gastro-jejunostomy. It occurs occasionally in the posterior operation, when the stoma is badly placed, or the opening in the transverse mesocolon is inadequate.

When gastric lavage and other conservative measures fail to stop the vomiting, the abdomen must be reopened, and the efferent and afferent loops of the gastro-jejunostomy anastomosed.

Gastro-jejunal Ulcer (*syn.* **Anastomotic Ulcer**).—A new ulcer at the site of the anastomosis is the bugbear of gastro-jejunostomy. It is found in perhaps 2 per cent. of all cases of this operation, but is distinctly less frequent since catgut has been used as a suture material instead of silk. Gastro-jejunal ulcer is not entirely limited to patients who have had gastro-jejunostomy performed, for it occurs occasionally after partial gastrectomy.

Anastomotic ulcer appears to occur most frequently after operations upon cases of duodenal ulcer with a very high free hydrochloric acid content.

The symptoms are almost identical with duodenal ulcer, except that the patient frequently vomits and pain is referred to the left side. These ulcers sometimes perforate, and indeed are liable to all the complications of the primary ulcer, except carcinoma.

The treatment is difficult. Relapses are usual after medical treatment. Excision of the anastomosis and repair of the organ so as to reconstitute normal anatomy is less formidable than secondary partial gastrectomy, but both procedures have their place in the surgery of this troublesome condition.

Jejunal ulcer is far less common than the foregoing. Sherren insisted that jejunal ulcer was the result of using a clamp upon the jejunum during gastric operations. A jejunal clamp is unnecessary.

Gastro-jejunal-colic fistula is a complication of gastro-jejunal ulcer. The ulcer penetrates and erodes the transverse colon. In addition to the symptoms of anastomotic ulcer, the unfortunate patient eructates foul gas, and even vomits fæces, and wastes with great rapidity. The only treatment is to undo the anastomosis and excise the fistula. This is one of the most difficult operations in surgery.

Gastro-jejunal intussusception is a curiosity. The jejunum becomes intussuscepted into the stomach through the anastomosis. The treatment is to effect reduction.

GASTRIC NEOPLASMS

Carcinoma of the Stomach

While carcinoma of the duodenum is exceptional, carcinoma of the stomach is one of the captains of the men of death. Four thousand persons die annually from this disease in Britain, and nine thousand in America (Sherren). Males are twice as often affected as females.

Ætiology.—Certain clinical facts throw some light upon the frequency with which the stomach is attacked. As gastric cancer does not occur in animals, and as negroes are almost exempt, it is reasonable to argue that highly civilised man, by pouring hot, semi-solid, and fluid nourishment into the stomach. is subjecting his gastric mucosa to a form of repeated irritation which predisposes to malignancy.

Pathology.—*Microscopically.*—The growth is usually columnar-celled, but cubical, and even squamous-celled neoplasms arise near the œsophageal orifice.

Macroscopically. — 1. *Encephaloid* carcinoma usually arises on the *lesser curvature*, viz. : ——————→

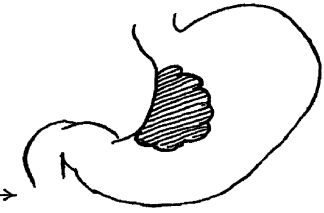

Such growths have a tendency to break down and bleed. More rarely, an encephaloid growth commences on the *greater curvature*, viz. :—→ and in spite of its malignant nature, the prognosis is not always so bad as might be expected, for it gives rise early to a palpable tumour. Hence the aphorism, "A palpable tumour of the stomach is not necessarily a sign of inoperability." Fig. 186 illustrates a case in point.

2. *Scirrhus* is a common form of gastric cancer. It

FIG. 186.—Specimen obtained by partial gastrectomy in a man of 71. The growth gave rise to a palpable tumour. The patient was alive and well one year after the operation.

frequently occurs in the region of the pylorus and antrum, but is not unusual in the cardia.

3. *Atrophic Scirrhus.*—The bulk of evidence favours the view that what is known as a "leather-bottle" stomach (p. 233) is an atrophic scirrhous carcinoma.

The Spread of Gastric Cancer.—No better illustration of the various modes by which carcinoma spreads can be taken than the case of the stomach.

(*a*) *Direct Spread.*—As the growth enlarges, it tends to invade neighbouring viscera. The pancreas and transverse colon are the usual organs involved.

(*b*) *Lymphatic spread :*

1. *By Emboli.*—Small clumps of carcinoma cells are swept along the lymphatic vessels, to become arrested in the neighbouring lymphatic glands.

2. *By Permeation.*—Carcinoma cells grow along the lumina of the lymphatic vessels. At operation lymphatic vessels, enlarged and white from contained neoplasm, can sometimes be demonstrated.

(*c*) *Spread by the Blood-stream.*—Minute portions of the growth are carried by the venous system to the liver and other distant organs.

(*d*) *Transcœlomic Implantation.*—Carcinoma cells sometimes fall from the stomach into the peritoneal cavity. They gravitate to the pelvis, and in the female alight upon the ovaries, giving rise to **Krukenburg's tumours,** which are sometimes an occasion for diagnostic confusion.

(*e*) *Alimentary Propulsion.*—It is possible for a portion of carcinoma to be cast off into the stomach and carried down the alimentary canal, thereafter to become implanted, say, in the rectum. This method of spread is exceedingly rare, and some deny that it ever takes place.

Clinical Features.—(*a*) *Carcinoma of the Body of the Stomach.*—Three clinical types are met with in practice :

(1) *Acute Onset.*—In 10 per cent. of cases the onset of symptoms is abrupt, being ushered in with a short history of acute indigestion, sometimes complicated by hæmatemesis, or even perforation. A wise clinician always assumes that every case of rapidly oncoming dyspepsia, which is not relieved after two weeks' medical treatment in bed, in a patient over the age of 45, is one of carcinoma of the stomach, until it has been definitely proved that it is otherwise.

(2) *Insidious Onset.*—The patient feels tired and weak. There is probably some epigastric discomfort, but pain is not a leading symptom. Anorexia is the cardinal symptom in these cases. This type simulates closely pernicious anæmia. Carcinoma of the stomach is frequently mistaken for pernicious anæmia, and *vice versa.*

(3) *Secondary to a Chronic Gastric Ulcer.*—After years of typical attacks of symptoms of chronic gastric ulcer the symptoms change. The clinical features of this variety have been discussed on p. 223.

(*b*) *Carcinoma of the Pylorus.*—The symptoms are identical with those of simple pyloric stenosis, and the only feature favouring a malignant origin is a comparatively short history.

(*c*) *Carcinoma of the cardiac end of the stomach* often simulates closely œsophageal obstruction, from which it must be differentiated by X-ray examination and œsophagoscopy.

X-ray and Barium meal (fig. 187) frequently reveal a deformity in the outline of the stomach or a filling defect.

Fractional Test Meal.—Achlorhydria is the rule in advanced cases. A low acidity is suggestive but not confirmatory evidence of a gastric neoplasm.



FIG. 187.—Carcinoma of the stomach. Radiograph showing a large filling defect.

Treatment.—There is no curative treatment except partial gastrectomy, and this is possible only when the growth is not fixed or confined to the left half of the stomach, and when there are no secondary glands beyond those in the immediate vicinity of the stomach. Total gastrectomy has been practised successfully on rare occasions. Even in fully operable cases, recurrence after several months or years is common.

LEATHER-BOTTLE STOMACH (*syn.* LINITIS PLASTICA ; GASTRIC FIBROMATOSIS)

There is a generalised and localised form of leather-bottle stomach.

When localised, it is the pyloric antrum which is mainly involved. The stomach wall is enormously thickened (fig. 188), and feels, as its name implies, like leather. The mucosa in specimens we have examined appears quite normal. Microscopically there is an enormous overgrowth of fibrous tissue in the subserosa and submucosa, which sometimes spreads between the muscle fibres and strangulates them. The blood-vessels show evidence of endarteritis. It is usually difficult or impossible to find any evidence of carcinoma, even in serial sections, but secondaries are sometimes to be found

FIG. 188.—Leather-bottle stomach, showing the enormous thickening of the stomach wall.

in the regional lymph glands. While the consensus of opinion favours the view that leather-bottle stomach is always an atrophic scirrhous carcinoma, some consider that the condition is due to syphilis, or other chronic inflammations.

The symptoms are those of pyloric obstruction, and the small capacity of the stomach on X-ray examination makes the diagnosis tolerably certain.

Treatment. — In the localised variety partial gastrectomy offers hope of prolonging life, and even of a cure, but recurrence is unfortunately only too common.

SARCOMA OF THE STOMACH

Sarcoma of the stomach is very rare, and is usually mistaken for carcinoma until a histological examination has been made.

There are three main varieties:

1. Round or spindle-celled, from the submucosa.
2. Fibrosarcoma, from the subserosa.
3. Lymphosarcoma.

The prognosis is not always as hopeless as one might expect. Indeed, there are several reported cases of cures after partial gastrectomy. Type 2 is a comparatively benign growth, and sometimes gives rise to a tumour of immense size, which is mistaken for an ovarian cyst.

BENIGN TUMOURS OF THE STOMACH

Benign tumours of the stomach are rare and unimportant. Myomata, fibromata, and adenomata are found from time to time. The last sometimes gives rise to intussusception of the stomach. Diffuse polyposis of the gastric mucosa infrequently occurs, and is usually mistaken for carcinoma until a histological examination has been made.

Angiomata and lipomata of the stomach are pathological curiosities.

OTHER SURGICAL CONDITIONS OF THE STOMACH AND DUODENUM

Acute Phlegmonous Gastritis (*syn.* **Acute Suppurative Cellulitis of the Stomach**).—Acute phlegmonous gastritis is due to a streptococcal infection of the submucosa of the stomach. There is a generalised and localised form of the disease. In the acute generalised form the diagnosis of acute pancreatitis or perforated gastric ulcer is usually made.

The condition is nearly always fatal, but an attempt should be made to deliver the stomach on to the surface and fix it into position, and then drain the submucosa by multiple incisions passing through the muscle coat.

The localised form, when situated near the pylorus, has been treated successfully by partial gastrectomy.

Volvulus of the Stomach.—Axial rotation of the whole stomach is an exceptional emergency. Successful cases of untwisting the organ are on record.

Curling's ulcer (*syn.* **duodenal ulcer following burns**) is an acute ulcer in the first part of the duodenum, which in exceptional cases follows extensive cutaneous burns or scalds. The ulcer is small, clean cut, and deep. The cause is probably an infected embolus from the burnt area.

If perforation occurs, the treatment is similar to that of any perforated duodenal ulcer.

Chronic duodenal ileus is a rare condition, and the symptoms are akin to pyloric stenosis. The duodenum is found considerably dilated up to the point where the superior mesenteric vessels cross it.

Duodeno-jejunostomy will cure those cases in which the diagnosis is established definitely.

Duodenal diverticulum, which is usually congenital, is liable to become inflamed, when it gives rise to symptoms like appendicitis or cholecystitis. The diverticulum sometimes causes obstruction by pressure upon the common bile-duct or upon the duodenum itself. The presence of a diverticulum is suggested by X-ray appearances.

The treatment in cases with symptoms is excision of the structure.

Traumatic rupture of the duodenum is a rare accident, usually the result of a blow on the right flank. The rupture may be intra- or extraperitoneal, or both.

Intraperitoneal Rupture.—The tear can usually be sutured.

Extraperitoneal Rupture.—The initial symptoms are often slight, and the condition is overlooked until an abscess forms. When such an abscess is opened a duodenal fistula results.

Duodenal fistula follows the opening of an abscess associated with a perforation of the duodenum. This perforation is usually connected with a duodenal ulcer, but may arise as a complication of traumatic rupture of the duodenum or perforation of a duodenal diverticulum. The duodenal contents well up on to the surface, and pancreatic enzymes soon digest and excoriate the skin.

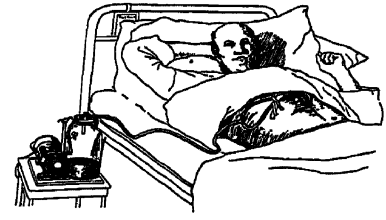

FIG. 189.—Suction apparatus used in a case of duodenal fistula. (Cameron.)

Treatment. — Continuous suction (fig. 189) is sometimes very successful, for it removes the digestive ferments, and permits the wound to heal. Especially in traumatic cases, where the deficiency in the wall of the duodenum is considerable, pyloric occlusion combined with gastro-jejunostomy prevents starvation and puts the fistula at rest.

CHAPTER XV

THE SPLEEN AND LIVER

THE SPLEEN

FROM the surgical standpoint the spleen may be said to have two pedicles—the gastro-splenic omentum and the lieno-renal ligament ; the splenic artery and vein lie in the latter (fig. 190).

SPLENECTOMY

A left paramedian incision is made and the organ located. If it is adherent to the diaphragm the operation is difficult,

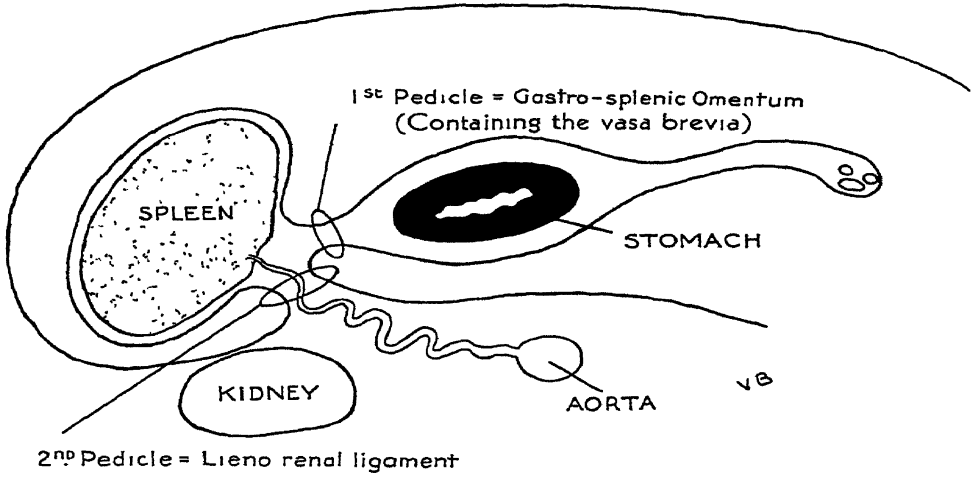

FIG. 190.—The spleen has two pedicles. The splenic vessels lie in the lieno-renal ligament.

and excessive adhesion of an enlarged organ, such as is sometimes found in advanced Banti's disease, is reasonable justification for abandoning splenectomy. Division of adhesions is effected at the expense of the diaphragm rather than of the splenic capsule. Once the organ is free, its pedicle is identified. The gastro-splenic omentum is

divided between ligatures. The main pedicle (the lieno-renal ligament) having been grasped between the fingers, it is divided little by little, clipping, then cutting, until the organ is removed. This technique does away with the necessity for mass ligature where, as it were, all the eggs are placed in one basket, and it minimises considerably the possibility of wounding the tail of the pancreas.

Physiological Effects of Splenectomy

1. **Spleniculi (Miniature Spleens) Hypertrophy.**—It is not uncommon to find in the gastro-splenic omentum of a normal subject one, two, or even three spleniculi. After the spleen has been removed these tiny spleens enlarge. A case is on record where, some years after splenectomy, the dimensions of a hypertrophied spleniculus rivalled those of a normal spleen.

2. **Bone Marrow changes its Character.**—Within six months red marrow replaces yellow marrow in many of the long bones (Rendle Short). This accounts for fleeting bone pains "like rheumatism," which are sometimes a matter of serious concern to the patient.

3. **Changes in the Blood.**—*Initial Changes*:

(*a*) Leucocytosis.
(*b*) Decreased red blood-corpuscles.
(*c*) Diminution in hæmoglobin.
} These changes are maximal between two weeks and two months.
(*d*) Increased coagulability.

After two months lymphocytosis is invariable, and is independent of the cause for which the spleen was removed.

After many months there is moderate eosinophilia, and the mast cells increase in number.

Experimentally, in the splenectomised animals it has been shown that there are alternating periods of hæmatogenesis and hæmatogenous jaundice; hinting that there may be an interaction between the liver and spleen in the construction and destruction of red blood-corpuscles (Whipple and Hooper).

4. **There is more iron in the tissues** (Hill and Flack).

Rupture of the Spleen

Cases of ruptured spleen may be conveniently divided into three groups:

1. **The Patient succumbs rapidly, never rallying from the Initial Shock.**—This type is rare in temperate climates; only complete avulsion of the spleen from its pedicle gives rise to the symptoms which characterise this group. In countries where malaria is rife, splenic rupture is often rapidly fatal,

and advantage has been taken of this knowledge by murderers in China, who achieve their end by digging the victim beneath the left ribs with an implement known as the larang (fig. 191).

Treatment is usually impracticable.

2. **Initial Shock, Recovery from Shock, Signs of a Ruptured Spleen.**—This is the usual type seen in surgical practice. After the initial shock has passed off there are signs which point to an intra-abdominal disaster, and by correlating these signs it is often possible to arrive at a correct preoperative diagnosis.

FIG. 191.—A larang, which, being interpreted, means "forbidden."

General Signs.—There are signs of internal hæmorrhage, but it must be emphasised that classical signs are inconstant. Perhaps the most helpful is increasing pallor; a rising pulse-rate may also be of value.

Local Signs.—(*a*) Abdominal rigidity is present in more than half the total cases. It is most pronounced over the left upper abdomen.

(*b*) Local tenderness is found constantly.

(*c*) Shifting dullness in the flanks is often present.

Ballance's sign is said to be pathognomonic of splenic rupture. There is a dull note in both flanks, but on the right side it can be made to shift, whereas on the left it is constant. The interpretation is that there is blood in the peritoneal cavity, but the blood in the neighbourhood of the lacerated spleen has coagulated.

(*d*) Abdominal distension commences to appear about three or four hours after the accident, and is due to ileus.

(*e*) Kehr's sign is pain referred to the left shoulder. There may be hyperæsthesia in this area. This sign is present very often if especially sought.

3. **The Delayed Type of Case.**—After the initial shock has passed off the symptoms of a *serious* intra-abdominal catastrophe are postponed for a variable period up to fifteen days, or even more. Delay of serious intra-peritoneal bleeding is explained in one of three ways:

(*a*) The great omentum, performing its well-known constabulary duties, shuts off that portion of the general peritoneal cavity in the immediate vicinity of the bleeding.

(*b*) Blood clot temporarily seals the rent.

(*c*) A subcapsular hæmatoma forms and later bursts.

Treatment of Rupture of the Spleen

Immediate laparotomy and splenectomy is the only reliable course. Blood is mopped up and the abdomen

Fig. 192.—Ruptured spleen successfully removed from a man of 52

closed completely. As a rule subcutaneous saline infusion is all that is necessary to replenish the circulation, for the subjects are often previously healthy individuals who can afford a loss of blood. In exsanguinated weak subjects auto-transfusion at the time of the operation or blood transfusion later is indicated. The results of operation for traumatic rupture of the spleen are exceedingly good.

POST-OPERATIVE COMPLICATIONS

The following complications have been noted from time to time after removal of a ruptured spleen. They have all occurred within the first two or three weeks after operation.

1. **Peritoneal effusion** is due to a wound of the tail of the pancreas. The effusion lasts three or four weeks, and usually gradually lessens in amount. It is accompanied by slight pyrexia.

2. **Left pleural effusion** is due, no doubt, to bruising of the dia-

phragm at the time of the accident or during splenectomy. Treatment consists of aspiration, if necessary repeated.

3. **Persistent hiccough** is the result of irritation of branches of the left phrenic nerve upon the under-surface of the left side of the diaphragm.

4. "**Burst**" **abdomen** is liable to occur where the tail of the pancreas has been wounded, for escaping ferments digest the catgut in the abdominal wound.

5. **Hæmatemesis** from temporary congestion of the fundus of the stomach, due to the vasa brevia.

SPONTANEOUS RUPTURE OF THE SPLEEN

Diseased, and even normal, spleens have been known to rupture spontaneously. An example of the latter occurred in our practice. A healthy young man was seated before his fireside when the spleen ruptured. In this case the ruptured organ was removed successfully.

ANEURISM OF THE SPLENIC ARTERY

Of 183 consecutive aneurisms found in the course of necropsies at the Jena Pathological Institute, 9 concerned the splenic artery. The symptoms of the condition are vague. In reported cases the spleen has been found more or less enlarged. Rupture of a splenic aneurism usually presents symptoms similar to those of spontaneous rupture of the spleen. In such a case St. Leger Brockman heard a bruit over the left hypochondrium, and was thereby enabled to make a correct preoperative diagnosis. Splenectomy, together with excision of that part of the artery containing the aneurismal sac, has been performed successfully.

INFARCTION OF THE SPLEEN (fig. 193)

The patient, who is often suffering from mitral stenosis or endocarditis, is seized with agonising pain in the left hypochondrium.



FIG. 193.—Infarct of the spleen. (Pool and Stillman.)

In a case seen by us, symptoms mimicked those of a perforated gastric ulcer, but the heart lesion helps the clinician to elucidate

the diagnosis. When the embolus is aseptic the symptoms pass off in a few days. If the embolus is infected and the primary condition does not prove fatal, a splenic abscess may be expected to follow.

MOVABLE SPLEEN (*syn.* Wandering Spleen)

Curiously, in general visceroptosis the spleen is the one abdominal organ which maintains its correct anatomical position. Movable spleen is a congenital abnormality, and the majority occur in women. The condition is of great rarity, and the diagnosis is seldom made correctly, the movable tumour being mistaken for an ovarian cyst.

Torsion of the splenic pedicle sometimes occurs in the wandering organ. The torsion may be acute or chronic, acute cases presenting the symptoms of an intra-abdominal catastrophe. Chronic torsion may result in atrophy of the spleen, and after a period of indefinite abdominal discomfort all symptoms abate.

Treatment.—A movable spleen giving rise to symptoms should be removed. Splenopexy is not a reliable method of treatment, but the results of extirpation are entirely satisfactory.

ABSCESS OF THE SPLEEN

Abscess of the spleen is another rare condition. The most frequent cause is typhoid fever. The *bacillus typhosus* is frequently present in the pus. The diagnosis of a splenic abscess is confirmed by splenic puncture.

Splenic Puncture.—A long, fine needle is used. The puncture is made in the tenth intercostal space in the mid-axillary line. The patient is instructed to hold his breath, and the aspiration is done as quickly as possible. If the patient makes a respiratory movement the needle must be allowed to follow the movements of the spleen.

Treatment.—Splenectomy is the ideal form of treatment. When the organ is adherent to neighbouring structures the abscess must be drained.

SPLENIC ANÆMIA (*syn.* Banti's Disease)

Splenic anæmia may be divided into three stages. First, that of splenomegaly and anæmia; second, that of liver enlargement; and third, the terminal stage of ascites. The beginning of the condition is insidious.

The first stage lasts a long time, even for five to ten years. The patient feels run down, and his friends tell him he looks pale. On examination the spleen is found to be enlarged, and the blood-count shows a considerable secondary anæmia. During the latter part of the first stage a tendency to hæmorrhages commences.

The second stage is characterised by definite enlargement of the liver. The edges of the organ feel somewhat roughened, and its consistency is hard. This stage is a

comparatively short one, lasting from six to eighteen months.

The third stage is marked by the onset of symptoms of portal obstruction. When fluid begins to collect in the peritoneal cavity a fatal termination is to be expected within two years, and splenectomy offers the only hope of prolonging life. In progressive cases the patient becomes more and more anæmic, and a blood-count shows, in addition to a diminished red cell-count, a leucopænia and a relative lymphocytosis. He is prone to gastric and other hæmorrhages, and finally is carried off by pneumonia or some other intercurrent infection. Necropsy reveals a large adherent spleen with a sclerotic splenic artery and a much-enlarged splenic vein which is not infrequently as large as a thumb (fig. 194). The liver is cirrhotic, and the peritoneum opaque and dotted over with milk-white patches.



FIG. 194.—Enlarged spleen from a case of splenic anæmia. Note the large size of the splenic vessels.

Treatment.—The only effective treatment for splenic anæmia is splenectomy. When the patient survives operation he almost always exhibits striking improvement. In a few cases, after several years, the symptoms appear to return,

but this is no argument against the performance of the operation, for medical treatment is without value. The operation of splenectomy in these cases is often a very serious undertaking, for the presence of adhesions makes extirpation of the organ increasingly difficult as the disease progresses. Blood transfusion at the close of the operation has helped to lower the mortality.

Von Jaksch's Anæmia

Von Jaksch's anæmia is a condition occurring in children, and presents many of the features of Banti's disease. Some consider it is a juvenile form of that disease, others, perhaps the majority, look upon it as a separate clinical entity. The patient is usually between the ages of 3 and 9. There is profound anæmia, a slight enlargement of the liver, considerable enlargement of the spleen (fig. 195), and sometimes

Fig. 195.—Von Jaksch's anæmia. The enlarged spleen has been marked out. Splenectomy was performed successfully in this case.

hypertrophy of the superficial lymph glands. The examination of the blood shows a striking diminution in hæmoglobin, and in the number of red cells. The hæmoglobin may be as low as 20 per cent., and the red cells down to a million. Following the removal of the spleen there is usually a tremendous increase in the number of nucleated red cells in the blood.

Treatment.—As the disease is progressive, those cases

which do not respond to medical treatment should be splenectomised, and this measure, combined with blood transfusion, has given encouraging results. It is of advantage to give a series of blood transfusions both before and after splenectomy.

Late Results.—Many patients appear to be cured. There is a possibility of "gastric" hæmorrhages occurring from a dilated œsophageal varix. We encountered such a case where the child had been splenectomised five years before. In spite of repeated blood transfusions, he bled to death.

EGYPTIAN SPLENOMEGALY

Splenomegaly among the Egyptian fellaheen is one of their most disabling diseases (fig. 196). Stiven believes that the enlarged spleen is in some way connected with bilharzia. After careful preoperative preparation splenectomy performed under spinal anæsthesia has given excellent results.

ACHOLURIC JAUNDICE

By *acholuric* jaundice is meant jaundice without bile in the urine. Acholuric jaundice is usually familial, but there is an acquired form which is very rare. The latter type is confined to women. The cause of acholuric jaundice is obscure.

FIG. 196.—Egyptian splenomegaly. (Stiven.)

Acholuric familial jaundice is characterised by *crises*. These are ushered in with severe abdominal pain, and there are all the signs of biliary obstruction. The symptoms are identical with those of a stone in the common bile duct; indeed, 50 per cent. of sufferers have gall-stones. Not a few patients will give a history of a previous operation for gall-stones, the key to the diagnosis, viz. an enlarged spleen, evidently having been overlooked. The spleen is large, weighing 2 or 3 lb., and easily palpable

in thin subjects. The blood examination reveals an absolutely characteristic feature. There is fragility of the red cells, that is, they tend to hæmolyse in isotonic salt solution.

Treatment.—Providing that gall-stones, if present, receive appropriate treatment, splenectomy will render the patient symptom-free. Splenectomy and cholecystectomy performed at the same time is a big undertaking, and in frail subjects it is sometimes advisable to remove the spleen and the gall-bladder separately, with an interval of a few months between the operations. After the splenectomy the jaundice disappears, but the tendency to spontaneous hæmolysis persists, and has been demonstrated twenty-five years after removal of the spleen.

GAUCHER'S DISEASE

Gaucher's disease is characterised by an enormous enlargement of the spleen, which may weigh up to 8 or 9 lb. Pathologically the condition is generally conceded to be an endothelioma. In the majority of cases the splenic enlargement begins in childhood, usually before the age of 12, although the patient is rarely presented before adult life. Until the splenic enlargement becomes massive the symptoms are few. There is slight anæmia of the chlorotic type, and the patient usually presents a brownish-yellow discoloration of the skin of the hands and face. A curious conjunctival thickening is a characteristic feature which helps to clinch the clinical diagnosis. Jewesses appear to be more prone to this disease than the rest of humanity.

Treatment.—Splenectomy rids the patient of a large abdominal tumour. The end results of this, the only treatment, are not encouraging, for the patients seldom survive more than two years.

PURPURA

Purpura is a disease of great interest to the surgeon. It forcibly intrudes into his diagnostic arena ; on rare occasions it is the cause of an intussusception, but more frequently the subserosal hæmorrhages produce signs similar to those of acute intestinal obstruction (fig. 197) ; it may give rise to profound hæmaturia or alarming hæmorrhage from a mucous lining of the body ; it is a condition which calls for blood transfusion, and evidence is accumulating rapidly that certain carefully selected cases are permanently benefited by splenectomy.

In the past purpura has been divided into various types :

1. Purpura simplex.
2. Purpura rheumatica, or Schönlein's disease.

which do not respond to medical treatment should be splenectomised, and this measure, combined with blood transfusion, has given encouraging results. It is of advantage to give a series of blood transfusions both before and after splenectomy.

Late Results.—Many patients appear to be cured. There is a possibility of "gastric" hæmorrhages occurring from a dilated œsophageal varix. We encountered such a case where the child had been splenectomised five years before. In spite of repeated blood transfusions, he bled to death.

EGYPTIAN SPLENOMEGALY

Splenomegaly among the Egyptian fellaheen is one of their most disabling diseases (fig. 196). Stiven believes that the enlarged spleen is in some way connected with bilharzia. After careful preoperative preparation splenectomy performed under spinal anæsthesia has given excellent results.

ACHOLURIC JAUNDICE

By *acholuric* jaundice is meant jaundice without bile in the urine. Acholuric jaundice is usually familial, but there is an acquired form which is very rare. The latter type is confined to women. The cause of acholuric jaundice is obscure.

FIG. 196.—Egyptian splenomegaly. (Stiven.)

Acholuric familial jaundice is characterised by *crises*. These are ushered in with severe abdominal pain, and there are all the signs of biliary obstruction. The symptoms are identical with those of a stone in the common bile duct; indeed, 50 per cent. of sufferers have gall-stones. Not a few patients will give a history of a previous operation for gall-stones, the key to the diagnosis, viz. an enlarged spleen, evidently having been overlooked. The spleen is large, weighing 2 or 3 lb., and easily palpable

purpura, petechial hæmorrhages appear distal to the constricted area. The tourniquet should be left in position for three minutes.

Treatment.—The treatment of purpura in the acute stage is largely symptomatic. The general supervision of the patient is essentially the domain of the physician, but surgical complications, such as profound hæmaturia, suspected intussusception, or profound loss of blood necessitating transfusion, require the surgeon's attention.

The question of splenectomy arises in cases of recurrent or chronic purpura, which have been shown to have a diminished blood-platelet[1] count. In such cases removal of the spleen has cured the disease.

PERNICIOUS ANÆMIA

The success which has attended the liver treatment of pernicious anæmia has rendered this condition almost entirely medical once more. A few years ago, at the Mayo Clinic, repeated blood transfusion, combined with splenectomy, was reported to be giving encouraging results.

LEUCOCYTHÆMIA

Splenectomy is absolutely contraindicated, for in cases in which it has been tried it has proved invariably fatal. X-rays or radium are the only forms of treatment.

CYSTS OF THE SPLEEN

There are several distinct types of splenic cysts :

1. *Single, usually unilocular, non-parasitic cyst.*—This variety often reaches a large size, and is satisfactorily treated by splenectomy. It is supposed to be due to an ancient subcapsular hæmorrhage.
2. *Small multiple cysts* are sometimes encountered at necropsy and occasionally at operation. They have no clinical significance.
3. *Polycystic Spleen.*—The polycystic disease is sometimes confined to the spleen, but is more often associated with congenital cystic kidneys and liver.
4. *Hydatid Cyst of the Spleen.*—A number of cases of hydatid cyst of the spleen have been reported, and in this situation hydatid cysts are readily removed with the whole spleen.

NEW-GROWTHS

New-growths of the spleen are of the utmost rarity. Only about twenty cases of primary sarcoma of the spleen have been reported. The remaining new-growths, with the exception of Gaucher's disease (which has been considered

[1] The normal blood-platelet count is 250,000 per cub. mm.

FIG. 198.—Perisplenitis. The capsule is a quarter of an inch in thickness in places.

already), require no detailed consideration.

PERISPLENITIS

Some degree of thickening of the splenic capsule has been noted at necropsy, usually in subjects with advanced hepatic cirrhosis. The best example of perisplenitis occurs in association with multiple serositis (Pick's disease). In this obscure malady the spleen appears as though covered with sugar icing. The covering is hard, structureless, and gives staining reactions similar to hyaline cartilage.

Fibrous perisplenitis, apparently the result of bygone inflammation, has received but scant attention in the literature. In the figure (fig. 198) illustrated the capsule of the spleen was a quarter of an inch thick in places, the organ was adherent to the diaphragm and to the cardiac orifice of the stomach, causing angulation of the latter. This produced dysphagia. Gardham has reported a similar example which so deformed the stomach that an X-ray diagnosis of carcinoma of the stomach was made.

INDICATIONS FOR SPLENECTOMY

The principal present-day indications for splenectomy may be summarised as follows :

1. Rupture, with which is included delayed rupture, spontaneous rupture, and rupture of a splenic aneurism.
2. Movable spleen with symptoms.
3. Splenic anæmia—Banti's disease.
4. Von Jaksch's anæmia.
5. Egyptian splenomegaly.
6. Acholuric familial jaundice.
7. Recurrent or chronic purpura, with a diminished platelet count.
8. Cysts and abscess of the spleen.
9. New-growths.

. . . . .

The spleen is a meeting-place of medicine and surgery. We have outlined those conditions of particular surgical interest. There remains perhaps the most important task, that of presenting to the reader a readily assimilable table of enlargements of the organ.

ENLARGEMENTS OF THE SPLEEN

1. *Infective*
   - Bacterial
     - Typhoid (sometimes splenic abscess [3]).
     - Typhus.
     - Anthrax.
     - Tubercle.[3]
     - Septicæmia.
     - Pneumonia.
   - Protozoal
     - Malaria.[3]
     - Kala-azar.
     - Weil's disease.
     - Syphilis.
     - Hydatid.[1]
2. *Blood diseases*
   - Splenomedullary leucocythæmia.
   - Lymphatic leucocythæmia.
   - Pernicious anæmia.[3]
   - Polycythæmia.
   - Acholuric familial jaundice.[1]
   - Hodgkin's lymphadenoma.
   - Purpura.[3]
3. *Cause unknown*
   - Splenic anæmia—Banti's disease.[1]
   - Von Jaksch's anæmia.[1]
   - Egyptian splenomegaly.[1]
   - Non-parasitic cysts.[1]
4. *Disease of liver.*—Cirrhosis.
5. *Metabolic*
   - Rickets.
   - Amyloid.
6. *Circulatory*
   - Infarct
     - Endocarditis.
     - Mitral stenosis.
   - Aneurism of the splenic artery.[2]
7. *Neoplastic*
   - Gaucher's disease.[1]
   - Angioma.[1]
   - Primary sarcoma
   - Lymphosarcoma.

[1] Benefited by splenectomy.
[2] Splenectomy indicated sometimes.
[3] Splenectomy indicated on rare occasions.

THE LIVER

The surgical conditions of the liver are limited. The success which often attends the removal of an immense hydatid cyst or the aspiration of a large tropical abscess, or, less frequently, the resection of a primary neoplasm of this organ, is due to a remarkable power possessed by the liver to a greater degree than by any other organ. It is that of regeneration. If a large part of the liver is destroyed and the noxious agent is removed, within twelve months the organ compensates its loss and regains its pristine bulk and activity.

Rupture of the Liver

There are no special symptoms and signs of a ruptured liver; they are those of a hæmoperitoneum, very similar to a ruptured spleen.

The main difference is that localising signs, if present, are likely to be more in evidence upon the right side. The nature of the violence which produces this injury is usually of a crushing type. An extensive rupture of the liver is an extremely grave accident. A considerable proportion of these cases are associated with other severe injuries, and the total mortality is very high. We have noticed small tears in the liver at necropsy in subjects who have died from other injuries. Small tears probably occur rather frequently, but give rise to no serious symptoms, and consequently are undiagnosable.

Treatment.—A hæmoperitoneum always requires immediate laparotomy. In this instance, when the abdomen has been opened and the liver is found to be severely torn, the rupture is dealt with by one of the following methods:

1. If the tear is accessible and moderate in size, it is repaired by tiers of mattress sutures tied not too tightly,

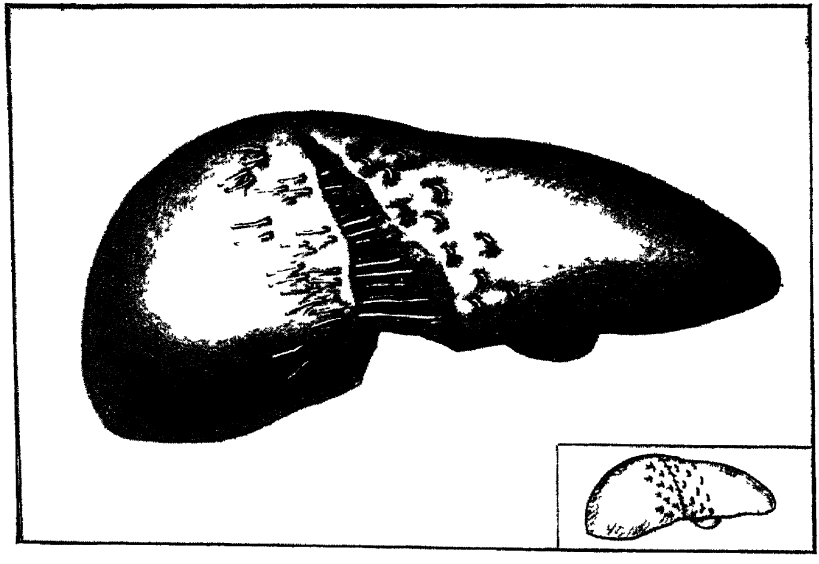

FIG. 199.—Method of repairing a deep rent in the liver by tiers of mattress sutures (*Emergency Surgery*).

and preferably over a piece of detached omentum, for the liver is a friable organ.

2. If the tear is not readily accessible, or very extensive, recourse must be made to packing with a length of gauze, the end of the gauze being left protruding from the abdominal wound. This packing should be left *in situ* for five days and then removed gradually.

Abscess of the Liver

A liver abscess can be due to many causes, and the infection reaches the liver by one of several paths, viz. via—

1. **The Portal Vein.**

(*a*) Suppurative appendicitis.
(*b*) Inflamed hæmorrhoids.
(*c*) Diverticulitis.
(*d*) Inflamed carcinoma of the colon.
(*e*) Typhoid (rare).
(*f*) Amœbic abscess also comes under this category.

2. **The Hepatic Artery.**

General pyæmia.

3. **The Bile Ducts.**

Retrograde infection up the common bile duct; usually a complication of a gall-stone impacted in the common duct.

4. **The Umbilicus.**

(*a*) Along the umbilical vein of the new-born.
(*b*) Along the veins of Sappey.

5. **Direct Extension**

(*a*) Subdiaphragmatic abscess.
(*b*) Empyema.

6. **Infected Penetrating Wounds.**
7. **Suppurating Hydatid.**

Pylephlebitis (*syn.* Portal Pyæmia)

The causes of pylephlebitis are set out in the foregoing table.

Pathology.—Particularly when occurring secondary to appendicitis, the commonest cause, the liver is often riddled



Fig. 200.—Pylephlebitis. Liver riddled with small abscesses.

with abscesses (fig. 200). The abscesses are connected together, forming a "canal and cavity" system (H. M. Turnbull). In rare instances there is localisation of the infection.

Clinical Features.—Repeated rigors usually usher in this very fatal complication. The patient soon becomes slightly jaundiced, and the liver will be found to be somewhat enlarged and tender. When there is no known focus of infection, the rectum should be examined for inflamed hæmorrhoids.

If a swinging temperature and rigors occur in the course of acute appendicitis, pylephlebitis is one of the first conditions to be considered. In the early stages pylephlebitis is often difficult to differentiate from subdiaphragmatic abscess.

Prophylaxis.—(*a*) Hæmorrhoids should never be removed in an acutely inflamed state. (*b*) Ligation of the ileocolic vein in addition to appendicectomy is to be recommended in those rare cases of early acute appendicitis where rigors are in evidence.

Treatment.—In very early cases repeated injections of intravenous mercurochrome may possibly abort the infection. Such treatment is well worth trying. When pylephlebitis is fully established, the outlook is practically hopeless, but we consider that it is more than justifiable to perform laparotomy. Several cases have been reported where a localised collection of pus has been evacuated, and the patient has recovered. We witnessed an unreported case where two large collections of pus in the right lobe were drained successfully. Unfortunately, the usual operative finding is that the surface of the liver is studded with abscesses. When such a picture is seen a fatal issue is inevitable, although the patient, if young, often drags on for several weeks. Such cases are almost the most distressing to be seen in surgical practice.

Tropical Liver Abscess (*syn.* Amœbic Abscess, Solitary Abscess, Dysenteric Abscess)

Tropical liver abscess is one of the terminations of amœbic hepatitis, which in turn is a complication of amœbic dysentery. Tropical liver abscess most often develops soon after dysentery; less frequently its appearance is delayed, sometimes many years. The incidence has diminished considerably since the introduction of treatment by emetine of the original infection.

Pathology.—*Entamœbæ histolyticæ* pass from the colon along the portal vein and enter the liver. Here they colonise and live at the expense of the liver cells, causing them to liquefy. The amount of

liver destruction is proportional to the size of the colony and the resistance of the host. Usually the abscess is solitary. Except in long-standing cases, amœbæ can be isolated from a scraping of the abscess wall. The content of the abscess cavity seldom contains the parasite ; indeed, the pus is usually sterile. Characteristic pus from a tropical liver abscess is chocolate coloured, and consists of broken-down liver cells, leucocytes, and red blood-cells.

The abscess, which in 90 per cent. of cases is situated in the right lobe of the liver, runs a variable course.

1. Usually it enlarges, most often in an upward direction. It is at this stage that surgical intervention is called for.

2. It may become encapsulated and remain dormant for long periods.

3. Very occasionally it resolves completely under emetine treatment, or even without such treatment.

4. Unrecognised and untreated, it often bursts into neighbouring viscera (fig. 201), or less frequently, points beneath, the skin overlying the liver.

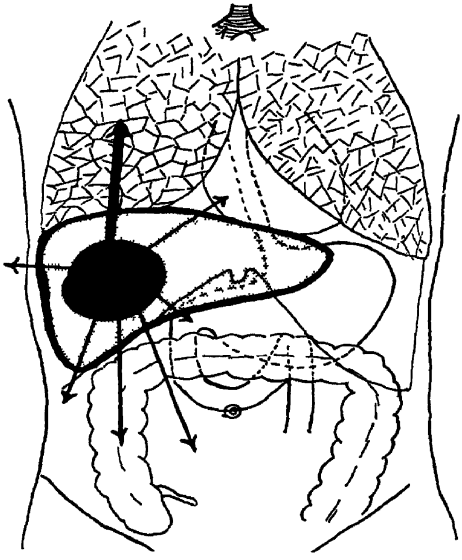

FIG. 201.—Directions in which a tropical liver abscess may burst. (After Cope.)

The bursting of a liver abscess into the lung and the expectoration of a quantity of chocolate-coloured sputum sometimes results in a natural cure.

Bacterial infection is a possible and serious complication of tropical liver abscess.

Clinical Features.—White men, usually between the ages of 20 and 40, who have resided in the tropics for only a comparatively short time, are the most frequent victims. Possibly because they drink less alcohol, women are rarely affected.

Fever is nearly always present. Rigors occasionally occur, especially in the early stages.

Pain is constantly present in the liver area, and is occasionally referred to the right shoulder.

Tenderness and *rigidity* in acute cases is comparable to that of acute cholecystitis. In old-standing chronic cases tenderness is often absent.

Enlargement of the liver can often be demonstrated by clinical methods. An X-ray examination is frequently most helpful in demonstrating the enlargement, upward enlargement being characteristic.

Basal lung signs on the corresponding side are always present in acute cases of hepatic abscess.

General symptoms—anæmia, anorexia, abdominal discomfort, and an "earthy complexion"—of chronic infection are often the first symptoms.

Treatment.—When the diagnosis is even suspected intramuscular injections of emetine are commenced, and are continued if the diagnosis of an amœbic infection is confirmed. When the signs point to tropical liver abscess, there should be no undue delay in evacuating the pus. This may be done in one of the following ways :

1. *Aspiration* has yielded good results, and is the treatment of choice in most cases.

After the skin has been anæsthetised by novocaine, a No. 9 bore hollow needle 3½ inches long is inserted into the right lobe of the liver, usually through the eighth or ninth intercostal space in the mid-axillary line. If the abscess cavity is entered pus is evacuated by attaching an aspirating syringe to the needle. If pus is not at first encountered the needle is partially withdrawn and reintroduced in a different direction. The considered opinion of those with experience in these cases is that injection of medicated fluids into the abscess cavity is useless and harmful. Re-aspiration in a few weeks is sometimes necessary.

2. *Cantlie's method* is indicated when the pus is too thick to run through a hollow needle. A special combined trocar and cannula is employed. A drainage tube is introduced into the abscess cavity through the cannula.

By minimising the possibility of secondary infection,

3. *Open operation* is seldom required ; formerly it was the usual method of treatment.

The transpleural approach, similar to that used for a subdiaphragmatic abscess, is the usual route to be followed. When the abscess is more anteriorly placed or is invading the left lobe of the liver, then the abdominal approach is chosen.

which, particularly in hot countries, is very prone to occur, aspiration and emetine have reduced considerably the mortality of tropical liver abscess.

ACTINOMYCOSIS OF THE LIVER

Actinomycosis of the liver produces the well-known "honeycomb" liver. The ray fungus reaches the organ in one of the following ways:

1. Secondary to actinomycosis of the right iliac fossa, 50 per cent.
2. Direct continuity . . . . . 20 ,, ,,
3. Metastasis, particularly from the neck . . 30 ,, ,,

For the treatment of the original actinomycotic lesion intensive iodine therapy will doubtless have been tried, but by the time the liver is involved the prognosis is almost hopeless.

HEPATIC SYPHILIS

As far as the liver is concerned syphilis, always an accomplished actor, can, and often does, deceive the clinician, and even the operator. Gummata form rounded masses in the right lobe of the liver many years after the primary infection. These swellings sometimes push up the right cupola of the diaphragm, and simulate closely a liver abscess. In the left lobe such a mass forms an epigastric tumour, liable to be mistaken for a carcinoma of the stomach. A single gumma of the lower part of the right lobe imitates a primary hepatic neoplasm or even an enlarged gall-bladder. Multiple gummata of the liver give signs not unlike secondary carcinoma when examined clinically, although, when displayed to the light of day, they lack the characteristic umbilicated appearance of the latter. Syphilitic cirrhosis is sometimes accompanied by ascites.

TUBERCULOSIS OF THE LIVER

Tuberculosis of the liver is exceedingly uncommon. When present it is usually secondary to ileo-cæcal tuberculosis. It sometimes takes the form of solitary masses or localised abscesses which have been drained successfully.

Hydatid Disease of the Liver

Although the parasite may develop in any one of the many organs, in 70 per cent. of cases it does so in the liver. It enters this structure through the radicles of the portal vein.

Pathology.—A hydatid cyst consists of two distinct layers. There is the ectocyst made up of fibrous tissue, the result of the liver's reaction to the parasite and the endocyst formed of the parasite itself. The ectocyst is grey in colour, and intimately blended with the liver. The endocyst is whitish and elastic, and contains the hydatid fluid. Daughter and granddaughter cysts may form within (figs. 202 and 203). The endocyst very closely resembles

a child's uncoloured balloon filled with water. Hydatid fluid registers a specific gravity of 1,005 to 1,009, con-

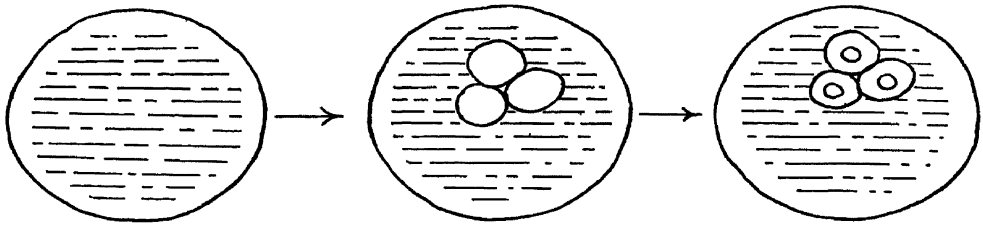

Simple Cyst.—The usual type in a young adult.

Development of daughter cysts.—Commonly seen in the adult.

Development of granddaughter cysts, and other complications such as suppuration and rupture, typify cases which have been neglected until past middle life.

FIG. 202.

tains no albumin, occasionally a trace of sugar, and, when not too old, hooklets and scolices.

Clinical Features.—In their early stages hydatid cysts are symptomless. In the course of time, owing to the preponderance (75 per cent. of cysts) on the inferior aspect of the liver, a visible and palpable tumour in the upper segment of the abdomen is discovered (H. Dew). The size to which a hydatid may attain without causing much disturbance of health would seem to be limited only by

FIG. 203.—Multiple hydatid cysts in the liver. The patient, who had never left England, died after a street accident.

the volume of the peritoneal cavity. In academic circles undue prominence is accorded to the hydatid thrill, a sign which is rarely present, even in advanced cases. Percussion reveals dullness over the swelling continuous with the liver dullness.

When the liver is enlarged upwards by the cyst the diagnosis is much more difficult, and amongst other conditions a differential diagnosis must be made between hydatid cyst and tropical liver abscess. Naturally, when the patient hails from Australia or a locality where hydatid disease is rife, the diagnosis is simplified. Radiography and immunological tests are of great diagnostic assistance in obscure cases.

The Intradermic Test (Casoni and Fairlie) is comparable to the tuberculin reaction, and is positive in 95 per cent. of all cases of hydatid disease.

A blood count shows an eosinophilia (6 per cent. or more).

Course of the Disease.—1. Occasionally the parasite dies. The fluid is absorbed, and all that remains is an encapsuled, laminated, bile-stained membrane, such as is occasionally found at necropsy (fig. 204). In very old-standing cases the walls of the dead parasite calcify.



FIG. 204.—An encapsuled hydatid found at necropsy. (Aschoff.)

2. Usually the cyst gradually enlarges, and by its size becomes manifest. It is at this juncture that surgical intervention is indicated.

3. Complications arise. "It is the onset of complications that makes the morbidity not much inferior to that of malignant disease" (Fortacin).

Treatment of Hydatid Cyst of the Liver

The only treatment is surgical, for there is no drug which has the slightest effect upon the course of the disease.

The cyst should be exposed by an incision which gives the best access to the cyst. The peritoneal cavity is packed off with gauze wrung out in saline solution. Finally, a black pack, wrung out in 1 per cent. formalin, is tucked around the exposed liver—*black* so that daughter cysts and scolices should show up against the background ; *formalin* because this antiseptic kills the parasites. The cyst is aspirated, and a quantity of formalin solution is introduced so as to render the cyst about three-quarters full. An incision is made through the liver overlying the cyst, and the ectocyst is opened. This brings the rubbery endocyst into view. Very gently the endocyst is grasped with ovum forceps, and the endo- is separated from the ectocyst. The aim in view should be to separate the endocyst and deliver it intact. This is possible in uncomplicated cases. In complicated cases it is sometimes necessary to remove the endocyst piecemeal. When the endocyst can be cleanly and completely enucleated, the resulting cavity in the liver is filled with normal saline and closed completely. In less favourable circumstances it is advisable to drain the cavity. No attempt should ever be made to remove the ectocyst. We have seen the liver irreparably split during an ineffectual attempt to excise an ectocyst in the belief that it was the endocyst. In all cases full precautions should be taken to prevent spilling the contents of the cyst into the peritoneal cavity or the layers of the abdominal wall. Such precautions minimise the possibility of dissemination of the disease.

Complications of Hepatic Hydatid Cyst

1. Rupture

(*a*) Into the peritoneum.
(*b*) Into the biliary channels.
(*c*) Into the alimentary canal.
(*d*) Into the thorax.

2. Suppuration

Rupture into the peritoneum is accompanied by profound shock, and all the sign of general peritonitis. A green discoloration about the umbilicus has been noted in rare instances. As with any case of rupture of a hydatid cyst, anaphylactic phenomena, notably urticaria, are prone to occur. The treatment of intraperitoneal rupture must be immediate, and directed to combating shock and cleaning the peritoneal cavity. Even in those who survive, the ultimate prognosis is poor, for the disease must tend to become disseminated in the peritoneum.

Neoplasms of the Liver

PRIMARY TUMOURS

1. **Angiomata.**—Cavernous angioma is the commonest primary neoplasm of the liver. It is usually small, and causes no symptoms. Large angiomata occasionally arise ; they are frequently in the left

lobe, and may attain enormous dimensions. One of 37 lb. has been reported, and another of 10 lb. was successfully removed. When such a tumour appears laparotomy will be indicated. If the neoplasm is found to be localised and accessible, it should be excised, care being taken to cut through normal liver a reasonable distance from the vascular growth. The use of the cautery knife is advantageous in this instance.

2. **Adenomata.**—(*a*) There is a rare tumour often known as a *hepatoma* which grows rapidly, and tends to become malignant.



FIG. 205.—Hepatoma removed from the liver of a woman of 28.

FIG. 206.—Enormous enlargement of the liver. A case of cystadenoma of the bile ducts.

The subject is usually an adolescent or a young adult. Whenever possible, resection of the tumour is indicated.

(*b*) *Cystadenoma* can develop from the intrahepatic bile canaliculi. The condition is of the utmost rarity, and the liver grows slowly to an enormous size (fig. 206). The whole liver in the case illustrated was a mass of cysts of varying sizes, and eventually the neoplasm proved fatal.

3. *Congenital cystic liver* occasionally accompanies congenital cystic kidney.

4. *Primary Carcinoma of the Liver.*—In 98 per cent. of cases carcinomata of the liver are secondary, yet "cancer of the liver" (indicating that the liver is the primary seat of the neoplasm) is a favourite diagnosis amongst a certain section of the profession. Primary carcinoma of the liver is often of the nodular form, not unlike hepatic cirrhosis at first sight; indeed, primary carcinoma of the liver sometimes occurs in areas of regeneration which accompany cirrhosis (Turnbull). It has been found in persons under the age of 20, and even in childhood. Sometimes this neoplasm, which

is always fatal, is accompanied by irregular pyrexia. A localised primary carcinoma of the liver is occasionally found, and this form has been treated by excision, but early recurrence is usual.

5. *Primary sarcoma of the liver* is even rarer than primary carcinoma.

RESECTION OF A PORTION OF THE LIVER

Although always a serious undertaking, resection of a primary growth of the liver is often attended by success. The mortality at the present time is about 25 per cent. of all cases. The best method of arresting hæmorrhage is to pass and tie deep interrupted sutures half an inch beyond the proposed line of section. The resection itself usually takes the form of a wedge, which should include half an inch of healthy liver on all sides of the tumour. The resulting raw surfaces of the cut liver are approximated by deep sutures inserted with a blunt liver needle and tied not too tightly.

Secondary Neoplasms of the Liver

1. **Secondary Carcinoma.**—As is well known, the liver is a favourite site for carcinomatous metastases. Characteristic secondary growths in the liver are umbilicated.

Invasion of the liver by a primary carcinoma of the gall bladder does not come into the above category. We have resected successfully a portion of the liver, together with the gall bladder, in such a case.

2. **Secondary sarcoma** of the liver is not uncommon.

3. **Secondary melanoma** occurs frequently, unless the primary growth is removed very early. In the case of melanoma of the uveal tract, treated by early excision of the eyeball, secondary growth in the liver may appear after years of apparent freedom.

HEPATOPTOSIS (*syn.* Movable, Wandering, or Dislocated Liver)

Hepatoptosis is rarely congenital, may be acquired, but is usually part of a general visceroptosis. The congenital form is due to an absence of certain ligamentous supports of the liver, while the acquired form is thought to arise from injury. Almost without exception the patient is a female, and in extreme cases the liver descends below the umbilicus. When it is impossible to control this displacement by a belt, and when it is not associated with general visceroptosis, operation has been advised and practised successfully. After scarification of its dome, so as to invite adhesion to the diaphragm, the liver is slung to the abdominal wall and lower costal cartilages.

RIEDEL'S LOBE (*syn.* Floating Lobe, Linguiform Lobe, Partial Hepatoptosis).

There is a tongue of liver projecting downwards from the right lobe, which forms a palpable mass beneath the right costal margin.

This accessory lobe must be distinguished from an enlarged kidney, the only certain method being by palpating the kidney separately from it. Riedel's lobe was thought to arise from tight lacing, yet it is met with at the present time, when the corporal constriction of former days is rare. This condition is believed to be more common in patients with a diseased gall bladder, the reason for this relationship being unknown.

The Surgical Aspects of Hepatic Cirrhosis

Alcoholic cirrhosis (*syn.* Atrophic cirrhosis, Hobnail liver).—For the treatment of ascites due to this disease omentopexy was devised. The operation aims at establishing an efficient venous anastomosis between the systemic and portal systems. It is indicated when the patient has withstood several tappings, has promised to be a total abstainer, and is free from pulmonary, renal, or cardiac disease.

The Talma-Morison Operation.—Laparotomy is performed and ascitic fluid evacuated. The surfaces of the liver and spleen are scrubbed with gauze to encourage subsequent adhesion between these organs and the parietal peritoneum. The omentum is then fixed to the parietes at several points, particularly to the peritoneal edges of the incision. After the operation, several further tappings are necessary, but in successful cases the ascites abates, and large veins coursing over the abdominal wall bespeak the establishment of an efficient collateral circulation between the portal and systemic circulations.

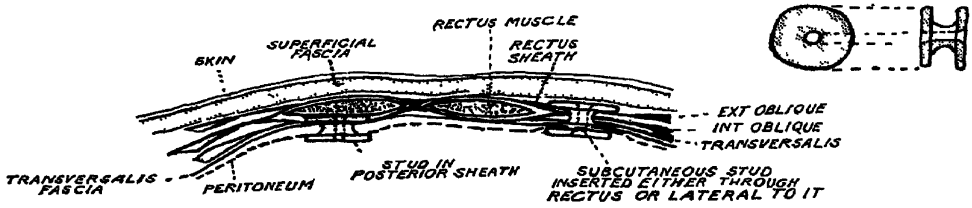

Fig. 207.—Tannahill's operation. Inset shows the perforated glass bobbin. (Tannahill.)

Tannahill's Operation.—Laparotomy is performed, and omentum is stitched to the sheath of the rectus. Two perforated glass bobbins (fig. inset) are fixed in the position shown in (fig. 207). By their agency ascitic fluid drains into the abdominal wall and becomes absorbed. This obviates the necessity for tapping, while the formation of a collateral circulation is in progress.

The following table of the usual enlargements of the liver will be found to be of service :

ENLARGEMENTS OF THE LIVER

- *General enlargement*
  - With jaundice
    - Regular
      - Cholangitis (secondary to common duct stone impaction [1]).
      - Pylephlebitis.[1]
      - Liver displaced downwards by subphrenic abscess.[1]
      - Carcinoma of head of pancreas.
      - N.A.B. poisoning (look for vein puncture at elbow).
      - Catarrhal jaundice.
    - Irregular—Late secondary carcinoma.
  - Without jaundice
    - Regular
      - Cirrhosis.
      - Failing heart.
      - Leucocythæmia.
      - Rickets.
      - Amyloid (examine spleen and urine).
    - Irregular
      - Secondary carcinoma.
      - Gummata.
- *Localised lump*
  - Is it the gall bladder ?
  - Hydatid.
  - Tropical abscess.
  - Hepatoma.
  - Riedel's lobe (rare).
- *Massive irregular enlargement*
  - Polycystic disease (examine kidneys).
  - Cystadenoma.
  - Secondary melanoma.

[1] Pyrexia a feature.

Beware the individual with a glass eye and a large liver. Many years may elapse between the extirpation of the eyeball for melanoma and the appearance of secondary deposits in the liver (see p. 117, chapter, "Jaws").

CHAPTER XVI

THE GALL BLADDER AND BILE DUCTS

CONGENITAL ABNORMALITIES

THERE are great variations in the anatomical arrangement of the bile passages. For instance, the gall bladder may enter the common duct directly, the cystic duct being absent. Conversely, the cystic duct is sometimes of considerable length, opening into the common duct low down. The cystic artery and right hepatic artery from which it springs at times lie anteriorly to the ducts. These are but a few of the possible variations in this region. They are of great importance in operative surgery.

The Gall Bladder may have a Mesentery.—It is in these cases that the rare abdominal emergency **torsion** of the gall bladder occurs. Cholecystectomy is the treatment, and because of the laxity of the parts it is seldom difficult.

Duplication of the Gall Bladder.—Cases have been reported of patients with two gall bladders, one of which is full of stones and the other free.

Absence or Obliteration of Part of the Bile Ducts.—When the common bile duct is congenitally occluded the infant becomes jaundiced soon after birth. Life is not prolonged for more than a few weeks.

Congenital Cysts of the Bile Ducts.—Closely allied to the above is cystic dilatation of the common duct, which may be explained by partial congenital occlusion. A palpable cystic swelling develops during childhood or youth, and sometimes becomes immense. Anastomosis of the cyst with the small intestine has been carried out successfully.

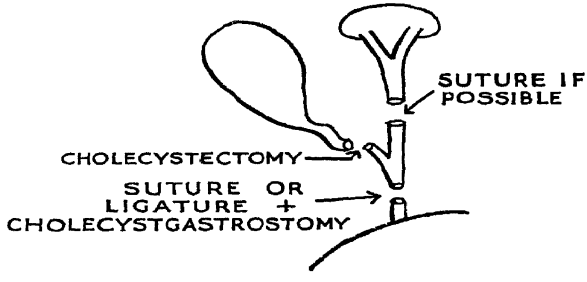

FIG. 208.—A symposium of methods of treating early complete tears of the biliary tract.

TRAUMATIC RUPTURE OF THE BILE PASSAGES

Rupture of the gall bladder or the bile passages is a rare abdominal injury, usually the result of a run-over accident. It is unlikely that a correct pre-operative diagnosis will be made. The signs are

identical with those of rupture of the small intestine. When the abdomen is opened bile is found in the peritoneum.

The best methods of treating these injuries are represented in fig. 208.

Cholecystitis

Acute obstructive cholecystitis implies that there is a stone impacted in the cystic duct. The first result is usually a hydrops (*syn.* mucocele) of the gall bladder (fig. 209). Infection is liable to supervene, and an empyema of the gall bladder results. On rare occasions the distended inflamed organ perforates. Doubtless the infrequency of perforation is due to the fibrotic nature of an organ which has long been the seat of chronic cholecystitis. Perforation is favoured by cathartics and ingestion of solid food, but with the patient confined strictly to bed and on a fluid diet, it is almost unknown.

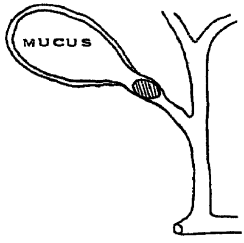

Fig. 209.—Mucocele of the gall bladder.

Acute Non-obstructive Cholecystitis.—All grades of acute inflammation, from catarrhal to gangrenous cholecystitis, occur. Again perforation is exceptional save in the case of acute typhoid cholecystitis. Treated expectantly, it has been found that 10 per cent. of the latter cases culminate in perforation.

Clinical Features of Acute Cholecystitis.—The onset is usually sudden. The pain is located in the right hypochondrium, and there is often pyrexia, sometimes up to 101° F. or more. Biliary colic may be experienced, and it is a mistake to consider this only occurs in cases of gall-stones. *There is rarely jaundice.* On examination tenderness and rigidity in the right hypochondrium is found. If the patient can be persuaded to relax, particularly in obstructive cases, an enlarged gall bladder can be palpated. Where rigidity is a notable feature, the signs closely mimic those of acute appendicitis, the only difference being that the maximal rigidity is inclined to be higher, that is, nearer the costal margin. The differential diagnosis between acute appendicitis and acute cholecystitis is often difficult. Acute

pyelitis and other acute inflammations of the right kidney must also be excluded.

Treatment.—Experience shows that in most cases the acute symptoms of acute cholecystitis subside with intelligent inactivity. The patient is placed in Fowler's position, and for the first forty-eight hours water alone is given. If the temperature, pulse, and other physical signs show that the inflammation is subsiding, the diet is gradually increased. During the third week laparotomy is performed and, if feasible, cholecystectomy carried out.

When there is uncertainty about the diagnosis, or the signs point to a definite empyema of the gall bladder, urgent laparotomy may be performed. Under such circumstances it is usually advisable to limit the operation to cholecystostomy, although in the opinion of some, even under these circumstances cholecystectomy is the operation of choice. Typhoid fever is now comparatively rare. In acute typhoid cholecystitis, because of the danger of perforation, immediate laparotomy must be advised.

Because general peritonitis supervenes readily and rapidly, perforation of an infected gall bladder is a grave complication. The only hope lies in the immediate drainage of the peritoneal cavity and the gall bladder.

Chronic Cholecystitis.—Chronic cholecystitis is now recognised by many as the most frequent organic cause of chronic dyspepsia. While the disease is commonest in middle life, there is increasing evidence that the original infection occurs in early adolescence, or even in childhood. In most established cases the history dates back many years. Females are more commonly affected than males (2 : 1).

Pathology.—The wall of the gall bladder is thickened and opaque. Its mucous membrane shows evidence of chronic inflammation. On slitting up the gall bladder the well-known condition of "strawberry gall bladder" is sometimes found (fig. 210), but this interesting finding is distinctly rare. The pinhead, yellowish deposits are composed of cholesterol esters. Variable adhesions are found about the gall bladder; sometimes these are exceedingly dense.

Occasionally fistula formation occurs between the gall bladder and adjacent organs. In 55 per cent. of cases chronic cholecystitis is associated with gall-stones.

Symptoms.—Flatulent dyspepsia and pain in the right hypochondrium are the leading symptoms. The dyspepsia associated with chronic cholecystitis has never been adequately explained. Sometimes there is associated hyperchlorhydria, which accounts for gastric discomfort, but at other times the test meal shows no striking departure from normal.

FIG. 210.—Strawberry gall bladder.

It is our belief that cholecystitis brings about pyloric spasm, and in order to overcome that spasm the patient swallows air. Here, at least, is an explanation of the belching. Chronic cholecystitis is often overlooked, for the remaining symptoms are extremely varied. For instance, pseudo-anginal attacks sometimes have their origin in a gas-laden stomach secondary to a diseased gall bladder (Miller).

So variable can be the symptoms of chronic cholecystitis that the diagnosis may become abused. The tendency to make cholecystitis a diagnostic rubbish heap, as chronic appendicitis and pyorrhœa alveolaris have been before it, should be avoided. A corrective in this respect is that in a large analysis of cases of proven cholecystitis 90 per cent. had pain in the right upper quadrant of the abdomen.

Diagnosis.—Cholecystography has revolutionised the accurate diagnosis of cholecystitis.

Cholecystography.—Visualisation of the gall bladder by X-ray has been one of the many notable advances in surgery during the past few years. The test depends upon the excretion in the bile of tetrahalogen compounds of phenolsulphonephthalein. The evening meal, consisting of an egg, bread and butter, and stewed fruit, is taken at 6 p.m. Soon after the meal the patient takes 6 capsules of tetraiodophenolphthalein at half-hourly intervals with water. No food of any kind is allowed until the radiological examination has been made, but the patient is permitted and urged to drink water, which may, if necessary, be flavoured with fruit juices. Films are taken at 9 a.m., 11 a.m., and 12 noon the following morning. Then a glass of milk with cream is

given (to empty the gall bladder), and a final film is taken. Normally, the gall bladder is visualised by this method (fig. 211). The most frequent and reliable sign of gall-bladder disease is failure of the gall bladder to cast a shadow in any of the serial X-rays. Distortion of the gall bladder or the presence of gall-stones can sometimes also be demonstrated.

Treatment.—Unless there are contraindications, cholecystectomy should be performed, and there is hardly a more satisfactory operation. Medical treatment rarely cures the patient. Felamine, a preparation of cholic acid and urotropin, sometimes gives temporary relief. The dose is 1 tablet t.d.s. p.c. Careful dieting and a course of spa treatment or saline aperients occasionally render the patient symptom-free, but eventual recurrence is only too common.

FIG. 211.—A normal cholecystogram.

Typhoid Carriers.—It is now proven that typhoid carriers harbour living organisms in their gall bladders. These are discharged into the alimentary tract from time to time, and eliminated through the fæces. Cholecystectomy in such cases rids the patient of his infection, and the community of a potential danger.

GALL-STONES (*syn.* CHOLELITHIASIS)

Ætiology.—" Every gall-stone is a monument to the germ which lies within it " (Moynihan). In other words, at some time previously there has been an attack of bacterial cholecystitis.

Types of Stones.—1. *The solitary calculus* is rounded, and may attain a great size. In some cases it consists of pure cholesterol, when it is feebly translucent, like tallow. More often, although consisting mainly of choles-

terol, there is a deposit of bile pigment in its composition (fig. 212).

2. *Multiple stones* (fig. 214) are the commonest. By mutual pressure they become faceted. When such a stone is bisected it will be seen to consist of alternating layers of cholesterol and bile pigments, hence these stones are also known as mixed calculi. The stones are frequently all much of the same size, which suggests that they were formed at one



FIG. 212.—Solitary gall-stone from a gall bladder. It is unfaceted.

FIG. 213.—Gall bladder packed with calculi. (X-ray after removal)

and the same time. Often the gall bladder is packed with these stones (fig. 213).

3. *Pigment stones* (fig. 215) are composed of bile pigments, and usually take the form of biliary mud. This type of calculus is more often found and formed in the bile ducts than in the gall bladder. Pigment calculi sometimes take the form of black grit, which on chemical analysis is shown to be calcium bilirubin.

Clinical Features.—A fat female of 40 is the classical sufferer. Useful as is this clinical memorandum, it should be remembered that gall-stones at a much earlier age occur quite often, and in both sexes, even occasionally in childhood.

Silent Gall-stones.—It is possible for calculi to be present in the gall bladder and give rise to no symptoms during a long lifetime. About 5 per cent. of adult necropsy subjects have stones in the gall bladder which have not contributed to the cause of death.

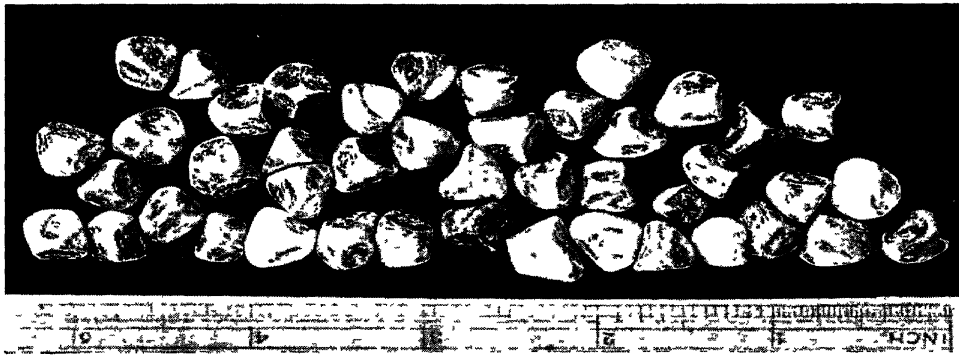

FIG. 214.—Multiple gall-stones.

Inaugural Symptoms.—Stones in the gall bladder usually give rise to reflex dyspepsia, which has been discussed under chronic cholecystitis. The patient feels distended after



FIG. 215.—Pigment stones and biliary mud.

meals ; women have to undo their corsets, and flatulency is a regular accompaniment. This stage may last for years, until one day a stone enters the cystic duct. Migration of the stone into the cystic duct is accompanied by :

Gall-stone Colic.[1]—Suddenly the patient experiences excruciating pain in the epigastrium and right hypochon-

[1] See Pseudo-biliary Colic, p. 453.

drium. The pain shoots to the back or between the shoulder blades. In severe cases it "doubles her up," and she rolls in agony on the floor. The attack often passes off as suddenly as it came on. In most cases heat somewhat relieves pain, and in old-standing cases a brown pigmentation of the skin over the right hypochondrium bespeaks frequent hot applications.

Physical Signs.—When examined soon after an attack of gall-stone colic a tender enlarged gall bladder may be palpated. Deep tenderness in the right hypochondrium can often be elicited even during the stage of the inaugural symptoms.

Murphy's Sign.—If continuous gentle pressure is exerted over the right hypochondrium (fig. 216) while the patient takes a deep



FIG. 216.—Murphy's sign. (Moynihan's method)

breath, there is a "catch in the breath" just before the zenith of the inspiration.

Boas's Sign.—There is an area of epicritic hyperæsthesia posteriorly between the ninth and eleventh dorsal segments of the right side.

STONES IN THE COMMON HEPATIC AND COMMON BILE DUCTS

While it is possible for stones to be present in the common bile duct without jaundice, the typical features of this condition are *colic followed by transient jaundice*. If the stone or stones pass onwards into the duodenum, the attack will last a few hours, at the most a few days. The patient becomes jaundiced, the stools are clay-coloured, and the urine dark. These symptoms pass off completely three or four days after cessation of pain. Bile can be demonstrated in the urine for

several days after the yellow tinge of the skin and conjunctivæ is no longer perceptible. **Impaction** of a stone (fig. 217) can occur in the supraduodenal or retroduodenal portions of the common duct, or at the ampulla of Vater. When impaction occurs, colic continues at varying intervals, but gradually the pain lessens and usually passes off completely. The jaundice deepens, but nevertheless varies in intensity from day to day. The skin commences to itch, sometimes intolerably. The patient loses weight. From the viewpoint of differential diagnosis perhaps the most important sign is that *in cases of calculus impaction the depth of the jaundice varies*. Another

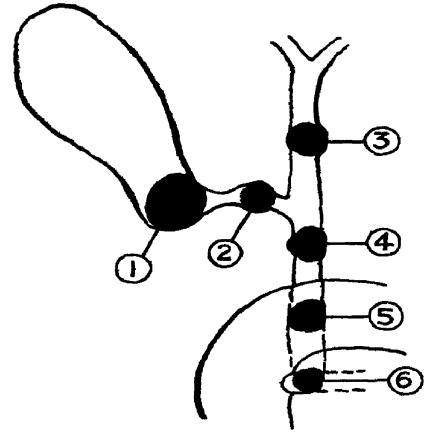

FIG. 217.—Usual sites of impaction of biliary calculi.
1. In Hartmann's pouch.
2. In the cystic duct.
3. In the common hepatic duct.
4. In the supraduodenal portion of the common duct.
5. In the retroduodenal portion of the common duct.
6. In the ampulla of Vater.

less reliable sign is the absence of a palpable enlargement of the gall bladder (see Courvoisier's law, p. 283).

With expectant treatment, most cases of calculus impacted in the common bile duct tend to improve for a time. If the obstruction is not relieved eventually the jaundice becomes profound.

Death usually follows in one of three ways :

(*a*) *The Liver ceases to Function.*—This is heralded by the secretion of "white bile." The ducts above the stone are found filled with a clear mucoid fluid. The finding at operation of white bile within the ducts is of grave, but not necessarily fatal, significance.

(*b*) *Suppurative Cholangitis* (*syn.* the Intermittent Hepatic Fever of Charcot).—Where there is stagnation of bile, in-

fection is prone to occur. Suppurative cholangitis is ushered in by a rigor, and later the temperature chart reveals sudden elevations, precipitate descents, and complete intermissions, known colloquially as the "steeple chart." There is loss of appetite and malaise. Pain is not a marked feature, but it may be referred to the right shoulder. The jaundice deepens, and an enlarged, tender liver can often be made out. Unless the bile passages are drained at the earliest possible moment—and the simplest method is by cholecystostomy—the condition is nearly always fatal. At necropsy an engorged, bile-stained liver riddled with multiple pin-head abscesses is found.

(*c*) The gall-stone ulcerates through the wall of the common duct, and general peritonitis supervenes.

BILIARY FISTULÆ

(*a*) **Due to a Stone ulcerating through the Wall of the Gall Bladder**

1. *Into the Duodenum.*—Gall-stones in the gall bladder may ulcerate through into the duodenum. This is the commonest internal

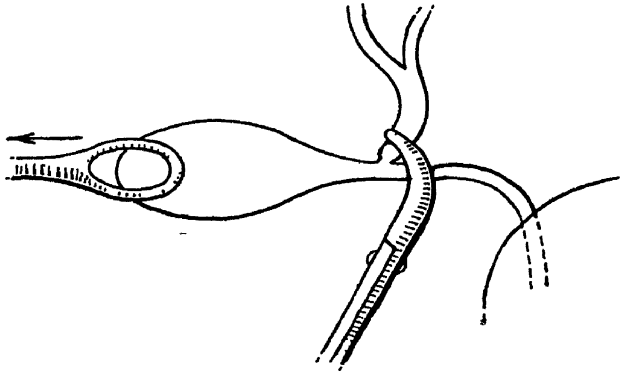

FIG. 218.—One method by which the common bile duct may be severed in cholecystectomy. The accident is more common when the gall bladder is removed from its fundus downwards.

biliary fistula. If the stone is over one inch in diameter, intestinal obstruction sometimes follows, the stone becoming impacted in the ileum (p. 341).

2. *Into the Colon.*—No untoward complication follows, as a rule, but a large stone may become impacted in the rectum.

3. *Through the Skin of the Umbilicus.*—The gall-stones are extruded on to the surface.

4. *Into the Peritoneum.*—General peritonitis quickly supervenes.

5. *Into the Ureter.*—The curiosity of a gall-stone in the urinary bladder has occurred.

6. *Into the Thorax.*—A broncho-biliary fistula results. The patient may cough up gall-stones.

(*b*) **Post-operative Fistula**

1. *After Cholecystostomy.*—Occasionally a cholecystostomy opening fails to close naturally. When the cystic duct is occluded, the

discharge is mucus. Especially if there is partial obstruction to the common duct, the fistula discharges bile.

2. *After Cholecystectomy.*—A biliary fistula after cholecystectomy usually means that the common bile duct has been injured or divided completely. This accident would never occur if the operation is performed in the manner described below. It is more liable to occur when the gall bladder is removed from its fundus downwards and a way in which this happens is depicted in fig. 218.

The Treatment of Gall-stones

Stones in the Gall Bladder.—Medical treatment sometimes relieves symptoms, but never removes stones from the gall bladder. Unless there is some definite contraindication to operation the correct treatment for stones in the gall bladder is cholecystectomy. Cholecystostomy (removal of stones and drainage) is now comparatively rarely employed, except in the aged, when operation has to be undertaken urgently for empyema of the gall bladder, or when adhesions are so dense as to render the identification of the junction of the cystic and common ducts impossible.

Fig. 219.—Cholecystectomy. The junction of the cystic, common hepatic, and common bile ducts has been displayed and the cystic artery has been clamped and divided.

Cholecystectomy.—It is important to have the patient in the "gall-bladder position," that is, with the back arched over a sandbag or some similar contrivance. The incision may be a right paramedian, transverse, or a Kocher's oblique, according to preference. When the peritoneum has been opened the gall bladder is located and examined. The field is isolated with packs, the liver rotated, and by dissection the junction of the cystic, the common hepatic, and the common bile ducts is displayed (fig. 219).

Removal of the gall bladder should never be commenced until all three ducts have been clearly exposed. The cystic duct is then divided between ligatures. The cystic artery is ligated and severed. From below upwards the gall bladder is dissected off the liver. After coapting the peritoneum over the raw surface on the under surface of the liver the abdomen is closed with drainage.



FIG. 220.—Choledochostomy. The stone has been seized with Desjardin's forceps.

Stone in the Common Duct.—If the patient is jaundiced the problem of treatment is more difficult. In most cases jaundice lessens, at any rate for a time, and usually it is advisable to spend several days in preparing the patient for operation. During this period rectal infusions of glucose are ordered. Kalzana, or some other calcium preparation, is given in order to lessen the bleeding at the time of the operation; as is well known, jaundiced patients tend to ooze from a cut surface. It is also useful to give biliary antiseptics (p. 267). Under this treatment, in a few cases, the jaundice completely abates, most are improved, and in the few where there is no improvement, operation must be hurried forward. In the last group a preliminary blood transfusion is of great service. In a jaundiced patient the length of the operation should vary inversely with the depth of the jaundice. Thus it comes about that where no improvement has occurred under expectant treatment the operation should be limited to opening the common bile



FIG. 221.—Transduodenal choledochostomy.

duct (choledochostomy), removal of stones, and drainage (fig. 220). When the stone is impacted in the ampulla of Vater the transduodenal route (fig. 221) will be chosen.

In patients in good condition cholecystectomy can be performed in addition to relieving the obstruction, but if the patient is jaundiced, it is wise to defer it. In all cases the post-operative treatment will include liberal infusions of glucose solution.

Reconstruction of the Common Bile Duct.—This difficult operation is indicated:

1. When the common duct has been severed by injury or at operation.
2. In cases of simple stricture of the bile duct, which is usually due to cicatricial contracture after stone impaction.

In recent cases end-to-end anastomosis of the duct over a rubber tube is sometimes practicable. The external fistula leading into the proximal end of the common duct has been dissected free and implanted into the duodenum. The most generally applicable method is Walton's modification of Sullivan's operation. Here the proximal end of the common duct is united to the anterior wall of the first part of the duodenum by means of a rubber drainage tube, a flap of the wall of the duodenum being used to fashion a new duct (fig. 222). Later the drainage tube is passed per rectum.

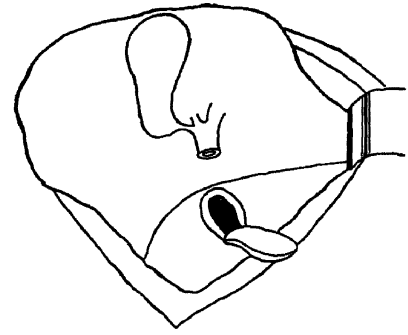

FIG. 222.—Walton's modification of Sullivan's operation. The first stage; the duodenal flap has been raised. (After Walton.)

CARCINOMA OF THE GALL BLADDER

Carcinoma of the gall bladder is much more frequent than is generally supposed. Fully 5 per cent. of cases of stones in the gall bladder are associated with carcinoma (Rolleston). This is a convincing testimony to the theory that carcinoma is often inaugurated by chronic irritation. There are no characteristic symptoms or signs; by the time there is an unmistakable palpable tumour the case is inoperable. When the neoplasm is confined to the gall bladder cholecystectomy offers considerable hope of a cure. Even when the growth has slightly involved the liver locally, cholecystectomy, together with extirpation of a wedge of liver substance, sometimes cures the patient.

THE PANCREAS

Acute Pancreatitis

Pathology.—The following outstanding features can be seen at necropsy. The great omentum and subperitoneal fat are studded with opaque areas termed fat necroses. If some of these are dabbed with a solution of cupric acetate they will be seen to stain an intense blue (Benda's test). Fat necroses are not always limited to the abdominal cavity. They can sometimes be demonstrated beneath the pleura and pericardium, and even in the subsynovial fat of the knee joint (Turnbull). The peritoneal cavity, especially the lesser sac, contains a blood-stained exudate, which in ultra acute cases seems to be almost pure blood. In 50 per cent. of cases the gall bladder contains stones.

Where the lesser sac has been drained and, as a consequence, life has been prolonged for some days up to a few weeks, portions of the peripancreatic tissue and even of the pancreas itself may have sloughed. These are represented by putty-like masses. In cases which survive, sloughs are sometimes extruded from the wound, and have shown upon analysis to be composed largely of calcium stearate.

In a few instances—but very few—there is some demonstrable cause for the pancreatitis, for instance, a round worm has been found blocking the ampulla of Vater, or a gall-stone has been found in a similar position.

Ætiology.—The cause of acute pancreatitis has not been fully elucidated.

The following theory (Eve's hypothesis) is a rational explanation of the widespread distribution of the fat necroses :

1. Bacteria can convert trypsinogen into trypsin (Mellanby).
2. In acute pancreatitis there is a *Bacillus coli* or other bacterial infection of the pancreatic ducts.
3. The bacteria liberate free trypsin in the inflamed pancreas.
4. This trypsin erodes the pancreatic tissue.
5. Thus all the pancreatic enzymes are set free, including :
6. Steapsin (lipase), which splits fat into glycerine and fatty acid.
7. The free fatty acid combines with calcium to form soaps=*fat necrosis.*

Clinical Features.—The patient is often a robust, fat man about 40 years of age, but we have met many exceptions to this rule. There is considerable accumulation of evidence to show that pancreatitis is recurrent, that is to say, the

patient is the victim of several visitations of the disease, which are at first mild, and ultimately culminate in the acute attack. The salient features by which the disease can be distinguished from other abdominal disasters are as follows :

Cyanosis.—Cyanosis is a fairly common accompaniment of the most acute forms of acute pancreatitis, and it is most marked in the cervico-facial region. The explanation generally given to account for the cyanosis is that the abdominal musculature and diaphragm are held so rigidly that the respiratory movement is embarrassed and anoxæmia results. Such a hypothesis is untenable, for the abdominal muscles, far from being held in vice-like con-



FIG. 223.—Loewi's Test. A positive reaction. (*B.M. Journal.*)

tracture, are usually relaxed. The cyanosis is undoubtedly due to the profundity of the toxæmia.

The pain is often severe, is mainly epigastric, and it passes through to the back. When the tail of the organ is involved there may be tenderness in the left costo-vertebræ angle.

Rigidity is not characteristic. Indeed, in many cases rigidity is conspicuous by its absence. This is an important point in differential diagnosis.

Loewi's Mydriatic Test.—The mydriatic test is a valuable scientific confirmatory sign which is easily applied. The pupils are examined : into one conjunctival sac 4 drops of fresh 1 in 1,000 adrenalin solution are instilled ; after five minutes 4 more drops are instilled, and the pupils examined again after half an hour. While adrenalin has no effect upon the pupil of a healthy individual, in acute pancreatitis a positive reaction—namely, dilatation of the pupil—is quite often obtained (fig. 223). The dilatation is not infrequently

slightly eccentric, and often conspicuously oval in form. A negative pupillary reaction implies nothing, but a positive result in an acute abdominal case is highly suggestive of acute pancreatitis.

Grey Turner's sign is a local discoloration of the skin. It usually occurs in the loin. The patches have the appearance of the skin in late extravasation. It is only seen in cases of some two or three days' standing. The condition is clearly due to the direct action of the pancreatic juice, which escapes by way of the retroperitoneal tissues, and passes by the most direct route to the surface.

FIG. 224.—Fat necrosis. A piece of omentum from a case of acute pancreatitis.

The diastatic index of the urine is not uncommonly raised from the normal 15 units to 150 or more. This test is not uniformly reliable; for instance, an increased index may be present in pneumococcal peritonitis.

Sugar in the urine is present in a small proportion of cases of acute pancreatitis. It is of little diagnostic significance, unless we know that glycosuria was not present previously.

Treatment.—Urgent laparotomy is imperative. The patient should be given anti-shock treatment while preparation is being made for the operation. During the interval the result of the mydriatic test may be observed. When the abdomen is opened the diagnosis is at once clinched by the blood-stained exudate and fat necroses (fig. 224). The pancreas is most readily explored by opening the lesser sac between the stomach and transverse colon (fig. 225). In a few cases, where there is ptosis of the stomach, the pancreas can be more conveniently exposed through the gastro-hepatic omentum. In most cases the operation should be

limited to drainage of the lesser sac and the general peritoneal cavity, and unless the condition of the patient is desperate, it is advisable to perform cholecystostomy in addition.

Suppurative Pancreatitis.—In those rare instances where suppuration has occurred around the pancreas, but the general peritoneal cavity is not affected, posterior drainage by an incision beneath the twelfth rib and burrowing up with the finger towards the head of the pancreas may be employed with advantage.

Post-operative Treatment.—As soon as the patient has been returned to bed, continuous saline infusion must be commenced. The escaping pancreatic juices tend to digest the abdominal wall and the sutures contained therein. "Burst abdomen" is not an uncommon complication, and should be guarded against by suitably supporting the incision. Digestion of the skin around the wound can be effectively prevented by smearing the skin with an ointment containing 2 per cent. of hydrochloric acid, which renders the pancreatic ferments impotent.

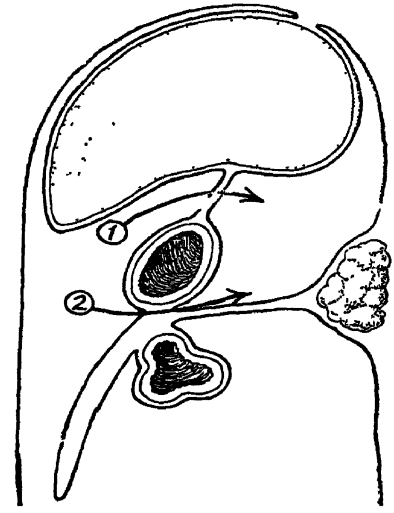

FIG. 225.—Routes of approach to the pancreas.

1. Through the gastro-hepatic omentum. (Rarely used.)
2. Between the stomach and the colon.

Pancreatic asthenia sometimes occurs, especially during the end of the first week after an operation for acute pancreatitis. There is weakness, a mask-like expression, and a drawling voice, muscular relaxation, and a tendency to salivation. The only treatment of value is blood transfusion.

MORTALITY.—Acute pancreatitis is perhaps the most serious intra-abdominal inflammatory catastrophe. With early operation nearly 50 per cent. recover, but as has been pointed out, a few of these fall victims to a similar attack later.

Subacute pancreatitis gives rise to symptoms similar to those of acute cholecystitis. Its close relationship to an

ultimate attack of acute pancreatitis has been insisted upon already.

Chronic pancreatitis is a condition quite apart, and will be considered later.

INJURIES TO THE PANCREAS

Type 1.—The patient, who has had a severe injury to the upper abdomen, presents signs of a serious lesion of some intra-abdominal organ, and it is thought wise to explore. When the pancreas is the injured organ, there is often blood-stained fluid in the lesser sac, and fat necroses are sometimes present.

Type 2 (Milder Injuries).—The first intimation that the pancreas has been lacerated is often the development of a pseudo-pancreatic cyst.

Treatment.—When the abdomen has been opened soon after the injury a ruptured pancreas has several times been successfully repaired by sutures. Other cases have recovered by simply packing the rent and draining the lesser sac. Drainage is essential in all cases.

PANCREATIC CALCULI

Stones in the pancreatic ducts are infrequent. The symptoms are similar to those of chronic pancreatitis or to gall-stones. Pancreatic calculi have been demonstrated radiologically.

Treatment.—The stone, or stones, should be removed by an incision into the duct of Wirsung through the substance of the pancreas, or by slitting up Oddi's sphincter according to circumstances. After the pancreas has been incised drainage is essential.

PANCREATIC CYSTS

1. **True Pancreatic Cysts** (fig. 226) (40 per cent. of all cases).

(*a*) *Retention cysts*, due to impaction of pancreatic calculi or fibrosis around the duct of Wirsung.

(*b*) *Cyst Adenomata.*—One-third of all true cysts belong to this group.

(*c*) *Congenital Cystic Disease.*—Very rare indeed.

(*d*) *The ubiquitous hydatid* completes the list.

2. **Pseudo-pancreatic cysts** (fig. 227) (60 per cent. of all cases). These are due to injury of the pancreas, or, rarely, to pancreatitis.

Clinical Features.—*True Cysts.*—The clinical features are very variable, and differ with the size of the cyst or cysts. Epigastric discomfort and a palpable tumour are the leading signs. When large there is a fixed cystic swelling above the umbilicus, which transmits aortic pulsation. The latter is less in evidence in the knee-elbow position. A differential diagnosis has to be made, principally from an ovarian cyst. In smaller, multiple cysts it is

probable that the diagnosis will not be made until the abdomen has been opened.

Pseudo-cysts are much more readily diagnosed. Following an injury, a supra-umbilical cystic swelling appears. This usually takes several weeks to form, and is due to the lesser sac becoming filled with fluid. An injured or inflamed pancreas, with ferments leaking therefrom into the lesser sac, is the cause.

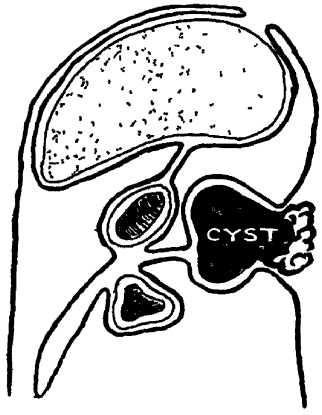

FIG. 226.—True pancreatic cyst.

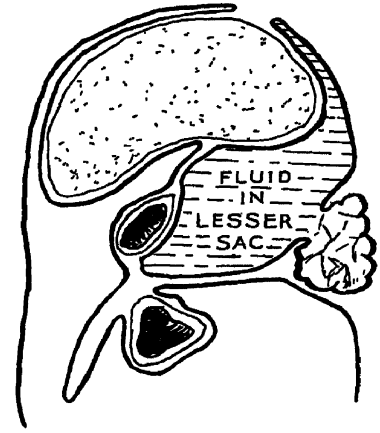

FIG. 227.—Pseudo-pancreatic cyst.

Treatment.—Large retention cysts are treated by marsupialisation; that is, by stitching the peritoneum to the sac wall, and then draining through the extraperitonealised portion of the cyst wall. An endeavour should be made to remove pancreatic calculi, if such be present. Failing this fortunate possibility, a permanent pancreatic fistula is likely to follow. A cyst-adenoma, affecting only the tail of the pancreas, has been resected successfully. When the cyst or cysts are small they should be removed by dissection.

Pseudo-cysts can be very satisfactorily treated by drainage of the lesser sac between the stomach and the colon. The fluid, which is rich in pancreatic ferments, continues to drain away for some time, but after about six weeks the sinus usually closes.

CHRONIC PANCREATITIS

Chronic pancreatitis is not an uncommon disease, but the symptoms are obscure, and the diagnosis is always fraught with considerable difficulty. There are four main types of chronic pancreatitis :

Type 1. Associated with Gall-stones.—This is the commonest type, and sometimes attention is first drawn to it after the gall bladder has been removed and the symptoms still persist.

Type 2. Associated with Obstruction of the Common Bile Duct.—A chronically inflamed and probably fibrotic head of the pancreas

causes constriction of the common bile duct near its termination. Jaundice is a leading symptom. This type is difficult, if not impossible, to distinguish from carcinoma of the head of the pancreas (p. 283).

Type 3. Associated with Diabetes.—There is a widespread fibrosis, which destroys the islets of Langerhans, as well as the external secretory mechanism.

Type 4. As a cause of Chronic Dyspepsia.—Here the diagnosis of chronic gastric ulcer will probably be made, only to be ruled out by further investigation.

Clinical Features.—There are no pathognomonic symptoms or signs of chronic pancreatitis. It is exceedingly unlikely that the enlarged, hardened pancreas will be felt on palpation. Even when the abdomen has been opened, it is difficult to be certain that a pancreas is larger and harder than normal, or of the exact nature of a mass in the head of the pancreas. The diagnosis of chronic pancreatitis must rest largely in laboratory tests, of which the following are important.

TESTS FOR PANCREATIC INSUFFICIENCY

(*a*) **Of the External Secretion**

1. *Steatorrhœa.*—The normal fat content of the fæces is about 20 per cent., but in chronic pancreatitis it may rise to between 50 per cent. and 90 per cent.

2. *Coope's Test.*—There are (microscopically) many unaltered striated meat fibres in the fæces.

3. *Kashiwado's Test.*—The patient swallows a muslin bag containing chopped thymus. This is recovered from the fæces, and an investigation is made as to the number of cells with undigested nuclei. In pancreatic disease they are numerous.

4. *Sahli's Test.*—Salol is given by mouth, and under normal conditions it will be split up by the trypsin into salicylic acid and excreted in the urine. If no salicyluric acid can be found in the urine by chemical examination, the secretion of trypsin has diminished.

5. *The diastatic index of the urine* is often increased in pancreatitis (p. 278).

(*b*) **Of the Internal Secretion**

1. *Loewi's Mydriatic Test* (p. 277).

2. *The Cammidge Reaction.*—Osazone crystals form in the presence of phenyl-hydrazine in the urine of a patient who has a defective internal secretion of the pancreas.

Treatment.—In early cases associated with gall-bladder disease, cholecystectomy may arrest chronic pancreatitis. In cases where fibrosis in the head of the pancreas has caused obstruction to the common bile duct, cholecystgastrostomy will cure the jaundice and ameliorate symptoms. In view of

the possible development of common bile-duct obstruction, cholecystgastrostomy appears to be a rational method to adopt even in earlier cases of chronic pancreatitis, providing the walls of the gall bladder are even moderately elastic. In widespread fibrosis of the pancreas there is no effective treatment, and in this respect the disease is comparable to hepatic cirrhosis. Pancreatic extracts should be tried.

Carcinoma of the Head of the Pancreas

Pathology.—The tumour never attains the size of a fist; rarely is it more than a quarter of this size.

Histologically there are three types of carcinoma of the pancreas:
1. *From the Acini.*—A spheroidal-celled carcinoma with a large amount of fibrous tissue. This is the commonest.
2. *From the Ducts.*—A columnar-celled carcinoma.
3. *From the Islets of Langerhans.*—This variety has much larger cells, with relatively enormous nuclei.

Dissemination is late and rare. The growth kills the patient by its local effect of blocking the common bile and pancreatic ducts.

Clinical Features.—*Jaundice*, steadily progressing, is the leading symptom. The icteric tinge becomes deeper and deeper, until, in some cases, the skin and conjunctivæ assume an almost mahogany shade. It should be noticed that in carcinoma of the head of the pancreas, jaundice precedes the pain.

Pain comes on late in the disease, and is usually not severe, but a continuous discomfort. Severe pain, attributed to cœliac neuralgia, has been noted in some cases, although we have not observed it.

Wasting occurs, but this is not diagnostic, for patients with a stone impacted in the common bile duct also waste rapidly.

The gall bladder is distended in accordance with Courvoisier's law.

Courvoisier's law states that if in a jaundiced patient the gall bladder is enlarged, it is *not* a case of stone impacted in the common bile duct, for previous cholecystitis must have rendered the gall bladder fibrotic. There are a few exceptions to this law, notably double impaction, when there is one stone in the cystic and another in the common bile duct, and a pancreatic calculus causing obturation at the ampulla of Vater.

There are signs of deficient external secretion of the pancreas (p. 282).

When very advanced, obstruction of the portal vein and even of the duodenum sometimes occurs.

At times it is difficult to be certain if, in a given case, the jaundice is obstructive or non-obstructive. Here laboratory tests are of value.

The van den Bergh *reaction* **is a test for bilirubin in the blood. The test is a modification of Ehrlich's diazo reaction.**

The immediate direct reaction **indicates the presence of uncombined bilirubin, and suggests the existence of mechanical obstruction.**

The delayed direct reaction **indicates impaired liver function (e.g. acute atrophy of the liver).**

A biphasic reaction **suggests both obstruction and impaired liver function.**

It is impossible to distinguish clinically carcinoma of the head of the pancreas from carcinoma of the common bile duct. The latter is not very uncommon, and is occasionally associated with stones in the duct. Unlike carcinoma of the head of the pancreas, a carcinoma of the common duct often metastasises early.

The Treatment of Carcinoma of the Head of the Pancreas (which includes Carcinoma of the Common Bile Duct).—Even when the abdomen has been opened it is not always possible to say definitely if an indurated head of the pancreas is a carcinoma or a chronic inflammation. Thus it comes about that in a very few cases, if an obstruction to the flow of bile is circumvented, to everyone's surprise the patient remains well for years. The operation of choice in irremovable obstruction to the common duct is **Cholecystgastrostomy.** When the patient is deeply jaundiced, preliminary cholecystostomy is recommended by some, and fourteen days later, at a second operation, the gall bladder is anastomosed to the stomach.

Radium and radon have been tried for the treatment of the primary growth in the pancreas. Observing that this is the only possible radical treatment, it should be attempted whenever circumstances permit.

CHAPTER XVII

THE PERITONEUM, OMENTUM, MESENTERY, AND RETROPERITONEAL SPACE

Acute Peritonitis

Nearly all types of peritonitis are due to an invasion of the peritoneal cavity by bacteria. To such an extent is this true, that when the term " peritonitis " is used without qualification, bacterial peritonitis is assumed.

The bacteria most often responsible are :

1. Bacillus coli communis.
2. Streptococcus.
3. Staphylococcus aureus.
4. Pneumococcus.
5. Bacillus pyocyaneus.

Mixed infection is very common.

The bacteria gain access to the peritoneal cavity in various ways. Prominent amongst these is through a breach of continuity of the alimentary canal, which is always swarming with organisms.

Paths of Bacterial Invasion.—1. Via perforation of the gastro-intestinal tract, e.g. perforated appendix.

2. By transmigration through damaged gut wall, e.g. unrelieved intestinal obstruction.

3. From or via the Fallopian tubes.

4. Through a penetrating wound of the abdominal wall.

5. Hæmatogenous infection.

Even in non-bacterial peritonitis, after a few hours, or at the most days, the peritoneum becomes infected by transmigration of organisms from the bowel, and so what may be termed mechanical or chemical peritonitis becomes a peritonitis in the usual sense of the term. Some of the more common non-bacterial forms of peritonitis are as follows :

1. As a result of a hæmoperitoneum.
2. From leakage of sterile bile, such as may be occasioned from traumatic rupture of the gall bladder.
3. Extravasation of urine into the peritoneal cavity from intraperitoneal rupture of the bladder.

4. From bursting of an aseptic hydatid or ovarian cyst.
5. From rupture of a gastric or duodenal ulcer. The mechanical peritonitis in this case is very transient, but none the less definite.

Clinical Features.—In the first instance peritonitis is commonly a more or less localised lesion. Prominent amongst the agents which attempt to localise intraperitoneal infection is the great omentum (p. 301).

Peritonitis can be divided into :

1. Localised.
2. Localised but diffusing.
3. Diffuse.

Localised.—The symptoms and signs of localised peritonitis are variable and intimately wrapped up with those of the original lesion, e.g. acute appendicitis, acute diverticulitis, etc. (*q.v.*).

Localised but Diffusing.—A good example of this variety is to be found in pelvic peritonitis. Here the rigidity and later distension are limited to the lower abdomen. Rectal or vaginal examination reveals tenderness of the pelvic peritoneum. Although the patient looks and feels ill, and probably vomits, the condition, though serious to be sure, is less grave than the similar process commencing or extending into the upper abdomen.

Diffuse Peritonitis.—While a perforated gastric ulcer gives rise almost immediately to a diffuse peritonitis, this is initially chemical or mechanical peritonitis due to the gastric juice or food which has escaped. We are referring now rather to the diffuse bacterial lesion. By the time a state of diffuse bacterial peritonitis has been reached the patient's condition is always grave. Considerable widespread abdominal rigidity, the key-note of early diffuse peritonitis, later to some extent passes off, and gives place to distension. Respirations tend to be mainly of the costal type, the patient sparing himself all unnecessary movement of his acutely tender abdomen. Vomiting is frequent, soon becomes effortless, and takes the form of regurgitation of mouthfuls of bile-stained material. The temperature is usually, but not necessarily, raised. Nearly all these symptoms and signs

are modified or abolished by the administration of morphia. Under the influence of a narcotic the patient may feel and look comparatively well, while the peritonitis spreads apace. In dealing with these cases the watchword should be "*avoid opium until the diagnosis has been made and permission for operation obtained.*"

A rising pulse-rate is of ominous significance. Later still the pulse becomes thready and rapid, the eyes sunken but bright, and the facies drawn and anxious. By this time there is little to do but to regret, too often, that a correct diagnosis was not made at an earlier stage of the infection.

Treatment.—The treatment of acute peritonitis is essentially operative, but as the object of any operation is to aid Nature, the time at which it is to be performed must be well chosen. If the diagnosis is made within the first twenty-four hours immediate operation is to be recommended almost invariably. It should be the clinician's highest aim to diagnose cases of peritonitis within this period, and save his patient the possibility of a spreading infection by removing the focus or stopping the leak. The advance of operative surgery in this direction has been remarkable, but hardly less so than the triumph of postural treatment, its handmaiden.

George Ryerson Fowler was born in New York in 1848. With the help of his son Russell he evolved what is universally known as Fowler's position. Fowler the elder died of acute appendicitis on February 6th, 1906. His name must ever be linked inseparably with the greatest advance in the treatment of peritonitis.

Fowler's position favours internal drainage of the infected peritoneal fluid into the pelvis. This position is used after all operations for peritonitis, and in cases of peritonitis awaiting operation.

High Fowler's Position.—The head of the bed is raised 18 in., and pillows and bolsters are arranged so that the patient is in a semi-sitting position (fig. 228). In order that he should not slip down the bed a support is placed beneath the knees. High Fowler's position is used in widespread peritonitis providing the patient's pulse is adequate.

Low Fowler's position is similar to the above, except

that the head of the bed is not elevated. This position is used in the more localised forms of peritonitis.

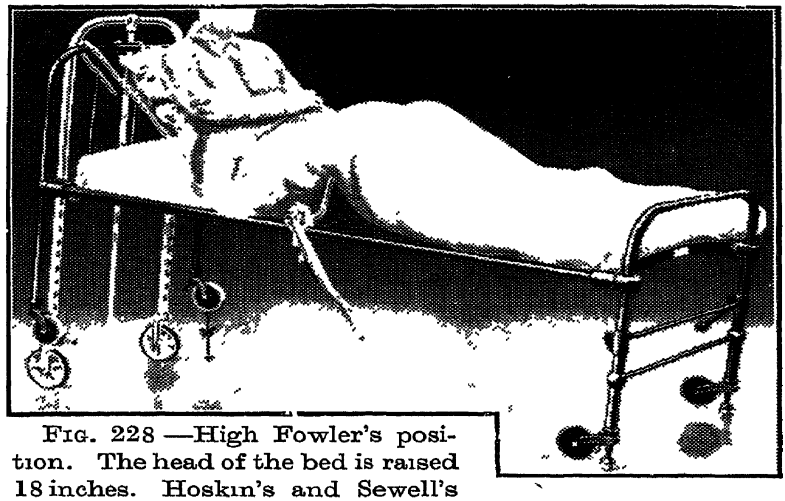

FIG. 228 —High Fowler's position. The head of the bed is raised 18 inches. Hoskin's and Sewell's bed-lifter in use. Wooden blocks can be used.

The administration of salt solution in considerable quantities is definitely beneficial in the treatment of acute peritonitis. Perhaps the most useful method of giving the saline in a form in which it is steadily absorbed is by the continuous rectal drip (Murphy's drip). Gravitation from a thermos flask (fig. 229) is rightly popular, for it is a method of ensuring a small but even flow of warm saline into the rectum. Proctoclysis favours the absorption of much fluid while the irritable stomach and inflamed intestines rest. In severe cases, or when the saline is not absorbed from the rectum, the continuous administration of saline intravenously has proved a life-saving measure.

FIG. 229. — The treatment of peritonitis. Patient in Fowler's position. Continuous proctoclysis with Souttar's apparatus.

The Operative Treatment of Peritonitis.—In early cases of peritonitis, if the focus of infection be removed

the abdomen often can be safely closed without drainage. The capability of the peritoneum to overcome a certain amount of infection is truly remarkable. In later cases drainage is all-important, and offers the greatest hope of a successful issue. In diffusing or diffuse peritonitis drainage must be accompanied by removal of the focus of infection or suture of the perforation. Unlike the excellent result which can usually be expected after simple drainage of a localised intra-peritoneal collection of pus, simple drainage of the peritoneal cavity in a non-localised peritonitis accomplishes little—indeed, in many cases it appears to hasten the end. On the other hand, removal of the focus of infection plus drainage is often a life-saving procedure.

The details of the operative treatment of peritonitis are considered with the individual lesions which habitually give rise to it, e.g. acute appendicitis, perforated gastric ulcer, etc.

The Ochsner Treatment of Peritonitis.—Ochsner of Chicago taught that in certain cases of peritonitis it was unwise to operate immediately. Broadly speaking, the cases to which this treatment can be applied fall into two categories.

1. Where the peritonitis has been present for two days or more and Nature has localised the infection. To disturb adhesions is to invite a possible spreading peritonitis.

2. In cases of grave diffuse peritonitis, where it is judged that the patient would not survive an immediate operation more than a few hours, in the hope that the general condition will improve and the infection become localised.

The Ochsner treatment should never be conducted deliberately anywhere but in a surgically equipped institution. The patient is placed in high Fowler's position. All food is withheld, water only being allowed by mouth. In necessary cases saline is administered, and if vomiting is much in evidence the contents of the stomach are aspirated. Further details of the treatment will be found in Chapter XX.

Complications of Peritonitis

All the complications of a severe bacterial infection are possible, but we refer rather to the special complications of peritonitis :

1. Intestinal obstruction (p. 340).
2. Paralytic ileus (p. 343).
3. Persistent hiccough.
4. Residual abscesses (fig. 230).

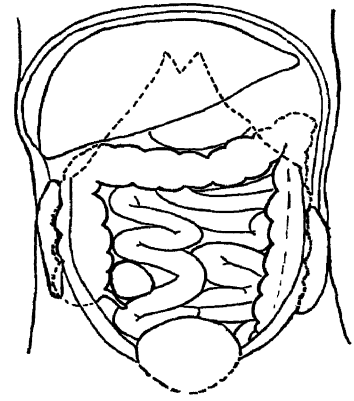

Fig. 230.—Common situations for residual abscesses.

It remains to describe in detail two common forms of residual abscess, viz. pelvic abscess and subdiaphragmatic abscess.

Pelvic abscess is common, because the vermiform appendix is commonly pelvic in position and the Fallopian tubes are also a frequent focus of infection. Even if this were not so it might be expected that the incidence of pelvic abscess would be high, for are not all cases of peritonitis nursed in Fowler's position, which favours accumulation of infected material in the pelvis ? Pus can accumulate in this area without serious constitutional disturbance, and unless the patient has been carefully examined from day to day, such abscesses may attain considerable proportions before being recognised. The most characteristic symptoms of a pelvic abscess are diarrhœa and the passage of mucus in the stools. It is no exaggeration to say that the passage of mucus occurring for the first time in a patient who has, or is recovering from, peritonitis is pathognomonic of pelvic abscess. Rectal examination reveals a bulging of the anterior rectal wall which, when the abscess is ripe, becomes softly cystic. It is inaccurate to say that it fluctuates, unless fluctuation can be elicited between it and the abdominal wall. Fluctuation cannot be tested with one finger. Left to Nature, a proportion of these abscesses burst into the rectum, after which the patient nearly always recovers rapidly. It is far too risky to wait for this possible happy termination. A pelvic abscess should be drained deliberately. In certain cases, notably those where the primary focus is in the Fallopian tubes, vaginal drainage through the posterior fornix is chosen. In other cases, where the abscess is definitely pointing into the rectum, rectal drainage (fig. 231) is employed. We have found this method exceedingly efficacious in selected cases, but have sometimes first opened the abdomen in order to be quite certain of the diagnosis. Providing the abscess is shut off from the general

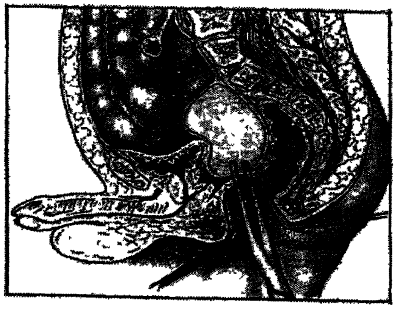

Fig. 231.—Opening a pelvic abscess into the rectum.

peritoneal cavity, a point which can be ascertained undeniably when the abdomen has been opened, rectal drainage of a pelvic abscess is preferable to suprapubic drainage, which in many cases unavoidably breaks down Nature's barriers, and exposes the general peritoneal cavity to the dangers of spreading infection.

SUBPHRENIC ABSCESS

Anatomy.—The complicated arrangement of the peritoneum and its attachment to the various organs and structures under the dia-

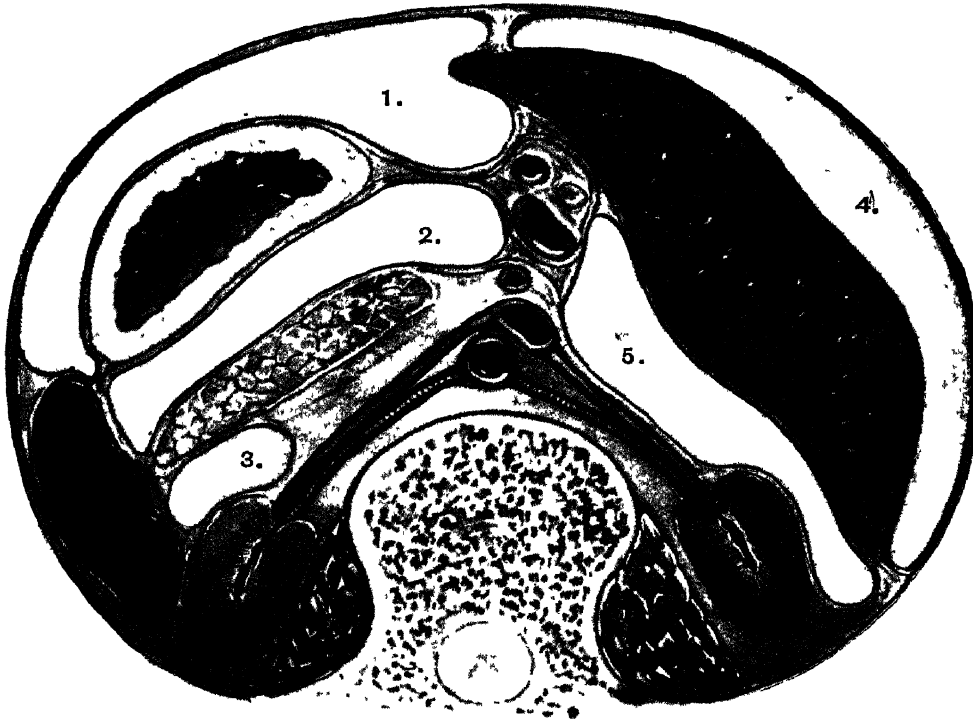

FIG. 232.—Diagram showing anatomical relationships of five types of subphrenic abscess. 1. Left anterior intraperitoneal: 2. Left posterior intraperitoneal: 3. Left extraperitoneal: 4 Right anterior intraperitoneal: 5. Right posterior intraperitoneal.

phragm results in the formation of seven spaces in which pus may collect. Three of these spaces are on either side of the body, and one is approximately in the mid-line (fig. 232).

Left Side.—*Anterior intraperitoneal*, bounded above by the diaphragm, behind by the left lateral ligament and left lobe of the liver, the gastro-hepatic omentum and anterior surface of the stomach. To the right is the falciform ligament, and to the left the spleen, gastro-splenic omentum, and diaphragm. When pus is present the space is closed below by adhesions between the stomach or great omentum and the diaphragm or anterior abdominal wall.

Posterior intraperitoneal, which is the upper part of the lesser sac (or omental bursa). Consequently, it is bounded behind by the diaphragm, pancreas, mesocolon, and transverse colon, in front by the Spigelian lobe, gastro-hepatic omentum, and stomach, and to the left by the lieno-renal ligament, spleen, and gastro-splenic omentum. On the right side is the proximal third of the first part of the duodenum, above which is the foramen of Winslow, through which the lesser sac communicates with the right posterior intraperitoneal space.

Extraperitoneal, which is normally only a potential space. When an abscess forms, pus collects near the upper pole of the left kidney, and strips the peritoneum off the diaphragm. The space so formed is bounded above by the diaphragm, behind by the left suprarenal and upper part of the left kidney, and anteriorly by the œsophagus, bare area of the stomach, and lesser sac. To the left is the diaphragm, and to the right the aorta and vertebræ.

Right Side.—*Anterior intraperitoneal*, which lies between the superior, anterior, and right lateral surfaces of the right lobe of the liver and the corresponding part of the diaphragm. It is limited posteriorly by the anterior layer of the coronary and the right lateral ligaments, and to the left by the falciform ligament.

Posterior intraperitoneal (*syn.* Rutherford Morison's kidney pouch) is pyramidal in shape, and lies transversely beneath the right lobe of the liver. To the right the base is in contact with the right lobe of the liver and the diaphragm, but it extends to a somewhat lower level, and can consequently be approached from beneath the twelfth rib. To the left the apex is situated at the foramen of Winslow, and below this lies the duodenum. In front are the liver and gall bladder, and behind the upper part of the right kidney and diaphragm. The space is bounded above by the liver, posterior layer of the coronary, and the right lateral ligaments, and below by the transverse colon and hepatic flexure. Communication exists with the lesser sac through the foramen of Winslow, but when an abscess occurs this aperture becomes closed by adhesions.

Extraperitoneal, which is the " bare area " of the liver, where it is separated from the diaphragm merely by cellular tissue. This area is bounded anteriorly by the right lobe of the liver and right suprarenal body, posteriorly by the diaphragm, to the left by the inferior vena cava and right crus of the diaphragm. Above is the anterior layer of coronary ligament, below is the posterior layer of coronary ligament. and to the right these two layers fuse to form the right lateral ligament. In front the cellular tissue is continuous over the summit of the liver with that in the falciform ligament. Inferiorly the space extends behind the ascending colon into the lumbar region.

Falciform Ligament.—The two layers which form this ligament are occasionally separated by a collection of pus, which either tracks forwards from the bare area of the liver, or arises from infection around the umbilicus.

Ætiology.—The commonest causes of subphrenic abscess are appendicitis, and gastric or duodenal ulcers, especially following perforation or operation. In the investigation of a series of seventy-eight cases of subphrenic abscess, we found that appendicitis was the cause in no less than thirty. However, owing to the universal adoption of Fowler's position, and the growing tendency to select

the time for operation with discretion, subphrenic abscess is a less common complication of appendicitis than formerly. Less common causes include hepatic and biliary infection, gastric carcinoma, diverticulitis, and renal infections. The condition occasionally arises apparently *de novo*, in which case hematogenous infection of the cellular tissue is a possible cause. Although an empyema is frequently associated with a subphrenic abscess, yet infection of the subphrenic spaces very rarely follows an empyema.

A consideration of the anatomical arrangement of the subphrenic spaces will indicate which type of abscess is likely to be associated with any particular lesion.

Clinical Features.—The symptoms and signs of subphrenic infection are frequently obscure, and when the diagnosis of subphrenic abscess is a possibility, it is well to remember the aphorism, "Pus somewhere, pus nowhere else, pus under diaphragm." Not infrequently the diagnosis is only made by exclusion of pus elsewhere, and after exploration of the subphrenic spaces.

Symptoms.—The typical history is that when some infective focus in the abdominal cavity has been dealt with, the condition of the patient improves temporarily, but after an interval of a few days or weeks, symptoms of toxæmia reappear. Owing to rapid absorption of toxins, the patient steadily, and often rapidly, loses ground. Sweating, wasting, and anorexia are present. The patient sometimes complains of epigastric fullness, abdominal discomfort or pain in the shoulder on the affected side, owing to irritation of sensory fibres in the phrenic nerve, and referred pain along the descending branches of the cervical plexus. We have found that the exact site of the pain is useful in determining the position of the abscess. Thus, irritation of the anterior part of the diaphragm causes pain to be referred along the supra-clavicular nerves, i.e. the front of the shoulder, while a posterior abscess causes pain over the back of the shoulder, via the supra-acromial nerves.

Signs.—General signs are those of toxæmia, and include an irregular and often intermittent temperature, with increasing listlessness, wasting, and anæmia.

If the abscess is anterior, abdominal examination will reveal some tenderness, rigidity, or even a palpable swelling. In a few cases the liver is displaced downwards, but more often it is fixed by adhesions. Examination of the chest is of extreme importance, and in the majority of cases pressure signs at the base of the lung, or evidence of effusion or empyema are to be found. Anaerobic organisms in the pus sometimes form gas in sufficient

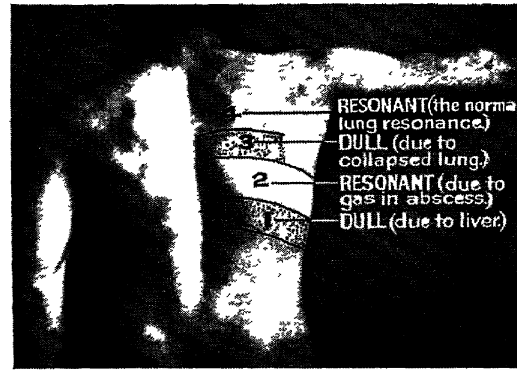

FIG. 233.—Subdiaphragmatic abscess with gas. The four areas of differential percussion.

quantities to be recognised clinically. In these cases percussion demonstrates four zones. Below, the note is dull over the liver; above this a tympanitic note is obtained owing to gas in the abscess; at a higher level a pleural effusion or collapsed lung yields a dull note, and above this the normal resonance of the lung is obtained.

Accessory Investigations

(i) *Blood Count.*—A relative and absolute leucocytosis is the rule.

(ii) *X-ray.*—A simple radiograph sometimes demonstrates the presence of gas, or of a pleural effusion.

On screening, three points may be noted:

(*a*) Elevation of the diaphragm, which on the right side normally reaches the fifth rib, and on the left side extends to the fifth space.

(*b*) Diminished mobility, i.e. less than the usual excursion of 1–1½ in. during deep breathing.

(*c*) Alteration of contour due to the underlying localised collection of pus.

(iii) *Needling.*—Which is the final court of appeal.

If the needle has penetrated a subphrenic abscess the movements of the diaphragm are transmitted to the needle, which consequently oscillates during respiration. In the case of an empyema these movements are absent. Needling should always be performed in the operating theatre, and if pus is discovered the needle is left *in situ* as a guide to the abscess, and the operation performed forthwith. Promiscuous needling is to be condemned, as infection may occur along the needle track, and subsequent exploration sometimes fails to rediscover the abscess.

Differential Diagnosis.—*Pylephlebitis* (*syn.* Portal Pyæmia) is often due to the same causes as a subphrenic abscess, so that the history is identical. However, portal pyæmia frequently commences with a rigor, and rigors sometimes continue at intervals during the course of the disease. A tender, enlarged liver is usually palpable in pylephlebitis, and jaundice occasionally occurs, owing to an abscess compressing an intrahepatic bile duct. Radiographic evidence is often valuable in distinguishing these conditions.

Tropical abscess of the liver closely simulates a subphrenic abscess. The history of the case, the discovery of amœbæ in the stools, and the reaction to emetine may assist in forming a correct diagnosis.

Empyema, as already mentioned, is often associated with subphrenic cellulitis or infection. Needling is sometimes necessary to ascertain the precise position of the pus.

Other conditions which have been confused with a subphrenic abscess include perinephric abscess, splenic infarct following ulcerative endocarditis, aortic aneurism, pancreatic cysts, and renal tumours, but the characteristic features of these conditions should distinguish them.

Treatment.—*Prophylactic* measures play an important part in the prevention of subphrenic infection. As already stated, careful consideration of the best time to operate in certain types of acute appendicitis will avoid spread of infection and separation of protective adhesions. In the case of any abdominal infection, Fowler's position encourages inflammatory exudates to gravitate into the pelvis. Adequate abdominal drainage is important, and in the case of acute

appendicitis, should be obtained either suprapubically or through a stab wound in the loin, rather than through a grid-iron incision. Cases of cholecystectomy should always be drained, as bile is likely to ooze from the raw bed of the gall bladder. An operation for a perforated ulcer should include careful toilet of the peritoneum, with suprapubic drainage if deemed necessary.

Operative treatment comprises drainage of the abscess. If a swelling can be detected in the subcostal region or in the loin, an incision is made over the site of maximum tenderness, or over any area where softening, œdema, or redness is discovered. The parietes usually form part of the abscess wall, so contamination of the general peritoneal cavity is unlikely.

When needling is indicated, a wide-bore needle is inserted through the lower intercostal spaces in the posterior axillary line. If no pus is discovered, the needle is reinserted along the mid-axillary and paravertebral lines. When pus is discovered the needle is left *in situ*, and part of the rib immediately below is excised subperiosteally. In the absence of adhesions, the parietal pleura is stitched to the diaphragm. This is always a wise procedure if the resected rib is above the ninth, as in these cases, when pus is evacuated the diaphragm collapses to such an extent that adhesions between it and the parietal pleura are likely to separate, and so allow infection of the pleura cavity. The diaphragm is incised across its fibres, so that retraction will encourage drainage. The pus is then evacuated, and a large drainage tube inserted.

The mortality of operations for subphrenic abscess is about 30 per cent. The reason for this high figure is that many cases are allowed to languish too long before the condition is thought of, or before exploration is performed, and also the subphrenic "spaces" are, more correctly, nooks and crannies, so that collections of pus tend to ramify and so become more or less completely separated from their parent abscess.

Special Forms of Acute Peritonitis not considered Elsewhere

Pneumococcal Peritonitis.—There are two forms of this disease:

1. Secondary to pneumonia.
2. Primary pneumococcal peritonitis.

In the latter variety, which is the more common, infection probably often occurs via the Fallopian tubes.

The patient is usually a little girl of about 5 years of age, underfed and undernourished. While pneumococcal peritonitis can be suspected in such a patient, it can hardly be distinguished from acute appendicitis with pelvic or diffuse peritonitis, unless an epidemic of pneumonia is rife. Rightly, the abdomen is opened as for acute appendicitis. The ap-

pendix is examined, and doubtless will be inflamed on the outside, in common with the other viscera, but there is no perforation. If the operator doubts the innocence of this organ it may be removed, when it can be demonstrated that it is more inflamed on the outside than the inside. The nature of the pus in pneumococcal peritonitis is often so characteristic as to leave no doubt as to the nature of the infecting organism, for it is slimy and of a green tinge.

Treatment.—Pneumococcal peritonitis is always a grave condition. Early operation under gas and oxygen anæsthesia offers the best prospect. The operation should be conducted as quickly as possible, and limited to draining the peritoneal cavity suprapubically. Blood transfusion, which is definitely beneficial in these cases, is best performed when signs of septicæmia are just commencing; this is usually before the peritoneal cavity has been drained. A small second transfusion later is sometimes beneficial. In desperate cases, especially those secondary to pneumonia, the Ochsner treatment is recommended by some, and is rewarded occasionally by localisation of the pus in the pelvis. If localisation of the pus occurs, drainage is almost always followed by rapid convalescence.

Primary streptococcal peritonitis is a very fatal condition, and the most difficult form of peritonitis to understand. If the disease was limited to females, one could picture the organism reaching the peritoneal cavity through the Fallopian tubes, but, as it also occurs in males, and often at necropsy there is no demonstrable primary focus, we are baffled as to how the organism reaches the peritoneum, and we can only surmise that it is a blood-borne infection. The patients are usually gravely ill, and meteorism comes on early. On opening the abdomen thin, blood-stained fluid is usually present. The appendix is examined and found not to be the cause of the trouble. Other organs are likewise inspected with negative results. Drainage of the peritoneal cavity and the administration of anti-streptococcal serum offer the only hope.

Gonococcal Peritonitis.—Pelvic peritonitis is a common complication of gonococcal salpingitis. The disease is usually strictly localised to the pelvis, but a diffuse peritonitis of gonococcal origin is not very uncommon. The finding of gonococci in a smear taken from the cervix uteri is helpful confirmatory evidence in suspected cases. If gonococcal peritonitis could be diagnosed with irrefutable accuracy, urgent operation would seldom be required, for most of these cases do well by placing them in Fowler's position. With Ochsner's treatment resolution usually occurs. In the minority a

localised pelvic abscess forms, and such an abscess may be effectively drained through the posterior fornix. In cases where difficulties arise in diagnosis and also in cases of spreading peritonitis, laparotomy must be performed. We seldom drain cases of gonococcal peritonitis, but mop up the pus, close the abdomen, and continue to nurse the patient in high Fowler's position, and this practice has been attended by satisfactory results. After the acute stage has definitely settled down salpingectomy is often required.

Acute Tuberculous Peritonitis.—It is doubtful if tuberculous peritonitis is ever acute, but patients with tuberculous peritonitis sometimes have acute exacerbations of the disease which at times so closely resemble an acute peritonitis that when the patient is seen for the first time in such an attack the abdomen is rightly opened. Straw-coloured fluid escapes, and tubercles are seen scattered over the peritoneum and great omentum. Tubercles occasionally simulate fat necroses (p. 278) or the nodules of peritoneal carcinomatosis. The latter feel hard when rolled between the finger and thumb, making their differentiation tolerably simple. On opening the abdomen and finding a tuberculous peritonitis, the fluid is let out, a tiny portion of omentum removed for histological confirmation of the diagnosis, and the wound sutured without drainage.

Chronic Peritonitis

Chronic peritonitis is practically confined to tuberculous disease of the peritoneum.

Tuberculous Peritonitis.—Children are usually affected. It is rare, but by no means unknown, for the disease to appear first in adult life, and even in old age.

Origin of the Infection.—1. From tuberculous mesenteric glands.
2. From tuberculosis of the appendix, ileum, or cæcum.
3. From a tuberculous pyosalpinx.
4. By transmigration through the gut wall via an infected Peyer's patch (probable).
5. Primary blood-borne infection (possible).

There are three main varieties of tuberculous peritonitis :

1. *Ascitic Form.*—The peritoneum is studded with tubercles, and the cœlom becomes filled with pale, straw-coloured fluid. Ascitic is the commonest form of tuberculous peritonitis, and it is characterised by the presence of a large quantity of free fluid in the peritoneal cavity. Shifting dullness is readily elicited. The child is usually brought for advice because the abdomen is becoming large (fig. 234). Pain is often absent, but sometimes acute exacerbations of the disease with violent abdominal pain complicate the clinical picture. In the male child *congenital hydroceles* sometimes appear (see p. 533). On

account of the increased intraperitoneal tension *umbilical hernia* commonly occurs.

FIG. 234.—Abdominal tuberculosis. Ascitic form. (Macewen's *Textbook of Surgery*.)

In addition to the fluid, solid masses are sometimes felt within the abdomen. These may be:

(i) A rolled-up diseased omentum (p. 301).
(ii) Enlarged mesenteric glands.
(iii) Matted intestine, with encysted collections of fluid.

The diagnosis of the ascitic form of tuberculous peritonitis seldom presents difficulty, except when the patient is first seen in an acute exacerbation, or when the fluid becomes loculated in one portion of the abdomen. In the latter case all the difficulties connected with the diagnosis of an intra-abdominal cyst are present. Although spontaneous cures are not unknown, the disease runs a chronic course if untreated. The child becomes progressively emaciated, and finally falls a victim to disseminated tuberculosis or some intercurrent disease.

Treatment.—In children general treatment, which includes heliotherapy, is usually effective. Laparotomy with evacuation of ascitic fluid is distinctly beneficial, for it hastens the cure. Laparotomy should always be looked upon as but a part of the treatment, the general treatment being all-important. In adults the prognosis is not so good, and treatment should be continued for long after an apparent cure.

2. *Ulcerative Form.*—Amidst a mass of adherent gut and omentum pus is present. Intraperitoneal cold abscesses form, and point on the surface, commonly near the umbilicus, or burst through into the bowel. In this type, which is a frequent complication of tuberculous pyosalpinx, fæcal fistulæ are a common and serious complication.

Treatment is general. Operative treatment may be necessary for complications such as localised collections of pus or intestinal obstruction. The prognosis in this variety is poor.

3. *Fibrous Form.*—The onset is insidious, and the first intimation of the disease is usually intestinal obstruction. If the obstruction is acute and the disease widespread, the treatment is difficult. If

obstruction does not occur, or can be overcome, the prognosis in this variety, considering the apparent intraperitoneal chaos, is surprisingly good.

Ascites

Ascites can accompany a number of divergent conditions, and although a symptom rather than a disease, it is convenient to consider the common causes of ascites together.

Type 1. *Accompanying Failing Heart or Failing Kidneys.*—The ascitic fluid is part of a general dropsy. The fluid is a light yellow serum of low specific gravity, about 1,010.

Type 2. *Accompanying Cirrhosis of the Liver, and Other Forms of Portal Obstruction.*—The serum is darker in colour than the foregoing, and the specific gravity is about 1,015 (see also p. 261).

Type 3. *Accompanying Enlargements of the Spleen, particularly Banti's Disease.*—The fluid in all particulars resembles that of 2.

Type 4. *Accompanying Tuberculous Peritonitis.*—The fluid is pale yellow and usually clear. The specific gravity is comparatively high, often 1,020 or over. The fluid is rich in lymphocytes.

Type 5. *Accompanying Secondary Carcinoma of the Peritoneum* (fig. 235).—The fluid is dark yellow and frequently blood-stained. The specific gravity is high, 1,020 or over. Microscopic examination often reveals cancer cells.

Type 6. *As a Part of Polyserositis* (*syn. Pick's Disease; Concato's Disease*).—In addition to the peritoneal effusion, effusions occur into the pericardium and pleural cavities. The specific gravity is about 1,015.

Differential Diagnosis of Ascites.—Free fluid in the peritoneal cavity must be distinguished from a large ovarian cyst. When an ovarian cyst fills the entire abdomen the differential diagnosis can be very difficult. In this connection Blaxland's sign is helpful.

Blaxland's Sign.—A flat ruler is laid upon the abdomen just above the level of the anterior-superior iliac spine. The ruler is pressed firmly and steadily backwards towards the vertebral column. In the case of an ovarian cyst pulsation of the abdominal aorta can be felt, but not so in ascites.

Treatment of Ascites.—Sometimes, e.g. tuberculous peritonitis, laparotomy should be performed; indeed, in any case of ascites not belonging to groups 1, 6, and possibly 2, the question of the advisability of performing laparotomy

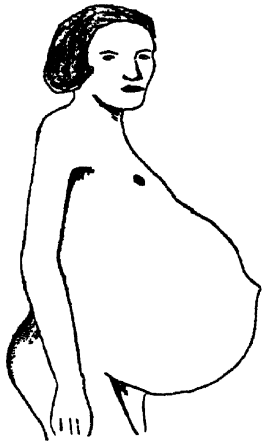

FIG. 235.—Advanced malignant ascites (from a photograph).

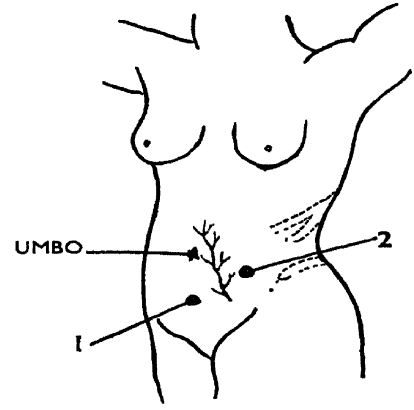

FIG. 236.—Usual points of puncture for tapping ascites. The bladder must be emptied by a catheter before the puncture is made. Note the relationship of the site of puncture to the deep epigastric artery.

arises. Otherwise the fluid must be removed by tapping (*syn.* paracentesis peritonei). The usual points of puncture are depicted in fig. 236. We find it convenient to employ Kidd's trocar for this purpose.

NEOPLASMS OF THE PERITONEUM

1. **Carcinoma peritonei** is a common terminal event in many cases of carcinoma of the stomach, colon, or other intraperitoneal organs. The peritoneum, both parietal and visceral, is studded with secondary growths, and the peritoneal cavity becomes filled with ascitic fluid. It is remarkable how often a patient riddled with intra-peritoneal carcinoma preserves her nutrition, and looks and feels comparatively well until the last. Withdrawal of the fluid by tapping renders the patient more comfortable.

2. **Pseudo-myxoma Peritonei.**—The abdomen is filled with a yellow jelly, large quantities of which are often more or less encysted. This rare condition is more frequent in females, and probably arises through the bursting of an ovarian cyst. At laparotomy masses of jelly are scooped out. Unfortunately, recurrence is usual. In one of our patients laparotomy and evacuation of quarts of jelly was undertaken on four occasions in a little over a year. Pseudo-myxoma peritonei is locally malignant, but does not give rise to metastases. After removal of the jelly deep X-rays may be tried in order to prevent re-formation, but eventually the disease almost always proves fatal.

The Great Omentum

The great omentum has been called by Rutherford Morison the "abdominal policeman." The omentum,

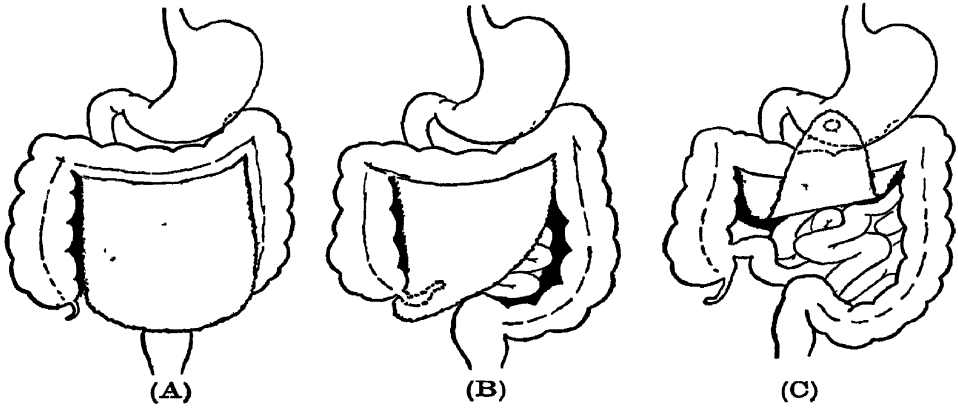

Fig. 237.—The great omentum. (A) Normal. (B) In appendicitis. (C) In gastric ulcer. (After Rutherford Morison.)

which is much better developed in the adult than in the child, performs a great service, for it attempts, often successfully, to limit intraperitoneal infective processes (fig. 237). For instance, an acutely inflamed appendix is often found wrapped in omentum, and this envelopment saves many a patient from developing diffuse peritonitis. Sufferers from herniæ are also greatly indebted to this structure, for it often plugs the neck of a hernial sac and prevents a coil of intestine from becoming strangulated.



Fig. 238.—Physical signs recorded in a case of tuberculous peritonitis.

In general tuberculous peri-

tonitis, where the omentum itself is diseased, it becomes rolled into a sausage-like mass, which extends across the abdomen above the umbilicus (fig. 238).

Torsion of the Omentum

Torsion of the omentum (fig. 239) is a rare emergency, and consequently is seldom correctly diagnosed. It is usually mistaken for appendicitis with somewhat abnormal signs. A tender lump may be present in the abdomen. The blood-supply having been cut off, the twisted mass sometimes becomes gangrenous, and peritonitis may follow.

Treatment.—The abdomen having been opened, the pedicle above the twist is securely ligatured and the mass removed.



Fig. 239.—Torsion of the great omentum. Specimen removed by operation. (Archibald.)

The Mesentery

A wound of the mesentery can follow a severe abdominal contusion, and is a cause of hæmoperitoneum. In about 60 per cent. of cases the mesenteric laceration is associated with a rupture of the intestine. If the tear is a large one, and especially if it is transverse (fig. 240), the blood-supply to the neighbouring intestine is cut off, and a limited resection of gut is imperative. Small wounds and wounds in the long axis (fig. 241) should be sutured.

Torsion of the mesentery (see Volvulus Neonatorum, p. 333, and Volvulus of the Small Intestine, p. 339).

Suppurating Mesenteric Glands.—No doubt the lymphatic glands of the mesentery become inflamed frequently. The early symptoms are inclined to simulate acute appendicitis. Occasionally suppuration occurs, and diffuse peritonitis follows. We have met with a number of such

cases. Usually the suppurating glands have been situated in the jejunal mesentery. Most of the patients have been, not as one might have expected, children, but young adult males. Prompt drainage of the general peritoneal cavity is the treatment.

Tuberculosis of the mesenteric glands (fig. 242) is very common, contaminated milk being responsible for the infection. Mesenteric tuberculosis is a subject of considerable

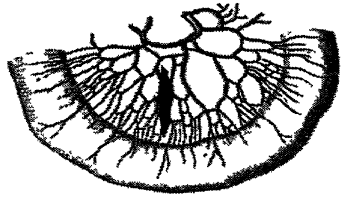

FIG. 240.

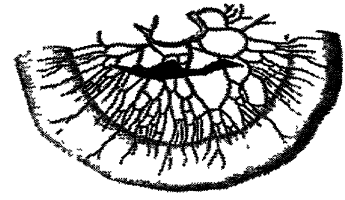

FIG. 241.

Laceration of the mesentery. A longitudinal tear (fig. 240) can be closed by suture. A transverse tear (fig. 241) often imperils the blood-supply of a segment of intestine, making resection necessary.
(From *Emergency Surgery*).

importance, and for convenience the clinical features may be divided into various types met with in practice.

Type 1. *Latent.*—Evidence of past tuberculous disease in some of the mesenteric glands is almost an invariable finding in a routine necropsy.

Type 2. *As a Part of Generalised Tuberculous Lymphadenitis.*—When a patient is presented with considerable tuberculous disease of the cervical, axillary, or lymphatic glands, the abdomen should also be palpated for enlarged glands (fig. 242).

Type 3. *As a Cause of Abdominal Pain.*—Many cases of suspected appendicitis, especially in childhood, upon laparotomy prove to be examples of tuberculous mesenteric lymphadenitis.

Type 4. *A Localised Caseating Mass in the Mesentery.*—The abdomen is opened, either because of abdominal pain, or because of a palpable lump, and a localised caseating mass is found in the mesentery. In most cases the caseating

FIG. 242.—Massive tuberculosis of the glands of the mesentery.

material should be removed. If an extra-capsular resection of the gland or glands is necessary, the blood-supply of the intestine in the immediate neighbourhood is often jeopardised (fig. 243), and resection of a segment of intestine becomes imperative.

Type 5. *As a Cause of Intestinal Obstruction.*—A coil of intestine becomes adherent to a caseating mesenteric gland, and thereby angulated (fig. 244) or otherwise obstructed. This is a frequent form of intestinal obstruction, and one to which considerable prominence should be given (p. 340).

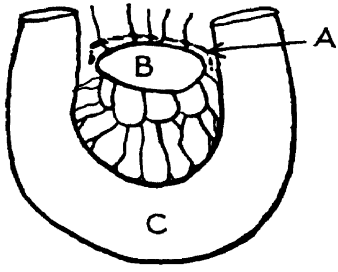

FIG. 243.—When an *extra*-capsular resection of a large tuberculous mesenteric gland is necessary the blood-supply to the gut is often imperilled. An incision of the mesentery along the line A to remove the gland B would vitiate the blood-supply of the gut at C.

Type 6. *As a Cause of (Pseudo-) Mesenteric Cyst* (see below).

Type 7. *As a Confusing Radiographic Shadow.*—A calcifying or calcified tuberculous gland is a constant source of difficulty in the diagnosis of urinary and other calculi (see p. 461).

FIG. 244.—Obstruction by angulation. The gut has become adherent to a breaking-down mesenteric gland.

CYSTS OF THE MESENTERY

A cyst of the mesentery (fig. 245) presents certain characteristic physical

cases. Usually the suppurating glands have been situated in the jejunal mesentery. Most of the patients have been, not as one might have expected, children, but young adult males. Prompt drainage of the general peritoneal cavity is the treatment.

Tuberculosis of the mesenteric glands (fig. 242) is very common, contaminated milk being responsible for the infection. Mesenteric tuberculosis is a subject of considerable

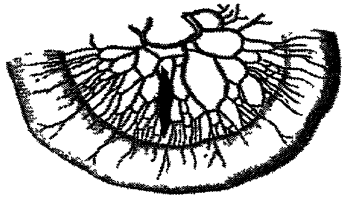

FIG. 240.

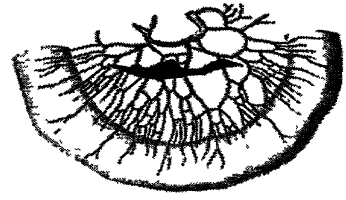

FIG. 241.

Laceration of the mesentery. A longitudinal tear (fig. 240) can be closed by suture. A transverse tear (fig. 241) often imperils the blood-supply of a segment of intestine, making resection necessary.

(From *Emergency Surgery*).

importance, and for convenience the clinical features may be divided into various types met with in practice.

Type 1. *Latent.*—Evidence of past tuberculous disease in some of the mesenteric glands is almost an invariable finding in a routine necropsy.

Type 2. *As a Part of Generalised Tuberculous Lymphadenitis.*—When a patient is presented with considerable tuberculous disease of the cervical, axillary, or lymphatic glands, the abdomen should also be palpated for enlarged glands (fig. 242).

Type 3. *As a Cause of Abdominal Pain.*—Many cases of suspected appendicitis, especially in childhood, upon laparotomy prove to be examples of tuberculous mesenteric lymphadenitis.

Type 4. *A Localised Caseating Mass in the Mesentery.*—The abdomen is opened, either because of abdominal pain, or because of a palpable lump, and a localised caseating mass is found in the mesentery. In most cases the caseating

2. **Tuberculous Abscess of the Mesentery**
3. **Hydatid Cyst** of the Mesentery.

Treatment of a Mesenteric Cyst

Enucleation is the ideal treatment, but it is seldom possible, except in the case of small cysts.

Resection, which of necessity must include the involved segment of intestine, is a severe undertaking, carries a high mortality, and is not often necessary.

Drainage by marsupialisation (fig. 248) is the standard method for dealing with a large mesenteric cyst.

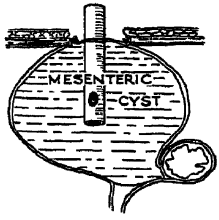

FIG. 248.—Marsupialisation of a mesenteric cyst. The peritoneum is closed about the cyst, leaving a small area uncovered. The cut edge of the peritoneum is sewn to the cyst wall around the base area, through which the cyst is drained.

COMPLICATIONS OF MESENTERIC CYSTS

1. Intestinal obstruction.
2. Rupture of the cyst.
3. Hæmorrhage into the cyst.
4. Torsion of a pedunculated cyst.
5. Impaction in the pelvis and consequent pressure upon the pelvic organs.

NEOPLASMS OF THE MESENTERY

New-growths situated in the mesentery give rise to physical signs similar to those of a mesenteric cyst, the sole exception being that they sometimes feel solid.

- MESENTERIC NEOPLASMS.
  - Benign
    - Lipoma
    - Fibroma
    - Fibromyxoma
  - Malignant
    - Primary Sarcoma
    - Secondary
      - Carcinoma
      - Lymphosarcoma.

THE RETROPERITONEAL SPACE

Pus or blood in the retroperitoneal space tends to track to the iliac fossa. It should be evacuated by an incision through the abdominal wall, meticulously avoiding opening the peritoneum.

Retroperitoneal Tumours

1. **Retroperitoneal lipomata,** in the first instance, are usually mistaken for a hydronephrosis, a diagnosis which is later ruled out by subsequent investigation. Women are more often affected. These swellings sometimes reach an immense size. We have removed such a tumour weighing 5½ lb., and much larger specimens have been recorded. These lipomata sometimes undergo myxomatous degeneration, a complication which does not occur in fatty tumours elsewhere.

2. **Retroperitoneal sarcomata** present signs similar to retroperitoneal lipomata, and are even more difficult to diagnose, exploratory laparotomy and removal of a small portion for histological scrutiny being the only certain method. They are inclined to occur in younger subjects than retroperitoneal lipomata. The sarcoma arises in the retroperitoneal connective tissue, and grows apace. Even when removed at a comparatively early stage, recurrence always takes place, and these tumours must be looked upon as necessarily fatal. Deep X-ray treatment should be tried.

CHAPTER XVIII

THE INTESTINES

Some Points in Surgical Anatomy.—It is of great practical importance to be able:

1. To distinguish various portions of the intestinal canal at sight.
2. To know in which part of the abdomen the upper coils, as opposed to the lower coils, of the small intestine lie in relationship to the anterior abdominal wall.
3. To be able to tell which is the proximal and which the distal end of any loop under consideration.
4. To distinguish irrefutably large from small intestine.

For practical purposes these problems are settled as follows:

1. The mesentery of the jejunum has only two series of arches of blood-vessels, whereas the lower ileum has several series of arches.

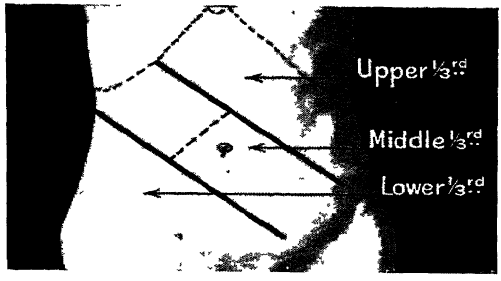

FIG. 249.—Monk's method of localising the small intestine upon the surface.

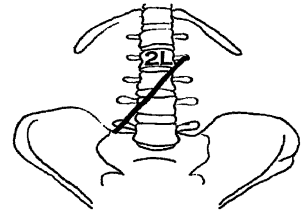

FIG. 250.—The attachment of the mesentery.

2. Monk's method of intestinal localisation roughly indicates the situation of the different sections of the small bowel (fig. 249).
3. The mesentery, after being made taut, is examined. As the mesenteric attachment runs from left to right (fig. 250), and palpation reveals the mesentery is not twisted, then the upper end of the bowel in the wound is the proximal end. Such a test is useful, but not so easy of performance in the living as in the dissecting room.
4. As the "small" intestine is sometimes found enormously distended, and the "large" gut entirely collapsed, size is no criterion. The large gut is characterised by its tæniæ coli and appendices epiploicæ.

Embryology.—Beneath the notochord appears the primitive alimentary canal, which is continuous with the yolk sac (fig. 251). This canal becomes differentiated into :

1. *The fore-gut*, from which are developed the pharynx, œsophagus, and stomach, together with the duodenum as far as the ampulla of Vater.

2. *The hind-gut*, which is the forerunner of the rectum, pelvic colon, and the descending colon.

3. *The mid-gut*, which gives origin to the remainder of the intestinal canal.

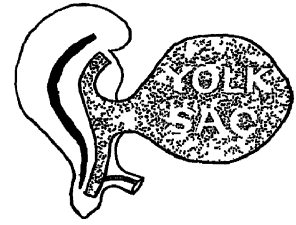

FIG. 251.—Embryo showing the primitive alimentary canal and the yolk sac.

The mid-gut is continuous with the yolk sac, but as development proceeds, the communicating channel between these two structures dwindles into the *omphalo-mesenteric* (syn. *Vitelline*) *duct.* Later still the duct disappears entirely, except in 2 per cent. of individuals, where its inner extremity is represented by a pouch, so well known as Meckel's diverticulum. The mid-gut grows apace, and becomes differentiated into large and small intestine, the junction being indicated by an out-growth, which later forms the cæcum. As the gut, which now is suspended by a mesentery, elongates, it also rotates, and the rotation of the various portions in relation to the middle line is depicted in fig. 252 At the fourth week of intra-uterine life the greater part of the mid-gut is extruded, and comes to lie within the umbilical cord. This is a temporary physiological hernia, which sometimes persists (see Exomphalos, Chapter XXII). The normal process of rotation occurs during the act of reduction of the physiological hernia.

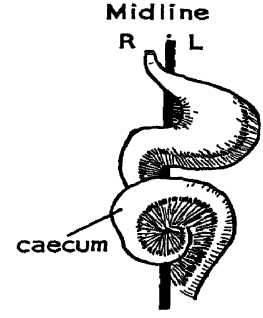

FIG. 252.—Rotation of portions of the alimentary canal on either side of the middle line.

CONGENITAL MALFORMATIONS OF THE GUT

Congenital atresia of the duodenum (p. 209).
Congenital atresia of the small intestine (p. 333).
Volvulus neonatorum (p. 333).

Failure of Descent of the Cæcum.—The cæcum remains under the right lobe of the liver—a normal situation of the structure in the mangabey monkey. This anomaly, which is not infrequent, is of importance, because it leads to remarkable displacements of the vermiform appendix.

Meckel's diverticulum and the remainder of the omphalo-

mesenteric duct give origin to many conditions of surgical interest and importance.

1. The omphalo-mesenteric duct occasionally remains patent (fig. 253), giving rise to an umbilical fistula, which

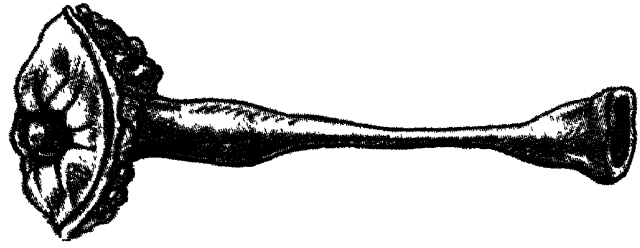

FIG. 253.—Patent omphalo-mesenteric duct opening into the umbilicus. (A. L. Taylor.)

discharges mucus and, rarely, fæces. Such a fistula is often associated with an umbilical "adenoma."

2. An intra-abdominal cyst can arise in conjunction with the structure.

3. With its lumen obliterated or unobliterated, the omphalo-mesenteric duct provides an intraperitoneal band which is a potential danger, for intestinal obstruction is most prone to occur. Obstruction results from a loop of intestine passing under or over, or by becoming twisted round the band (fig. 254).

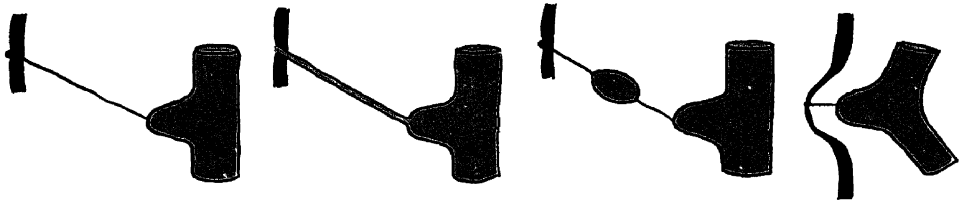

(a) (b) (c) (d)

FIG. 254.—Varieties of anomalies connected with the omphalo-mesenteric apparatus. (a) Intraperitoneal band. (b) Umbilical fistula. (c) Intra-abdominal cyst. (d) Meckel's diverticulum adherent to the sac of a congenital umbilical hernia.

Coming now to Meckel's diverticulum itself. It will be recalled that the structure is present in 2 per cent. of the human race; that it is situated upon the antimesenteric border of the small intestine, 2 ft. from the ileocæcal valve, and that it is usually 2 in. long. One need not be

acquainted with abdominal surgery for any length of time to realise that the diverticulum may be of much greater length, sometimes up to 2 ft. Its special diseases are :

1. *Meckelian Diverticulitis.*—Acute inflammation of the diverticulum produces the symptoms, signs, and complications of acute appendicitis. Moreover, the treatment is similar.

2. *Inversion of the diverticulum* is a potent cause of intussusception, especially during adolescent life (p. 337).

A patent or obliterated omphalo-mesenteric duct should be excised, together with, in most instances, the accompanying Meckel's diverticulum.

FIG. 255.—Diverticulum at the *mesenteric* border of small intestine.

Diverticula also occasionally occur at the mesenteric border (fig. 255) of the small intestine. In the pouches enteroliths sometimes form. It is possible that the closing of the mouth of such a diverticulum is the explanation of the formation of a mesenteric cyst—a condition otherwise difficult of explanation.



FIG. 256.—Hirschsprung's Disease. (W. Mercer.)

HIRSCHSPRUNG'S DISEASE (*syn.* CONGENITAL DILATATION OF THE COLON)

The babe is born apparently normal, but soon exhibits inveterate constipation, the colon gradually becoming obviously dilated. Enemata and purgatives have but little effect, and a motion is passed perhaps once in eight or nine days. Signs of intestinal toxæmia follow. Either death occurs early in life from this cause, or, less frequently, the bowel wall so hypertrophies that fæces are forced through the inactive segment, which appears to be usually the pelvic colon. In this way life is prolonged. The belly shows barrel-shaped distension (fig. 256). In a proportion of cases the compensatory hypertrophy is adequate, and the patient reaches maturity.

Pathology.—At necropsy upon a case of Hirschsprung's disease the size of the colon is fantastic. The colonic musculature can be seen to be greatly hypertrophied, especially the circular fibres. Areas of mucosal ulceration are frequent, and are no doubt the direct result of irritation by scybalous masses. There is no demonstrable mechanical obstruction.

Ætiology.—There is growing evidence that Hirschsprung's disease is due to a state of unbalance between the sympathetic and parasympathetic moieties of the autonomic system. The over-acting sympathetic results in a contracture of the circular fibres in the region of the pelvi-rectal junction, while the longitudinal fibres are inhibited.

Treatment.—1. A continuance of a conservative attitude is admissible in those cases which give some promise that compensatory hypertrophy will be adequate.

2. Dilatation of the lower sigmoid with bougies and bags has proved helpful, if not curative, in a few instances.

3. Lumbar ganglionectomy, or excision of the presacral nerve, combined with section of the inferior mesenteric nerves (fig. 257) gives considerable promise of being a curative operation.

4. Partial or complete colectomy is now justly unpopular. Complete colectomy carries a high mortality, and right partial colectomy is seldom curative. Excision of the pelvic colon by Paul's method is comparatively safe, and it attempts removal of the cause, viz. the inactive segment of the bowel.

ENTEROPTOSIS

Enteroptosis is a common condition and a penalty of the adoption by man of the upright position. The abdominal organs tend to sag, and in so doing a train of symptoms is produced which often mimic organic disease. In obscure cases of abdominal pain the possibility of enteroptosis should be constantly before one as a differential diagnosis.

General Visceroptosis (*syn.* Glénard's Disease)

All the organs are ptosed. The patient is nearly always a woman.

Rovsing recognised two types of general visceroptosis :

Maternal Visceroptosis.—As a result of repeated pregnancy the

abdominal wall loses its tone and the intra-abdominal organs slide down.

Virginal Visceroptosis.—From childhood the patient shows signs of ptosis. She has a long, narrow, upper abdomen (p. 228), and tends to stoop. She is of the "drooping lily" type, and as she grows older is constantly ailing. Although no doubt there are uncomfortable sensations from the ptosed organs, only too often the patient becomes hypochondriacal.

Treatment is unsatisfactory. A well-fitting abdominal belt put on each morning before the patient arises and worn

FIG 257.—Displaying the presacral nerve. The presacral and inferior mesenteric sympathetic nerves (following the inferior mesenteric artery) are divided (after Learmonth).

all day is of great service. Massage is helpful, especially in the maternal type.

Ptosis may affect particularly certain organs. We have dealt already with nephroptosis, gastroptosis, hepatoptosis, and with wandering spleen. It is necessary here to deal with ptosis affecting particularly the intestines.

Kinks, Membranes, and Bands associated with Enteroptosis.—There are a number of kinks, membranes, and bands associated with ptosed intestines, and these are of considerable surgical importance, for in extravagant cases some of

them produce stasis, if not actual intestinal obstruction. Their origin is disputed, the consensus of opinion being that they are all congenital.

1. *Cystico-duodenal band* runs from the gall bladder to the pylorus. To those operators unaware of its existence, it is often looked upon as an inflammatory adhesion.

FIG. 258.—Lane's first kink.

2. *Mesocolic band of Pringle* runs from the mesocolon to the duodeno-jejunal flexure, and occasionally kinks this portion of the intestine.

3. *Lane's first kink* (fig. 258) runs from a point 4 in. from the ileocæcal valve to the ovary. We have seen definite chronic intestinal obstruction from this band, which was relieved by its division.

4. *Jackson's membrane*, which is comparatively common, runs from the great omentum, enveloping like a shroud an unusually lax, capacious cæcum and ascending colon. When this veil is gently pulled so as to make it move upon the cæcum, its contained blood-vessels become the more apparent. This structure, once seen, can never be mistaken (fig. 259).



FIG. 259.—Jackson's membrane.

5. *Payr's membrane* is the same as 4 over the splenic flexure; it is less often seen, for it is the right side of the abdomen which is usually opened.

6. *Toldt's membrane* is again the same as 4 over the pelvic colon. It sometimes binds the omega loop to the left iliac fossa, and produces what is known as **Lane's last kink.**

RIGHT-SIDED PTOSIS (*syn.* CÆCOPTOSIS)

In selected cases, benefit has accrued from plastic operations, designed to lift and fix the mobile loose cæcum and ascending colon (Waugh's operation).

CHRONIC INTESTINAL STASIS

Chronic constipation is often a troublesome feature of visceroptosis, and in some cases the stasis produces a recognisable train of ill-health. The complexion is muddy, and evil-smelling sweat (bromidosis) bespeaks the toxic state. In such cases, and others of obstinate constipation with toxic absorption, where intestinal lavage and medical and dietetic treatment have failed to cure, colectomy has been advised, but this operation, which was advocated by Sir Arbuthnot Lane, is now seldom performed.

TRAUMATIC RUPTURE OF THE INTESTINE

The intestine can be ruptured without any external wound. The most frequent cause of such an accident is a kick in the abdomen; the rupture being probably produced by a coil of intestine being crushed against the sacral promontory. Rupture of the intestine is said to be more frequent where

a fixed part of the alimentary tract joins a free portion, such as the duodeno-jejunal flexure, but this has not been our experience. The latter lesion is sometimes met with after run-over accidents.

In small perforations the mucosa prolapses and tends partially to seal the rent; consequently the early signs are misleading. In general it may be stated that the signs simulate closely those of a perforated gastric ulcer.

Traumatic rupture of the large intestine is very much less frequent. Compressed-air rupture of the colon is nearly always the result of a damnable form of practical joke, whereby a hose, carrying air under considerable pressure, is turned on near the victim's anus.

The treatment is immediate laparotomy and suture of the perforation. Except in early cases of high jejunal perforation, the general peritoneal cavity must be drained.

Inflammations

Chronic ulcerative colitis is a serious condition, coming on in early adult life. Children are hardly ever affected. The infecting organism is believed to be a streptococcus. The disease is ushered in by an acute attack of diarrhœa, accompanied by blood-stained mucus. The course of the disease is variable, but relapses are only too frequent. In severe cases, even if she is not bedridden, the loss of strength and vitality with constant diarrhœa and tenesmus make the patient's life a misery. Exacerbations are accompanied by pyrexia.

Sigmoidoscopy.—In many instances the final diagnosis rests with sigmoidoscopy (fig. 260). The granular, reddened mucosa dotted with tiny ulcers (fig. 261) is very different from the picture seen in amœbic dysentery, where there are large deep ulcerations with the intervening mucosa comparatively healthy.

Radiology after a barium meal tends to show an attenuated colonic shadow—a characteristic appearance due to the empty contracted state of the organ, and particularly affecting the pelvic colon.

Surgical Treatment of Ulcerative Colitis (and the Dysenteries which fail to respond to Medical Treatment).

(*a*) *Appendicostomy.*—The lumen of the appendix is used

to introduce irrigating fluids to the inflamed colonic mucosa. The antiseptic solutions used for this purpose must be very diluted, for the colon greedily absorbs chemicals.

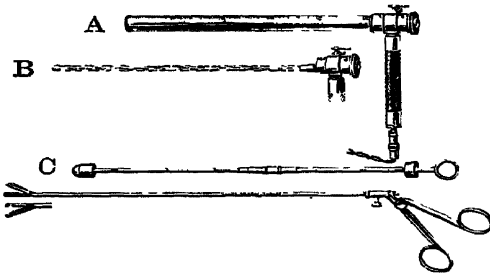

FIG. 260.
A. Sigmoidoscope assembled.
B. Illuminated lens.
C. Obturator.
D. Forceps for carrying swabs down the instrument.



FIG. 261.—Ulcerative colitis. The granular inflamed appearance of the mucosa is characteristic (after Lockhart-Mummery).

The appendix, unless it is anomalous or diseased, can be brought to the surface, as is shown in fig. 262. After a week it is cut off flush with the skin. In performing appendicostomy, *it is essential to preserve the appendicular artery*, or the organ will slough. If this cannot be done, or disease or abnormality makes appendicostomy (fig. 262) impracticable, a valvular cæcostomy is undertaken instead.

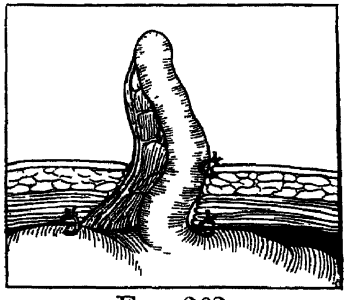

FIG. 262.
Appendicostomy.

(*b*) *Enterostomy*.—In the worst cases it is necessary to put the colon at rest, and the only effective method is to divide the lower end of the ileum right across, and to bring out each end on to the abdominal wall. The enterostomy, if well cared for, is compatible with a tolerably happy

FIG. 263.—Appendicostomy catheter.

existence. It is often remarkable how quickly the general health improves after this measure.

The surgery of chronic ulcerative colitis is satisfactory up to a point. Even if the patient has not passed blood or mucus for months, the disease is not dead, but sleepeth, and disappointment awaits him who too early accedes to a request to close the artificial anus.

THE SURGICAL COMPLICATIONS OF TYPHOID AND PARATYPHOID

1. *Intestinal hæmorrhage* may be the leading symptom. In three cases in our practice torrential rectal hæmorrhage has been the first indication of a typhoid infection. The condition must be distinguished from purpura with intestinal symptoms, and intussusception. A Widal reaction should be employed, and if negative, repeated in suspected cases. Blood transfusion may be necessary.

FIG. 264.

FIG. 265.

FIG. 264.—A typhoid ulcer is longitudinal to the long axis of the gut.

FIG. 265.—A tuberculous ulcer is transverse.

2. *Perforation.*—Perforation of a typhoid ulcer usually occurs during the third week; occasionally it is the first intimation of the disease (ambulatory typhoid). The perforation is longitudinal to the long axis of the gut (fig. 264), and in the case of typhoid, it is situated in the lower ileum. In paratyphoid β, perforation of the large gut sometimes occurs. Treatment is to perform laparotomy under local anæsthesia as soon as the diagnosis is probable, and to close the perforation with sutures. The prognosis is very poor.

3. Spontaneous rupture of the enlarged *spleen* has been recorded.

4. *Liver abscess* is most often a complication of paratyphoid.

5. *Gall Bladder.*—The relationship of cholecystitis and gall-stones to typhoid has been referred to already (p. 267).

6. *Phlebitis.*—Venous thrombosis, particularly of the left common iliac vein, is a not very infrequent complication of typhoid fever.

7. *Genito-urinary Complications.*—Typhoid cystitis, pyelitis, bacilluria, and epididymo-orchitis all occur (p. 545).

8. *Parotitis.*—Typhoid is a common cause of suppurative parotitis. In this instance the onset of parotitis is usually of grave significance (p. 138).

9. *Joints.*—All degrees of arthritis, from a mild effusion to suppuration, have occurred as a complication of this disease.

10. *Bone.*—Typhoid osteomyelitis and typhoid spine are discussed on p. 795.

11. *Larynx.*—Typhoid perichondritis is met with occasionally, and typhoid laryngitis has been known to obstruct the airway.

TUBERCULOSIS

(*a*) **Tuberculous ulcer** affects particularly the ileum. These ulcers are usually multiple, and are placed transversely

(fig. 265) (cf. typhoid ulcer). Tubercles over their peritoneal surface allow of recognition at operation. Perforation is rare, but cicatricial contracture of the gut wall is a frequent and serious complication. Excision of the affected segment is sometimes possible. At other times the disease is widely distributed through the small intestine, and curative treatment is not possible.

(*b*) **Hyperplastic tuberculosis of the cæcum** simulates closely carcinoma of the cæcum, and is mimicked by actinomycosis of the right iliac fossa and chronic appendix abscess. There is a mass in the right iliac fossa. X-rays often reveal a filling defect (fig. 266), which at least tends to eliminate the possibility of an appendix abscess. Even on laparotomy, there is no certain means of telling if the mass is tuberculous or neoplastic (fig. 267). The treatment is excision of the cæcum and right half of the colon.

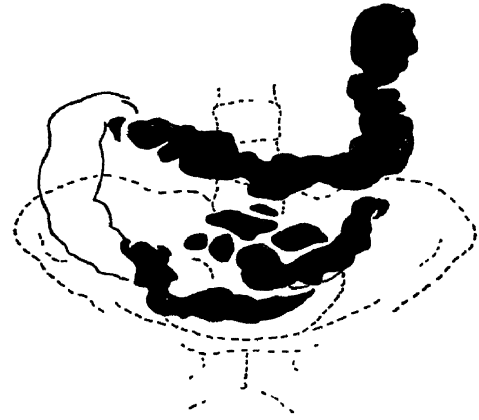

FIG. 266.—Stierlin's filling defect present in tuberculosis and carcinoma of the cæcum (after Cawadias).

(*c*) **Generalised tuberculosis of the colon** is rare outside sanatoria, which makes it probable that it is secondary to tuberculosis elsewhere. Early cases may be mistaken for appendicitis, for the disease usually begins in the right half of the colon. Later, chronic blood-stained diarrhœa is the leading symptom, and the clinical picture simulates closely that of ulcerative colitis. Heliotherapy and general treatment are usually advised.

CYSTIC PNEUMATOSIS OF THE SMALL INTESTINE

Cystic pneumatosis of the small intestine is an exceedingly rare condition, of which only about 100 cases have been recorded. There are clusters of gas-containing cysts upon the small intestine, usually the ileum. Aggregation of such cysts sometimes forms an abdominal tumour, but for the most part the cysts have been discovered during

FIG. 267.—The difficulties in diagnosis of a mass connected with the cæcum. In this case the lump outlined on the skin was thought at first to be an appendix abscess. After the cæcum and ascending colon had been excised the specimen had many of the appearances of tuberculosis. Histologically the mass proved to be a carcinoma

a laparotomy for chronic gastric or duodenal ulcer. The condition, which is probably allied to the intestinal emphysema of swine, often disappears spontaneously.

DIVERTICULOSIS AND DIVERTICULITIS

Definition.—Colonic diverticul*osis* — the presence of diverticula in the colon—is not an inflammatory condition, but as all the baneful effects of these pouches are due to inflammation occurring within or about them—diverticul*itis*—the reason for including the subject here will be evident.

Literally, a diverticulum means a wayside house of ill-fame, and these wayside houses certainly live up to their evil reputation. When diverticulitis is spoken of, it is assumed that colonic diverticulitis is implied, otherwise the site of the diverticulum is defined, viz. duodenal diverticulitis.

Ætiology.—The cause of diverticulosis is uncertain. It is not congenital, for the diverticula usually appear in elderly subjects, but there are exceptions. Herniation of the mucosa through the muscle coats, especially where blood-vessels emerge, appears to be the cause, but why the herniation occurs has not been elucidated ; that it is due to increased intra-colonic pressure following constipation is not an entirely satisfactory explanation.

Pathology.—The diverticula are usually multiple. Sometimes there are only two or three, usually scores are present, especially when the pelvic colon is affected (fig. 268). Al-

though no part of the large intestine is exempt, the cæcum is least often, and the pelvic colon most often, affected ; indeed, 80 per cent. of the diverticula occur in the latter region. The subject is usually an obese man over 50. The appendices epiploicæ are often of a great size, and contain fat of a yellow hue. The diverticula may be empty, but frequently at least some of them contain fæcal concretions. Exceptionally, a diverticulum passes into an appendix epiploica, and simulates to a nicety a vermiform appendix.

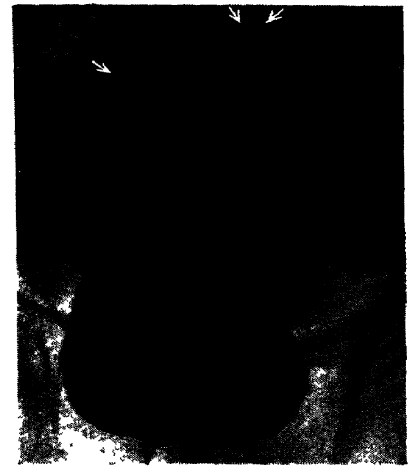

FIG. 268.—Barium enema. Diverticulitis of pelvic colon. The patient complained of pain and the passage of muco-pus per rectum.

Clinical Features.—*Diverticulosis.* — In diagnostic clinics, where a routine barium meal is part of the investigation, diverticulosis is a common finding in those patients past middle life. Diverticulosis does not necessarily give rise to symptoms, and is compatible with longevity.

Diverticulitis, a comparatively recently recognised disease, is a great imitator. It can mimic perfectly carcinoma of the colon. At other times it imitates appendicitis, although, because the pelvic colon is usually affected, the symptoms tend to be left-sided. Various clinical types of diverticulitis are met with.

Type 1. *Hyperplastic Diverticulitis.*—The symptoms, signs, complications, and treatment are exactly those of carcinoma coli. The latter condition is simulated so closely, that in some instances the deception is not realised until a histological examination has been made. Particular attention is drawn to hyperplastic diverticulitis as a cause of intestinal obstruction.

Type 2. *General or Pelvic Peritonitis.*—The bursting of a

diverticulum (fig. 269) into the peritoneal cavity is even more serious (if that be possible) than the similar catastrophe in connection with the vermiform appendix. Both are usually the direct result of the abuse of purgatives. The high bacterial content of the sigmoid sets up an especially virulent peritonitis.

Type 3. *Abscess* (fig. 270) is not an uncommon complication of diverticulitis. The pus is shut off from the general

FIG. 269 —Perforated diverticulum of the pelvic colon found at necropsy upon a case of diffuse peritonitis.

FIG. 270.—Abscess of the abdominal wall connected with a perforated diverticulum of the transverse colon.

peritoneal cavity by adhesions. The abscess is often situated in the left iliac fossa.

Type 4. *Fœcal fistula* dates from the opening or incision of an abscess; in other words, the fistula is a complication, and a rather common one, of Type 3.

Type 5. *Vesico-colic Fistula.*—Diverticulitis is the commonest cause of pneumaturia (p. 489).

Type 6. *Adhesions.*—Extensive adhesions of the affected segment of colon to surrounding structures are the rule in diverticulitis. These may be looked upon as Nature's method of limiting the disease. Adhesions may cause obstruction, kinking, or predispose to volvulus. By pulling

upon the peritoneum they are sometimes the cause of chronic pain.

Treatment of Diverticulitis.—In early cases (i.e. cases of diverticulosis with indefinite abdominal pain assumed to be due to diverticulitis) a careful diet and regular doses of liquid paraffin will sometimes avert indefinitely the onset of complications.

In cases of peritonitis following the perforation of a diverticulum, it is usually insufficient to drain the peritoneal cavity; the perforation must be closed in addition, or a catheter sewn into it and brought to the surface. In all cases of diverticulitis a well-planned colostomy is the best treatment. The artificial anus is made immediately above the diseased area, which is thereby put at rest. After a year or eighteen months, when the inflammation has completely abated, resection of the diseased segment, together with, when possible, restoration of the continuity of the colon, may be undertaken in suitable cases. Attention is directed to the necessity for a long period of preliminary drainage before radical treatment is attempted.

The mortality of diverticulitis due to peritonitis, obstruction, or pyæmia, is high. When the disease is recognised earlier than is the case at present, these fatal complications will be obviated by a timely colostomy.

Attention may be directed here to the fallacy of the prevalent opinion that life with a colostomy is necessarily a life not worth living. This idea is a legacy of the early days of colonic surgery, when a right lumbar colostomy was in vogue. With gas escaping and fluid fæces welling out upon the loin, where it was impossible for the patient to attend to the orifice, life must have been a misery, and very different from the management of a modern left inguinal colostomy. We have known patients leading an active life

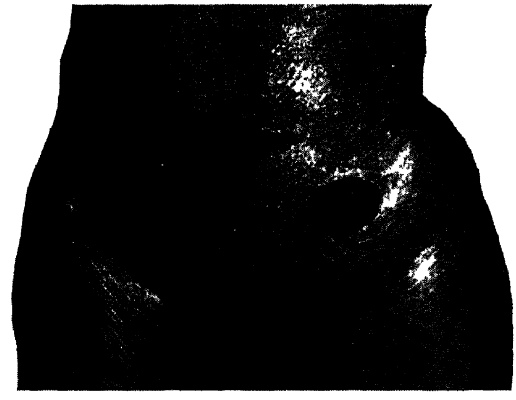

FIG. 271.—Left inguinal colostomy. The patient has excellent control, usually having one action only each day.

so comfortable and so little inconvenienced by their inguinal anus (fig. 271) that they were unwilling to undergo a comparatively slight operation to have it closed.

Fæcal Fistulæ

Fully 80 per cent. of fæcal fistulæ occur after operations for gangrenous appendicitis, and the leak is from the cæcum. Other common causes of a fæcal fistula are: pressure necrosis from a drainage tube left in too long; the giving way of a patch of gangrenous intestine, or the aftermath of opening an abscess connected with diverticulitis or carcinoma of the colon.

Fig. 272.—Prolapse of the bowel through a large fæcal fistula. The prolapse was reduced and the fistula closed by operation.

Treatment.—Fæcal fistulæ, especially those in connection with the small intestine, tend to heal spontaneously. The abdominal wall must be protected from erosion by escaping intestinal juices, and for this purpose dressings of horse serum are very useful. The administration of suitable doses of Pulv. Cretæ. Aromat. are valuable in thickening the contents of the bowel, and rendering the escaping material less obnoxious. A fistula with mucosa visible continuous with the skin edge will never close spontaneously. In some of these cases, where the opening is a large one, the gut tends to prolapse upon the surface (fig. 272).



Fig. 273.—Incision for closure of a fæcal fistula of the cæcum.

The operative treatment for closure of a fæcal fistula consists of a dissection of the tract and closure of the bowel and abdominal walls. In complicated fistulæ operation is difficult, but in the case of the cæcum it is usually straightforward (fig. 273).

Benign Neoplasms

Lipomata are usually found in relationship to the wall of the *small intestine*. Occasionally such tumours, which may be multiple, are subserous, but usually they are submucous, and tend to cause a protuberance which invites intussusception—their only danger.

Fig. 274.—Pedunculated adenomatous polyp of the intestine. Longitudinal section. (J. H. Saint.)

Adenomatous polypi (fig. 274) are practically confined to the *large gut*, and since more attention has been directed to them, they have been found to be not uncommon. They may be single, but are often multiple, and their chief claim to considerable importance is the frequency with which malignant disease supervenes. Unfortunately, unless they are near the termination of the colon, they are hardly capable of being diagnosed.

The treatment is thorough excision of a single polyp or resection of the affected portion of intestine in the case of a cluster of polypi.



Fig. 275.—Carcinoma of the small intestine. Note the dilatation of the lumen above the stricture. (G. P. B. Huddy.)

Malignant Neoplasms

Of the Small Intestine.—Both lympho-sarcoma and carcinoma occur, but with comparative infrequency. Attention is usually directed to malignant disease of the small intestine (fig. 275) by the supervention of intestinal obstruction.

Resection of the growth is the only treatment.

Carcinoma of the Colon

Pathology.—Microscopically, the neoplasm is a columnar-celled carcinoma originating in cells which line the bowel, or

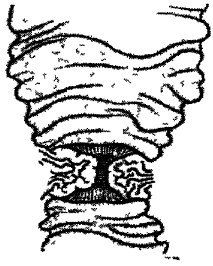

Fig. 276. Annular.

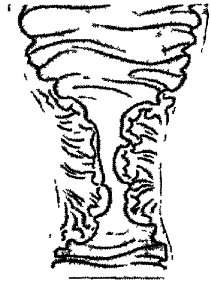

Fig. 277. Tubular.



Fig. 278. Ulcer.



Fig. 279. Cauliflower mass.

in the crypts of Lieberkühn. Macroscopically the growth takes the form of :

1. An annular constricting ring (fig. 276).
2. Tubular (fig. 277).
3. A carcinomatous ulcer (fig. 278).
4. A cauliflower mass, projecting into the lumen (fig. 279).

It is said that the annular form is the most malignant, in that it gives rise to secondary deposits comparatively early. Type 4 is the least malignant form, and it is now certain that these papilliferous masses commence as simple adenomata.

Site.—Fig. 280 represents diagrammatically the relative frequency of the usual sites of the growth.

The Spread of Carcinoma of the Colon.—Generally speaking, carcinoma coli is a comparatively slowly-growing neoplasm, and if extirpated thoroughly at a reasonably early period a cure can be hopefully anticipated.

Local Spread.—The growth is limited to the bowel for a considerable time.

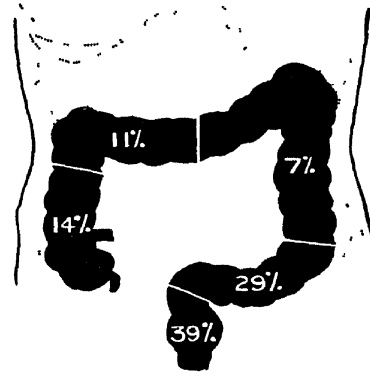

Fig. 280.—Relative frequency of carcinoma in various portions of the large intestine including the rectum.

It spreads round the lumen, and to a certain extent longitudinally, but it usually causes obstruction before it has penetrated into surrounding structures. In some cases, mostly of the ulcerative type, perforation into the peritoneum or into adjacent organs (e.g. the bladder) occurs before the onset of obstruction.

Lymphatic Spread.—The groups of lymphatic glands which drain the colon have been worked out fully. They are :

1. *The epicolic glands*, situated in the immediate vicinity of the bowel wall.
2. *The paracolic glands*, which lie in relationship to the leash of blood-vessels proceeding to the colonic walls.
3. *The intermediate glands*, which lie along the ileo-colic, mid-colic, and left colic vessels.
4. *The main glands*, which are aggregated around the superior and inferior mesenteric vessels, where they take origin from the abdominal aorta.

Spread by the Blood-stream.—Metastases are carried to the liver by this route, and in this instance very rarely to other distant organs.

The Test of Operability.—The abdomen having been opened, (1) the growth is examined with a view to ascertaining if it is fixed or free. As long as it can be mobilised sufficiently to be delivered into the wound it is operable; (2) the various groups of lymphatic glands which drain the particular segment are palpated. Their enlargement does not necessarily mean that these are invaded by metastases, for it may be inflammatory enlargement, as we have noted in diverticulitis; (3) the peritoneum, particularly the pelvic peritoneum, is palpated for implantations of the growth; (4) the liver is palpated for secondary nodules.

While this examination should be undertaken in every case, we are inclined to the view that extirpation of the growth should be undertaken whenever possible, but on the left side particularly, only after the gut has been drained and cleaned for a week or so.

Clinical Features.—Men are attacked more often than women (2 : 1). Although usually appearing during the fifth and sixth decades, it is not exceptional to meet cases at an earlier age. The disease is very rare in childhood, but we have seen an example in a boy of 7. In general it may be said that growths of the cæcum occur at an earlier age than those in the rest of the colon. In a large number of cases, especially when the left half of the colon is the seat of

the neoplasm, the first symptoms are those of early obstruction. The patient states that he has *increasing* difficulty in getting the bowels to move, and that he has to take *increasing* doses of purgatives. Unfortunately, such warnings and the frequent turbulent borborygmi which accompany them are disregarded, and surgical aid is not sought until a state of acute-on-chronic intestinal obstruction has set in. The latter is discussed on p. 344.

Earlier symptoms, the recognition of which are so important if the disease is to be diagnosed in its operable stages, are more obscure, pain and loss of weight being singularly absent.

The following table culled from an analysis of case-histories of carcinoma of the colon (excluding the rectum), is helpful:

	Per cent.
Constipation	37
Alternating diarrhœa and constipation	21
Diarrhœa	14
Tumour	8
Pain	7
Blood or blood and mucus per rectum	5
Dyspepsia	3



FIG. 281.—An example of the inestimable value of sigmoidoscopy. The patient has been diagnosed and treated for some weeks for "Ulcerative Colitis." A barium meal was negative. Sigmoidoscopy showed a small bun-shaped carcinoma giving rise to an intussusception.

It thus comes about that if a patient, and particularly one past middle life, comes complaining of diarrhœa or constipation of recent origin, in addition to a clinical examination a barium enema and sigmoidoscopy (fig. 281) are essential. Unless advantage is taken of these diagnostic refinements, the clinician is neglecting his duty, and many comparatively early growths are bound to escape detection.

Treatment

If the growth is **inoperable,** see acute-on-chronic intestinal obstruction (p. 344). If the growth is **operable,** one of the following procedures can be undertaken :

Carcinoma of the cæcum seldom causes obstruction, and a satisfactory one-stage operation can often be performed. The last foot of ileum, the cæcum, ascending colon, and the right third of the transverse colon (fig. 282) are resected, and the continuity of the alimentary tract re-established by a lateral, end-to-end, or end-to-side anastomosis.

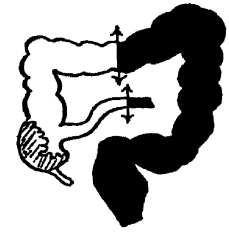

FIG. 282.—The portion of intestine removed in carcinoma of the cæcum or ascending colon.

Carcinoma of Other Portions of the Colon.—Before undertaking resection and anastomosis, the colon must be empty and clean. It is therefore often necessary to drain and wash out the bowel for a few weeks. For this purpose a temporary cæcostomy is often employed. The advantages of a cæcostomy are :

1. The temporary anus is well away from the field of the proposed resection.
2. The cæcostomy acts as a safety-valve during early days of the anastomosis, and this spares tension at the suture line.
3. A small cæcostomy sometimes closes spontaneously.

Its disadvantage is that it is difficult to cleanse the left half of a loaded colon through a cæcostomy opening, and on this account some operators prefer to forgo its advantages, and employ a temporary colostomy a little above the growth.

Carcinoma of the Ascending Colon or the Hepatic Flexure.—After preliminary drainage, the same wide resection as in the case of the cæcum is undertaken.

Carcinoma in the Remainder of the Colon.—A less extensive resection is employed, the aim being to remove 2 in. of healthy mucosa on either side of the growth, together with the glands in the mesentery. After this the ends of the bowel are anastomosed. A side-to-side anastomosis is safe, but owing to fixity, seldom practicable, except in the trans-

verse colon. An end-to-end anastomosis is usually employed, and the suture line is reinforced by an omental patch. In some growths, especially those of the pelvi-rectal junction, it is found impossible to bring the ends of the gut together without tension. Under these circumstances resection as wide as necessary having been completed, the lower end of the bowel is closed, while the upper end is used to make a permanent colostomy.

Paul's (syn. *Mickulicz's*) *Operation.*—In the absence of severe obstruction, preliminary drainage is unnecessary. Paul's operation embodies an entirely different principle. The method is not universally applicable, because for its performance the segment containing the growth must be capable of being delivered upon the surface. This operation removes the growth, but not always the glands in the mesentery. Briefly, the operation consists of the following stages :

1. That part of the gut containing the growth and as much mesentery as possible is drawn outside the abdominal wound, the two limbs of bowel being approximated by suture (fig. 283).

2. A few days later the prolapsed bowel is excised.

3. A crushing clamp is applied to the septum between the two limbs of the Paul's colostomy (fig. 284). This cuts through the septum in about five days.

4. There is now continuity of the lumina of the limbs (fig. 285), but a fæcal fistula remains, which requires closing in the usual way at a later date.

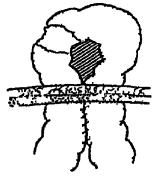

FIG. 283.

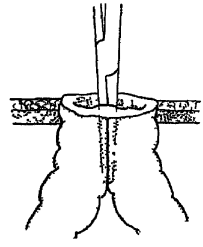

FIG. 284.

FIG. 285.

Paul's operation (see text).

CHAPTER XIX

INTESTINAL OBSTRUCTION

INTESTINAL obstruction can be divided advantageously into three classes :

Acute
Acute-on-Chronic
Chronic

ACUTE INTESTINAL OBSTRUCTION

GENERAL PRINCIPLES

Special forms of acute intestinal obstruction will be detailed later. It is necessary first to draw attention to the high mortality of acute intestinal obstruction in general, due largely to avoidable delay in arriving at the diagnosis.

Salient Features of Acute Intestinal Obstruction.—In acute obstruction, as opposed to acute-on-chronic obstruction, the small intestine is involved and *distension does not come on until late*. The first symptom is severe colicky pain, and this is soon followed by vomiting. The pain passes off, and the patient may look and feel well, but the pain returns again suddenly. In every case of suspected intestinal obstruction the first duty is to examine hernial sites ; we will assume that this has been done with negative results. In a thin subject visible peristalsis may be seen. The application of a stethoscope to the abdomen and the sound of turbulent peristalsis is valuable evidence in assembling diagnostic data. It is obvious that the bowels will be constipated, but too much reliance must not be placed upon this ; even in complete obstruction a fæcal result to an enema is often obtained. A second enema half an hour later is of more diagnostic value. The nurse should be told to note especially if *flatus* is passed. To administer a purgative to a patient with undiagnosed abdominal pain and vomiting is unpardonable ; neither is it justifiable to give morphia for

the relief of pain before the diagnosis has been made. If the present high mortality of intestinal obstruction is to be lowered, it must be more generally appreciated that considerable abdominal distension in acute obstruction is a late sign and that fæcal vomiting is but a herald of impending death.

The Cause of Death in Intestinal Obstruction.—So inevitably does the condition of a patient with intestinal obstruction deteriorate ; so surely, and in the case of the small intestine, so quickly does death follow if the obstruction is not relieved, that enquiring minds have sought to solve this riddle. The only explanation for the indisputable fact that the higher the obstruction the more rapidly is it fatal is that toxins are more easily absorbed from the jejunum.

THEORIES OF THE TOXÆMIA OF OBSTRUCTION

1. **The Chemical Toxin Theory.**—In obstructed intestine, digestion of proteins runs amok, and as a result of perverted katabolism a poisonous proteose, or amino-acid, is produced and absorbed (Whipple).
2. **The Bacterial Toxin Theory**
   Fact.—*B. Welchii* swarm in obstructed intestinal contents.
   Theory.—Their toxins are absorbed, and produce symptoms of toxæmia (Williams).
3. **The Dehydration Theory.**—As a result of repeated vomiting the tissues become dehydrated.
4. **The Alkalosis Theory**
   Fact.—In advanced obstruction the blood and tissue chlorides fall tremendously, and the alkali reserve increases (Haden and Orr).
   Theory.—The toxæmia is the result of alkalosis.

The outcome of this work is of the highest practical importance, for, as a result of the knowledge of these four theories, four methods of adjuvant treatment are instituted—adjuvant to the all-important relief of the obstruction by operation :

1. The stomach contents are aspirated, and the obstructed bowel is emptied of its contents at the earliest possible moment.
2. Anti-gas-gangrene serum is administered.
3. The dehydrated tissues are replenished by an isotonic solution given per rectum, subcutaneously, or intravenously, according to circumstances.

4. This solution should be isotonic sodium chloride, in order to restore the depleted blood chlorides.

Treatment.—Spinal, local, or evipan anæsthesia should be insisted upon in most cases. Spinal anæsthesia gives good muscular relaxation, which facilitates the work of the surgeon, and it circumvents the possibility of regurgitant vomiting. Under inhalation anæsthesia, when the intestine is obstructed, there is always a possibility of vomitus entering the air passages, which so often leads to fatal broncho-pneumonia.

The incision will depend upon the circumstances. If the cause of the obstruction is not known, a right lower paramedian is the best. On opening the abdomen the hand is passed at once to the cæcum. *If the cæcum is ballooned* the cause of the obstruction must lie in some part of the large gut. *If the cæcum is collapsed*, but the small intestine distended, the obstruction will be found in the small intestine; under such circumstances a collapsed loop is sought (fig. 286) and followed upwards. In this way the site of the obstruction is found.



FIG. 286.—Acute intestinal obstruction: tracing a collapsed coil to the site of obstruction (from *Emergency Surgery*).

The cause having been displayed, the simplest operation which will save life is indicated. The only exception to this rule is when the gut is gangrenous, for in this instance resection of the affected segment and end-to-end or side-to-side anastomosis must be completed. The following is a résumé of the simplest procedures in varying circumstances:

1. *The cause can be removed without difficulty*, e.g. bands, reducible intussusception, gall-stone.

2. *The obstruction can be removed, but there is considerable intestinal distension.* The gut must be emptied either by a temporary enterostomy or jejunostomy.[1]

3. *The obstruction cannot be removed, or only by a severe operation.* The distended intestine must be drained.

4. *The patient's life is almost despaired of before operation has begun.* Jejunostomy under local anæsthesia is performed, and general treatment, including salines and the administration of anti-gas-gangrene serum, is energetically pursued. Slender as are the chances, in young subjects the preservation of life is possible, and a more radical operation can be undertaken if the general condition improves.

Special Forms of Acute Obstruction

Acute Intestinal Obstruction of the New-Born

1. **Volvulus neonatorum.**—The whole mid-gut is affected (fig. 287). The symptoms are those of high acute intestinal obstruction. Suddenly the infant becomes the victim of a most acute intestinal obstruction, and vomits bile-stained material. Unless laparotomy is performed forthwith and the gut is untwisted, the condition is necessarily fatal.

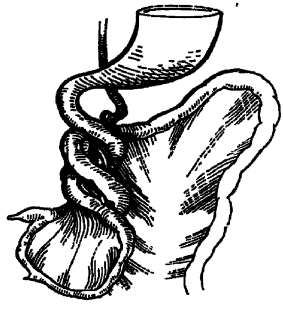

Fig. 287.—Volvulus neonatorum (after Dott).

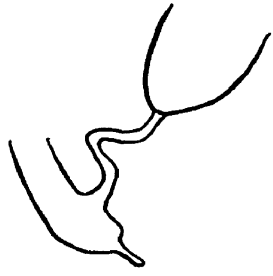

Fig. 288.—Congenital atresia of the ileum. The relative size of the gut above and below the septum is not exaggerated.

2. **Congenital atresia of the ileum** is due to a congenital septum across the lumen of the gut (fig. 288), usually at the level of Meckel's diverticulum. The obstruction comes on more gradually than in the case of volvulus neonatorum, but is nevertheless complete. The con-

[1] See also acute-on-chronic intestinal obstruction (p. 344).

dition is nearly always fatal, but there is no reason why this should be so if the septum is treated in the manner depicted in fig. 160.

See also Congenital atresia of the duodenum (p. 209).

Strangulated Hernia (see Chapter XXII).

Acute Intussusception

One portion of the gut becomes invaginated into another immediately adjacent; almost always it is the proximal into the distal. Occasionally the intussusception is retrograde.

Pathology.—An intussusception is made up of three parts:

1. The entering, or internal, tube.
2. The returning, or middle, tube.
3. The sheath, or outer, tube.

The outer tube is called the *intussuscipiens*. The inner and middle tubes together form the *intussusceptum*. The neck is the junction of the entering layer with the mass. That part which advances is the apex, and the mass which constitutes the intussusception (fig. 289) gathers as it advances.

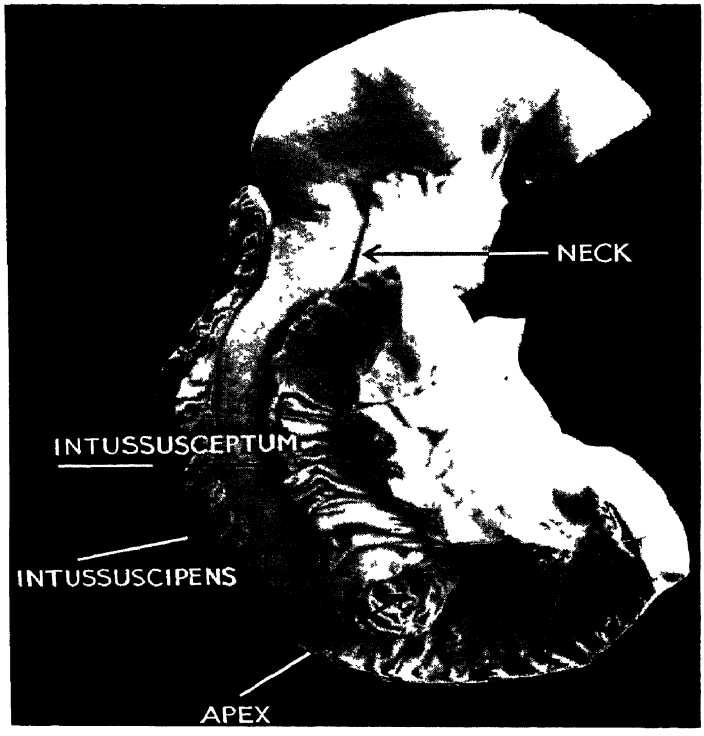

Fig. 289.—An intussusception dissected to show its constituent parts. (R.C.S. 6331.1.)

The blood-supply of the inner layers of the intussusception is liable to be cut off. It will be appreciated that the onset of gangrene is dependent upon the tightness of the invagination, and so it comes about that gangrene is especially liable to occur early in small, tight intussusceptions.

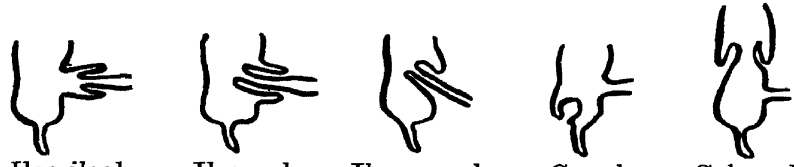

FIG. 290.—Varieties of intussusception.

Varieties (fig. 290).—The following is a simple classification :

1. *Ileo-ileal.* Ileum is invaginated into ileum	Approx.	8 per cent.
2. *Ileo-colic.* An ileo-ileal intussusception which has passed through the ileo-cæcal valve into the colon . . .	,,	36 ,,
3. *Ileo-cæcal.* The ileo-cæcal valve is the apex of the intussusception . .	,,	46 ,,
4. *Cæcal.* The caput cæci becomes invaginated	,,	2 ,,
5. *Colo-colic.* The colon is invaginated into the colon	,,	8 ,,

Ætiology.—In a few cases there is some understandable cause, for at the apex of the intussusception a polyp, a papilliferous carcinoma, a submucous lipoma, or an inverted Meckel's diverticulum is found protruding. Obviously such a protrusion invites intussusception (fig. 291). In intussusception of infants there is no such demonstrable cause, and considerable ingenuity has been expended in accounting for this common disease.

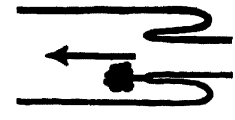

FIG. 291.—The mechanism of the production of an intussusception.

The following is a reasonable hypothesis for a condition which is otherwise difficult to explain.

Facts

1. Idiopathic intussusception occurs most often between the sixth and ninth months.
2. Between the sixth and ninth months there is a change in the infant's diet—it is weaned.
3. An idiopathic intussusception usually commences in some part of the last 2 ft. of the small intestine.
4. Peyer's patches are maximally aggregated in the lower ileum.

Theory

1. The change of diet brings about a change of intestinal bacteria.
2. This predisposes to inflammation of the intestinal tract.
3. Which in turn causes inflammation of Peyer's patches.
4. As a result Peyer's patches swell.
5. A swollen Peyer's patch produces an elevation protruding into the lumen of the gut comparable to one of the known causes of intussusception.

Clinical Features of Intussusception in Infants.—The patient is often a fine, lusty, male child between six and eighteen months, usually in perfect health when attacked. The onset is sudden. The child has a paroxysm of abdominal pain, draws up his legs (fig 292), and screams, and as the attacks grow more severe they are accompanied by distinct facial pallor. In between the attacks he lies listless and somewhat drawn. A normal stool may be passed at the commencement. Later blood and mucus are evacuated, which together are very characteristic, and constitute the well-known "red-currant jelly" stool.

FIG. 292.—Attitude of the infant during the spasms of colic which characterise intussusception.

On Examination.—The abdomen is not distended. It is important to palpate with a warmed hand between the spasms if possible while asleep. A lump, which hardens on palpation, may be felt in some part of the course of the colon (fig. 293). If the lump is lying under the right lobe of the liver, or at the splenic flexure, it is sometimes not possible to feel it even under an anæsthetic. There is said to be a feeling of emptiness in the right iliac fossa (signe de Dance). On rectal examination, if the intussusception has travelled far enough, its apex, a conical mass which is aptly likened to the cervix uteri, will be felt. In a few cases the intussusception actually protrudes through the anus. This does not necessarily imply that the intussusception is advanced, but rather that the patient has a mesentery which is unduly mobile.

FIG 293.—The physical signs recorded in a typical case of intussusception in an infant.

Unrelieved, the pain becomes continuous. The abdomen

commences to distend, and vomiting, which has not up to the present been much in evidence, becomes copious. Absolute intestinal obstruction follows, and death from this cause, or from peritonitis secondary to the gangrene, is the rule. Once in a while a natural cure, due to sloughing of the intussusceptum, has been reported.

Differential Diagnosis

1. *From Acute Enteritis.*—Here there is previous diarrhœa, whereas intussusception is more commonly preceded by constipation.
2. *From Purpura with Intestinal Symptoms (syn.* Henoch's purpura).—There is likely to be the characteristic rash, which is often mistaken for flea-bites. Intussusception is a not uncommon accompaniment of this form of purpura, consequently the differential diagnosis is not of vital importance, for exploratory laparotomy must be performed in suspicious cases.
3. *From Cœcal Tuberculosis.*—There will be a lump in the right iliac fossa, and perhaps passage of blood per rectum.
4. *From Prolapse of the Rectum.*—This is readily eliminated. In prolapse the projecting mucosa can be felt continuous with the perianal skin (p. 378). In intussusception protruding from the anus the finger passes indefinitely into the depths of a sulcus.

Intussusception in adolescents is nearly always caused by an inverted Meckel's diverticulum (p. 311).

Intussusception in adults is most often due to a papilliferous carcinoma ; consequently, the colo-colic type is frequent. Idiopathic intussusception is practically unknown except in Egypt, where examples have been encountered during the Mohammedan fasting season (Mooro).

Treatment of Intussusception.—No doubt in the early stages spontaneous rectification sometimes occurs. Reduction in established cases has followed repeated enemata, but so uncertain is this form of treatment that it has rightly fallen into disuse. The treatment of intussusception is urgent laparotomy. Unless the diagnosis has been unduly delayed, the intussusception can be reduced. Thanks to better diagnosis, the number of irreducible intussusceptions in infants is getting smaller and the mortality is correspondingly lower.

The Operation.—If the child is collapsed 5 per cent. glucose solution is administered before operation. We now use, almost as a routine, spinal anæsthesia in these cases. ·2 c.c. of stovaine in saline is the standard dose, but this must vary with the weight of the baby ; ·2 c.c. should, however, not be exceeded under the age of 2. The great advantage of

spinal anæsthesia is the resulting relaxation of the abdominal wall, which greatly facilitates the work of the surgeon. The abdomen is opened by a right paramedian incision. The intussusception is found, and with spinal anæsthesia it is usually possible to deliver the lump through the wound. This is always possible when the splenic flexure has been passed in the process of reduction. Reduction is accomplished by squeezing the lowest part of the sausage-like mass (fig. 294), and little by little the intussusception becomes unravelled. The last part of the intussusception is the most difficult to reduce, but in the majority of instances the whole process can be carried out in about 30 seconds. After reduction is completed, the terminal portion of small intestine, the caput cæci, and the appendix will be seen reddened and stiffened with œdema.

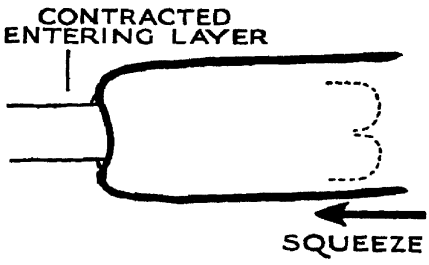

FIG. 294.—Diagram showing the method of reducing an intussusception

If the intussusception is difficult to reduce, the following methods are attempted, in sequence.

1. Continuous firm pressure.
2. The little finger is inserted into the neck of the intussusception and an endeavour is made to separate adhesions between the intussuscipiens and intussusceptum, after which reduction is attempted (Cope's method).
3. Blunt-nosed forceps are used to stretch the intussuscipiens at the neck (fig. 295) (Daw's method).

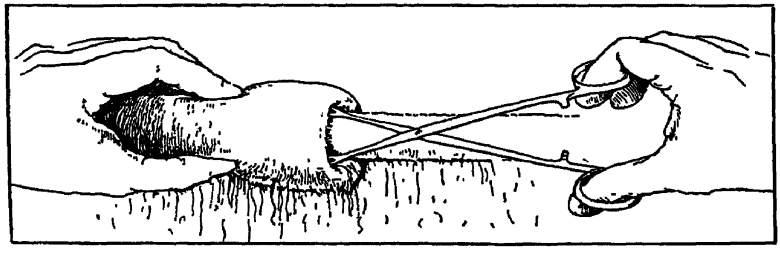

FIG. 295.—Daw's method of aiding the reduction of a tight intussusception.

4. One blade of a pair of scissors is introduced on the flat into the same space into which the little finger was previously inserted. The tight intussuscipiens below the neck is then nicked with the scissors.

Reduction is now always possible, but after reduction the rent, which will usually be found in the cæcum, must be repaired (Brown's method).

5. If gangrene has supervened, some form of resection with anastomosis of the ends of the gut is the only course.

After-treatment.—The patient is returned to bed, and anti-shock treatment continued. The foot of the bed is raised, and continuous 5 per cent. glucose solution is administered. In infants nepenthe, minim 1, is given by mouth every three hours for four doses.

VOLVULUS

Compared with the foregoing, volvulus is very rare in this country. A volvulus is caused as a result of axial rotation of a portion of the alimentary tract.

(*a*) **Volvulus neonatorum** (p. 333).

(*b*) **Volvulus of the small intestine,** other than the above, usually occurs in the lower ileum, and is favoured by the presence of an adhesion of the convexity of an intestinal loop (fig. 296) to the parietes or the pelvic organs.

FIG. 296.

(*c*) **Volvulus of the cæcum** occurs occasionally, especially when the right half of the colon is lax and mobile, and again it is favoured by a band of adhesions from the caput cæci to the peritoneum of the right iliac fossa, such as may follow appendicitis.

(*d*) **Volvulus of the sigmoid** is common in Eastern Europe. The predisposing causes are indicated in fig. 297. The usual picture of volvulus of the sigmoid is one of very acute obstruction, with rapid and enormous abdominal distension—distension so great that it may cause respiratory embarrassment. While the final attack is of this type, long before there are usually symptoms of recurrent attacks of pain in the left iliac fossa, which are often accompanied by a palpable resonant tumour. Massive œdema of the rectal wall, due to the inferior mesenteric vein becoming occluded in the torsion, has been noted in this form of volvulus.

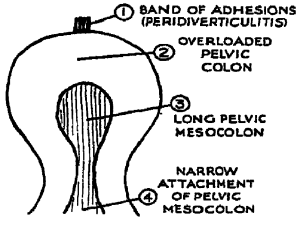

FIG. 297.—The predisposing causes of volvulus of the sigmoid.

Treatment.—The fluid found on opening the abdomen is said to be chocolate-coloured, due to altered blood. When laparotomy has been performed early in the attack untwisting is usually possible. In the case of volvulus of the sigmoid, recurrence is so likely that it is advisable to bring the dilated loop on to the surface, and later to excise and anastomose the ends by Paul's method (p. 329). When a volvulus is irreducible, or gangrene has occurred, resection must be carried out.

Obstruction by Bands and Adhesions

By Bands.—Bands form an important group in the causes of obstruction. The band may be congenital, e.g. an obliterated omphalo-mesenteric duct, or, more frequently, inflammatory, due to previous peritonitis. Division of the band or bands, thereby releasing the obstructed loop, providing the gut is viable, is the simplest and most satisfactory capital operation in surgery.

Fig. 298 —Obstruction of the small intestine by a band. (R.C.S. 2691.B.)

By Adhesions

Type 1.—Adherence of a loop or loops of intestine to inflamed intraperitoneal structures, e.g. a tuberculous mesenteric gland.

Type 2.—As a complication of the plastic form of tuberculous peritonitis (fig. 299).

Type 3.—Early post-operative adhesions usually occurring between ten days and three weeks after an abdominal operation, particularly one for peritonitis.

Type 4.—Late post-operative adhesions occurring any time from months to many years after such an operation.

Obstruction due to adhesions is not nearly so easily remedied as in the case of bands. In early cases the affected loop can be dissected free and wrapped in omentum. In other cases, lateral anastomosis between a dilated loop above and a collapsed loop below circumvents the obstruction, although more radical measures may have to be undertaken later.

Obstruction from Stricture of the Intestine

Stricture of the Small Intestine.—Cicatricial contracture is usually an aftermath of tuberculous ulceration. Multiple strictures are often present, but the one with the smallest

lumen becomes blocked with food residue or an ingested foreign body. Malignant stricture is rare. Both carcinoma and lympho-sarcoma occur from time to time.

Stricture of the large intestine so often gives rise to acute-on-chronic obstruction that it is considered under that heading.

FIG. 299.—Adhesions, between loops of intestine, the result of tuberculous peritonitis (Maylard.)

Obstruction by Gall-stone

Obstruction by gall-stone usually occurs in elderly women. The gall-stone, which is a large one, ulcerates through the wall of the gall bladder into the duodenum. It passes down the small intestine, and becomes impacted in its lower third, because this is the narrowest part of the small gut. The symptoms are elusive. The patient experiences colic, accompanied by copious vomiting. There is often a fair result to an enema, and remissions of symptoms are frequent, but the vomiting returns, and by this time it is bilious. There is no abdominal distension until late, and late intestinal obstruction in an old person is an almost hopeless condition. On rare occasions a gall-stone causes obstruction by lodging in the large intestine, and produces symptoms similar to those of carcinoma of the colon.

Treatment is laparotomy and removal of the stone with the repair of the incision into the gut. It is an advantage



FIG 300.—Gall-stone which caused intestinal obstruction (actual size).

to sew up the incision in the intestine transversely, to avoid constriction at this point. The gall-stone which causes intestinal obstruction is nearly always barrel-shaped (fig. 300).

OBSTRUCTION BY STERCOLITH

This gives rise to similar symptoms. It is much rarer, and usually occurs in younger persons. The stercolith may contain as a nucleus a fruit stone, or other foreign body.

Treatment is similar to the above.

OBSTRUCTION DUE TO WORMS

In African negroes a tangled intestinal mass of worms is not an uncommon obstructing agent. Again, the lower end of the ileum is the usual seat of the obstruction. The treatment is similar to the above.

EMBOLUS AND THROMBOSIS OF THE SUPERIOR MESENTERIC VESSELS

An embolus lodging in the superior mesenteric artery or thrombosis occurring in the corresponding vein gives rise to the same train of symptoms, but the former is likely to be more sudden in its onset. Repeated vomiting, with, it should be noted, sometimes blood-stained diarrhœa, ushers in this catastrophe. On examination an indefinite movable sub-umbilical soft lump can often be felt in thin subjects. The lump is the infarcted congested segment of small intestine.

Mesenteric embolus is not often correctly diagnosed before operation, but it should be strongly suspected when a patient with heart disease, particularly mitral stenosis, presents symptoms of acute obstruction.

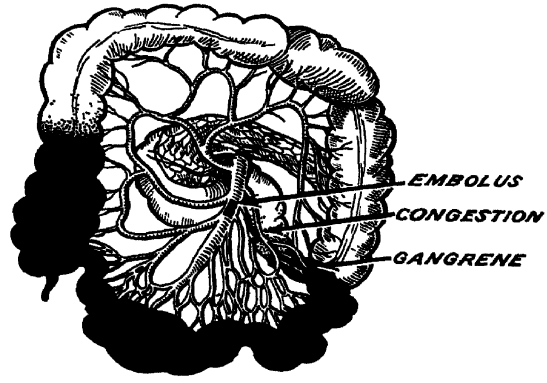

FIG. 301.—Embolus lodged in the superior mesenteric artery showing the widespread gangrene which results (after Childe).

Treatment.—Providing laparotomy is carried out early, that is, within a few hours of the initial attack, wide resection of the affected segment of intestine with anastomosis offers reasonable hope. Naturally, if the main trunk of the artery is entirely blocked (fig. 301) the condition is hopeless. More usually the embolus lodges in one

of its branches, and many feet of infarcted intestine have been excised successfully.

INTERNAL HERNIÆ

A loop of intestine passes into a peritoneal opening within the abdominal cavity, which may be one of the following:

1. A congenital defect in the left side of the diaphragm.
2. A hole in the mesentery.
3. One of the retroperitoneal fossæ, of which the following are the most important.

Fossæ about the Duodenum

(*a*) A para-duodenal fossa. The inferior mesenteric vein lies in its free border.

(*b*) The right duodeno-jejunal fossa. The superior mesenteric artery runs in its free border.

(*c*) The foramen of Winslow. The portal vein, common bile duct, and hepatic artery lie in its free border.

Fossæ about the Cæcum and Appendix

(*a*) Superior ileo-cæcal fossa between the mesoappendix and the general mesentery.

(*b*) Inferior ileo-cæcal fossa. Between the "bloodless" fold of Treves and the mesentery of the appendix.

(*c*) The retrocæcal fossa behind the cæcum.

The Intersigmoid Fossa

With the exception of the fossæ about the cæcum, important, if not vital, blood-vessels run in the free edge of the neck of the sac. These must not be divided to relieve the obstruction. In the case of the paraduodenal fossa and the intersigmoid fossa, it is generally feasible to cut the neck in an avascular region, and thus free constricted gut. This is always possible in the case of the fossa about the cæcum and appendix. In the case of the foramen of Winslow, or a hole in the mesentery, the gut must be emptied in the manner shown in fig. 302, after which reduction will be possible. In the former instance the obstructive loop can be exposed by entering the lesser sac between the stomach and the colon (see fig. 225).

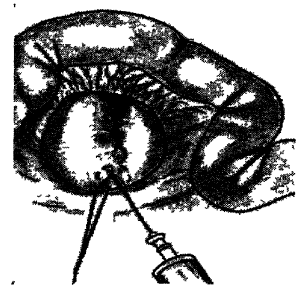

FIG. 302.—Strangulation through a hole in the mesentery. Emptying the obstructed loop before attempting reduction.

PARALYTIC ILEUS (*syn.* ADYNAMIC ILEUS)

Paralytic ileus follows a number of different conditions. As the name implies, the gut wall becomes paralysed, and refuses to transmit peristaltic waves. It dilates, sometimes enormously, and the patient exhibits signs of intestinal obstruction. As a rule, the lower ileum is maximally affected. Clinically a large number of these cases occur as a complication of pelvic peritonitis, but in this instance it is a moot point whether a mechanical obstruction, due to mutual plastic adhesion of loops of small intestine, or adynamic ileus is the major factor.

Treatment.—Great differences of opinion exist as to the better method of procedure. Some advocate commencing treatment with stimulation of the bowel by giving purgatives, pituitrin, and eserine. Others insist that to stimulate peristalsis is like whipping a tired horse, and therefore often aggravates the condition, for it simply results in forcing more intestinal contents from the non-paralysed loops above into paralysed loops below. They teach that the intestine should be rested. If vomiting is in evidence, the stomach contents are aspirated. Anti-gas-gangrene serum is given, and only water by mouth and by rectum. If the diagnosis is assured,[1] a dose of morphia is prescribed. Twelve hours later an enema is given. If there is still no result, but the patient is somewhat better, another period of rest is sometimes prescribed. More usually, and especially if the case belongs to that common class following peritonitis, 1 c.c. of pituitrin is given. If the bowels act, well and good ; if not, spinal anæsthesia is induced. Occasionally spinal anæsthesia relieves the condition, and the patient passes a copious motion. If there is still no result, the abdomen must be opened, and a loop of dilated small intestine drained.

Acute-on-Chronic Intestinal Obstruction

This form of obstruction is almost confined to the large gut. Occasionally some of those conditions which have been dealt with in acute intestinal obstruction are preceded by a chronic stage. However, the cause is so regularly carcinoma of the colon (or its imitator, hyperplastic diverticulitis), that for practical purposes acute-on-chronic intestinal obstruction is a large-gut obstruction due to carcinoma of the colon or rectum.

Clinical Features.—The patient has increasing constipation, which is later associated with colic. In the case of the large intestine, abdominal distension is the leading feature, and no matter where the obstruction lies, whether in the ascending, transverse, or descending portions of the colon or in the rectum, the brunt of the obstruction will be borne by the

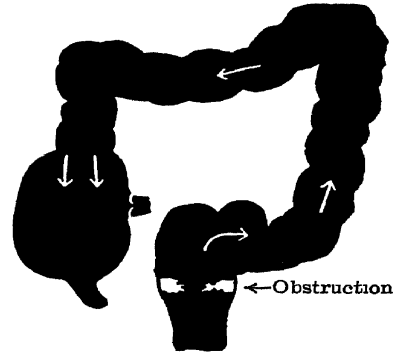

Fig. 303.—Wherever the large intestine is obstructed the cæcum bears the brunt.

[1] 1 gr. of acetylcholine hourly for six doses has been found effective in some cases of paralytic ileus A great advantage of this only is that it does not precipitate obstruction if the diagnosis happens to be incorrect and there is mechanical stenosis of the gut's lumen (A. L. Abel).

cæcum. This has been likened to a gun backfiring into its breach, and the cæcum becomes ballooned (fig. 303). Peristalsis can often be seen if the abdomen is patiently watched. The general condition of the patient remains good until a late hour, and it is not until fæcal vomiting has set in that he presents the sharpened features, sunken eyes, rapid pulse, and clammy skin which foretell that the toxæmia of obstruction has set in. Acute-on-chronic intestinal obstruction of the large intestine should cause but little difficulty in diagnosis. The early symptoms are much too frequently attributed to fæcal impaction, a condition which, in our experience, is comparatively rare. A rectal examination will at once eliminate this possibility, for in fæcal impaction masses of hard fæces will be felt.



FIG. 304.—Sites for an artificial anus. 1. Left inguinal colostomy. 2. Transverse colostomy. 3. Cæcostomy.

Treatment of Acute-on-Chronic Obstruction.—The same principles of general treatment as in those of acute obstruction hold good, but we must review briefly the operative technique to be adopted when the obstruction lies in the large gut.

If the patient's condition is very grave, blind cæcostomy is performed. By *blind* cæcostomy is meant that the cæcum is drained without exploring the abdomen.

With this exception, the abdomen should be explored through a left paramedian incision. If the growth is **operable** a temporary cæcostomy is performed.

If the growth is **inoperable** a colostomy is performed, and the site of the artificial anus will depend on the situation of the growth (fig. 304). *If it is in the pelvic colon or rectum* a left inguinal colostomy will be best. *If at the splenic flexure* a transverse colostomy is indicated. *If at the hepatic flexure or in the ascending colon,* as a permanent

cæcostomy is so objectionable (the fæces here are fluid) a short-circuiting operation is usually advisable.

Special Complication.—In cases of enormous distension, which too frequently accompanies neglected cases of acute-on-chronic intestinal obstruction, spontaneous perforation into the peritoneum quite often occurs. The perforation is usually in the cæcum, where the brunt of the obstruction is felt. Less often it is found at the site of the growth.

FIG. 305.—Left inguinal colostomy. Passing a spigot through the mesentery so as to keep the loop of gut on the surface.

CHRONIC INTESTINAL OBSTRUCTION

Causes

In the child

1. Hirschsprung's disease (p. 311).
2. Adhesions, usually an accompaniment of tuberculous peritonitis (p. 298).
3. Chronic intussusception.

In the adult

1. Carcinoma of the colon (p. 325).
2. Diverticulitis (p. 319).
3. Peritoneal adhesions.
4. Chronic intussusception.
5. Fæcal accumulations.
6. Chronic intestinal stasis.

CHAPTER XX

THE VERMIFORM APPENDIX

ACUTE APPENDICITIS

OVER three thousand persons die annually from appendicitis in England and Wales alone. Many of them are in youth or the prime of life. Practically all these lives could be saved if an early diagnosis was made, and, at this stage, the comparatively simple operation of appendicectomy was performed. The importance of this subject cannot be overstated.

SURGICAL ANATOMY

The vermiform appendix is present only in man, certain anthropoid apes, and the wombat. Morphologically it is the undeveloped distal end of the large cæcum found in many lower animals, just as the cæcum of these animals is but a rudiment of the comparatively enormous cæcum of herbivora.

Physiologists have been unable to assign any specific function to the appendix, except that in common with the rest of the intestine it secretes a little mucus. That it is entirely dispensable is proved by hundreds of thousands of individuals who have had their appendices removed, and who remain in perfect health.

Size.—So great are the variations in length and circumference that it is difficult to state what should be looked upon as normal. The average length is between 3 in. and 4 in., but variations from ½ in. to 8 in. are not unusual. As to the normal dimensions of its lumen, we are on more certain ground ; it should be of uniform calibre, admitting a goose quill. There is a feeble valve at the cæcal orifice which is merely a fold of mucous membrane (Gerlach's valve).

The Coats of the Appendix.—Upon transverse section the following layers can be distinguished from without inwards.

1. The peritoneal coat, which is complete except over the attachment of the mesentery.
2. A subserous layer of connective tissue.
3. A muscular coat comprised of an outer longitudinal and an inner circular layer. The muscular vestment of the appendix is not complete. Gaps called the *hiatūs muscularis* are present where the vessels penetrate its walls. These gaps afford a possible explanation of the apparent ease with which organisms in appendicitis migrate to the peritoneal cavity.
4. A submucous layer containing a heavy deposit of lymphadenoid tissue.
5. Mucous membrane, rich in Lieberkühn's glands.

The mesoappendix contains a variable amount of fat.

Vascular Supply.—The appendicular artery is usually stated to be the only arterial supply of the appendix (fig. 306).

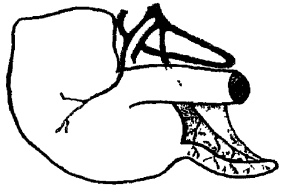

FIG. 306.—The usual arterial supply of the appendix.

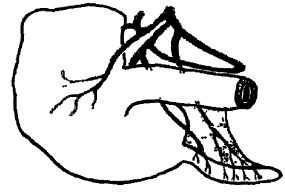

FIG. 307.—In nearly 50 per cent. of cases there is an accessory appendicular artery, a branch of the posterior cæcal. (After Seshachalam.)

Surgeons note repeatedly that there is a second artery in the mesoappendix which requires a second ligature. The accessory appendicular artery is usually a branch of the posterior cæcal artery (fig. 307).

The appendicular vein is a radicle of the ileo-colic vein, which drains into the portal system.

Lymphatic Supply.—The lymphatics draining the appendix follow the appendicular arteries between the layers of the mesoappendix. There are four, six, or more of these channels, and they empty into the ileo-cæcal glands, situated between the layers of the mesentery of the small intestine at the ileo-cæcal angle.

McBurney's point has been the guide to the area of greatest tenderness in appendicitis ever since it was first described by its originator in 1889. The point is usually inaccurately described. In the original statement it is given as being

between $1\frac{1}{2}$ in. and 2 in. from the anterior superior iliac spine upon a line joining the anterior superior iliac spine and the umbilicus (fig. 308). McBurney's point, as described by McBurney, is the classical point of greatest tenderness in appendicitis, and also a most useful point to have in mind when an incision to expose the appendix is about to be made.

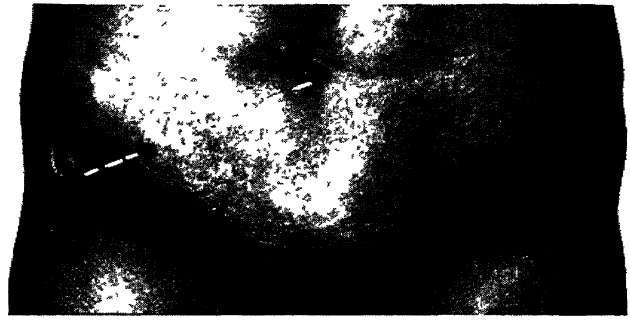

FIG. 308.—McBurney's point.

Its erroneous usurper, which unfortunately has been copied from book to book, is a point at the junction of the outer and middle thirds on the same line. The latter is too far medial.

Inconsistency of Position.—The vermiform appendix is the only organ in the body which has no normal position. Extravagant positions are usually associated with failure of the cæcum to descend (p. 309). The relative frequency of the more usual positions occupied by the organ are depicted in fig. 309.

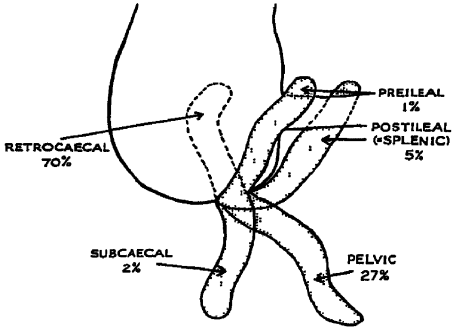

FIG. 309.—The relative frequency of the various positions of the appendix. (From data compiled by Gladstone and Wakeley.)

Locating the Appendix.—Even when the cæcum is in full view it is not always an easy matter to find the appendix. In difficult cases the following method will be found to be of value in aiding the search. Trace one of the tæniæ coli downwards; this must lead to the base of the appendix. If the organ is still not visible and it is certain that it has not been removed, it will probably be found

buried in the posterior cæcal wall, and will be discovered by palpation and dissection.

ÆTIOLOGY

Appendicitis was practically unknown until the close of the nineteenth century. During the past thirty years it has become a disease of great frequency and importance.

The Longest, Narrowest Intestinal Diverticulum.—Attention has been directed already to the liability of intestinal and urinary diverticula to inflammation, and the reader will have no difficulty in appreciating why the vermiform appendix is so frequently attacked. Here is a long, mucus-lined canal with a narrow orifice opening into the cæcum. Owing to the shape of its mesentery the appendix is habitually more or less kinked, and in 50 per cent. of cases the organ is supplied by a small, single artery. It requires little imagination to realise that if the organ becomes more kinked or twisted, or if there is even a slight œdema of the mucosa near its base, or if its lumen becomes obturated by a fæcal concretion, we have all the factors necessary for an immediate and lively bacterial invasion.

Race and Diet.—Appendicitis is particularly common in the highly civilised European, American, and Australian countries, while it is rare in Asiatics, Africans, and Polynesians. If, however, individuals from the latter races migrate to the countries where appendicitis is common they soon acquire the local susceptibility to the disease (Rendle Short). Even apes in captivity appear to acquire the human liability to appendicitis. These significant facts satisfy many that the rise of appendicitis amongst the highly civilised is due to an unbridled departure from a simple diet rich in cellulose. But this cannot be the whole explanation, for acute appendicitis occurs in babes at the breast and in life-long vegetarians, as we have witnessed.

Familial Susceptibility.—That there is sometimes a familial tendency to the disease cannot be disputed. This generally accepted fact can be accounted for by an hereditary malformation of the organ, which predisposes to infection. Thus,

the whole family may have a long retrocæcal appendix with a comparatively poor blood-supply, and many of its members fall victims to appendicitis in one form or another.

Foreign Bodies.—Grape-pips, shot, pins, and other foreign bodies are found occasionally in the lumen of the appendix, but they are at least as frequently discovered by accident as in the course of designed operation for appendicitis. That pips and fruit-stones are the cause of appendicitis is a theory deeply rooted in the lay mind. This fallacy was born in the early days of appendicectomy when fæcal concretions within excised appendices were reported to be date-stones and fruit-pips.

Worms.—Not unnaturally, if worms are present in the intestinal canal some of them are likely to find their way into a patent vermiform appendix. Thread worms, a widespread intestinal parasite, are not infrequently found within excised specimens. It is quite possible that oxyuris, ascaris, and other intestinal parasites, e.g. bilharzia, cause inflammation in isolated instances of appendicitis.

Trauma.—It is unlikely, but impossible to disprove, that trauma is directly responsible for the onset of appendicitis. This being the case, when the onset of appendicitis and the history of a relevant accident closely coincide, judgment in the courts has been given in the plaintiff's favour.

Concretions and Strictures.—Appendicular concretions and strictures narrowing the lumen of the appendix, while probably not being an actual cause of appendicitis, undoubtedly are often contributory factors. The worst form of appendicitis, to wit, appendicular obstruction, is often determined by the presence of a concretion or a stricture preventing the products of inflammation escaping into the cæcum.

The Abuse of Purgatives.—Here again is another contributory factor of great importance. It is abundantly clear that the common practice of administering purgatives, particularly castor oil, to patients with "stomach ache," and the violent peristaltic action which results, favour, and often determine, perforation of an inflamed appendix. "Purgation means perforation" is a wise adage.

Is the Appendicular Artery Culpable?—It has been shown that in approximately 50 per cent. of cases the appendicular artery is a single-end artery. It is possible, but in our view unlikely, that this artery becomes suddenly obstructed by angulation of the appendicular mesentery, and so early gangrene of the organ is produced. When gangrene results in a non-obstructed appendix a contributory factor appears to be a thrombosis of the appendicular veins rather than an obstruction to its arterial supply.

Bacteriology.—There is no one organism mainly responsible for appendicitis. Cultures from inflamed appendices usually reveal that the infection is mixed and there is hardly a pyogenic organism which has not been isolated from such specimens.

FIG. 310.—Acute appendicitis. Perforation imminent.

Rarely, a pure or almost pure culture of Bacillus coli is obtained, and more rarely still a Streptococcus fæcalis is the only organism present. B. aerogenes capsulatus (B. Welchii) has been found in a number of cases of appendicitis, including fulminating examples. Anti-gas-gangrene serum has been found of value, in conjunction with surgical treatment, in cases of gangrenous and perforated appendicitis. Aschoff considers that a small gram-positive organism, which he has found situated near the tip of symptomless and normal appendices, for some reason becomes virulent and is the actual cause of appendicitis.

Pathology.—The menace of acute appendicitis lies in the frequency with which the peritoneal cavity is infected from this focus. Peritoneal infection takes place :—

1. By perforation (fig. 310).
2. By transmigration of bacteria through the appendicular wall.

Attention has been directed to the value of the great omentum in attempting to limit the extent of the peritoneal invasion on the one hand and on the other to the force-pump action of ingested purgatives in determining a widespread infection.

It is of the greatest possible importance to recognise two types of acute appendicitis.

(*a*) **Acute Appendicitis Proper.**—There is an acute inflammation of the wall of the appendix. Such inflammation probably always commences as a simple catarrhal mucosal lesion and like any inflammatory process inflammation terminates in one of the following :—

1. Resolution.
2. Suppuration.
3. Fibrosis.
4. Gangrene.

(*b*) **Acute Appendicular Obstruction.**—The lumen of the inflamed appendix is obstructed by a concretion, a stricture, or both. Acute appendicular obstruction is very fatal because it is of the closed loop type, which tends to early gangrene, and within six to twenty-four hours the obstructed organ is lifeless and green (fig. 311). Close examination of gangrenous appendices directly after their removal shows conclusively that they usually belong to the obstructive group. In calling attention to this fact Professor Wilkie has rendered a great service.

FIG. 311.—Acute obstructive appendicitis with gangrene. There is a large fæcal concretion impacted in the proximal end of the lumen of the organ.

Very often perforation of the obstructed appendix results, particularly at the site where a concretion is impacted (fig. 312). As soon as a perforation is established the obstructed contents of the appendix metaphorically, if not actually, hiss forth (fig. 313) to infect the peritoneal cavity.

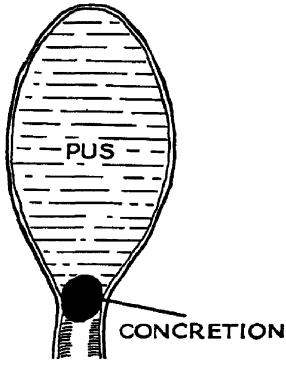

FIG. 312.—Acute obstructive appendicitis.

Fæcal concretions vary in size and have a laminated structure. They are composed of inspissated fæcal material, calcium and magnesium phosphates and carbonates, bacteria and epithelial debris; rarely, a foreign body is incorporated in the mass.

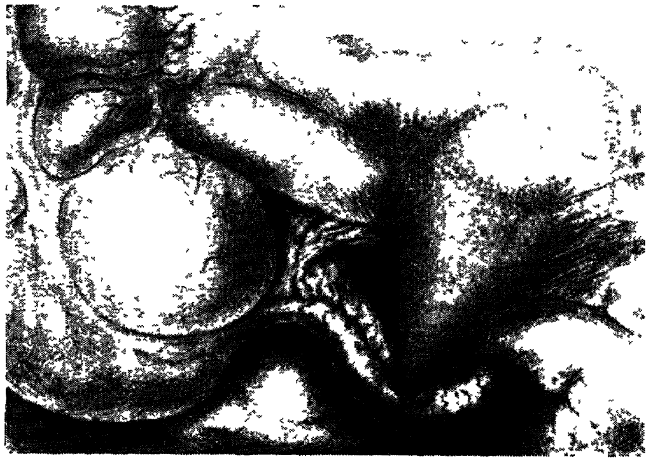

FIG. 313.—The bursting of an obstructed appendix often results in an immediate widespread bacterial peritonitis.

Clinical Features of Acute Appendicitis

Age.—No age is exempt. While it is true that appendicitis is far more common in young adults, it is found in early infancy and even in extreme old age.

Sex.—Until a decade or so ago males were attacked more often than females. To-day there is very little disparity between the frequency with which the sexes are attacked. The rise in the number of females suffering from appendicitis is but another curious factor in this comparatively new disease.

Typical Symptoms and Signs.—Usually without previous warning, and classically at 2 a.m., the patient develops sudden, severe, general abdominal pain, most marked near the umbilicus. This is soon followed by nausea and vomiting. Vomiting is reflex, and often, as soon as the stomach is empty, it ceases for many hours. Examined at this stage the whole abdomen is tender. The tongue is moderately furred and the bowels recently constipated.

The tenderness is most marked in the right iliac fossa, where a variable amount of rigidity is also present. In a large proportion of cases hyperæsthesia in Sherren's triangle (fig. 314) can be elicited.

Between six and twelve hours after the onset of the attack the pain shifts from around the umbilicus to the right iliac fossa and rigidity in this area becomes more marked.

No mention has been made of the temperature and pulse because they are of little diagnostic importance. The temperature is usually somewhat raised and the pulse quickened. The diagnosis of acute appendicitis is usually

easy, and the best single sign is localised rigidity in the right iliac fossa.

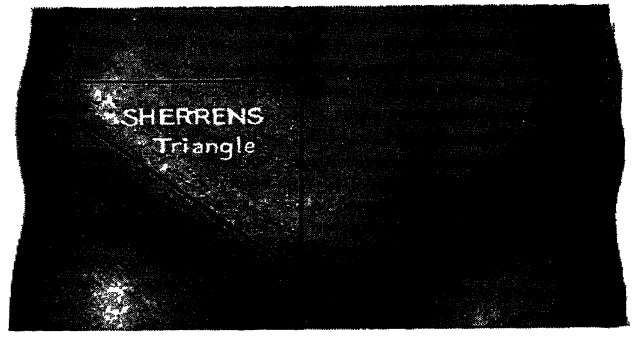

FIG. 314.—Sherren's triangle, formed by the umbilicus, the highest point of the iliac crest and the right pubic spine.

In those cases where there is even the slightest doubt in the diagnosis a rectal examination should be made. Indeed, it is a good practice to make this examination an invariable rule. If the appendix occupies a pelvic position there will be tenderness in the recto-vesical pouch. Typical cases constitute about 60 per cent. of the total, and a history of previous attacks makes the diagnosis undeniable. One attack of appendicitis predisposes to another.

ACUTE APPENDICULAR OBSTRUCTION

The leading symptom is colic—general abdominal pain comes and goes. The colic is often severe. The patient may vomit once or twice, but this does not relieve the spasms. The temperature is usually normal and the pulse between the attacks is not necessarily accelerated. Abdominal tenderness is general, and if the appendix is in the right iliac fossa and not covered by the cæcum this area will be acutely tender. If it is in the pelvis the rectal examination will be significant. If retrocæcal or splenic in position localisation of tenderness may be entirely missing, although deep finger-point tenderness in the loin sometimes suggests a diseased appendix in the former situation. Hyperæsthesia in Sherren's triangle is often of the utmost value in the diagnosis of these cases. When it is present the appendix should be removed just as soon as it is possible. We have also found Rovsing's sign of help in not a few instances.

Rovsing's Sign.—Even pressure is exerted over the pelvic colon. This forces gas into the cæcum. If pressure on the left causes pain

to be felt in the right iliac fossa the case is probably one of acute appendicitis.

Appendicular colic must be distinguished from renal, biliary, and intestinal colic.

From Renal Colic.—In both renal and appendicular colic the testis of that side is often retracted. In typical renal colic the pain commences in the loin, and passes to the groin. This peculiar radiation, combined with some definite urinary symptom, serves to distinguish many, if not most, cases.

When the difficulty in differentiating renal from appendicular colic remains insuperable after examining the patient twice in the space of an hour and testing the urine, there should be no hesitation in performing urgent cystoscopy. If the discharge of indigo carmine from the right ureter (fig. 422) is delayed considerably, it suggests that the patient is suffering from renal colic. Several times in perplexing cases we have taken a specimen of urine from the right ureter by catheterisation, and by immediately centrifuging the specimen demonstrated pus cells when the clinical examination of the urine had revealed nothing abnormal. If these facilities are not available or are inconclusive, and the differential diagnosis cannot be arrived at quickly, appendicectomy should be performed forthwith.

From Biliary Colic.—Typical cases of biliary colic are diagnosed readily, the radiation of the pain from the right hypochondrium to the back or between the shoulders being characteristic. A high, obstructed retrocæcal appendix sometimes gives similar symptoms. By careful deep palpation between the attacks it is often possible to make out a tender pyriform swelling continuous with the liver. The elicitation of Murphy's sign (p. 270) between the spasms is also helpful.

From Intestinal Colic.—Unfortunately the laity usually diagnose "green apple" colic, and promptly administer a powerful purgative. The administration of a dose of castor oil in a case of acute obstructive appendicitis can render a mother the unconscious murderer of her child. If it were not for the fact that the patient often vomits the purgative the death-rate from "cathartic" peritonitis, already alarmingly high, would be higher still. The absence of diarrhœa, the presence of hyperæsthesia, and the finding of an acutely tender spot over one of the possible positions of the appendix, in the majority of cases make clear the diagnosis of

appendicitis. If acute obstructive appendicitis cannot be ruled out early appendicectomy is more than justified.

The general appreciation of acute obstructive appendicitis and its manifold dangers would help to lower the excessive preventable mortality from appendicitis.

Atypical Acute Appendicitis

A factor to be contended with is that the diagnosis of acute appendicitis is sometimes very difficult. There are many atypical cases, which is not to be wondered at in an organ whose size, shape, and above all position, are so variable.

As in the case of acute intestinal obstruction, and every other condition where there is a regrettably high, preventable mortality, textbooks are blamed for impotency in portraying a true clinical picture of the disease in its curable form. We will now endeavour to grapple with the problem of atypical acute appendicitis, and some of the legion of differential diagnoses which arise therefrom.

1. **Early Acute Appendicitis with a High Temperature.**—If the temperature is over 102° F. within the first twelve or twenty-four hours of an attack of abdominal illness, there is a tendency at once to rule out acute appendicitis, even in the presence of some sign pointing to that condition.

True, such cases are usually due to pneumonia or right-sided pyelitis, and it is not our object to question this probability. But we have seen a case of a boy of 16 who, within six hours of an attack of acute appendicitis, had repeated rigors and a temperature of 103·5. Such cases are confusing and often signify that portal pyæmia is imminent.

The point we wish to make is that appendicitis cannot be eliminated because the temperature is too high. The examination should be just as thorough and the differential diagnosis weighed, taking the temperature as but a moiety of the factors before us.

2. **Acute Appendicitis with Diarrhœa.**—Constipation is so usual in the early stages of acute appendicitis that when diarrhœa accompanies it the true diagnosis is liable to be overlooked. If diarrhœa is accompanied by even slight, but constant, tenderness and some rigidity in the right iliac fossa, other things being equal, the appendix should be explored (see also Pelvic Abscess, p. 290).

3. **Acute Appendicitis without Abdominal Rigidity.**—Abdominal rigidity may be entirely absent :

(*a*) When the appendix is deeply placed in the pelvis. The rectal examination should prove invaluable in this instance.

(*b*) When the appendix is retrocæcal and virtually extra-peritoneal. Some of the problems connected with retro-cæcal appendicitis have been referred to in the differential diagnosis of the colics (p. 356).

(*c*) In obstructed appendicitis, especially soon after perforation has occurred. Immediately after an obstructed appendix has perforated the violent abdominal pain disappears. The patient often says he feels better. The hyperæsthesia goes, rigidity may be almost, if not entirely, absent, but *the pulse-rate soon begins to rise.* But for the last-named sign we would be mistaken more often than we are. Probably this is the most difficult phase of acute appendicitis to diagnose.

It is in problems such as the above that a leucocyte count is sometimes of value, a polymorpho-leucocytosis being contributory evidence of an inflammatory lesion.

The Erroneous Diagnosis of Acute Appendicitis

The commendable anxiety to diagnose and remove an acutely inflamed appendix early in the attack necessarily leads to a proportion of cases where the diagnosis is found to be in error. Such a proportion should be small ; for it to be high implies carelessness or perhaps an exuberance of zeal.

Cases where the diagnosis of acute appendicitis is in error fall into three classes.

1. **Definite Acute Pseudo-Appendicitis.**—Acute appendicitis is diagnosed and the appendix is removed. Macroscopically and microscopically the appendix appears to be normal. The patient is relieved of symptoms and convalesces without incidence. Such cases are not infrequent and are difficult to explain. It is possible that a few of them are in truth examples of early acute appendicitis, for the histological diagnosis of early appendicular inflammation is notoriously difficult. The remainder are probably examples of temporary gaseous distension of the cæcum associated

with constipation. In this instance no harm, and possibly good, accrues from the removal of the appendix.

2. **The Patient is suffering from a Condition not requiring Operation.**—From a long list of possible errors the following important examples can be cited.

(*a*) *Early Pneumonia and Pleurisy.*—Diaphragmatic pleurisy often gives rise to referred abdominal pain and abdominal rigidity. When right sided, and when percussion and auscultation of the chest are negative, the differential diagnosis can be difficult. Movement of the alæ nasi and an increased rate of respiration definitely favour a thoracic lesion. To operate in early pneumonia jeopardises the life of the patient. In all doubtful cases a consultation with a physician should be held. This is the outstanding erroneous diagnosis, and the one which gives greatest cause for regret.

(*b*) *Abdominal influenza* is another condition which is sometimes supremely difficult to distinguish from acute appendicitis. The difficulty, of course, only appertains during epidemics of influenza. We have more than once removed a normal appendix in such circumstances.

(*c*) *Early pregnancy* sometimes commences with abdominal pain and vomiting, and when the pain is right sided differential diagnosis is difficult, especially in the unmarried.

(*d*) *Suppurating Deep Iliac Glands.*—Acute inflammation of the deep iliac glands forms a clinical entity which has not received the attention it deserves. It is far from rare, and when right sided is often mistaken for acute appendicitis. Psoas spasm is a leading feature, particularly in the early stages of the disease. The patient lies with his leg drawn up

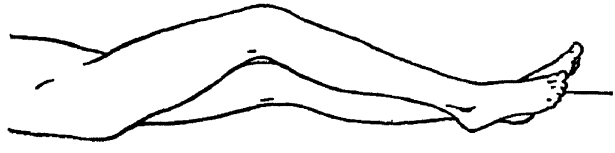

FIG. 315. — Psoas spasm. The hip joint is flexed. This is seen in suppurating iliac glands, hip-joint disease, and occasionally in appendicitis.

(fig. 315). Psoas spasm is seen occasionally in acute appendicitis and also in acute hip disease. As the rotatory movements of the hip joint are free, and there is tenderness

and often rigidity above Poupart's ligament, acute appendicitis is sometimes suspected. In three-quarters of all cases of suppurating deep iliac glands there is a demonstrable infective focus such as a scratch or a sore upon the lower limb of the affected side. Suppuration in these glands leads to an extraperitoneal abscess (fig. 316) which is opened by a suitable incision, meticulously avoiding the peritoneum.

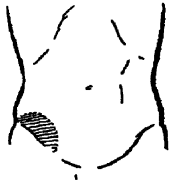

FIG. 316.—The usual situation of a lump connected with suppurating deep iliac glands.

(*e*) *Salpingitis.*—Unlike early acute appendicitis, early salpingitis is far better treated by non-operative measures. The history of a vaginal discharge, of menstrual irregularities and dysmenorrhœa, of burning on passing water, are all helpful differential diagnostic points. The tenderness in salpingitis is usually more medial than that found in acute appendicitis, and it is inclined to be bilateral (fig. 317). A vaginal examination often gives conclusive evidence of acute tubo-ovarian disease. A smear from the cervix uteri examined microscopically sometimes clinches the diagnosis. In a few cases the differential diagnosis is so difficult that it is wiser to explore the abdomen.

FIG. 317.—Typical distribution of abdominal tenderness in acute salpingitis.

3. **The Patient is suffering from some other Acute Abdominal Catastrophe normally requiring Abdominal Exploration.**—In acute abdominal cases it should be the clinician's highest aim to make a correct pre-operative diagnosis. Especially in examples of diffuse peritonitis, this ideal cannot always be attained, and so the appendix—the commonest source of acute intra-abdominal mischief—is sometimes

explored first and found to be innocent. The acute intra-abdominal catastrophes which are from time to time mistaken for acute appendicitis have been dealt with elsewhere, but this is a convenient place to describe shortly from the standpoint of a differential diagnosis some of those affections of the female internal generative organs which fall into this category but have so far not been considered.

(*a*) *Ectopic Gestation.*—It is unlikely that a *ruptured* ectopic pregnancy, with its well-defined signs of hæmoperitoneum, will be mistaken for acute appendicitis, but the same cannot be said for a right-sided tubal abortion, or more still for a right-sided unruptured tubal pregnancy. In the latter the signs are very similar to acute appendicitis, except that the pain *begins* in the right side and there is often a history of a missed period. In tubal abortion signs of intra-peritoneal hæmorrhage are likely to be manifest. When the internal bleeding has not been excessive the differential diagnosis between acute appendicitis and tubal abortion is not always simple, especially when the history of a missed period is lacking. The abdomen moves well on respiration, there is deep tenderness in the iliac fossa, but seldom rigidity. A vaginal examination reveals the cervix softer than usual, and all the fornices are tender; which is of considerable importance since in inflammatory conditions the tenderness is only posterior and lateral.

(*b*) *Ruptured lutein cyst* (*syn.* apoplectic ovary) occurs particularly during the spring months, and in early womanhood. The patient is usually unmarried, or recently married and childless. The signs are similar to those of very early tubal abortion, but of course the history of a missed period is absent, as also is the sign of a soft cervix. We have encountered nearly a score of these cases and so far have not yet made the correct pre-operative diagnosis with assurance. It is practically impossible to rule out the possibility of a mild acute appendicitis.

(*c*) *Twisted and ruptured ovarian cysts* also occasionally enter the field of differential diagnosis, but for a description

of these conditions the reader is referred to works on Gynæcology.

Complications of Acute Appendicitis

Peritonitis (Chapter XVII)
- Local.
- Diffuse
  - Diffuse pelvic.
  - Diffuse general.

Abscess formation.
Pylephlebitis—p. 251.
Intestinal obstruction—p. 340.
Purulent sinus.
Fæcal fistula—p. 323.
Thrombosis of the femoral and iliac veins.

Appendix Abscess

"An appendix abscess" signifies a localised abscess connected with a perforated or otherwise inflamed vermiform appendix. A subdiaphragmatic abscess or a pelvic abscess can arise from the same source, but these conditions are not usually categorised under this heading, and rightly so. The signs of an appendix abscess (fig. 318) are those of acute appendicitis plus the presence of a tender swelling. When a lump is present early in an attack of acute appendicitis it is probable that the bulk of the swelling is due to a mass of great omentum performing its constabulary duties (p. 301).

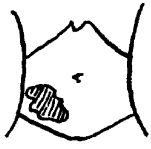

Fig. 318.—Physical signs recorded in a case of appendix abscess.

Treatment of Acute Appendicitis

The treatment of acute appendicitis is appendicectomy. If the diagnosis is made within 48 hours, all are agreed that the appendix should be removed urgently.

Appendicectomy.—A variety of incisions are practised, but the most popular are the gridiron and Battle's incision (fig. 319). Of the two we prefer the gridiron except in females, where the possibility of primary disease of the uterine adnexæ cannot be excluded.

The Gridiron Incision.—An incision about two inches long is made with its centre over McBurney's point (fig. 319), at right angles to McBurney's line. The external oblique is incised in the length of the incision. The fibres of the internal oblique and transversalis are separated, and after suitable retraction the peritoneum is opened.

FIG. 319.—1 Gridiron incision; 2. Battle's incision.

Battle's Incision.—The skin incision is shown in fig. 319. It is over the outer third of the sheath of the rectus, which is opened in the length of the incision. The rectus muscle is displaced medially, care being taken to avoid injury to the deep epigastric vessels. The posterior portion of the sheath and the peritoneum are then incised as one layer.

Removal of the Appendix.—We will assume that the abdomen has been opened by the gridiron incision. A retractor is placed under the medial side of the peritoneum and the abdominal wall is lifted up. This allows one to peer into the peritoneal cavity and to see the state of affairs before anything is disturbed. It is often possible to see the cæcum, and occasionally the appendix also. If pus or purulent fluid wells up a strip of gauze is packed under the peritoneum on the mesial side. The cæcum is withdrawn. Using a swab, the cæcum is pulled gently, and usually the appendix will come into view. The finger may be inserted into the wound to aid delivery of the appendix. Once the appendix has been delivered the cæcum is given to an assistant to hold He should be instructed to take a good grip and hold the slippery structure in a gauze swab. Morrant Baker forceps are applied around the appendix in such a way as to encircle the organ and yet not damage it (fig. 320). Clipping, then cutting, section by section, the mesoappendix is severed, until the base of the organ is reached. A long hæmostat is then applied to the base of the appendix. It is released, and applied again a few milli-

metres more distally. Around the crushed portion a ligature is applied, tied, and its ends cut short. A purse-string suture is inserted to encircle the caput cæci about half an inch from the appendix. This stitch passes through the muscular coat, particularly at the longitudinal bands. The purse-string having been inserted, it is momentarily left untied while the base of the appendix is severed between the hæmostat and the ligature. The free ends of the purse-string are held moderately taut whilst the appendicular stump is wiped with a gauze swab, which is promptly cast aside. The cut mucous membrane may be touched with pure carbolic. The appendix is now invaginated (fig. 321) with a small pair of smooth dissecting forceps and the purse-string is tied, burying the appendix stump. Attention is now directed to the ligaturing of the mesoappendix. For this purpose transfixion sutures are safe and cannot slip.



FIG. 320 —Appendicectomy. (Inset) Morrant Baker forceps in use. (From *Emergency Surgery*.)

Retrograde Appendicectomy.—In certain cases, especially when the appendix is retrocæcal and adherent, it is an advantage to commence by dividing the base of the organ. After the stump has been ligatured and invaginated the organ is removed from base to tip.

Drainage is seldom needed if the appendix is removed within

FIG. 321. — Appendicectomy. Inverting the stump of the appendix. (From *Emergency Surgery*.)

24 hours of the commencement of the attack. It is not often necessary even up to 48 hours, except in cases with frank peritonitis. The question of drainage has been dealt with in Chapter XVII.

If, for one reason or another, the diagnosis has not been made until the third or fourth day of the disease, and there is local peritonitis or an appendix abscess, opinion is divided as to the best course to adopt immediately. At the present time surgeons are divided into two schools.

The *immediate school* advocate removal of the appendix under all conditions just as soon as possible, irrespective of the time since the onset of the attack, although even disciples of this school often stipulate "unless the patient is recovering from the attack."

The *Ochsner-Sherren (delayed) school* teach that after the forty-eighth hour of attack of acute appendicitis primary thought should be given as to the advisability of an immediate operation. While being *prepared* to operate immediately, they institute a rigid non-operative regime and only operate if the signs point to a failure of Nature to combat the infection.

The Ochsner-Sherren (Delayed) Treatment of Late Acute Appendicitis.—The delayed treatment cannot be described in a few words, for not even ardent supporters of the Ochsner-Sherren school would attempt to deny that this treatment is open to abuse, and if abused would defeat the object of its inception, viz. to lower the high mortality of acute appendicitis.

The treatment is not merely a postponement of operation ; it is not just the old "interval appendicectomy" ; it is not a substitute for operation, but a preparation for it—essentially a surgeon's treatment, to be undertaken only in a surgical hospital, or a correspondingly equipped nursing home, with a nursing staff trained in the method. Above all, in a civilised country, the treatment must always be carried out on the very threshold of the operating theatre. As private houses are not thus equipped, it should be regarded as criminal to attempt the treatment in the patient's home. But one can picture circumstances—for instance, in a small ship at sea—where to attempt the treatment would be less dangerous, by reason of these circumstances, than to attempt operation.

SELECTING CASES FOR THE "DELAYED TREATMENT"

The history is taken, and particular note is made of the number of hours since the onset. The history begins "10, 26, 55 *hours* ago," not "last Thursday," or "three days ago." The physical signs are then recorded in diagrammatic form. The extent of the rigidity is marked by shading ; the presence of a lump is drawn as near as possible to scale. The presence or absence of hyperæsthesia is

always recorded, and the findings of a rectal examination are not omitted. It is necessary to include these particulars, for it is impossible to proceed without minute attention to detail, for fear of being misunderstood.

If the diagnosis of acute appendicitis is made and the history is of *under forty-eight hours' duration* immediate operation is nearly always advised. If the diagnosis of acute appendicitis is made and the history is *over fifty hours' duration* one should ask oneself the question, "Is there any reason why this appendix *should* be removed at once?" The answer by one trained in the delayed treatment is, "It is safer to postpone operation for the time being, unless . . ."

EXCEPTIONS TO THE RULE

1. Hyperæsthesia is present. Providing that the other signs are consistent this may be taken as good evidence that the appendix is still unperforated.

2. Age under 8 years.

3. The diagnosis cannot be made between acute appendicitis and some other intra-abdominal catastrophe normally requiring immediate operation—particularly perforated diverticulitis and perforated duodenal ulcer.

4. General peritonitis has supervened. Only cases which have obvious general, as opposed to pelvic, peritonitis are excepted.

5. The recent ingestion of a powerful purgative may be a justifiable indication for performing operation which otherwise would be delayed.

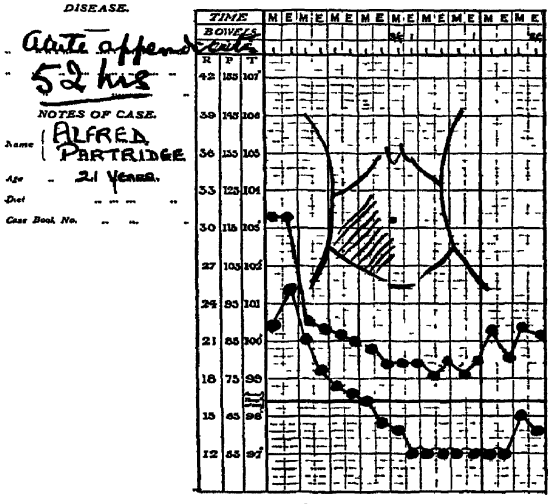

FIG. 322.—Chart of a case of acute appendicitis first seen 52 hours after the onset of the attack treated by the Ochsner-Sherren method.

Charts.—As a routine the pulse is recorded every two hours in graphic form on a special chart. In cases where anxiety is felt as to the advisability of continuing the treatment an hourly chart is employed. Temperature is relatively unimportant, and it is recorded every four hours. Instructions are given to the nurse to record any vomiting on a separate piece of paper, known as a "vomit chart." On this is entered the time at which the vomitus was ejected, together with the quantity and character of the fluid.

Diet.—Water only is given for four days, or occasionally longer. This is adhered to very strictly. The amount of plain cold water the patient may have is unlimited, although he is not encouraged to drink more than is necessary to satisfy his thirst.

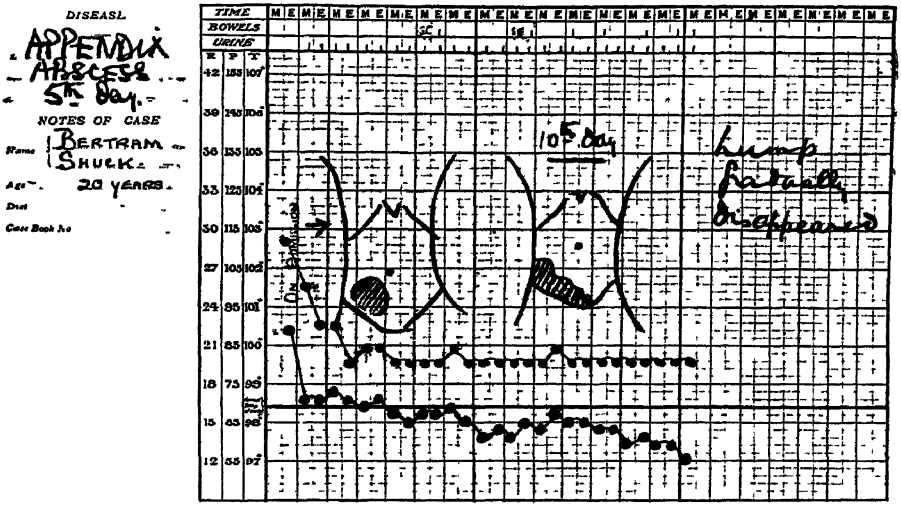

FIG. 323.—Chart of a patient with an appendix abscess treated by the Ochsner-Sherren method.

On the fifth day, if the pulse and temperature are satisfactory and the patient feels hungry, feeding is commenced. Small feeds of Benger's food, alternating with a cup of Bovril, are given. On the sixth day custard and jelly are allowed. After that the diet is gradually increased.

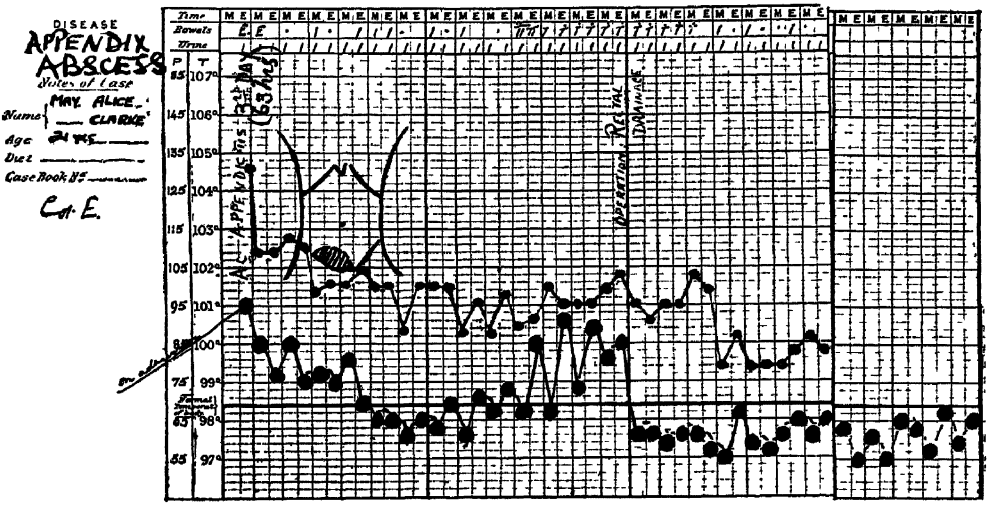

FIG. 324.—Chart of a patient with an appendix abscess treated by the Ochsner-Sherren method. In this case a pelvic abscess formed. The abscess was drained into the rectum.

Drugs.—All drugs are forbidden. It should be particularly noted that no morphine or its derivatives are given.

Pain, as opposed to tenderness, is very seldom complained of after the first night of the treatment. A hot bottle may be given to the patient to apply to the abdomen ; but it is well to repeat that as long as the inflamed appendix remains *in situ* drugs are forbidden, for they may mask those all-important signs which foretell that the delayed treatment is not likely to succeed.

Bowels.—The bowels are left confined if they are not opened naturally. On the fourth or fifth day a small glycerol enema is given. No purgatives of any kind are given until resolution is complete—that is, until the temperature and pulse have been normal for a week and pain and physical signs are absent—then liquid paraffin 2 drachms thrice daily, is prescribed.

WATCHING FOR NATURE'S FAILURE TO COMBAT THE INFECTION

Instructions are given for the nurse in charge to watch the patient and report immediately (1) a rising pulse-rate, (2) vomiting, (3) pain, and, in the later stages of the treatment, (4) diarrhœa or the passage of mucus in the stools (pelvic abscess).

A rising pulse-rate in the early stages is the most reliable single sign that it is dangerous to proceed with the delayed method. If the pulse-rate has increased even ten points in the first twenty-four hours, operation is often indicated.

Vomiting after the first few hours should always be regarded seriously, and this by itself may be a sufficient indication to abandon delayed treatment.

A patient undergoing delayed treatment should not complain of pain, as opposed to tenderness, after the first six hours of such treatment. If he does, usually there is something wrong, and this is a strong indication for operation.

THE OUTCOME

Under the delayed treatment most cases resolve without incident (fig. 323), and the appendix is duly removed after the acute stage has abated. In a few, where the signs point to failure of the delayed treatment, urgent appendicectomy must be undertaken.

The Treatment of Appendix Abscess.—The same controversy exists in the case of appendix abscess. The immediate school proclaim an old and usually wise surgical axiom—" where there is pus you must let it out." The delayed school state that the rule may be broken in the case of small and moderate-sized appendix abscesses, and the abscess should only be opened if it is getting larger or fails to resolve. They find that appendix abscesses often resolve completely under the Ochsner-Sherren regime, and when the time comes for the appendix to be removed (in about three months' time) there is usually a remarkable freedom from adhesions.

Opening an Appendix Abscess.—The swelling is palpated under the anæsthetic. A point is chosen about the centre of the swelling, but rather nearer the lateral than the medial aspect. A small incision is made ; small because it is naturally very prone to become infected, and there will be less of it to break down. The peritoneum is opened. More often than not, opening the peritoneum does not open the abscess. Every care should be taken to avoid breaking adhesions unnecessarily, especially on the medial side. The extremity of a length of gauze may be gently packed into the *mesial* part of the wound. The index finger is passed into the wound and very, very gently burrows laterally and backwards. In the case of a large abscess it is hardly a moment before the finger is felt to enter a large cavity. The finger is still kept *in situ* and acts as a bung to the flow of stinking pus until a tube can be passed into the abscess cavity. See also pelvic abscess, p. 290.

* * * * *

It has been considered advisable to include the following practical problem :

After an operation for acute appendicitis the condition of the patient is unsatisfactory. The temperature is swinging and the pulse is elevated—signs which foretell of pocketing of pus. How would you investigate the case ?

1. *Examine the scar or wound and the abdominal wall* for an abscess of the abdominal wall.
2. *Consider the possibility of a pelvic abscess* (p. 290).
3. *Palpate the left iliac fossa* for an abscess in this situation.
4. *Examine the loin* for a perinephric abscess (p. 470).
5. *Look at the legs*—to exclude the possibility of phlebitis.
6. *Examine the conjunctivæ for an icteric tinge and the liver for enlargement, and enquire if the patient has had rigors*—pylephlebitis.
7. *Examine the lungs*—pneumonia or empyema.
8. *Examine the urine for organisms* (pyelitis) and *the fæces for blood and pus* (proctitis or enteritis).
9. Lastly, *concentrate diagnostic endeavour upon the possibility of a subdiaphragmatic abscess* (p. 291).

Subacute Appendicitis

Subacute appendicitis is but a mild form of acute appendicitis, and requires no detailed consideration.

Recurrent Appendicitis

Appendicitis is notoriously recurrent. This is perhaps the commonest form of appendicitis—mild subacute attacks which are so often attributed to "biliousness" or a "chill on the liver." The attacks vary in intensity, and the majority of cases ultimately culminate in severe acute appendicitis. If careful histories are taken from patients with acute appendicitis, over two-thirds remember having milder but

similar attacks of pain. This bespeaks the importance of recurrent appendicitis as a precursor of the more serious lesion.

Chronic Appendicitis

One should be careful to distinguish recurrent from chronic appendicitis. Many cases called "chronic appendicitis" are typical examples of the recurrent form of the disease. Chronic appendicitis is a comparatively rare affection; it certainly exists, and its most typical symptoms are referred to the stomach and duodenum—appendicular dyspepsia (see p. 228).

Pathology.—Appendices removed from patients suffering from true appendicular dyspepsia usually show a characteristic macroscopical change. There is obliteration of the lumen commencing at the tip and spreading along the organ for a variable distance. The walls of the obliterated portion can be seen to be composed almost entirely of white fibrous tissue. In long-standing cases the greater part of the organ is attenuated from fibrous contracture. In a few cases the fibrous changes are seen in the proximal end, but this is more characteristic of the recurrent type of the disease.

Diagnosis is difficult. One should remember constantly that in chronic appendicitis there are often no signs in the right iliac fossa—only referred symptoms elsewhere. We should be watchful lest, perchance, we fall into a common error of classing as chronic appendicitis neurotic patients (usually female) with a ptosed, gurgling, and apparently tender cæcum. Removal of the appendix brings no permanent relief to the sufferer nor credit to the surgeon.

Radiology as an Aid to Diagnosis.—In the case of the vermiform appendix, radiology is not a great diagnostic aid. If the appendix cannot be visualised after an opaque meal it suggests that its lumen is obstructed. If it fills and empties, it is indicative that the organ is healthy—but as nobody can tell the length of a given appendix until the organ has been displayed, there must always be uncertainty in the radiological diagnosis of appendicitis.

Treatment.—A diseased vermiform appendix should always be removed.

ACTINOMYCOSIS OF THE RIGHT ILIAC FOSSA

It is impossible to state definitely if the infection begins in the appendix or in the cæcal wall. That the appendix is often the original focus is strongly suggested by the operative findings in type 1.

Type 1.—Appendicitis is diagnosed, and an inflamed appendix is removed. The wound continues to discharge for weeks or heals and then breaks down. A consultation is held; a wise clinician suggests the possibility of actinomycosis. After perhaps many examinations of the pus, sulphur granules are found.

Type 2.—A patient comes with a hard mass in the right iliac fossa. The difficulties in diagnosis from tuberculosis and carcinoma of the cæcum have been discussed on p. 319.

Treatment is to persevere with iodine in milk therapy as in other cases of actinomycosis, and to provide drainage when abscess formation occurs. Autogenous vaccines may also be tried. Except when the disease is recognised at an early stage, the prognosis is extremely poor. Multiple sinuses, pelvic abscess, and fæcal fistulæ are common complications. Sometimes the wounds heal, only to break down later—eventually the infection proves fatal in fully 80 per cent of cases.

VERMIFORM APPENDICULAR DIVERTICULOSIS

Diverticula of the appendix are not rare, and have been seen in otherwise diseased appendices. The diverticula (fig. 325) may be due to pressure in an obstructed organ, but in specimens we have examined the cause of the diverticulosis has not been apparent.



FIG. 325.—Appendicular diverticulosis.

CARCINOMA OF THE APPENDIX

Carcinoma of the vermiform appendix is found in 0·39 of all appendices removed. It is highly important to recognise two forms of the disease.

True carcinoma of the appendix usually occurs at the proximal end of the organ, and is intimately related to carcinoma of the cæcum (p. 328). When a carcinomatous mass has formed in the region of the caput cæci it is often impossible to state precisely where the growth originated, even after a careful pathological examination.

False Carcinoma of the Appendix (*syn.* Carcinoid Tumour of the Appendix; Argentaffin tumour).—False carcinoma of



FIG. 326.—Carcinoid tumour of the appendix. The solid bulbous end is characteristic. (After Lee Wilmott.)

the appendix always occurs at the tip, forming a solid bulbous extremity to the organ (fig. 326). This growth is usually found in young females, and when a pathological report of carcinoma is returned there is often much unnecessary anxiety. Carcinoid tumour of the appendix is entirely benign, and although difficult to distinguish from true carcinoma histologically, it does not give rise to metastases. The tumour occupies to-day the same position as a myeloma occupied a generation ago, when it was thought to be a sarcoma.

CHAPTER XXI

THE RECTUM AND ANAL CANAL

Examination of the Rectum

Digital examination of the rectum is invaluable, and should be performed as a routine in all cases where rectal disease is suspected. Examination by a speculum (figs. 327 and 328) is also of paramount importance, but only the anal canal and a small part of the lower rectum can be inspected with such instruments. A sigmoido-

Fig. 327.

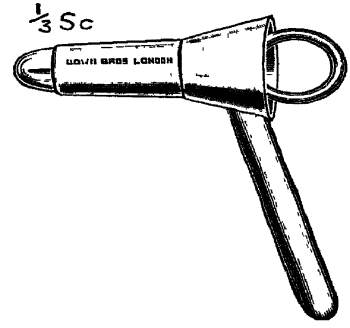

Fig. 328.

Rectal specula. The type shown in fig. 327 is valuable for use in the injection treatment of hæmorrhoids.

scope is necessary for the visualisation of the upper reaches of the rectum. By its aid, providing the rectum has been emptied by suitable preparation, the valves of Houston (fig. 329) are normally seen, and pathological conditions of the rectal wall are clearly apparent.



Fig. 329.—Houston's valves as seen through a sigmoidoscope.

ENEMATA

Among a large variety of enemata the following will be found to satisfy almost every requirement:

1. **Soap and water enema** is the one usually prescribed for general purposes.
2. **Turpentine enema** is similar to the above, but contains ʒi of oil of turpentine to the pint. A turpentine enema is

prescribed when the bowels have failed to act after a simple enema, and particularly in those cases where it is desired to expel flatus, as in post-operative distension.

3. **Glycerine Enema.**—Two ounces of warm glycerine are injected slowly into the rectum by means of a glass and vulcanite piston syringe. We prescribe this enema in those cases of pelvic and other forms of peritonitis where it is undesirable to disturb localising and reparative processes.

4. **Olive-oil enema** is occasionally useful for softening a mass of hard fæces.

5. **Nutrient Enema.**—Based on physiological knowledge, there are many who doubt the value of nutrient enemata. If such an enema is introduced into the empty colon, considerable antiperistalsis carries the fluid, at any rate as far as the cæcum. A nutrient enema given per rectum has been observed to flow out of an enterostomy wound, which conclusively demonstrates that antiperistalsis may carry nourishment to a portion of the intestine where it can be absorbed. A good nutrient enema is as follows: yolks of 2 eggs, 1 oz. of dextrose, 7½ gr. of common salt, pancreatised milk 10½ oz.

The Danger of the Rigid Nozzle.—It is desirable to call attention to faulty technique in the administration of enemata. Many cases have occurred, and not a few have been reported of a fatal issue, following penetration of the rectal wall by the bone nozzle of a Higginson's syringe. An inexperienced nurse and a patient with hæmorrhoids is the usual combination for this serious accident. A virulent peri-rectal cellulitis is very apt to follow. The prevention is simple. All enemata should be administered through a rubber catheter attached to the Higginson's or other syringe used for the purpose.

Embryology

Early in embryonic life there is a common chamber—the cloaca—into which open the hind gut and the allantois. The cloaca becomes separated into the bladder and post-allantoic gut (rectum) by the down-growth of a septum (fig. 330). About this time an epiblastic bud grows inwards towards the rectum. Normally, fusion between these

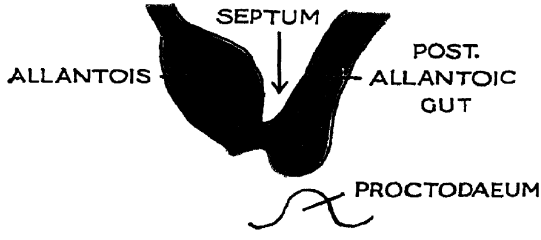

Fig. 330.

two structures occurs, and the point of fusion is marked in later life by the valves of Ball (fig. 331).

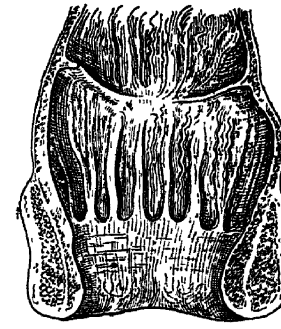

FIG. 331.—The anal canal showing the columns of Morgagni and the valves of Ball.

CONGENITAL ABNORMALITIES

(*a*) **Imperfections of the Development of the Proctodæum.**—The proctodæum can be totally absent, represented by a dimple, or separated from the rectum by a membrane only (fig. 332). The degree of development of the proctodæum is no indication of the degree of development of the rectum.

(*b*) **Imperfections in Development of the Post-allantoic Gut (Rectum).**—1. The post-allantoic gut may be entirely absent, the rectum ending blindly at the upper border of the vagina or prostate, to which it is attached by a fibrous cord (fig. 333).

2. The post-allantoic gut is but feebly developed, and there exists a considerable space between the proctodæum and its blind end (fig. 333).

(*c*) **Persistence of the Cloaca.**—*In the male* the fistula is most often at the verumontanum, but it may occur anywhere from the base of the bladder to the membranous urethra. *In the female* the fistula is most commonly found in the fossa navicularis, and it is sometimes associated with double vagina (failure of the Müllerian ducts to fuse). Persistence of the cloaca is usually associated with complete absence of the post-allantoic gut (fig. 334).

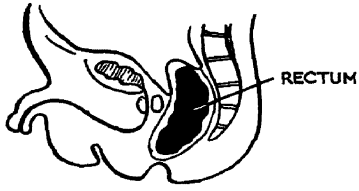

FIG. 332.—The proctodæum is separated from the rectum by a thin transverse septum.

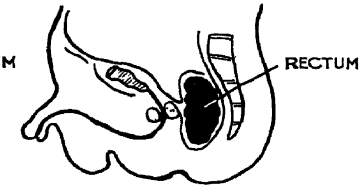

FIG. 333.—The post-allantoic gut is feebly developed and a considerable interval exists between its blind end and the surface.

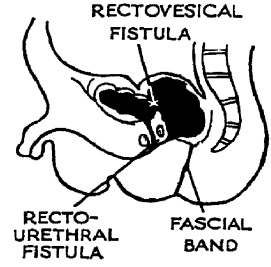

FIG. 334.—Absence of the post-allantoic gut associated with persistence of the cloaca.

IMPERFORATE ANUS

It is surprising how many cases are undetected until signs of intestinal obstruction are manifest. In settling

the important question as to which class of imperforate anus a case belongs (figs. 332, 333, 334), some help may be derived from watching and feeling the septum when the child cries. If there is a definite impulse, it is probable that the case is one of a simple septum (fig. 332). In cases of doubt an aspirating needle may be introduced ½ in. through the centre of the supposed anal site. If meconium is withdrawn, it is certain that the case is one of the simple variety, and all that is necessary is to incise the septum crucially, dilate with the finger, and unite the mucosa with a few interrupted sutures. In the more usual variety, where the rectum is not accessible, two courses are open :

FIG. 335.—Left inguinal colostomy in an infant with imperforate anus (type II). The child thrived.

1. An incision is made in the posterior part of the perinæum and a dissection is carried upwards until the rectum is found. The blind end is drawn down, sutured to the skin about the anus, and opened.

2. Left inguinal colostomy is performed. This is a less formidable procedure, and does not necessarily preclude the possibility of a plastic operation later in life. Unless there is evidence of an external sphincter, a left inguinal colostomy (fig. 335) is preferable to an incontinent anal orifice in the natural situation.

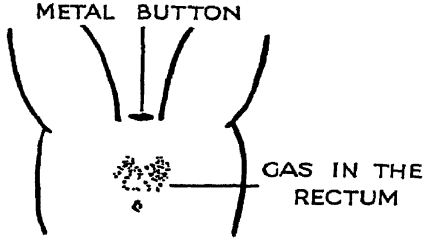

FIG. 336.—From an X-ray film (after Wangensteen).

A useful method of determining which course to pursue is as follows. The child is held upside-down ; the gas in the rectum will rise to the top, and indicate the distance between the rectal wall and the skin when an X-ray film has been made. A metal button placed over the site of the absent anus helps to clarify the film in this respect. Gas gives a dark shadow on the X-ray film (fig. 336).

The Fovea coccygea.—A little blind pit in the skin beneath the tip

of the coccyx is occasionally noticed in the course of a clinical examination. The extremity of this corresponds to the attachment of the caudal ligament to the skin.

Congenital Post-anal Fistula (*syn.* Pilonidal Fistula).—Congenital post-anal fistula is but a more obvious example of the above. When such a fistula discharges, it is probable that it is connected with a post-anal dermoid—and this can be suggested by a rectal examination and confirmed by injecting lipiodol along the sinus (fig. 337).

Post-anal Dermoid.—The space in front of the lower part of the sacrum and coccyx is occupied by a soft, cystic swelling—a post-anal dermoid cyst. These cysts are liable to become infected. If a sinus is present, or the inflamed cyst bursts or is incised, a troublesome form of blind external fistula-in-ano results. Treatment is complete excision of the cyst and sinus, if present. In large cysts it is sometimes necessary to remove the coccyx in order to gain space for dissection.



FIG. 337.—Post-anal dermoid cyst with coccygeal sinus Injected with lipiodol. Sinus and cyst excised.

PROLAPSE OF THE RECTUM

1. Incomplete (mucous membrane only).
2. Complete (all coats).

Prolapse of the rectum occurs usually at the extremes of life—in children and the aged.

INCOMPLETE PROLAPSE (*syn.* PROLAPSUS ANI)

Ætiology.—Children under 5 years of age are the usual sufferers. In adults mucosal prolapse is associated, as a rule, with hæmorrhoids, while in the aged, where the sphincters have become atrophic, it is again often encountered.

The exciting causes of prolapse in children are : 1. Wasting, which includes loss of the fat of the ischio-rectal fossæ.

2. Constipation and diarrhœa.
3. Any factor which produces increased intra-abdominal pressure, e.g. atresia meati with phimosis ; chronic cough, particularly whooping-cough.
4. Intestinal worms.
5. Rectal polypus.

Clinical Features.—The protrusion consists essentially of a fold of mucous membrane (fig. 338). Reduction occurs

spontaneously at first, but later the fold remains outside the anus for hours after defæcation. Rarely, the prolapsed mucosa becomes strangulated, but a common complication is secondary inflammation owing to irritation while it is exposed. Especially in the case of an infant, prolapse has been confounded with an intussusception protruding from the anus. Figs. 339 and 340 will make the differential diagnosis clear.

FIG. 338.—Prolapsus ani. (De Quervain).

Treatment.—In children a cure can often be effected by removing the cause, e.g. worms, phimosis, chronic cough, together with a suitable diet and proper regulation of the bowels. In early cases which do not readily yield to these measures the patient should be confined to bed. The bowels are emptied by a wash-out, while the patient is resting on his side. Following this a rectal douche of alum 10 gr. to the oz. is given after every motion. If the protrusion recurs in spite of this treatment, the mucosa must be digitally replaced by the nurse and the buttocks strapped together. A fattening diet and cod-liver oil are prescribed. In adults, removal of the hæmorrhoids usually brings about a cure. In the aged, the excision of three longitudinal strips of mucosa, as in the operation of clamp and suture for hæmorrhoids, is often effective. While the above measures are nearly always satisfactory, it must be emphasised that the first principle in the treatment of prolapse is *remove the cause.*

FIG. 339.—Prolapse.

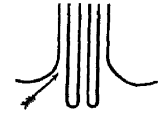

FIG. 340.—Intussusception protruding from the anus.

Complete Prolapse (*syn.* Prolapsus recti or Procidentia)

Compared with the foregoing, complete prolapse is infrequent. It is seldom observed in children, and is usually found in old women. In this form of prolapse all coats of the rectum are involved (fig. 341).

Ætiology.—While in the main the same ætiological factors enumerated previously are in evidence, the following causes are particularly associated with procidentia recti :

1. Partial or complete paralysis of the external sphincter from laceration at parturition, or lesions of the central nervous system, notably tabes.
2. Increased intra-abdominal pressure associated with enlarged prostate, urethral stricture, or an abdominal tumour.

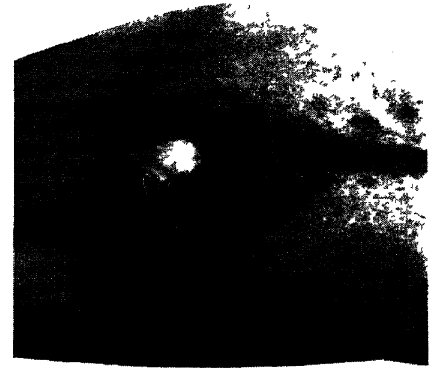

Fig. 341.—Complete prolapse of rectum and uterus.

Clinical Features.—The considerable prolapse, which is usually chronic, is evident on inspection. Unlike incomplete prolapse, it is possible to insinuate the finger into a groove between the anal margin and the prolapsed mucosa. Strangulation is very uncommon, because the sphincters are patulous.

Treatment.—Again the leading principle is to remove the cause ; however, this seldom brings about a cure, but it makes operative treatment worth while. There are numerous operative procedures advocated :

Linear Cauterisation.—Four or five lines are seared along the prolapsed portion with the cautery at a dull red heat. Care should be taken that the cautery does not penetrate the submucosa anteriorly, lest the pouch of Douglas be opened. After cauterisation the mass is reduced, and the anal orifice is narrowed by the excision of three longitudinal strips of mucosa, as was recommended for incomplete prolapse in the aged.

2. **Proctorrhaphy.**—Various plastic operations have been devised. One of the most popular is to make a transverse incision beneath the coccyx, to separate the tissues about the rectum from the coccyx and sacrum, and pack the cavity with gauze. The patient is kept in bed for a month, and the cavity is encouraged to fill and heal by granulation, the packing being changed at regular intervals.

3. **Colopexy of the Sigmoid.**—The abdomen is opened through a left paramedian incision, and the colon is hitched up by sutures to the peritoneum and muscles clothing the left iliac fossa.

4. **Excision of the prolapsed portion,** followed by restoration by suture of the continuity of the anal canal.

5. **Pararectal Injections of Irritating Substances.**—With a view to producing adhesions, which will prevent the rectal wall coming down, injections of alcohol or 1/2,000 solution of hydrochloric acid have been tried. The perirectal and submucous tissues are infiltrated with the solution. Using HCl, Haynes and others have had considerable success, even when operative measures have failed. The after-treatment, similar to that outlined for severe prolapse in children (p. 377), is all-important when this method is used.

Rectal Incontinence

Causes:

1. **Damage to the External Sphincter.**—Parturition, injuries, operation for fistula incorrectly performed.
2. **Lesions of the Central Nervous System.**
3. **As an accompaniment of Complete Prolapse.**
4. **Congenital absence of the External Sphincter.**

Treatment.—Rectal incontinence is a distressing condition. In cases where the trouble originates from a damaged external sphincter, many gratifying results accrue from plastic operations of that muscle. For example, we had a complete success by dissecting and uniting the anterior torn part of the sphincter in a woman who had had incontinence for twenty years following a difficult labour. It is remarkable how the external sphincter regains function when the continuity of even a portion of its torn and separated fibres is restored. When the sphincter is irreparably damaged, various plastic procedures have been attempted, with a varying degree of success, for details of which the reader must be referred to larger works on the subject.

In hopeless cases of rectal incontinence, a left inguinal colostomy is often preferable and more cleanly than an uncontrollable natural anus.

Injuries of the Rectum

1. **Impalement.**—The patient sits forcibly upon a somewhat spiked object which penetrates the rectum. The seriousness of this accident has been often overlooked. On superficial examination there is but a little blood about the anus, and too often it is not until general peritonitis has supervened that a penetration of the rectal wall into the peritoneum is discovered.

2. "**Split perinæum.**"—A lacerated wound of the perinæum, involving the anal canal, is becoming a frequent pillion-riding accident.

3. **Injury of the rectum caused by faulty administration of**

an enema has already been described in the section dealing with enemata (p. 373).

4. **Compressed air rupture** (p. 315).

Treatment.—If the rectum has been damaged the patient should be anæsthetised, and the rectum carefully examined with the finger and a speculum, special attention being directed to the anterior wall. All extensive wounds of the rectum require prolonged and certain drainage. This can only be effected by dividing the sphincter right back in the middle line to the coccyx. This, in addition, gives splendid access to the interior of the rectum for further exploration. If a laceration of the mucosa is found, its depth must be ascertained with the finger and by gently probing.

When the peritoneum has been penetrated laparotomy with suture of the perforation and drainage is urgently called for.

When the bladder has been penetrated cystostomy and transvesical suture of the perforation is the best treatment.

Foreign Bodies in the Rectum

The variety of foreign bodies which have found their way into the rectum is hardly less remarkable than the ingenuity displayed in their removal. A turnip has been delivered per anum by the use of obstetric forceps. A stick firmly impacted has been withdrawn by inserting a gimlet into its lower end. A tumbler, mouth looking downwards, has several times been extracted by filling the interior with a wet plaster of Paris bandage, leaving the end of the bandage extruding, and allowing the plaster to set.

If difficulty is experienced in grasping any foreign body in the rectum, recourse should be made early to a left lower laparotomy, which allows that object to be pushed from above into the waiting assistant's fingers in the rectum. If there is considerable laceration of the mucosa a temporary colostomy is advisable.

Inflammations (Ano-proctitis)

Inflammation of the anal canal and rectum can be acute or chronic. The causes are legion. Amongst them may be mentioned:

Traumatic.—From fæcal impaction; the abuse of enemata; foreign bodies.

Infectious.—The dysenteries, gonorrhœa, Ducrey's bacillus, and diphtheria, are amongst a number of possible specific infections.

Parasitic.—Thread-worms in childhood; bilharzia, especially in Egypt.

As a complication of other rectal conditions, notably hæmorrhoids.

Clinical Features.—The symptoms are burning, bearing-down pain, tenesmus, and a feeling of weight and fullness in the perineum.

There are often frequent watery stools of blood and mucus. In acute cases considerable fever and constitutional symptoms are usual. In all cases reflex irritation of the bladder is common.

On Examination.—Per rectum the examining finger detects a sensation of heat and the mucosa is exceedingly tender. With a speculum the inflamed mucosa, which bleeds readily, can be seen. Ulcerated areas are usual, and it is advisable to obtain a swab for bacteriological culture from the exudate in these areas.

Treatment.—The treatment naturally consists in removing the cause if possible. If the bacteriological examination reveals a specific organism, e.g. bacillary dysentery or diphtheria, the treatment will be largely medical.

The principles involved in inflammation of the rectum and anal canal are as follows :

General Treatment.—The patient is confined to bed on a slop diet. The pelvis is elevated to lessen pelvic congestion.

Local Treatment.—After an enema the mucosa is irrigated with a bland antiseptic, such as boric acid or mercurochrome, after which some demulcent solution, such as extract of hamamelis, containing 10 drops of laudanum, is instilled and retained as long as possible. In cases which do not respond to the usual measures, the interior of the rectum can be swabbed with a 2 per cent. solution of silver nitrate through a speculum, an anæsthetic being usually required. In cases where ano-proctitis is associated with colitis, recurrence is inevitable, unless the inflamed intestine above receives appropriate treatment (p. 315).

Round worms (*Ascaris lumbricoides and Oxyuris vermicularis*).—Irrigation with a solution of quassia kills the parasites in the lower bowel. Anthelmintics are necessary to rid the patient of parasites situated at a higher level.



Fig. 342.—Bilharzia papilloma (H. P. Keatinge, Cairo).

Bilharzia.—The rectum is the principal organ attacked by bilharzia. In Egypt, where the disease is endemic, bilharzia papillomatosis of the rectum is exceedingly frequent. The papillomata, which are sessile or pedunculated (fig. 342), contain the ova of the organism.

Untreated, the rectum becomes festooned, and prolapse of the diseased mucous membrane is usual. Multiple fistulæ-in-ano are prone to develop.

The **treatment** of bilharzia has been revolutionised by the introduction of tartar emetic therapy (p. 499). This has rendered the surgical removal of these masses unnecessary in most instances.

Ano-rectal Syphilis

Primary chancre of the anus is not a curiosity: returns from large venereal clinics show that, contrary to what might be expected, it is commoner in women. The lesion is usually situated in the posterior margin of the anus, and it simulates a fissure (fig. 343). Pain is not so much in evidence, and there is more discharge and more induration than in the case of a fissure. Much more rarely the sore is within the rectum itself. As a history of infection is always lacking, it is well to take a scraping from the base of indurated anal fissures of recent origin, and examine the pus by dark-ground illumination for the spirochæte.



Fig. 343.—Anal chancre.

Secondary manifestations take the form of mucous patches, and resemble those seen in the buccal cavity (p. 130). In the late secondary stages condylomata (fig. 344) are often seen in this region.

Tertiary lesions in the rectum are rare. *Gummata* (they are usually multiple) present the usual punched-out appearance of similar lesions elsewhere, but because of their rarity they are often mistaken for tuberculous ulcers, which are more common.

The ano-rectal syphiloma of Fournier is now seldom seen. There is great hypertrophy of the perianal tissues, and the whole ano-rectal canal is converted into a rigid tube. We have never met with this condition, which must be differentiated from actinomycosis and new-growth.

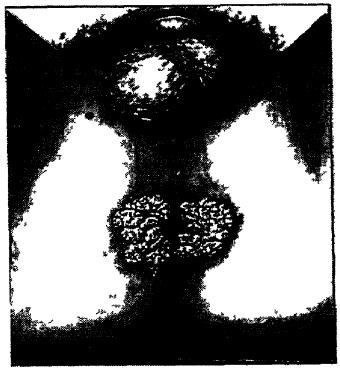

Fig. 344.—Condylomata ani.

Ano-rectal Tuberculosis

Tuberculosis cutis ani is occasionally primary, but more often secondary to tuberculosis elsewhere. The anal margin is the seat of ulceration. At first a single tuberculous ulcer, it later spreads, and in advanced cases the anus appears to open into the base of one large superficial ulcer.

Diagnosis.—Rests in finding the tubercle bacillus in scrapings from the ulcer.

Treatment.—Follows the usual lines for tuberculosis elsewhere. Local artificial sunlight is beneficial. In advanced cases cauterisation of the ulcer by heat is sometimes effective. In the worst cases colostomy should be performed in order to rest the inflamed area and prevent continual secondary infection.

Tuberculous Ulceration of the Rectum and Anal Canal.—Multiple tuberculous ulcers (fig. 345) are again usually secondary to tuberculous processes elsewhere. Often the colon is involved as well. The symptoms and signs are often similar to those of malignant

disease, and the final diagnosis can sometimes only be made with certainty by removing a portion of the ulcer for section.

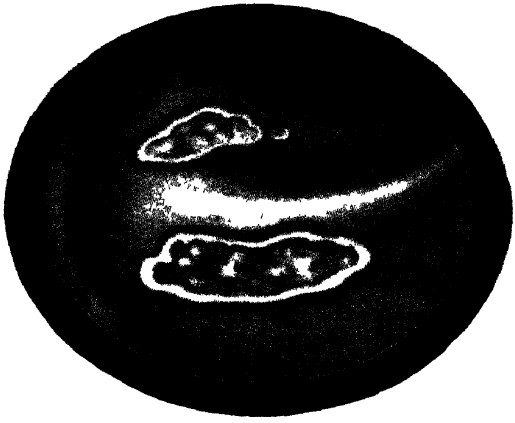

FIG. 345.—Tuberculous ulceration of the rectum. Sigmoidoscopic appearance.

Treatment is difficult. Colostomy affords the greatest relief, and by putting the rectum and anal canal at rest, gives the ulcers a chance to heal. In those rare cases of a solitary ulcer situated in the anal canal, excision of the mucous membrane after the manner of Whitehead's operation proved satisfactory in a case under our observation. In all instances general treatment of tuberculosis must be pushed to its uttermost limit.

CRYPTITIS

Between the columns of Morgagni are the valves of Ball, each forming a minute pocket opening upwards. By thorough proctoscopic examination obscure dull pain localised in the anal canal is sometimes traced to chronic infection in one or more of these crypts. Probably cryptitis is a frequent precursor of ischio-rectal abscess and fistula.

Treatment.—In mild cases applications of pure ichthyol on the point of a probe into the crypt usually brings about a cure. In cases where this treatment is not effective, the little pocket is ablated by a single cut and the wound is dressed regularly until healed.

ABSCESSES OF THE RECTUM (fig. 346)

1. **Perianal abscess** is the extension of a boil in the skin about the anus.

2. **Submucous abscess** generally follows small abrasions of the rectal mucosa. The symptoms are similar to those of ischio-rectal abscess.

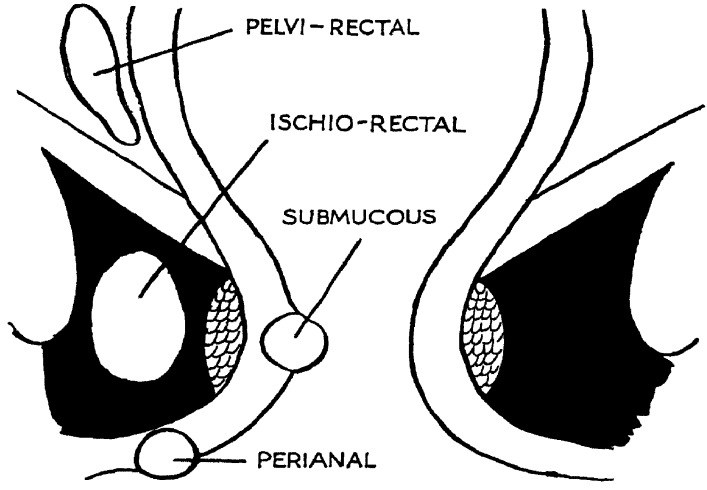

FIG. 346.—Abscesses about the rectum and anal canal.

3. **Ischio-rectal Abscess.**

ÆTIOLOGY.—Infection reaches the ischio-rectal fat by one of the following paths :

From the Floor.—Boils of the overlying skin.

From the Inner Wall.—Inflamed internal hæmorrhoids ; penetration of the rectal wall by a foreign body.

From the Front.—Periurethral abscess.

From the Outer Wall.—Pelvic disease.

CLINICAL FEATURES.—There is great pain, increased on defæcation. Reflex irritation of the bladder, and in severe cases even acute retention, is often noted.

FIG. 347.—Incision for draining an ischio-rectal abscess.

Treatment.—One should not wait until an ischio-rectal abscess points—it should be incised at the earliest possible moment. A brawny induration at the base of the ischio-rectal fossa is sufficient indication that an incision is necessary. Often there is a little redness of the skin at this stage. A cruciform incision (fig. 347) is made into the base of the ischio-rectal fossa. The edges of the incision are trimmed so as to allow the freest possible drainage, and a soft rubber tube is stitched into the wound. Antiseptic baths are begun twenty-four hours later. The tube is then removed, and as soon as the wound is clean, it is encouraged to granulate from the bottom. The early and effective drainage of an ischio-rectal abscess prevents the probable unpleasant sequel of a fistula-in-ano.

Tuberculous ischio-rectal abscess.—A chronic ischio-rectal abscess is sometimes caused by the tubercle bacillus. The origin of the infection has been shown to be often in the anal crypts.

The treatment is similar to the above, the only difference being that it is best to pack lightly the cavity with antiseptic gauze and to endeavour to prevent a secondary infection.

4. **Pelvi-rectal abscess** (see p. 387).

Fistula-in-ano

Definition.—Strictly, fistula-in-ano implies a suppurating tract connecting the mucous surface of the rectum or anal canal with that of the skin in the neighbourhood of the anus. Those "fistulæ" having but one orifice should be correctly known as sinuses—but the terms "blind external" and "blind internal" fistula are deep rooted, and as these terms convey a clear impression of what is meant, no useful purpose is served by departing from familiar terminology.

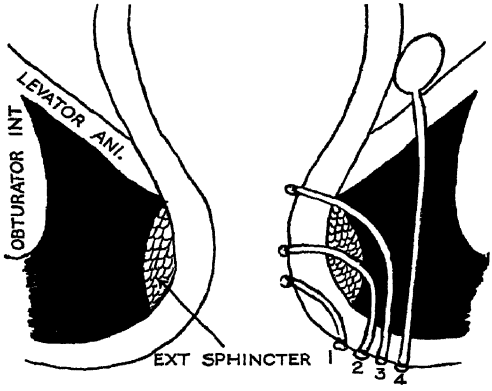

Fig. 348.—Varieties of fistula-in-ano:

1. Muco-cutaneous
2 and 3. Intermuscular.
4. Pelvi-rectal.

(1, 2, 3. Complete form shown. 4. Blind internal.)

Varieties (fig. 348)

			Approx.
Muco-cutaneous	Complete		70 per cent.
Intermuscular [1]	Incomplete	Blind external	20 per cent.
		Blind internal	9 per cent.
Supramuscular—nearly always blind internally			1 per cent.

Rarer, and complicated fistulæ

1. Horse-shoe, connecting the ischio-rectal fossa of each side.
2. "Watering-can" multiple external orifices.
3. Fistulæ connecting the rectum with other organs.
   - ♀ Recto-vaginal
     - Congenital.
     - Following difficult labour.
   - ♂ Recto-urethral
     - Congenital.
     - As complication of
       - Urethral fistula.
       - Periurethral abscess.
       - Prostatectomy.
       - Malignant ulceration.
   - ♀ and ♂ Recto-vesical (see p. 489).

[1] Inter = between. But there are really two varieties of intermuscular fistulæ, one which is between the muscle fibres of the external sphincter, which is common, and one between the external and internal (levator ani) muscles themselves, which is comparatively rare. Each of these is illustrated in fig. 348.

Ætiology.—Submucous, intramuscular, and intermuscular fistulae.—Fistulæ-in-ano of the usual varieties are almost invariably due to a neglected or poorly drained ischio-rectal abscess. If perianal and ischio-rectal abscesses were treated early and thoroughly, fistula-in-ano, which is very common, would be a rare condition.

Pelvi-rectal fistula is exceedingly unlikely to arise from, or in any way communicate with, the rectum. The common causes of this condition are an abscess connected with :

1. Uterus or Fallopian tubes.
2. The bladder or prostate.
3. The appendix.
4. Psoas abscess.

An injection of lipiodol prior to an X-ray is helpful in eliciting the cause.

Multiple external fistulæ suggest tuberculosis, but are occasionally associated with carcinomatous or other strictures of the rectum, the internal orifice of the fistula being situated in the ulcerative area above the stricture. Multiple external fistulæ are a common complication of bilharziasis of the rectum.

Other Unusual Cases of Fistula-in-ano.—Exceptionally, fistulæ about the anus arise from bone disease. We have seen an example where the origin was necrosis of the tuber ischii. Another possible source of fistula in this region is a periurethral abscess—but, again, this is exceedingly unusual. A fistula connected with a post-anal dermoid has been mentioned (p. 377).

Pathology.—In most cases the tract is lined with typical granulation tissue. Repeated and painstaking observations have disproved the popular conception that most fistulæ are tuberculous ; indeed, Gabriel has shown that fully 80 per cent. of fistulæ-in-ano are definitely non-tuberculous.

Clinical Features.—There is a constant purulent discharge, which irritates the skin in the neighbourhood and causes discomfort. Pain is not a prominent symptom so long as the fistula drains perfectly. Recurrent abscess formation, due to the fistula becoming blocked, is a common complication. A fæcal leak occurs through a complete fistula when the motions are liquid.

Diagnosis.—Fistulæ with an external orifice can hardly be mistaken, but it is less easy to prove or disprove that such

a fistula has an internal opening. The internal orifice of a complete fistula can sometimes be felt as an indurated elevation on the lateral wall of the rectum about 1 in. from the anal verge.

A valuable method of investigating the presence and location of an internal opening is to introduce a rectal speculum, and then inject, by means of a syringe, a solution consisting of 2 parts of methylene blue and 1 part of hydrogen peroxide into the external opening. The flow of coloured fluid down the speculum at once settles the fact that the fistula is complete ; moreover, the hole from which colouring

FIG. 349.—A director with a probe-pointed malleable extremity. A useful instrument for treating fistulæ.

matter is flowing can actually be seen. In complicated cases, and in the blind external variety, injection of 10 per cent. of bismuth paste or lipiodol prior to a radiograph is helpful ; stereoscopic pictures are particularly helpful.

Treatment.—Spontaneous healing is so infrequent that operative treatment should be undertaken in all cases.

Pre-operative Treatment.—The bowels should be evacuated thoroughly, the colon being washed out on three days prior to the proposed operation. During this time the fistula is syringed through with hydrogen peroxide and mild antiseptics, and the patient should have an antiseptic bath night and morning.

There are several operative measures which may be employed :

1. **Laying open the fistula** is the most general method of treatment, and in most cases it is eminently satisfactory. A director (fig. 349) is passed along the fistula (fig. 350) and the tract is laid open. As the majority of fistulæ are muco-cutaneous or intramuscular, at the most only a portion of the external sphincter is divided and incontinence does not follow. Even when the whole of the external sphincter has been severed at one point, as will be the case in the treatment of intermuscular fistula, the patient regains complete sphincteric control,

FIG. 350.—Laying open the fistula. The director in position.

providing the sphincter is sectioned transversally across its fibres, and not obliquely (figs. 351 and 352). The oblique section frequently results in partial incontinence.

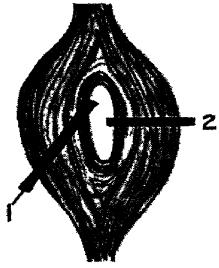

FIG. 351.—(1) Oblique section of the external sphincter can result in incontinence. (2) Transverse section at one point is never followed by this unfortunate sequel.

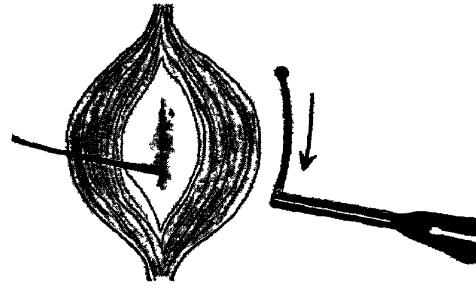

FIG. 352.—In order to ensure that the sphincter is cut across at right angles it is sometimes necessary to enlarge the externa orifice in such a manner as to bring the director at right angles to the muscular fibres.

After-treatment is highly important. A small tube is placed through the anus, to allow the passage of flatus, the wound is lightly packed with strip gauze moistened with liquid paraffin, and over all a T-shaped bandage is applied. The external dressings are changed when soiled, but the packing is left *in situ* until the fourth day, when an enema is administered through the tube. With a view to keeping the bowels confined, during the first four days very little food is given by mouth. Morphia or tinct. opii is prescribed in suitable doses with the same object in view; this also relieves pain. After the bowels have opened the patient is given an ordinary diet and liquid paraffin at night. From the fourth day onwards the patient sits for half an hour in an antiseptic hip-bath, after which the wound is repacked. In this way the wound is encouraged to heal by granulation from the bottom. In the later stages of treatment red lotion is a useful dressing. If the after-treatment is carried out with care, recurrence is very unusual. On the other hand, careless after-treatment, which permits the top of the wound to heal before the granulations have filled the cavity, leaves the patient with what may be a larger fistula than before.

2. **Excision** (*syn.* **Fistulectomy**).—A malleable probe or piece of silver wire is passed along the fistula, which is then excised in the manner shown in fig. 353. This leaves a larger, but a cleaner, wound than method 1. Fistulectomy

is particularly suited to the more superficial varieties of fistula. On rare occasions the wound may be sutured, but as a rule the after-treatment is similar to the above.

FIG. 353.—Fistulectomy.

3. **The Seton.**—A modified form of this ancient method is occasionally resorted to in the case of a fistula with its internal orifice above the internal sphincter (levator ani), for if such fistulæ are treated by the usual methods fæcal incontinence would probably result. By cutting through the tissues slowly, which is what the seton accomplishes, the chance of incontinence is minimised. Great pain was one of the many disadvantages of the cure of fistula by the seton. This is overcome by infiltrating the tissues about the fistula and especially the subcutis with a 1 : 300 solution of quinine urea hydrochloride, which exerts prolonged anæsthesia. The best material for the ligature is a small solid cord of rubber, which is passed along the fistula, and then tied fairly tightly in the manner shown in fig. 354. About 10 days are required for the seton to cut through. The resulting wound is treated in the same manner as for other fistulæ, and encouraged to heal from the bottom.

Treatment of Blind External Fistulæ.—Recent fistulæ of this type heal readily if the external opening is enlarged and any side-tracks opened up, but the same careful after-treatment as insisted upon previously is necessary for a successful issue. Recurrent cases probably have a minute internal orifice which has escaped notice. They are therefore often complete fistulæ, and should be treated as such.

FIG. 354.—Rubber cord seton *in situ* in a case of high fistula-in-ano. By gradually cutting through the mass of tissue included in the ligature the possibility of incontinence is minimised (after Yeomans).

Treatment of Blind Internal Fistulæ.—The principle is to convert the blind internal fistula into a complete fistula. By means of a speculum the orifice is found and a probe inserted down the fistula, until the probe point is felt or seen beneath the skin, which is perforated deliberately. Thereafter the operation is as for a complete fistula.

Treatment of a Fistula with Multiple Openings.—The usual method of procedure is to unite all external openings, and then pass the probe director through the internal orifice and lay open the tract. On no account must the external sphincter be divided at more than one point, and then only at right angles to its fibres.

Treatment of Tuberculous Fistula.—Patients with active tuberculous lesions elsewhere require exceedingly careful treatment. It is often advisable to postpone operation until the general health has been built up. In general, the use of the cautery instead of the knife is preferable, but in other respects the operative treatment is identical with the non-tuberculous fistula.

Anal Fissure (*syn.* Fissure-in-ano)

Definition.—An elongated ulcer in the long axis of the anal canal.

Ætiology and Pathology.—The fissure is an aftermath of constipation, the mucosa being injured by a scybalous mass. An anal fissure presents itself as a small, triangular ulcer, base downwards (fig. 355), and it is nearly always solitary. It is seldom seen on the lateral walls of the anus; in the majority of instances the fissure occupies the median plane posteriorly, and it rarely extends upwards beyond the white line of Hilton. An anterior fissure is relatively common in females.

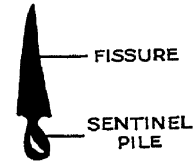

Fig. 355.

The Valve Theory.—A scybalous mass impinges upon one of the valves between the columns of Morgagni and tears it down (fig. 356), leaving behind a raw area, to the inferior end of which is attached a pyriform fleshy tag, which metaphorically guards the fissure like a sentinel. This is Ball's explanation, and it is probably the correct one in many instances. It is a theory which accounts for the common association of a fissure and a "sentinel pile" (p. 396).

Fig. 356.—Anal fissure resulting from tearing of a valve of Ball.

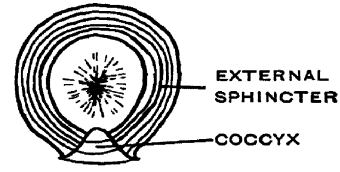

Fig. 357.—Showing why the perianal tissues are relatively unsupported by muscle posteriorly.

The Mucosal-stretching Theory.—The external sphincter muscle, attached as it is to the coccyx, leaves the posterior portion of the anal mucosa poorly supported by muscle (fig. 357). When the anus is overstretched by a fæcal mass this is the first portion of mucosa to

tear. In the female, owing to trauma at parturition, the anterior anal mucosa may be left with little muscular support—a possible explanation of the anterior fissure found almost exclusively in women.

Once an anal fissure is present it seldom heals without surgical aid because :

1. The sphincter is always in action, and consequently the ulcer is never accorded that essential factor for spontaneous healing—rest.

2. It is constantly further aggravated by the patient postponing defæcation because of pain. The vicious circle (fig. 358) has set in. Multiple fissures, especially in children, suggest syphilis.

Clinical Features.—Anal fissure is found usually in adults ; it is rare in childhood and uncommon in the aged. Men and women are about equally affected.

Pain is *the* symptom—sharp agonising pain during defæcation, and lasting sometimes hours afterwards. The deeper the fissure the longer does the excruciating pain continue. As a rule it ceases suddenly, and the sufferer is comfortable until the next action of the bowel occurs. Reflex pain down the thighs simulating sciatica sometimes occurs. In extreme cases reflex frequency of urine is not unusual.

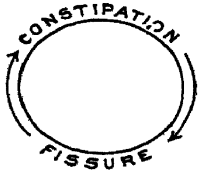

FIG. 358.

Stools are sometimes streaked with blood. In well-established cases of fissure they are said to possess a characteristic shape, and are flattened, short, with a " nipped-off " appearance, caused by sudden muscular spasms.

On examination a sentinel pile can sometimes be seen. In a few cases there is a small discharge of pus. The sphincter is tightly contracted. A tightly closed puckered anus confirms the diagnosis in cases with a typical history. Rectal examination is often impossible, because insertion of the finger causes the patient agony. Such an examination should be postponed until the time of the operation, when the characteristic crack which feels " like a button-hole " can be felt.

Treatment.—The pain of anal fissure is so great that usually the patient demands early relief.

1. *Dilatation.*—Thorough stretching of the external sphincter with the index fingers under general or spinal anæsthesia has, in our experience, been an entirely satisfactory form of treatment. The dilatation should be performed slowly, taking fully five minutes, and a successful divulsion leaves the anus patulous with a tendency for the mucosa to pout. This temporarily (two to three days) paralyses the sphincter, and allows the fissure to heal. At the same time the sentinel pile, if present, is snipped away.

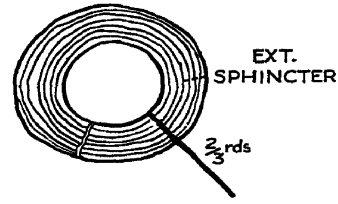

FIG. 359.

2. *Division of the Sphincter and Excision of the Fissure.*—Local anæsthesia is sufficient. The finger is inserted into the anal canal, and the interval between the external and the internal sphincters is sought. The external sphincter is then pressed outwards, and its now protruding fibres are incised cleanly at one point. This point can be through the base of the fissure, or perhaps, even better, to one side of it. The latter allows the fissure to be clearly excised, together with its sentinel pile. In any case, the skin incision should be about twice the length of the anal portion of the incision (fig. 359). A simple dressing is applied. Sitz baths are ordered. The patient can usually leave hospital on the fourth or fifth day, but must continue to attend for dressings until the wound has healed.

THE INJECTION TREATMENT OF FISSURE

A.B.A. (anæsthesin and benzyl alcohol in oil) is used. The first step is to inject some novocaine hypodermically, in order to alleviate the pain which A.B.A. causes for a few hours. For the A.B.A. injection a wide-bore needle is inserted into the subcutaneous tissues 1 in. below the fissure. The area injected is fan-shaped, and extends at least ½ in. on either side of the fissure, and also below its base. Some of the injection is instilled into the sphincter, the deeper parts of the injection being controlled by a finger in the anus.

The results are stated to be satisfactory and permanent (Dunbar).

Pruritus Ani

There is an intractable itching round the anus, which in severe cases almost dements the patient.

Treatment.—In a certain number of cases there is a definite cause, such as internal hæmorrhoids, which causes an excessive secretion of mucus. By removing the cause in early cases the condition clears up. In intractable cases the cure is most difficult. The number of divergent treatments which have been employed, and which are alleged to have cured individual cases, are extraordinary. Among them may be mentioned exposure to X-rays, autogenous vaccine of the *B. fœcalis*, injection of local anæsthetics, and innumerable analgesic salves. After all these treatments relapses are common, and it is in cases such as these that undermining the skin in the manner shown in fig. 360, whereby the cutaneous nerves are severed, a principle first recommended by Sir Charles Ball, has proved successful. Even after this operation, performed thoroughly, relapses sometimes occur.

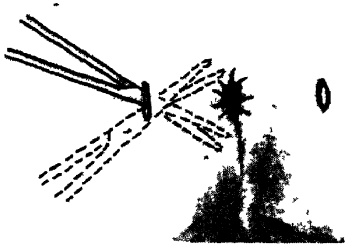

Fig. 360.—Undercutting the perianal skin so as to sever all cutaneous nerves.

HÆMORRHOIDS

Piles may be **external** or **internal**—external or internal to the external sphincter. The external varieties are covered by skin, while the internal are clothed by mucous membrane. When internal piles have prolapsed and remained outside for months, the covering mucous membrane becomes changed, and assumes the characteristics of stratified squamous epithelium. Such piles are sometimes known as **intero-external.**

All hæmorrhoids are again divided into two great classes —**primary** and **secondary**. By secondary is meant that the free venous return from the hæmorrhoidal plexus is interfered with. Pre-eminent among the causes of this venous obstruction are portal congestion (e.g. alcoholic hepatic

cirrhosis), and the presence of a pelvic tumour, notably a pregnant uterus. So often is the last-named a cause of transient hæmorrhoids that the term **pregnancy piles** is accepted as denoting a common clinical entity. The remarks which follow concern primary hæmorrhoids.

Ætiology.—Just as varicose veins of the extremity are the result of some inherent weakness of the walls of the branches of the saphena or an innocent neoplastic formation in these venous radicals, so probably many, or most, cases of primary hæmorrhoids are due to a hæmangiomatous multiplication and dilatation of the hæmorrhoidal plexus.

Accessory Factors in the Production of Hæmorrhoids

1. Hæmorrhoids are rarely found in horses and dogs; it is possible that they are one of the many penalties of man's adoption of the upright position.

2. There are no valves in the veins of the portal system.

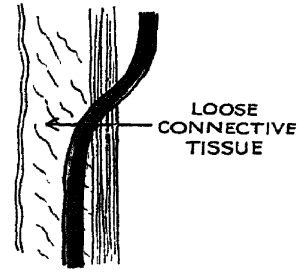

Fig. 361.

3. The superior hæmorrhoidal vein passes through the muscle coats of the rectum. It is liable to be compressed during rectal muscular contracture. Furthermore, distal to this point of possible obstruction, the hæmorrhoidal veins lie unsupported in loose submucous connective tissue (fig. 361).

4. Chronic constipation and the consequent straining at stool raises intravenous pressure.

Pathology.—In the early stages there is merely an engorgement of the column of Morgagni. Later, in addition to the congestion, the veins become permanently dilated and sacculated. About this stage there is also an actual multiplication of the veins of the region. Still later the walls of the veins become degenerate, the pars media being maximally affected.

Entering the upper level of the pile is a terminal branch of the superior hæmorrhoidal artery. Very occasionally there is a hæmangiomatous condition of the artery—"an arterial pile."

External Hæmorrhoids

External hæmorrhoids are a conglomerate group of conditions:

1. **Dilatation of the Veins of the Anal Verge.**—These are only evident if the patient strains, when a bluish cushion-like ring appears. This variety of external hæmorrhoid is almost a perquisite of those who lead a sedentary life.

FIG. 362.—Sentinel pile associated with fissure.

2. "**Cutaneous piles**" are redundant folds of skin about the anal margin.

3. "**Sentinel pile**" (fig. 362) is associated with fissure-in-ano (p. 391).

4. **Thrombotic pile** (fig. 363).—The term is a poor one, for a thrombotic pile is not due to thrombosis, but to the bursting of an anal venule, and it looks like an over-ripe cherry. In truth, it is a small hæmatoma in the perianal connective tissue which comes suddenly and is very painful.

Untreated, a thrombotic pile may:
- Resolve.
- Suppurate.
- Fibrose, and give rise to a cutaneous tag.
- Burst and extrude the clot.



FIG. 363.—"Thrombotic" pile.

Treatment of External Hæmorrhoids.—1. The first variety of external hæmorrhoids requires only an adjustment in the diet and habits of the patient.

2. "Cutaneous pile," if troublesome, can be snipped away with scissors under local anæsthesia.

3. "Sentinel pile" should be removed in conjunction with the treatment of the associated anal fissure.

4. Thrombotic pile is best treated as an emergency. A small incision is all that is required to evacuate the clot, when healing readily occurs with a dry dressing. If first seen after several days, applications of lead lotion are soothing, and absorption of the clot must be awaited.

INTERNAL HÆMORRHOIDS

Internal hæmorrhoids are exceedingly common—so common that sometimes a hasty conclusion is arrived at, and

more serious conditions are overlooked for want of thorough examination. Fig. 364 is a corrective in this respect.

Bleeding, as the name hæmorrhoids implies, is the principal and earliest symptom. At first the bleeding is slight, but in time often becomes considerable. This continual loss of blood oft-times renders the patient severely anæmic.

Protrusion is a much later symptom. In the beginning the protrusion is slight, occurs only at stool, and reduction is spontaneous. In time the protrusion is a cause of great discomfort. When a patient speaks of " an attack of piles " he usually means that the protruded membrane becomes nipped by the external sphincter, rendering the return of the protruding mucous membrane difficult.



FIG. 364.—Carcinoma of the rectum associated with hæmorrhoids. A diagnostic *pons asinorum.*[1]

Pain is usually absent. There is often a feeling of fullness in the rectum, especially after defæcation —a feeling as though the rectum had not been emptied completely.

Pruritus.—A mild itching of the perianal skin is a usual accompaniment of internal hæmorrhoids, and is no doubt due to an excessive moisture consequent upon the flow of secretion from the œdematous engorged mucous membrane.

Physical Signs.—In early cases of internal hæmorrhoids there is nothing to be made out upon digital examination. Nevertheless, this examination should never be omitted. If the buttocks are held apart, and the anus inspected while the patient bears down a little, gentle manipulation of the anal verge brings internal hæmorrhoids into view. In cases where this method fails, examination with a proctoscope will confirm or disprove the presence of internal piles.

[1] Another *pons asinorum* of a rectal examination is the mistaking of a normal cervix uteri for a rectal neoplasm.

The complications of hæmorrhoids are numerous, and important ; indeed, many, if not most, of the symptoms are strictly due to complications.

Complications of Internal Hæmorrhoids

1. Excessive hæmorrhage. Usually venous ; occasionally arterial.
2. Prolapse < Acute = strangulation. / Chronic = intero-external hæmorrhoids.
3. Thrombosis.
4. Inflammation.
5. Pruritus.

Some of these need detailed consideration.

FIG. 365.—Strangulated internal hæmorrhoids.

Prolapsed, Strangulated Hæmorrhoids.—The patient has a mass of prolapsed internal hæmorrhoids, blue, and often bleeding. He states that for a long time the piles have come down after defæcation, but on the last occasion he was unable to get them back (fig. 365).

Treatment.—A hot bath is ordered, after which the patient goes to bed. The foot of the bed is raised on blocks, and he is given an injection of morphia. A quantity of gauze soaked in normal saline is applied to the anus, covered with jaconet, and kept in position by a four-tailed bandage. The dressing is changed every four hours. Under this treatment the mass gets gradually smaller. The bowels are opened by an enema on the fourth day. By the end of the week the piles are barely visible. After suitable preparation, removal of the hæmorrhoids is then undertaken. In early cases of strangulation, that is, within the first twelve hours, it is sometimes advisable to anæsthetise the patient, stretch the sphincter, and return the hæmorrhoids. Never is it justifiable to remove hæmorrhoids in the acute stage, for pylephlebitis is a well-known aftermath of the precipitate removal of strangulated piles, which are always more or less inflamed. A large experience of the former method has proved entirely satisfactory, and saves the patient having two anæsthetics.

Thrombosis gives rise to no particular train of symptoms, but it is liable to follow strangulation. Old-standing thrombosed hæmorrhoids are confused occasionally with carcinoma of the rectum. They produce a hardened elevation upon the rectal wall, which in some respects simulates a new growth.

Inflammation and prolapse usually go hand in hand, the former

following the latter. The inflammation can culminate in suppuration, when pylephlebitis is a possible and grave complication.

Treatment of Internal Hæmorrhoids

Treatment by Injection.—Fully 85 per cent. of cases of internal hæmorrhoids can be treated satisfactorily by injection. The great advantage of this treatment is that it is entirely ambulatory, and there is no need for the patient to leave his work. The injection of hæmorrhoids has superseded operation as a routine method, although operation is still indicated in a minority of cases.

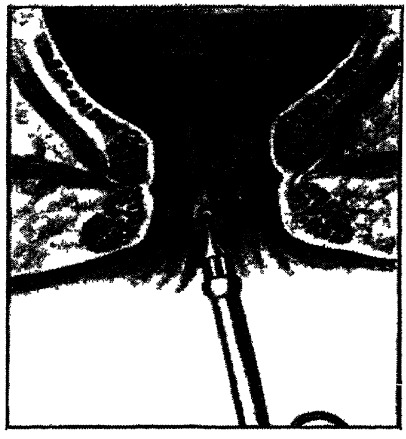

FIG. 366.—Showing injection of internal hæmorrhoids.

Technique.—The patient should have an empty rectum, but no special preparation is necessary. A speculum is introduced, and the piles are displayed. Into the base of each hæmorrhoid 5 minims of a 20 per cent. solution of phenol in extract hamamelis is injected (fig. 366) by means of a hypodermic, or preferably a special, syringe (fig. 367). In using this solution not more than 15 minims are used at any one sitting,

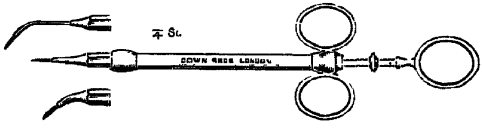

FIG. 367.—Mummery's syringe for injecting hæmorrhoids.

so that on an average three principal hæmorrhoids are injected at each treatment. Soon after the injection the pile swells, and there is a little bleeding from the point of puncture, which soon ceases. The injection is quite painless, and there is no special after-treatment. The only danger is the possibility of prolapse of the swollen pile. Piles should never be injected when they are outside the external sphincter, but temporarily prolapsed piles can be replaced and then injected. As a routine we strap the buttocks together with broad adhesive plaster after the injection, and tell the

patient to keep the strapping on until the next action of the bowels. Four, five, and six injections at weekly intervals are required in the average case. There is a host of formulæ for sclerosing solutions, and there is a tendency at present to use a larger quantity of a weaker solution of carbolic acid. We have employed the method detailed in an extensive series of cases, and found it entirely satisfactory.

Treatment by Operation.—It should be noted that external piles are entirely unsuitable for treatment by injection. If such treatment is attempted the pain is excruciating, whereas the injection of internal hæmorrhoids is an entirely painless process. Chronically prolapsed piles (intero-external hæmorrhoids) are better treated by operation. We also generally recommend operation in cases of internal hæmorrhoids which have strangulated. When an operation is necessary because of external hæmorrhoids it is convenient to remove internal hæmorrhoids as well. This applies also to cases of internal hæmorrhoids complicated by fissure or fistula. Of the many varieties of operations for internal hæmorrhoids, clamp and suture is rightly the most popular. The clamp is applied in the long axis of the gut, the portion of the hæmorrhoid distal to the clamp is cut off, and the gut edges sutured in the manner shown in fig. 368. When all the piles have been removed a morphia suppository is inserted into the rectum, and a tube round which has been wound a length of gauze soaked in liquid paraffin is inserted into the anal canal. This allows the passage of flatus, and should any bleeding occur the hæmorrhage would be noticed in the dressing instead of possibly being concealed in the rectum and colon.



FIG. 368.—Clamp and suture.

The operation can be carried out very efficiently under low spinal anæsthesia, using a comparatively small dose of anæsthesia : ·5 c.c. of stovaine in saline is injected into the theca between the fourth and fifth lumbar vertebræ. The

patient then sits up for a minute to allow the solution to diffuse, after which there is perfect anæsthesia of the anus and perineum.

Other Operative Methods

Simple Ligature.—The base of the pile is constricted by a ligature. The process of waiting for the necrotic pile to drop off is painful and olfactorily unpleasant.

Clamp and Cautery.—A special clamp is applied, and the pile is cut off with a cautery. This is still a popular method with a few surgeons.

Whitehead's operation is excision of the pile-bearing area. It is not often performed to-day. Simple stricture of the rectum is prone to follow an inaccurately performed operation of this type.

Stricture of the Rectum

Causes.—1. *Congenital.*—An incomplete septum at the point of union of the hind gut with the proctodæum.

2. *Inflammatory.*—As a sequel of proctitis or following pelvic cellulitis.

3. *Spasmodic.*

4. *Post-operative.*—Practically confined to improperly performed Whitehead's operation for hæmorrhoids.

5. *Neoplastic* (see p. 405).

Simple Stricture of the Rectum

Whilst causes 1 and 4 are included under this heading, for practical purposes, when simple stricture of the rectum is spoken of, an inflammatory stricture is implied.

Clinical Features.—The condition is nearly always seen in married women between 30 and 40, and it seems probable that it is a sequel of gonococcal proctitis. The stricture (fig. 369) is usually 2 or 3 in. from the anal verge, and it gives rise to symptoms of partial obstruction, viz. constipation alternating with spurious diarrhœa. Occasionally "pipe-stem," or much-narrowed fæces, are complained of. *On examination*, the rectum below the stricture is sometimes ballooned. The examining finger abuts against a transverse septum, in

Fig. 369.—Simple stricture of the rectum.

the middle of which there is a hole. The sensation imparted has been likened to feeling a hole in a turnip. In extreme cases chronic intestinal obstruction with abdominal distention is apparent.

Treatment is usually difficult.

1. *Dilatation* of the stricture with rectal bougies is often satisfactory in comparatively early cases, providing the patient attends regularly for treatment.

2. *Linear proctotomy* is comparable to internal urethrotomy in the case of stricture of the urethra. Careful preoperative treatment by rectal wash-outs is necessary, and the treatment is only to be recommended when the stricture is comparatively low down. An incision is made through the stricture directly backwards, until the bone (lower part of sacrum and coccyx) is reached. As in the case of urethral stricture, a continuance of treatment by bougies is essential.

3. *Excision of the Stricture.*

4. *A permanent colostomy* is probably the best treatment in intractable simple stricture, especially in patients who cannot, or will not, attend for regular dilatation.

NEOPLASMS OF THE RECTUM

- Benign
  - Adenoma = Polypus
  - Papilloma
    - Single
    - Multiple
    - Bilharzia
    - } = Villous Tumour
  - Rare Tumours
    - Fibroma [1]
    - Lipoma
    - Angioma
    - Myoma
- Malignant
  - Carcinoma
    - Columnar-celled
    - Squamous-celled (from the anus)
  - Sarcoma
    - Round-celled
    - Spindle-celled
    - Lympho-sarcoma
  - Melanoma (of the anus)

[1] "Fibroma" is usually a thrombosed internal pile and not a neoplasm.

Polypus

Polypus is the commonest benign tumour of the rectum. It arises in the epithelium of the glands of the mucosa, generally in the lower part of the rectum.

Clinical Features.—The condition occurs most often in children, and gives rise to repeated rectal hæmorrhage. When it first develops it is sessile, but because of constant traction on defæcation, it soon becomes pedunculated (fig. 370). A polyp sometimes is the cause of a local intussusception of the mucosa.



Fig. 370.—Rectal polyp seen through a sigmoidoscope.

Treatment.—Excision of the tumour, together with a small portion of normal mucosa at its base. In adults the tumour should be examined histologically for evidence of malignancy.

Papilloma of the Rectum (*syn.* Villous Tumour)

Papilloma of the rectum is comparatively rare. Pathologically it simulates the characteristics of its counterpart in the bladder (p. 498). The papilloma may be single or multiple, and sessile or pedunculated.

Clinical Features.—Villous tumour is confined to adult life, and is very liable to become malignant. The leading symptoms are hæmorrhage, and a glairy white discharge, which is almost characteristic.

Treatment.—If single, treatment may be undertaken as for a polyp. In the multiple cases the onset of malignancy is so certain that it is usually advisable to excise the rectum as for a carcinoma.

Carcinoma of the Rectum

The rectum is a common situation for carcinoma to develop. Unfortunately, many cases are diagnosed late,

often for the want of a digital examination of the rectum by the clinician who first sees the case.

Pathology.—In general the pathology of carcinoma of the rectum is comparable to that of carcinoma of the colon, which has been discussed already (p. 325). In order to avoid repetition, we will emphasise salient points peculiar to the neoplasm in this situation :

SITUATION OF THE GROWTH

In the recto-sigmoid . . .	63 per cent.
In the ampulla	30 per cent.
In the anal canal	7 per cent.

(Sir Hugh Rigby.)

By these figures it is evident that many of these growths in their early stages cannot be reached by the examining finger, and sigmoidoscopy is essential.

Broadly speaking, carcinoma of the rectum does not metastasise early. The eventual local lymphatic spread is depicted in fig. 371. In late carcinoma of the anal canal the inguinal glands are often involved.

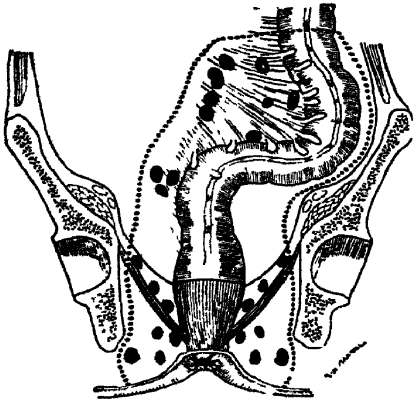

FIG. 371.—The lymphatic spread in carcinoma of rectum. It occurs downwards through the ischio-rectal fossæ laterally between the levatores and the pelvic fascia and upwards in the pelvic mesocolon. (W. E. Miles.)

Spread by the blood-stream occurs in advanced cases ; in a considerable series of necropsies at the Bernhard Baron Institute of Pathology on patients who had died from rectal carcinoma 50 per cent. had metastases in the liver.

Certain growths are relatively benign, while others are very malignant. This depends to some extent upon histological characteristics, and is reflected in the following investigation in a series of patients who survived a radical extirpation of the rectum :

Papilliferous . . .	Recurrence rate 0 per cent.
Adenoid	Recurrence rate 14 per cent.
Colloid	Recurrence rate 87·5 per cent.

(W. E. Miles.)

Clinical Features.—Although carcinoma of the rectum occurs most often between the ages of 40 and 60, it is not uncommon at a much earlier age. Other things being equal, the younger the patient the more hopeless the prognosis.

Growths high in the rectum give rise to symptoms of *stricture.*

Growths low in the rectum give rise to symptoms of *irritation.*

No *early* symptoms exist, except some changes of bowel habit and bleeding. Increasing constipation and diarrhœa are both late symptoms; by the time they appear the growth is too often inoperable. The best attitude to adopt is to suspect every patient—especially those over 40—who complains of recent constipation or bleeding, and to make a thorough examination digitally and proctoscopically. Above all, it is necessary to avoid jumping to a conclusion that because a patient has rectal hæmorrhage he is suffering from piles. When a growth has been found it is valuable to remove the fragment for biopsy. The histological examination not only irrefutably confirms the diagnosis, but allows the growth to be classed from the viewpoint of prognosis (see pathology).

Treatment.—The first question to decide is whether the growth is operable. Radical removal of the rectum is out of the question when:

The growth is fixed.

There are distant metastases, notably in the liver.

In some instances these points can only be determined by laparotomy.

Palliative Treatment.—Left inguinal colostomy, performed before obstructive symptoms develop, makes the patient's life tolerable, and in many instances causes temporary recession in the activity of the growth. If colostomy is

withheld there is a prospect of perhaps eight or nine months of life—but often a life of misery.

Radium has not proved of much value in the treatment of carcinoma of the rectum. Occasionally cures have been reported. In inoperable cases, after a preliminary colostomy, radium treatment is worth while.

Radical Treatment.—Two methods of removing the rectum hold the field at the present time: (1) the perineal operation; (2) the abdomino-perineal operation. The latter is more radical, because a widespread lymphatic area (fig. 371) is removed, but the former carries a lower mortality, and when performed in suitable cases has proved curative.

THE PERINEAL OPERATION

First Stage.—A left inguinal colostomy is performed fairly high up. At the same time the abdomen is explored for secondary deposits. The colostomy is opened two days later. Providing the abdominal exploration showed that the growth was operable, the second stage of the operation is undertaken two weeks later.

Second Stage.—The patient is placed in the left lateral position, and in the male a bougie is tied into the urethra. The anus is closed by a purse-string suture of stout silk. The incision is shown in fig. 372. The incision is deepened and carried through the ischio-rectal fat. The coccyx is disarticulated and the levatores ani cut through with scissors. The rectum having been separated from the prostate or vagina, the peritoneum is opened (fig. 372). The mesorectum is caught in forceps, divided, and ligated. The sigmoid is drawn down somewhat, and is divided between clamps with a cautery. The lower end of the sigmoid is closed and invaginated. The peritoneum is brought together below. The skin edges of the large wound are approximated, the considerable cavity being drained by a tube brought out through the posterior end of the wound, the better to avoid pressure upon the urethra.

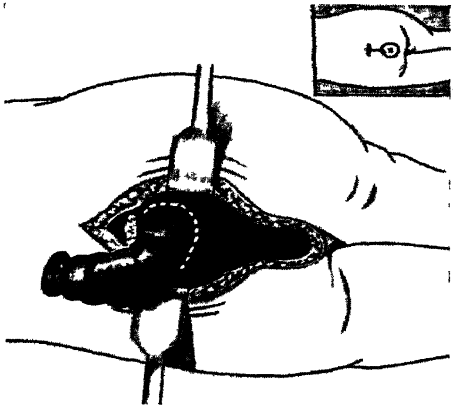

FIG. 372.—Perineal excision of rectum. (Inset, the incision.)

THE ABDOMINO-PERINEAL OPERATION

The Abdominal Stage of the Operation.—The patient is placed in high Trendelenburg's position, and the abdomen is opened through a large lower left paramedian incision. Providing there are no metastases on the peritoneum or in the liver, and the growth is mobile, the operator proceeds as follows. The small intestine is

packed away into the upper abdomen, and attention is directed to the pelvic mesocolon. If necessary, the peritoneum is divided on its outer side, thus to enable the pelvic colon to be drawn out of the wound and the taut mesocolon examined without hindrance. The upper portion of the root of the pelvic mesocolon is ligated by passing an aneurism needle around the sigmoid artery immediately below its first colic branch, care being taken to avoid the ureter (fig. 373). A second ligature similar to the above is placed ½ in. nearer the gut to occlude the corresponding venous channels bringing blood in the opposite direction, so that when the mesentery is divided between these ligatures the field is bloodless. The remainder of the pelvic mesocolon is divided between ligatures, keeping fairly close to its root. The peritoneum on either side of the pelvic colon and rectum is incised, after which the fatty connective tissue and lymphatics in the hollow of the sacrum can be stripped by thrusting the fingers into this space as far as the sacro-coccygeal articulation. Here a resistant band of connective tissue on either side must be divided with scissors. From this point the peritoneum is divided forwards on either side, carefully avoiding the ureters. The entire attachments of the rectum are next freed. Attention is now directed to the pelvic colon. It is drawn out of the wound and a hand's breadth from the termination of the descending colon a crushing clamp is applied and the bowel is divided between ligatures, the end being protected by tying rubber tissue firmly over them. The proximal ends are laid aside for subsequent use in establishing colostomy. The distal end is pushed down into the hollow of the sacrum. Peritoneal flaps are now fashioned and approximated so as to make a pelvic diaphragm above the now isolated bowel, which occupies the cavity of the pelvis. The abdominal portion of the operation is now complete save for establishing the colostomy, which is brought out through a small special incision in the left iliac fossa. The abdomen is closed.

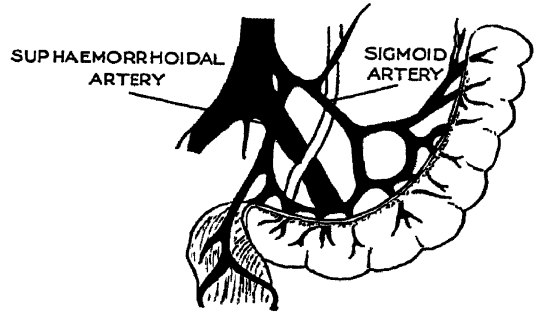

FIG. 373.

The Perineal Stage of the Operation.—The left lateral position is adopted, the table being horizontal. The operation is conducted in a similar manner to that of perineal excision of the rectum, but because of the elaborate dissection from above, the isolated distal segment of bowel almost falls out after a few touches of the scalpel. The edges of the perineal wound are then approximated with drainage, or the cavity is packed, the wound being left widely open. The area removed in the abdomino-perineal operation is indicated by a dotted line in fig. 371.

THE PERINEO-ABDOMINAL OPERATION

This method of excision of the rectum is growing in popularity. As its name implies, the perineal stage of the operation is done first.

CHAPTER XXII

HERNIA AND THE ABDOMINAL WALL

HERNIA

THERE are only three forms of hernia encountered frequently. They are inguinal, femoral, and umbilical. The most frequent of all is inguinal, which occurs in 73 per cent. of cases; then comes femoral, in about 10 per cent. of cases; and lastly umbilical, which occurs in about 8·5 per cent. of cases. This leaves only about 1 per cent. for the rarer forms. In this reckoning incisional hernia has not been included. At least twenty out of every thousand male inhabitants of Great Britain have hernia (Sir Arthur Keith).

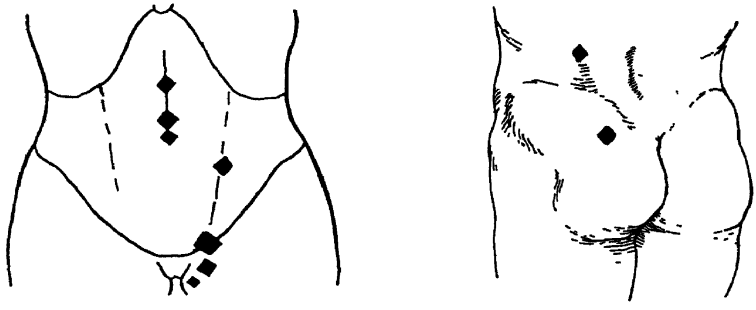

FIG. 374.

Red.—Common herniæ. Inguinal, femoral, umbilical, and para-umbilical.

Black.—Rare herniæ. Epigastric, lateral, obturator, lumbar, and sciatic.

Ætiology.—For centuries it has been known that there are two factors concerned in the production of a hernia: (1) a weakness of the abdominal wall at certain points (fig. 374), and (2) some force which tends to expel the abdominal contents from the cœlom.

The Saccular Theory.—Hamilton Russell and others claim that practically all herniæ, especially femoral and indirect inguinal, are congenital, in that the herniation of the abdominal contents occurs into a preformed sac.

Hereditary.—Statistics show that about 25 per cent. of patients give a history of hernia in their parents or grandparents.

Increased intra-abdominal pressure naturally tends to force the abdominal contents through any congenital or acquired orifice communicating with the peritoneal cavity. The common causes of increased intra-abdominal pressure are:

(*a*) Dysuria.
(*b*) Difficulty in defæcation.
(*c*) Chronic cough.
(*d*) The presence of an intra-abdominal tumour, e.g. pregnancy.
(*e*) Severe muscular effort.

Accidental muscular strain as a cause of hernia is a question which is constantly being disputed in the Law Courts. Where there has been a proved undue muscular strain incurred during and because of the plaintiff's work, and the clinical features and/or operative findings are compatible with the recent origin of the hernia, compensation is usually allowed.



FIG. 375.—The sac of a very large inguinal hernia removed at operation. The sac, which was completely removed by dissection, has been partially filled with water to enable the photograph to be taken.

Pathological Anatomy.—As a rule a hernia consists of three parts—the sac, the contents of the sac, and the coverings of the sac.

The Sac (fig. 375) consists of a diverticulum of peritoneum which is divided into a *neck*, where it passes through the abdominal wall, and an expanded extremity known as *the body, or fundus*. In recent herniæ the sac is thin-walled. In old-standing cases, especially after many years of pressure from a truss, the walls are often very thick or even of cartilaginous consistency.

Contents.—It has been said that every abdominal viscus except the liver has been found at times among the contents of hernial sacs. The commonest are:

1. Intestine = enterocele.
2. Omentum = omentocele (*syn.* epiplocele).
3. A portion of the circumference of the intestine = Richter's hernia.

4. A Meckel's diverticulum = Littré's hernia.
5. A diverticulum of the bladder.
6. Ovary, Fallopian tube, or testis.
7. Fluid.
8. Loose bodies, such as detached appendices epiploicæ, which have undergone secondary changes.

Coverings are derived from the various layers of the abdominal wall through which the hernia passes. They soon become atrophied from stretching, and are indistinguishable one from another.

Clinical Features of Hernia.—From a clinical standpoint it is most convenient to classify hernia in general into the following varieties :

1. Reducible.
2. Irreducible.
3. Inflamed.
4. Obstructed (*syn.* incarcerated).
5. Strangulated.

} Complications of 1.

Reducible Hernia

The hernia either reduces itself when the patient lies down. or can be reduced by the patient or by the surgeon.

The physical signs of reduction vary somewhat with the nature of the contents of the sac.

Gut gurgles on reduction. The first portion is more difficult to reduce than the last.

Omentum is doughy, and the last portion is more difficult to reduce than the first.

Bladder.—There is liable to be frequency of micturition, and the hernia may decrease in size after the bladder has been emptied.

Treatment of Hernia in General and Reducible Hernia in Particular

Palliative treatment is applicable principally to reducible herniæ when there is some contraindication to operation. In selected cases a truss is efficient. It must be worn continuously during waking hours, kept clean and in proper repair, and renewed as soon as it shows signs of irreparable wear. A good truss controls the hernia when the patient stands with his legs wide apart, stoops, and coughs violently.

"Does a truss ever cure?" is the constant query of the laity. Contrary to the advertisement assertions in the daily press, a truss or other appliance never cures, except occasionally in a young infant. Even in these cases it appears that only too often the cure is only apparent, for the hernia reappears in later life.

Operative treatment of all varieties of herniæ is exceedingly effective, providing the operation is well chosen and carefully performed. There are many varieties of operative technique, but only three *principles* involved:

FIG. 376.—Recurrent inguinal hernia. A strong indication for repair with fascial sutures.

Herniotomy.—Removal of the sac or obliteration of its lumen by injection.

Herniorrhaphy.—Removal of the sac, plus repair of the structures about the hernial orifice with heterogenous materials.[1]

Herniopiasty.—Removal of the sac, plus repair of the structures about the hernial orifice with living autogenous suture material (fascial graft).

Each of these methods has still a place in the treatment of individual cases. The modern tendency is to employ living sutures more and more in large and recurrent (fig. 376) herniæ and in patients who perform heavy manual work.

IRREDUCIBILITY

A hernia is said to be irreducible when its contents cannot be returned to the abdomen, and there are no other symptoms present. Such a condition is usually brought about by adhesions between the contents and the sac wall or from

[1] The materials which have been used for herniorrhaphy are numerous. Many of them have been almost entirely abandoned. These include linen thread, silk, silver wire (including the silver filigree). Materials still largely used are chromic catgut and kangaroo tendon.

an overcrowding of the sac. Irreducibility without any other symptoms is almost a perquisite of an omentocele.

Obstructed, or Incarcerated Hernia

So often is incarceration a dangerous diagnosis that we pass this by, referring the reader to the remarks on p. 431.

Strangulated Hernia

A hernia becomes strangulated when the blood-supply of its contents is seriously impaired, rendering gangrene imminent (fig. 377).

Fig 377. Strangulated inguinal hernia. (R.C.S.)

Strangulated Omentocele.—The clinical features are similar to those of an irreducible hernia, but the swelling is more tense, pain is sometimes a prominent feature, and the impulse on coughing is entirely absent. Unrelieved, a bacterial invasion of the dying contents of the sac will almost certainly occur, and lead to inflammation and local abscess formation.

Treatment is immediate operation and relief of the strangulation.

Strangulated Enterocele

Clinical Features.—General are those of acute intestinal obstruction, except in the case of a Richter's hernia, where they are usually entirely lacking.

Local are those of tenseness and tenderness of a hernia, and there is no impulse on coughing.

The Treatment of Irreducible Hernia in General and Strangulated Herniæ in Particular

Taxis.—Herniæ irreducible by ordinary means occasionally yield to taxis by the surgeon. This method is fraught with many dangers, particularly in cases of strangulation. Its application is limited to the case of inguinal hernia, and then only in the very early stages of strangulation and if previously reducible (p. 417).

Dangers of Taxis in Cases of Strangulation.

1. Rupture of the gut.

2. Reduction-en-masse (fig. 378).
3. Reduction into the abdomen of infected fluid.
4. Reduction into another sac = reduction-en-bissac.

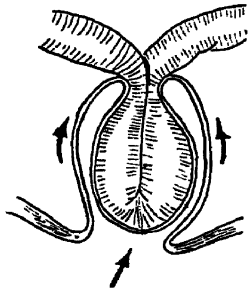

FIG. 378. — Reduction-en-masse.

THE RELIEF OF STRANGULATION

Immediate operation should be undertaken. Through a suitable incision the sac is opened and the constricting agent (usually the neck of the sac) is divided.

Strangulated Omentocele.—The affected portion of omentum is removed after securely ligating its pedicle.

Strangulated Enterocele.—The strangulation is relieved as in the foregoing. The gut is wrapped in a pad moistened with hot saline, and then inspected. Surgical judgment now comes into play as to the best course to adopt, depending on whether it is considered that the gut is viable, irreparably damaged by the strangulation, or frankly gangrenous. In deciding this momentous question it is often advisable to wait three or four minutes, applying and reapplying hot saline to the affected coil in an endeavour to restore the circulation. According to judgment, the following procedures may be adopted in individual cases :

1. An omental " overcoat " is wrapped round the affected coil, which is then returned to the abdomen.
2. The doubtful portion is invaginated.
3. Lateral anastomosis is performed above the site of the constriction and the doubtful gut is left protruding from the wound, wrapped in saline-soaked gauze, until the patient's condition improves, when it is returned or, if need be, resected.
4. The gangrenous portion is resected, and the continuity of the gut restored by end-to-end or lateral anastomosis.
5. In the case of strangulated **large** intestine only the following measures apply :

(*a*) If there is doubt as to the viability, an appendix epiploica is cut off. Other things being equal, if the cut edge bleeds the gut is viable (Hedei).

(*b*) In certain situations a doubtful portion of large intestine can be brought on to the surface, as in Paul's operation (p. 329).

(*c*) Gangrenous gut is resected, the distal end is closed, and the proximal end used as a temporary colostomy. It is never safe to resect and anastomose immediately large intestine.

Inguinal Hernia

Surgical Anatomy

The external abdominal ring lies ½ in. above and external to the spine of the pubis. The internal abdominal ring is situated ½ in. above mid-Poupart point. Between these lies the inguinal canal. The anatomy of the region is much simplified by visualising the versatility of the internal oblique in relationship to the cord.

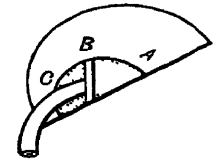

Fig. 379.

Referring to fig. 379, it will be seen that the Poupart fibres of the internal oblique are external (A); they then arch over the cord (B), and finally, in the form of the conjoined tendon, they lie behind the cord (C). Applying this knowledge, it is easy to remember the boundaries of the inguinal canal, viz:

In Front.—External oblique; Poupart fibres of **internal oblique.**

Behind.—**Internal oblique** (here conjoined tendon); deep epigastric artery; fascia transversalis.

Above.—**Internal oblique.**

Below.—Poupart's ligament.

See also Hesselbach's triangle (p. 418).

Indirect (*syn.* Oblique: Congenital) Inguinal Hernia

Ætiology.—There is every reason to believe that all indirect inguinal herniæ, at whatever age they first appear, are due to a preformed sac, to wit—the unobliterated funicular process.

In the first decade of life in the male inguinal hernia is common on the right side. This is no doubt associated with the later descent of the right testis (p. 539). After the second decade left inguinal herniæ are as frequent as right. The hernia is bilateral, or ultimately becomes so, in nearly 30 per cent. of cases, a fact which again supports the saccular theory.

Fig. 380.—Right inguinal hernia.

Injury to the ilio-hypogastric or ilio-inguinal nerves during the gridiron operation for appendicitis appears to be definitely associated with the development of a right inguinal hernia (p. 660).

Clinical Features.—All sizes of hernial sacs are encountered (fig. 380). On the one hand there is

the bubonocele, in which the fundus of the sac does not extend lower than the external abdominal ring. On the other there are enormous scrotal herniæ extending nearly to the knee. The diagnosis of a scrotal hernia presents no difficulty; the protrusion is obviously issuing from the inguinal canal. It is the bubonocele which is more difficult to diagnose. The most valuable method of examination is inspection of the inguinal region while the patient coughs.



FIG. 381.—Lipoma of the cord. Operative findings.

Differential Diagnosis.—An inguinal hernia must be distinguished from:

(*a*) *A femoral hernia* (p. 420).

(*b*) *A maldescended testis occupying the inguinal canal* (p. 540). An inguinal hernia is often associated with this condition.

(*c*) *A hydrocele* (p. 533).

(*d*) *An encysted hydrocele of the cord* (p. 534).

(*e*) *A lipoma of the cord.* This is often an extremely difficult, but unimportant, diagnosis. It is usually not settled until the parts are displayed by operation (fig. 381).

In the female.—A hydrocele of the canal of Nück (p. 535) is the commonest differential diagnostic problem.

Treatment

Palliative Treatment.—A truss is ordered.

Particulars required in ordering a Truss.—It is necessary to state the side and give some idea of the size of the protrusion; to indicate whether the opening through which the hernia escapes is large or small, and take the following measurement: pass a tape-measure round the girth of the body half-way between the iliac crest and the great trochanter (fig. 382). In difficult cases it is sometimes necessary to take a plaster cast of the pelvis for the guidance of the instrument maker.

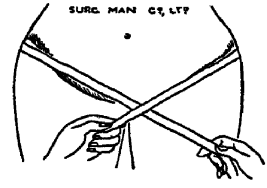

FIG. 382.

Operative Treatment

1. **Herniotomy.**—Complete excision of the sac (fig. 383) is satisfactory in the case of young children.

2. **Herniorrhaphy.**—Countless operative procedures have been employed, but they are nearly all modifications of two principles. In each the inguinal canal is opened by incising the external oblique and the sac is excised.

Halstead's Principle.—The conjoined tendon is sutured to

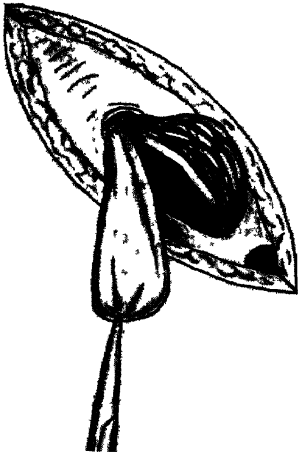

FIG. 383.—Herniotomy (after P. Turner).

FIG. 384.—Herniorrhaphy by the method of Jonathan Hutchinson.

Poupart's ligament over the cord. J. Hutchinson's modification of the Halstead principle is shown in fig. 384.

Bassini's Principle.—The conjoined tendon is sutured to Poupart's ligament under the cord.

3. **Hernioplasty.**—Living sutures of fascia are used to repair the inguinal canal. A strip is usually taken from the fascia lata, and using a needle having an especially large eye (Gallie's needle), the fascia is darned (fig. 385) into the weakened walls of the inguinal canal, using one of the principles of herniorrhaphy. When the external oblique muscle is in good condition (a rare event in large herniæ, which require especially repair by fascial sutures) a strip of the external oblique can be used (fig. 386).

Strangulated Inguinal Hernia (fig. 385)

The general principles governing strangulated hernia have been considered already (p. 412). It is only necessary to amplify the description in relation to inguinal herniæ in particular.



Fig. 385. — Hernioplasty. Strip of fascia lata being used to darn the walls of the inguinal canal.

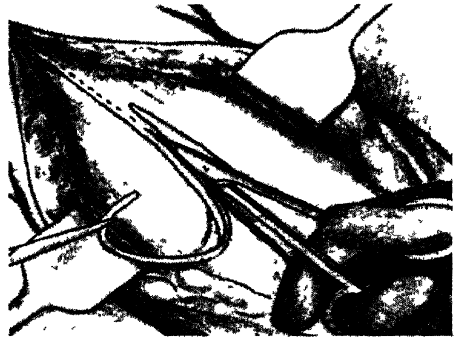

Fig 386.—Hernioplasty. Cutting a strip of fascia from the external oblique in the neighbourhood of the inguinal canal (after Adair)

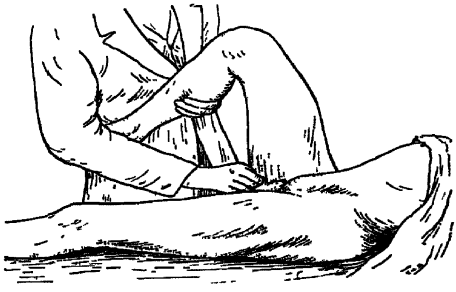

Fig. 387.—Applying taxis in the case of inguinal hernia. Note that the thigh is flexed and internally rotated.

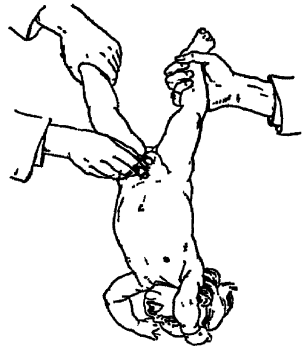

Fig. 388.—The "Judgment of Solomon" method of applying taxis in a strangulated inguinal hernia in infancy.

Taxis.—It is justifiable to apply taxis in early cases. The thigh must be flexed and internally rotated (fig. 387), which relaxes the

pillars of the external abdominal ring. With the limb in this position gentle, even pressure is exerted with the finger and thumb upon the fundus of the sac. If success does not attend the first attempt, the method should be abandoned in favour of operation.

In an infant taxis is often successful. The method of applying it in this instance is by adopting the "Judgment of Solomon" position (fig. 388).

Postural Treatment.—While arrangements are being made for the operation it is a good practice to raise the feet of the bed and administer a full dose of morphia. In a few instances the hernia reduces itself, rendering immediate operation unnecessary. We are inclined to think that less harm would be done if postural treatment was a recognised substitute for taxis in cases of strangulation, with the sole exception of recent strangulation in an infant.

Operative Treatment.—The sac is opened, and in most cases the point of strangulation will be found at the internal abdominal ring. The constriction is divided in an upward and inward direction, to avoid the deep epigastric artery. After dealing with the contents of the sac in the appropriate manner (p. 413) the operation is concluded by performing herniorrhaphy.

SPECIAL FORMS OF INGUINAL HERNIA

Direct Inguinal Hernia

Direct inguinal hernia occurs through Hesselbach's triangle (figs. 389 and 393). Probably 5 per cent. of all inguinal herniæ are direct, and they are found particularly in males with a weak abdominal wall (fig. 390). It is suggestive that an inguinal hernia belongs to this class if the palpating finger passes directly backwards through the external abdominal ring, but the only absolute method of diagnosis is to feel the pulsating deep epigastric artery on the lateral side of the neck of the sac; such a



Fig. 389.

finding can be seldom demonstrated with certainty. Direct herniæ rarely attain a large size, and they do not descend into the scrotum. Fifty-five per cent. are bilateral (Murray).

FIG. 390.—Malgaigne's bulgings. (Macready.)

The principles of **treatment** are comparable in every way to those of indirect inguinal hernia, but it is particularly in these cases that repair by fascial suture, where possible, is indicated.

SLIDING HERNIA (*syn.* HERNIE-EN-GLISSADE)

Sliding herniæ are due to a slipping of the posterior parietal peritoneum and the underlying cellular tissue, and it thus comes about that the posterior wall of the sac is not formed by the peritoneum, but by the cæcum on the right (fig. 391), and a portion of the pelvic colon on the left.

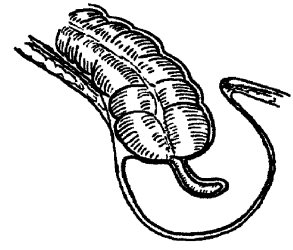

FIG. 391.—Hernie-en-Glissade.

Sliding herniæ are nearly always found in elderly men. They are not uncommon, particularly on the right side. Kirchner found 15 cases in 500 operations for inguinal herniæ. These herniæ are subject to the same complications as other inguinal herniæ, and are governed by similar principles in treatment.

The **operative treatment** is more difficult. The antero-internal portion of the sac is excised and closed, after which the large intestine is reduced and the inguinal canal repaired so as to form a floor upon which the ptosed viscus can rest.



FIG. 392.—Interstitial hernia. Usually a diverticulum from the sac of an inguinal hernia, but in the first and the last the entire vaginal process may pass between the layers of the abdominal wall.

INTERSTITIAL HERNIA (*syn.* INTERPARIETAL HERNIA)

The hernial sac, instead of passing out of the external abdominal ring, insinuates itself between the layers of the abdominal wall (fig. 392). The condition is due to a diverticulum from the processus vaginalis passing up between the layers of the abdominal wall.

Associated Abnormalities

(*a*) Fifty per cent. have some degree of maldescended testis.

(*b*) There is often superimposition of the abdominal rings, a persistence of the fœtal condition.

(*c*) An absence of the cremaster muscle.

Clinical Features.—Interstitial hernia is a difficult condition to diagnose, and usually it is only found in cases of strangulation. In non-strangulated cases interstitial hernia is sometimes suspected because of a bulging external to and above the external abdominal ring. In exceptional cases of interstitial hernia associated with an ordinary inguinal hernia, it may be possible to feel the peritoneal diverticulum fill up as the scrotal portion of the hernia is being reduced.

Treatment.—Operation should always be undertaken, and the sac is removed and the abdominal wall repaired.

FEMORAL HERNIA

Surgical Anatomy.—The femoral ring (fig. 393), or upper end of the femoral canal, is the small gap which transmits lymphatic trunks and sometimes lodges a lymphatic gland. It is plugged with fat—the septum crurale. The ring is bounded **in front** by Poupart's ligament, on the **inner side** by the concave, knife-like edge of Gimbernat's ligament, which is also prolonged along the ilio-pectineal line as Astley Cooper's ligament. **Behind** are found Astley Cooper's ligament, the pubic bone, and the fascia over the pectineus, while on the **outer side** there is a thin septum separating it from the femoral vein.

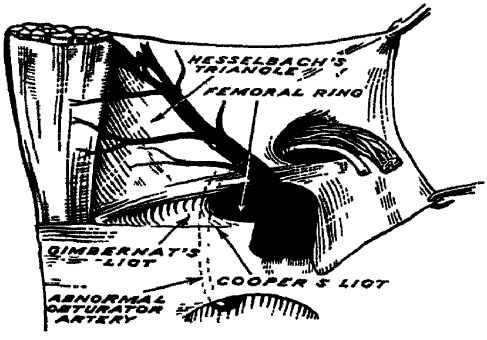

FIG. 393.—The femoral ring and its immediate neighbourhood from within.

A hernia passing down the femoral canal at first descends vertically, but, on reaching the saphenous opening, joyous, as it were, at leaving such a narrow, inelastic tunnel, it bulges through and enlarges especially in an upward direction. A fully distended femoral hernia assumes the shape of a retort (fig. 394), and its bulbous extremity is often above Poupart's ligament. Needless to say, by the time the contents have pursued so tortuous a path (fig. 395) they are irreducible, if not strangulated.

FIG. 394.

The abnormal obturator artery is the enlarged pubic branch of the deep epigastric; the dangerous form of abnormal obturator artery (fig. 396)—a source of real anxiety to a former generation of surgeons—does not perturb the operator to-day (p. 427). As heretofore, the femoral vein on the *outer side* and above all the **bladder** on the *inner side* are the surgeon's anatomical watchwords when dissecting the neck of a femoral hernial sac.

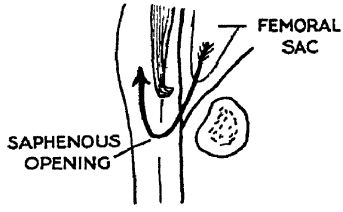

FIG. 395.—The path taken by a large femoral hernia.

Diverticulum of the Bladder in relationship to Femoral Hernia.—As pointed out above, the bladder, particularly a distended bladder, is an intimate internal relation of the neck of a femoral sac. Sometimes a diverticulum of the bladder finds its way down the femoral canal, usually in association with a femoral hernia. The condition should be strongly suspected when two sacs are found. Hernia of the bladder is much more often met with in the femoral than in the inguinal region.

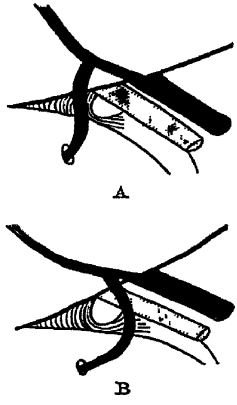

FIG. 396.—Abnormal obturator artery.
(*a*) Dangerous form.
(*b*) Non-dangerous form.

Clinical Features of Femoral Hernia.—Only 1 per cent. of femoral herniæ develop before the 15th year (Berger). The prevalence of femoral hernia increases from 20 to about 45 years of age,

and probably, because of the wider pelvis, it is twice as common in females as in males.

In men the proportion of inguinal to femoral hernia is at least 12 to 1. In women the two are of nearly equal frequency, inguinal hernia preponderating slightly. Although inguinal hernia is more than six times more common than femoral, the number of cases of strangulated femoral are nearly equal to those of strangulated inguinal hernia.

FIG. 397.—Femoral hernia. The swelling disappeared when the patient lay down.

A femoral hernia forms slowly and painlessly. Particularly in obese females, it passes unnoticed for years, until one day it strangulates. Three chief types are met with. In the first there is a rounded swelling lying below the inner end of Poupart's ligament (fig. 397). In the second the hernia, after it has passed the confines of the femoral canal, tends to descend the thigh (fig. 398). In the third there is the reverse of this, for the fundus mounts upwards in front of Poupart's ligament.

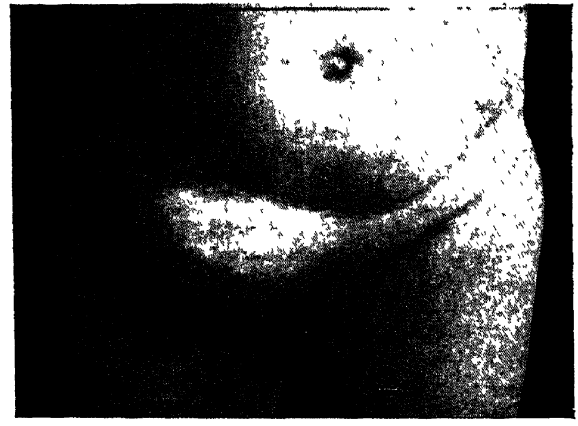

FIG. 398.—Large irreducible femoral hernia.

Differential Diagnosis

A reducible femoral hernia has to be distinguished :

(*a*) *From an Inguinal Hernia.*

1. The swelling as seen when the patient stands is more laterally placed than that of an inguinal hernia. In typical cases the swelling is manifestly below Poupart's ligament.

2. The neck of an inguinal hernia lies above and internal to the spine of the pubis, that of a femoral hernia below and external. If the spine of the pubis cannot be easily detected

the tendon of the adductor longus should be followed upwards.

3. If the tip of the little finger is insinuated into the external abdominal ring and the inguinal canal is found to be empty, then obviously the swelling cannot be an inguinal hernia.

(*b*) *From a Saphena Varix* (fig. 399). —An enlarged saphenous vein without obvious varicose veins in the neighbourhood is very liable to be mistaken for a reducible femoral hernia.

FIG. 399.—Saphena varix.

Both swellings appear when the patient stands and disappear when she lies down. In both there is an impulse on coughing. A saphena varix will, however, give one or more of the following signs, which are all absent in femoral herniæ:

1. *Venous Hum.*—A stethoscope is applied over the swelling and the characteristic saphenous hum is heard.

2. *Cruveilhier's Sign.* — When the patient coughs there is a thrill imparted to the palpating fingers as if a jet of water is entering and filling the pouch.

3. *Kelly's Test.*—This only applies when varicose veins are manifest. The veins below the knee are compressed with the left hand applied to the calf. With the right hand the inner side of the thigh is squeezed sharply just above the knee. The blood sent back through the internal saphenous vein makes a swelling in the groin quiver.

FIG. 400.—Psoas abscess simulating a femoral hernia.

(*c*) *From a Psoas Abscess* (fig. 400). —An examination of the back will usually clarify the diagnosis. In addition there is often a fluctuating swelling in the iliac fossa—an iliac abscess —which communicates with the foregoing

(*d*) *From a Psoas Bursa.*

(*e*) *From an Obturator Hernia* (p. 433).

Irreducible Femoral Hernia.—Again a real difficulty may be experienced in differentiating an irreducible femoral hernia from:

1. *An Irreducible Inguinal Hernia.*—The femoral hernia, even when it overlaps Poupart's ligament, always lies to the outer side of the pubic spine.

2. *An Enlarged Femoral Lymphatic Gland.*—If there are other enlarged glands in the region the diagnosis is tolerably simple, but when one gland only is enlarged, and that gland is situated in or near the femoral canal, the diagnosis may be impossible unless there is a lead, such as an infected wound or abrasion on the corresponding limb or on the perineum.

FIG. 401.—Hydrocele of a femoral hernial sac. The patient had had ascites, which improved under treatment with digitaline.

3. *Hydrocele of a Femoral Hernial Sac.*—The neck of the sac becomes plugged with omentum or by adhesions, and a hydrocele results (fig. 401).

4. *Rupture of the Adductor Longus* (with hæmatoma).—If there is no superficial bruising the diagnosis can be extremely difficult.

5. *A Lipoma.*

6. *A Femoral Aneurism.*

Treatment of Femoral Hernia

Palliative Treatment.—A femoral truss is usually unsatisfactory. Furthermore, the great liability of femoral

herniæ to strangulate is sufficient reason for urging the patient to have herniotomy performed. If necessary the operation can be carried out under local or spinal anæsthesia.

Operative Treatment.—There are many methods of performing femoral herniotomy:

The Lower Operation.—The hernia is exposed through a vertical incision over the sac, which is delivered into the wound and cleared as far up as possible. The sac is now opened and its contents reduced into the abdomen, after which the neck is ligatured as high up as possible. The femoral canal is then occluded by suturing Poupart's ligament to the fascia over the pectineus, or by driving a staple through Poupart's ligament into the pubic bone. The lower operation and its various modifications are going out of fashion in favour of methods which give better access to the neck of the sac.

The Inguinal (Lotheisen's) Operation.—The incision is similar to that for an inguinal herniotomy, but rather longer. The inguinal canal is opened and in the male the cord is held upwards and outwards. The conjoined tendon is retracted in the same direction, which displays the fascia transversalis; this is carefully divided, avoiding the deep epigastric vessels. The peritoneum above the neck of the sac is now in view, and with a little dissection the hernial sac can be seen entering the femoral canal. If the sac is empty it is delivered by traction. If the sac is not empty the peritoneum is opened and one can see exactly what is passing into it. If necessary, Gimbernat's ligament on the inner side may be divided from above. The abnormal obturator artery, if present, can easily be avoided or ligatured, if desired. The whole sac can now be brought into the inguinal wound and opened, emptied, and its neck ligatured and the sac removed. After the incision in the peritoneum has been closed obliteration of the femoral canal is carried out in the following way. Three sutures are passed through the periosteum and Astley Cooper's ligament overlying the iliopectineal line, care being taken to protect the femoral vein while these sutures are being placed (fig. 402). The free ends of these sutures are passed from the deep to the superficial surface of the conjoined tendon, which, when the stitches are tightened and knotted, is brought down and opposed to the iliopectineal line. All that now remains is to close the external oblique and the skin.

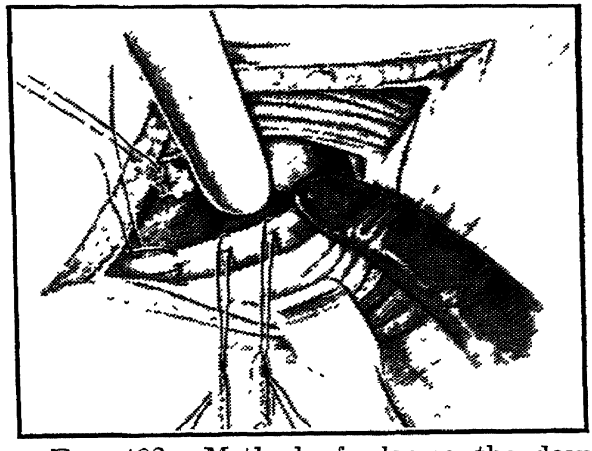

FIG 402.—Method of placing the deep sutures referred to in the text. (*B.M. Journ.*)

Hey Groves's Operation.—An incision similar to the above is made. The inner extremity of Poupart's ligament is defined, and it is cut off from the pubic spine. With a little dissection the whole thickness of Poupart's ligament is displaced laterally (fig. 403). This gives splendid access to the femoral sac, which is dealt with and removed in the usual manner. The repair of the region is conducted similarly to the foregoing, in that the conjoined tendon is approximated to the ilio-pectineal line. The sutures used for this approximation, after they have been tied, are left long, and are threaded through the free portion of Poupart's ligament and again tied, thereby firmly securing the ligament, though in a somewhat new position. It was formerly thought that to sever Poupart's ligament permanently weakened the abdominal wall. The results of Hey Groves's operation are amongst the best of any series followed over a long period.

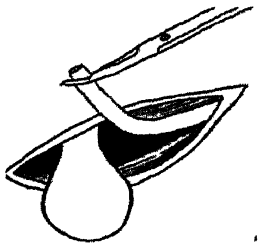

FIG. 403.—The principle of Hey Groves's operation.

Strangulated Femoral Hernia.—It cannot be emphasised too strongly that femoral herniæ frequently strangulate, and probably owing to the knife-like edge of Gimbernat's ligament and the exceedingly narrow neck of a femoral hernia, gangrene often develops rapidly.

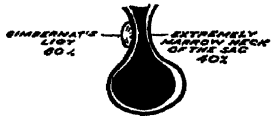

FIG. 404.—The obstructing agent in strangulated femoral hernia.

Mr. Souttar has called attention to the comparatively large number of cases in which the obstructing agent in strangulated cases is not Gimbernaut's ligament, but the neck of the femoral sac itself. The truth of his statement can be verified when the inguinal approach is used, and it will be found that in approximately 40 per cent. of cases division of Gimbernat's ligament does not relieve the obstruction, which will then be found actually in the neck of the sac (fig. 404).

A point upon which we should like to place great emphasis is the frequent occurrence of a **Richter's hernia** (fig. 405). When only a portion of the lumen of the gut is imprisoned the femoral swelling is sometimes not as big as a cherry. In addition, the patient, not having complete obstruction, continues to have her bowels opened naturally, or at any rate responds to enemata. Over and over again we have come across cases where a strangulated Richter's femoral hernia has been overlooked entirely or treated expectantly, until too late.

Treatment.—Taxis should not be attempted. Immediate operation, if performed soon enough, is a life-saving and entirely satisfactory measure. The bladder must be

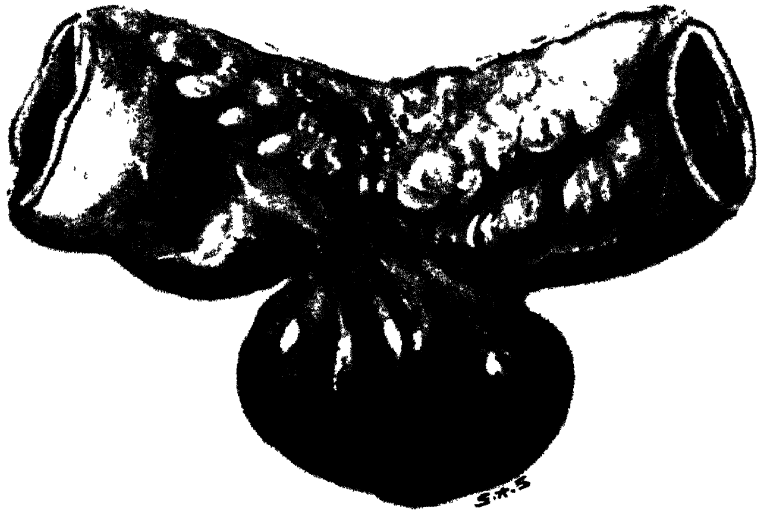

FIG. 405.—Gangrenous Richter's hernia from a case of strangulated femoral hernia.

emptied by a catheter just before the operation is commenced.

Whatever may be the relative merits of the various operative approaches in non-strangulated cases, the lower operation is beset with many disadvantages in cases of strangulation.

Disadvantages of the Lower Operation in Cases of Strangulation.

1. Resection and anastomosis within the limits of the wound is extremely difficult, and in many instances impossible. If resection is necessary laparotomy must usually be performed.
2. If the sac has been slit up in order to release a constriction high up in the neck, a loop of intestine may be reduced extra-peritoneally.
3. The bladder is in greater danger than when other methods are used.
4. An abnormal obturator artery, if cut, causes embarrassing hæmorrhage, whereas, when operating from above, the artery is seen and is accessible.
5. The knuckle or loop of imprisoned intestine may suddenly retract into the peritoneal cavity after the obstructing agent has been divided, and so prevent proper inspection unless laparotomy is performed.

For cases of strangulation Lotheisen's operation or Hey Groves's operation can be recommended strongly.

Umbilical Hernia

Several varieties of umbilical hernia exist :



Congenital. Infantile. Paraumbilical hernia of adults.

Fig. 406.—Varieties of umbilical hernia.

Congenital umbilical hernia
- Major = exomphalos.
- Minor = failure of complete retraction of the **U**-shaped loop (p. 309).

Infantile umbilical hernia.

Paraumbilical hernia of adults.

Fig. 407.—Exomphalos.

Exomphalos

The child is born with the intestines protruding from the umbilicus and covered by a delicate membrane (amnion) (fig. 407). Needless to say, such a flimsy sac is certain to rupture, and death will be inevitable. If, in addition to the intestines, the liver is outside the abdomen, the condition is hopeless, for it will be found that the abdominal cavity is too small to contain the viscera.

If intestines only are within the sac and operation is carried out a few hours after birth, there is a good chance of survival. The protruding intestines are reduced, the sac completely removed, and the abdominal wall brought together by through and through sutures.

Congenital Umbilical Hernia (Minor)

If a large number of young infants are examined a tendency to umbilical

protrusion will be found in approximately 20 per cent., but in nearly all it gradually disappears. In cases where the hernia is so noticeable that advice is sought, the application of a broad strip of adhesive plaster across the abdomen (fig. 408) often brings about a cure. In larger protrusions (fig. 409), and in those cases where simpler methods fail, operative measures similar to those described on p. 430 must be undertaken.

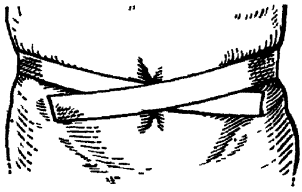

FIG. 408.

Infantile Umbilical Hernia

The umbilicus is a scar, and, like all scars, it may yield. Such an event usually occurs about the age of 3, and is a result of increased intra-abdominal pressure. Prominent amongst the causes are tuberculous peritonitis, chronic cough, atresia meati, and the pot-belly of rickets.

Treatment is to remove the cause ; but even after this has been accomplished the hernia persists and will need treatment. A broad rubber belt, having a rounded air-pad



FIG. 409.—Large congenital umbilical hernia in an infant.

opposite the umbilicus, can be worn constantly, and is a better and cleaner method of controlling the hernia than the well-known coin in a piece of adhesive plaster. If this does not bring about a cure within six months, and the child is now quite healthy, herniotomy can be undertaken.

Paraumbilical Hernia of Adults

It should be noted that the so-called umbilical hernia of adult life does not occur through the umbilicus. It is a

protrusion through the linea alba just above the umbilicus (fig. 406) or, very occasionally, just below that structure.

Clinical Features.—Women are five times more frequently affected. The patient is usually corpulent and between the ages of 35 and 50. Increasing obesity with flabbiness of the abdominal muscles is an important factor in the production of paraumbilical hernia, and in women repeated pregnancy strongly favours its occurrence. Paraumbilical hernia soon becomes irreducible because of omental adhesions within the sac. In old-standing cases intertrigo of the abutting edges of the skin (fig. 410) is a troublesome complication.

FIG. 410.

Treatment.—Once developed, paraumbilical hernia is never cured by truss pressure. Umbilical trusses are exceedingly difficult to keep in position and, as far as controlling the hernia is concerned, an abdominal belt is very little better. Untreated, the hernia increases in size, and more and more of its contents become irreducible. Eventually, strangulation occurs in not a few instances. It is for these reasons that early operation should be advised in nearly all cases.

Mayo's Operation for Umbilical Hernia.—A transverse elliptical incision is made about the umbilicus (fig. 411). The

FIG 411 — Paraumbilical hernia showing Mayo's incision.

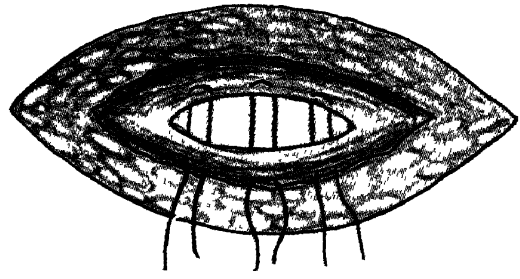

FIG. 412.—Mayo's operation for umbilical hernia.

neck of the sac is defined and opened. The contents passing through the neck are examined carefully piece by piece. Omentum is ligatured and divided ; intestine is reduced into

the abdomen. As soon as the contents have been dealt with, the neck of the sac is amputated. The peritoneum and layers of the abdominal wall are then incised for a short distance on each side, so as to allow the overlapping repair of the abdominal wall, depicted in fig. 412, to be carried out. The fat and skin are then approximated and the abdomen supported by a firm bandage. The patient should be confined to bed for three weeks, and if she has a tendency to bronchitis, which is not unusual, it is wise to prescribe expectorants, and order respiratory gymnastics with Woulff's bottles, similar to those employed in the after-treatment of empyema.

Strangulation

Strangulation is almost unknown in the umbilical herniæ of infancy and childhood, but it is a frequent and serious complication of a paraumbilical hernia.

Incarceration.—It is in large paraumbilical and incisional herniæ that the condition known as incarceration is supposed to occur. Personally, we have found the diagnosis an exceedingly dangerous one, and have operated on several cases where such a diagnosis had been made to find a putrefying strangulated portion of transverse colon within the sac. It seems very doubtful if the symptoms attributed to incarceration are consequent upon fæcal accumulation in the gut within the sac; as a rule such symptoms are due to recurrent subacute attacks of strangulation.

Treatment of Strangulated Umbilical Hernia.—Immediate operation must be undertaken. In most instances it is wise to employ spinal anæsthesia. The operation is conducted in a manner similar to that detailed for non-strangulated cases. The sac always contains a certain amount of omentum which on occasions is the sole content. Usually the transverse colon, and more rarely a loop or loops of small intestine, are found imprisoned, and they are dealt with in the appropriate manner.

Ventral Hernia

Definition.—Ventral herniæ include all those protrusions through the anterior abdominal wall which do not occur through the inguinal, femoral, or umbilical apertures.

Divarication of the recti is principally seen in elderly multipara. When the patient strains a gap can be seen between

the recti abdominis below the umbilicus through which the abdominal contents protrude. When the abdomen is relaxed the fingers can be introduced between the recti.

Treatment.—An abdominal belt is all that is required.

A similar condition is occasionally met with in babies, only the divarication exists above the umbilicus. No treatment is necessary; as the child develops usually a spontaneous cure results.

Fatty hernia of the linea alba (fig. 413) consists of a small protrusion of extraperitoneal fat through a deficiency in the linea alba, often about three or four fingers'-breadth above the umbilicus. Such a hernia tends to enlarge and drag a pouch of peritoneum with it, when it becomes a true epigastric hernia (fig. 414). Fatty hernia of the linea alba occurs principally in male manual workers between 30 and 45, and is probably a direct result of a sudden strain tearing the interlacing fibres of the aponeurosis. The hernia is often exceedingly small, and one no larger than a hazel nut can give rise to a great many symptoms, which include local pain, nausea, and vomiting. It is not uncommon to find that the patient has not noticed the hernia, but complains of symptoms referred to the stomach. On the other hand, a patient with an organic lesion of the stomach sometimes attributes all his symptoms to the small hernia.

FIG. 413.—Fatty hernia of the linea alba. (De Quervain.)

FIG. 414.—Epigastric hernia.

Treatment.—As a rule operation should be undertaken. If there is any doubt as to the fatty hernia being entirely responsible for the symptoms, it is a simple matter to explore the upper abdomen through a mid-line incision, and at the same time remove the fatty protrusion, and afterwards

repair the abdominal wall. Established epigastric herniæ are repaired in a similar manner to an umbilical hernia, but if the protrusion is well above the umbilicus a vertical, as opposed to a transverse, incision is often preferable.

Lateral ventral hernia is exceedingly uncommon. It occurs chiefly in the neighbourhood of the semilunar fold of Douglas. Usually these herniæ only partly penetrate the abdominal wall, and give rise to no obvious swelling.

Incisional Hernia

An incisional hernia can follow any abdominal operation, but fortunately it is not a frequent complication unless suppuration has occurred in the wound, or the patient's convalescence is interrupted by a severe cough. With a view to testing the integrity of the abdominal scar, all who have been subjected to laparotomy should have the scar inspected four weeks after being discharged. When a tendency to weakness of the scar is discovered a well-fitting abdominal belt will help to prevent the onset of an incisional hernia.

Treatment.—Once established, providing the patient's condition permits, an incisional hernia should be repaired by operation, and it is in these cases the **fascial sutures** are particularly useful. When operation is not advised, or refused, a special belt to meet individual needs should be fitted.

Large incisional herniæ are unilocular or multilocular. They are liable to strangulate, especially those following a lower, mid-line incision. *Incarceration* of an incisional hernia is a dangerous and probably inaccurate diagnosis. Small intestine is nearly always a constituent of the sac contents, and, probably because the intestine has been entangled in adhesions for a considerable time, the symptoms of acute obstruction are to some extent masked. These patients appear to tolerate the toxæmia of intestinal obstruction in a remarkable manner, whilst gangrene proceeds apace in the sac. **As a general rule, it may be said that conservatism in these cases usually spells disaster.**

The treatment of a strangulated incisional hernia is immediate operation similar to that for umbilical hernia.

Obturator Hernia

Obturator hernia is a condition of the greatest rarity. The hernia comes through the obturator foramen, which is below the femoral ring.

The swelling is liable to be overlooked, because it is covered by the pectineus. It seldom causes a definite swelling in Scarpa's triangle, but if the limb is flexed, abducted, and rotated outwards, the hernia sometimes becomes more apparent. Vaginal examination is said to be surprisingly effective in these cases. In strangulated cases pain is sometimes referred to the knee along the course of the obturator nerve.

Cases of obturator hernia which have been reported have usually been cases of strangulation, and the diagnosis has not been made until the abdomen has been opened for intestinal obstruction. The same remark holds good for sciatic, prevesical, and other exceedingly uncommon forms of herniæ.

Diaphragmatic Hernia

- Congenital
  - Through a pleuro-peritoneal hiatus
  - Through the œsophageal orifice
    - Thoracic stomach
    - Para-œsophageal hernia
- Acquired
  - Traumatic
  - non-Traumatic

The majority of diaphragmatic herniæ occur on the left side and they are usually congenital. Following the Great War a number of acquired cases were seen, but in civil life traumatic cases are of the utmost rarity. It is possible that non-traumatic diaphragmatic herniæ occur.

Diaphragmatic herniæ are difficult to diagnose. By X-rays after a barium meal, hollow viscera, which often include the whole or part of the stomach, can be demonstrated occupying a part of the thoracic cavity. Strangulation occurs sometimes (p. 343).

Treatment.—In cases giving rise to symptoms, an operation to close the defects can be undertaken, using the thoracic, abdominal, or combined routes.

Lumbar Hernia

Apart from incisional herniæ following kidney operations, and the yielding of a scar of a lumbar abscess which has discharged externally, a hernia occasionally occurs through Petit's triangle (fig. 415).

Differential Diagnosis.—A lumbar hernia must be distinguished from :

(*a*) A cold abscess pointing in this position.

(*b*) Phantom hernia, due to local muscular paralysis (fig. 416). Lumbar phantom herniæ can result from many conditions which interfere with the nerve-supply of the affected muscles. We have seen a case follow herpes zoster.

GLUTEAL AND SCIATIC HERNIÆ

The gluteal hernia passes through the great sacro-sciatic notch, either above or below the pyriformis.

The sciatic hernia passes through the lesser sacro-sciatic notch.

Swellings under the gluteus maximus cause great difficulty in iagnosis, because their individual character is masked by the verlying mass of muscle.

FIG. 415.—Lumbar hernia (after Sultan).

FIG. 416.—Phantom hernia due to localised muscular paralysis following anterior poliomyelitis.

Differential diagnosis must be made between this condition and—
(*a*) An aneurism.
(*b*) A cold abscess.
(*c*) A Weaver's bottom.
All doubtful swellings in this situation should be exposed by an pen incision.

PERINEAL HERNIA

Perineal hernia is practically confined to females. It occurs into he ischio-rectal fossa or into the labium majus.

Differential diagnosis must be made between this condition and—
(*a*) A pedunculated retroperitoneal fibroma.
(*b*) A cold abscess.
The hernia, which usually contains gut, is easily reducible. It as never been known to strangulate.

THE ABDOMINAL WALL

INJURY

Injury to the abdominal *wall* is so often overshadowed by concomitant intraperitoneal injury that the subject is elatively unimportant.

Intramural hæmatoma, following an accident, is often associated vith rupture of some portion of the abdominal musculature. On are occasions the deep epigastric artery has been torn without any ther major injury. The source of a lateral hæmatoma spreading nder the fascia transversalis is usually due to extraperitoneal upture of the corresponding kidney (p. 450).

Treatment.—Large hæmatomata must be evacuated and, if the leeding has not ceased spontaneously, the torn vessel ligated.

Ruptured Muscle.—Traumatic rupture of an abdominal muscle is almost confined to the rectus abdominis. The rectus is sometimes torn asunder in the spasms of tetanus (p. 16). When practicable the muscle should be repaired by suture to avoid an almost certain sequel of ventral hernia.

Burst Abdomen

Occasionally a laparotomy wound bursts open and the viscera are eventrated. The predisposing causes are hasty suture, leakage of pancreatic ferments which digest catgut, infection, and persistent cough.

A potent source of burst abdomen is the case of intussusception operated upon under general anæsthesia, which necessitates hasty and often imperfect closure of the abdominal wound. With spinal anæsthesia this complication does not arise (p. 337).

Prophylaxis.—When infection of the wound has supervened, or in other conditions in which it is thought that the stitches are liable to give way, the abdominal wall should be supported by " corsets " of adhesive plaster.

Treatment.—When the wound has burst asunder prompt action is imperative. Protruding intestine should be covered with a saline pad until the patient is anæsthetised, when, after carefully swabbing each coil with saline, it is returned to the abdomen and the abdominal wall resutured. Contrary to what might be thought, peritonitis rarely supervenes, and other things being equal, the majority of patients recover.

Infections

Spreading cellulitis of the abdominal wall is a serious, but fortunately rare, complication of a laparotomy. It presents the same clinical features as cellulitis in other situations.

Treatment.—Early incision into the lateral portions of the infected planes is essential, otherwise the condition is almost invariably fatal.

Abscess of the abdominal wall is seldom primary, but secondary to a focus within the abdomen, thorax, or the skeletal framework of the neighbourhood, e.g. ribs, spine, crest of ilium.

Neoplasms of the Abdominal Wall

1. **Fibroma** (*syn.* Desmoid Tumour).—Fibroma of the abdominal wall is a simple fibrous tissue tumour arising in the musculo-aponeurotic structures, especially those below the level of the umbilicus.

Ætiology.—Eighty per cent. of cases occur in women who have born children, and the neoplasm occasionally occurs in scars of old hernial, or other abdominal operation wounds. Consequently injury, e.g. the stretching of the muscle fibres during pregnancy, is a definite ætiological factor.

Pathology.—The tumour is composed of fibrous tissue containing multinucleated plasmoidal masses resembling foreign-body giant cells. It is usually of very slow growth, tending to infiltrate muscle in the immediate neighbourhood, but eventually it undergoes a myxomatous change, when the tumour increases rapidly in size. Metastasis does not occur, nor do these tumours in any way endanger life. Unlike many other fibromata, no case has been observed which has undergone a sarcomatous change.

Fig. 417.—Giant-celled sarcoma of the abdominal wall It was excised, but soon returned.

Treatment consists of early and complete removal with resection of a small margin of healthy tissue from which the tumour arose or has invaded.

2. **Sarcoma** of the abdominal wall is very rare, and is usually of the giant-celled variety. It appears to be singularly malignant, and in the solitary example which has come under our notice (fig. 417) a thorough excision of the mass was followed in a few months by extensive fatal recurrence.

The Umbilicus

The following table is a symposium of diseases of the umbilicus:

Inflammations.		Infection of the umbilical cord.
		Tuberculous peritonitis.
		Umbilical dermatitis.
		Primary chancre.
Fistulæ.	Fæcal	Patent omphalo-mesenteric duct.
		Tuberculous peritonitis.
		Neoplastic ulceration.
	Urinary = Patent urachus.	
	Biliary.	
	Gastric.	

Neoplasms.
- Adenoma.
- Carcinoma
  - Primary.
  - Secondary
    - from the Breast.
    - Stomach (fig. 418).
    - Liver.
    - Intestine.

Hernia (p. 428).

Cholesteatoma of the umbilicus.

A few of these require special consideration.

Fistulæ.—The umbilicus being a scar, and a central abdominal scar, it is understandable that a slow leak from any viscus is liable to track to the surface at this point.

For instance, an enlarged inflamed gall bladder perforating at its fundus has been known to discharge its contents, including gall-stones, through the umbilicus. Again, we were confronted with a middle-aged woman in whom an unremitting flow of pus from a fistula at the umbilicus led to the discovery of a length of gauze left in the peritoneal cavity during hysterectomy five years previously.

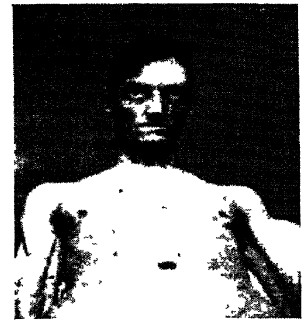

FIG. 418.—Secondary nodule at the umbilicus in a case of carcinoma of the stomach.

Added to this, certain embryological remnants, to wit, the omphalo-mesenteric duct and the allantois, open here in early fœtal life. Wherewithal, it has been aptly remarked that the umbilicus is a creek into which many fistulous streams may open.

Patent Omphalo-mesenteric Duct has been discussed on p. 310.

Unlike the omphalo-mesenteric duct, a **Patent Urachus** does not reveal its presence until maturity, or even old age. This is because contractions of the bladder commence at the apex of the organ and pass towards the base. A patent urachus, opening as it does at the extreme apex of the bladder, is temporarily closed during micturition, and so the potential urinary stream to the umbilicus is cut off. It so comes about that the fistula remains unobtrusive until a day when the organ is overfull, usually due to some form of obstruction, e.g. an enlarged prostate.

Treatment.—Usually no treatment is necessary other than that of removing the lower urinary obstruction. If the leak continues or a cyst develops in connection with the urachus, removal of the structure by dissection is indicated.

Umbilical Adenoma

The infant is brought because of a raspberry-like tumour at the umbilicus (fig. 419). The neoplasm, which is sometimes associated with a patent omphalo-mesenteric duct, is moist with mucus and tends to bleed. Histologically it shows columnar epithelium rich in goblet cells, signifying that the adenoma arises in the mucous membrane of the omphalo-mesenteric duct.

Fig. 419.—Umbilical adenoma.

Treatment is umbilectomy, combined with excision of the omphalo-mesenteric duct, which may, or may not, be patent.

CHAPTER XXIII

THE KIDNEYS AND URETERS

Urinary Symptoms

Three symptoms, a veritable triple alliance, accompany most urinary affections. They are: pain, frequency, and hæmaturia.

Pain.—*Renal pain* is usually "fixed" in the loin. *Ureteric pain* is the well-known renal colic passing from the loin to the groin, while *bladder pain* is mostly located in the urethra; in the male, at the tip of the penis.

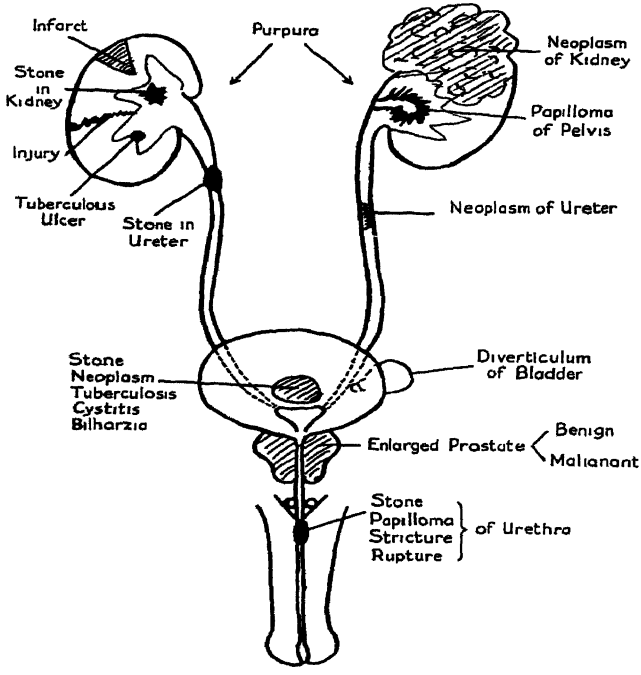

Fig. 420.—Scheme of some of the more important causes of hæmaturia.

Frequency.—The patient states that micturition is frequent. Of greater significance is the number of times he has to rise at night to empty his bladder. In the clinical history the record of such an enquiry is usually entered thus $\frac{D}{N} = \frac{?}{3}$.

Hæmaturia.—Blood in the urine, however transient, is a symptom which should

never be passed-by lightly. Painless hæmaturia is so often a symptom of new-growth in some part of the urinary tract that a complete renal investigation should be started at once, and the patient must not be discharged until the cause has been found. In painful hæmaturia the patient demands relief, and the task of persuading him to undergo a thorough examination is less difficult. The causes of hæmaturia are manifold. The more common ones are depicted diagrammatically in fig. 420, and these conditions will receive appropriate attention in the text which follows.

Urinary Investigation

It is possible to recognise advanced renal failure clinically by the following characteristics :

1. Headache.
2. Thirst.
3. A dry skin.
4. A dry, brown tongue.
5. Drowsiness.
6. Choked optic discs.
7. Polyuria of a urine of low specific gravity passing on to terminal anuria.
8. Sometimes hiccough.

Such symptoms are only in evidence when death is near at hand. Long before these symptoms and signs develop it is possible by scientific investigation to demonstrate slight degrees of renal failure. It is also possible to show the exact functional capability of each kidney separately, and to visualise the outline of the calyces, renal pelvis, ureter, and bladder upon the X-ray film. X-ray examination, blood chemistry, bacteriological and chemical examinations of specimens of urine from either kidney, cystoscopy, and pyelography have rendered the diagnosis of urinary disease an exact science. Some of the more important of these methods of investigation will now be referred to briefly :

The urine is examined chemically and bacteriologically. For the former a twenty-four-hour specimen is collected under normal conditions. For the latter a sterile specimen must be withdrawn with a catheter.

Urea Concentration Test

All fluid is withheld for eight hours. The patient then receives 15 grammes of urea dissolved in 100 c.c. of water. Urea is a diuretic, and the excess of urea in the circulating blood should be eliminated in a few hours if the kidneys are healthy. If the urine contains 2 to 2·5 per cent. of urea during the second and third hours after the intake, renal function may be regarded as satisfactory. If there is under 2 per cent. there is deficient functional activity of the renal tissue. The test may be combined with ureteric catheterisation, and the functional power of each kidney estimated in this way.

Blood Chemistry.—Among the most important is the quantitative examination of the blood urea. If such an examination shows that there is more than 45 mg. per 100 c.c. of blood, the patient is suffering from a corresponding degree of renal failure.

X-ray Examination.—X-ray examination has revolutionised the diagnosis of urinary calculi. It will be referred to in the section on renal calculus (p. 457).

Cystoscopy.—By cystoscopy the interior of the bladder is inspected and the ureteric orifices observed. If 7 c.cs. of a ·4 per cent. solution (adult dose) of indigo-carmine are injected intravenously, the excretion of the dye down the ureters can be watched (fig. 422). Delay of



FIG. 421.—A catheterising cystoscope.

excretion of the dye on one side is indicative of unilateral urinary obstruction, while delay on both sides suggests bilateral renal failure. By the catheterising cystoscope (fig. 421) ureteric catheters can be inserted into each ureter (figs. 423 and 424), and specimens of urine collected from each kidney. Such specimens are examined chemically and bacteriologically, and much absolute information obtained.

Pyelography.—(*a*) *Excretion Pyelography.*—A great advance was made when intravenous urography became adopted generally. Uroselectan, a product of Professor von Lichtenberg's genius, has been still further improved, and

FIG. 422.—Discharge of indigo-carmine down a right normal ureter. Cystoscopic appearance.

FIG. 423.—A ureteric catheter about to enter the ureteric orifice. Cystoscopic view.

FIG. 424.—Ureteric catheters in position. The shadow on the left is a mass of calcified mesenteric glands. The catheter on the right side has curled up in the renal pelvis, indicating that there is some degree of hydronephrosis present.

FIG. 425.—Excretion pyelogram.

Uroselectan B and Per-abrodil are the substances used at the present time. The doses of these various preparations vary considerably, and the correct amount to be injected is supplied in each case by the manufacturers. The injection is made intravenously, and X-ray photographs are taken (fig. 425) about fifteen, thirty, and sixty minutes after the injection. By this means the urinary tract can be visualised without the aid of preliminary cystoscopy and ureteric catheterisation.

(*b*) *Instrumental Pyelography.*—The ureters are catheterised, and the patient is conveyed to the radiological table. A sterile 20 per cent. solution of sodium iodide is injected up the catheter until the patient experiences discomfort in the loin. Normally, in the adult 7 or 8 c c. will be required to distend the pelvis of the kidney, but much larger quantities can be injected into a hydronephrosis. An X-ray photograph is then taken (see fig. 439). By this method it is possible to inject the pelves of both kidneys at the same sitting, but it is advisable to make each examination independently.

EMBRYOLOGY OF THE KIDNEY AND URETER

The metanephros, or permanent kidney, appears in human embryos as a bud from the lower end of the Wolffian duct. This bud grows back and upwards behind the peritoneum to the lumbar region (fig. 426). The stalk of the bud forms the ureter and its dilated extremity the kidney pelvis. Secondary buds from the renal pelvis now grow into the mesoblast, rebudding as they grow. Each group is the precursor of a pyramid. To review, the ureter, kidney pelvis, calyces, and pyramids are epiblastic in origin, and all derived from the metanephros.

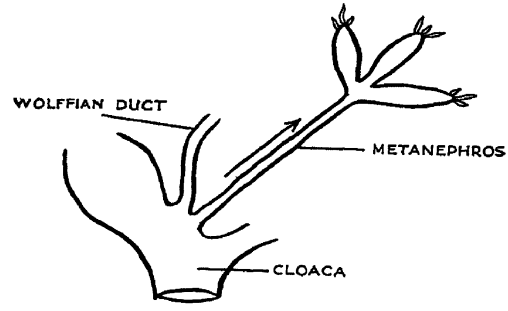

FIG. 426.—The metanephros.

The glomerulus, on the other hand, is formed from the mesoblast, as also are the convoluted tubules. The mesoblastic and the metanephric elements grow towards one another and fuse.

The fœtal kidney is at first lobulated, but in the human organ the lobules become welded together by the growth of a new cortex beneath the capsule.

Congenital Abnormalities

1. **One Kidney may be Absent.**—A diseased single kidney has, on rare occasions, been removed by an unwary surgeon. It is highly important to realise that one individual in every 1,500 has but a solitary functional kidney, the other being either completely absent or developmentally insignificant.

2. **The Kidney may remain Lobulated.**

3. **True Floating Kidneys.**—In very rare instances the kidney has a mesentery, and it thus becomes an intraperitoneal organ unstable in position.

Fig. 427.—Double ureter. Instrumental pyelogram.



Fig. 428.—A pyelogram showing a double pelvis of the right kidney.

4. **Misplaced Kidney.**—A kidney is arrested in some part of its normal ascent, usually at the brim of the pelvis.

5. **Double Ureter.**—The primary renal bud may be duplicated (fig. 427).

6. **Double Kidney Pelvis.**—Since pyelography has been in common use it has been found that this is a frequent congenital abnormality (fig. 428).

7. **Double Kidney.**—The whole kidney may be duplicated. Double kidneys are usually fused longitudinally. One half of a double kidney can be diseased and the other healthy. Excision of the diseased half has been practised successfully.

8. Pin-hole ureteric orifice gives rise to a ureterocele (fig. 429). On cystoscopy there is a swelling like a small balloon near the position at which one ureter should open. The treatment is to enlarge the ureteric orifice or make a new one by burning a hole with a cystodiathermy electrode.

9. **Horse-shoe Kidney.**

10. **Abnormal Renal Vessels.**

11. **Congenital Cystic Kidneys (Polycystoma).**

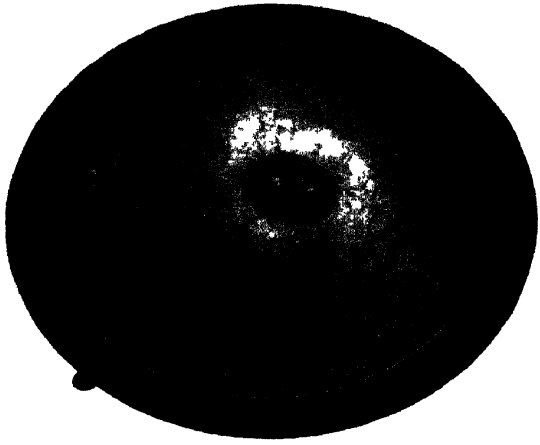

FIG. 429.—Right-sided ureterocele.

12. **Solitary Cyst of the Kidney.**

These last four are of such importance as to warrant detailed consideration.

HORSE-SHOE KIDNEY

The most median subdivisions of the primary metanephric bud of each side fuse, and the kidneys fail to ascend completely. The suprarenals, being developed separately, are in their normal positions beneath the diaphragm. It should be noted that the pelves of a horse-shoe kidney lie in front of the vessels instead of behind them, and their ureters cross in front of the fused lower poles (fig. 430). No doubt because the ureters tend to become somewhat

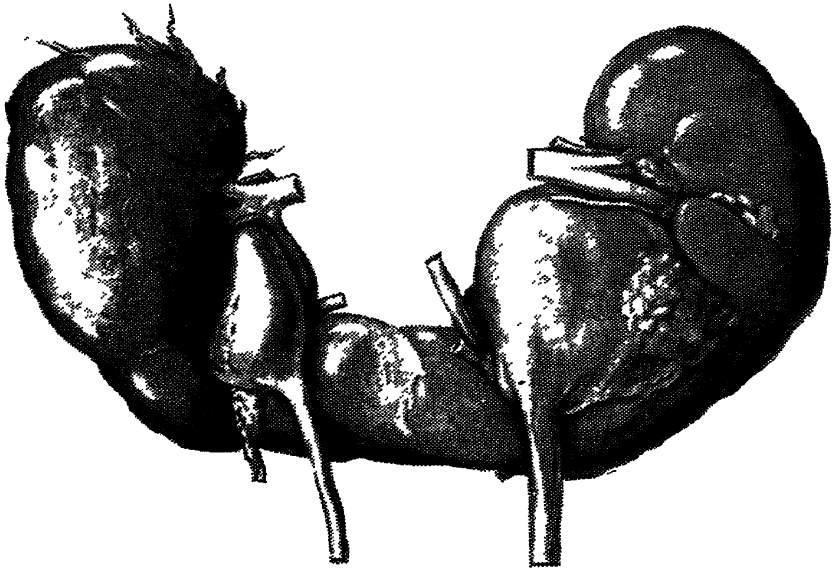

FIG. 430.—Horse-shoe kidney. Note the ureters passing in front of the fused lower poles. (Morson.)

obstructed as they pass over the horse-shoe, fused kidneys are more prone to be attacked by stone and tuberculosis as well as acute infections. The diseased half of a horse-shoe kidney can be excised.

Abnormal Renal Vessels

The presence of abnormal renal vessels passing to the lower pole across the commencement of the ureter (fig. 431)

Fig. 431.—Pelvic type of hydronephrosis caused by aberrant renal vessels.

sooner or later causes a kink, and gives rise to progressive hydronephrosis and its attendant evils.

Clinical Features.—The symptoms usually become manifest in young subjects. The leading symptom is unilateral renal colic. The diagnosis is made by pyelography (fig. 432), and excretion pyelography is particularly helpful in this instance. The pyelogram displays a constriction at the commencement of the ureter with a dilated pelvis above the constriction.

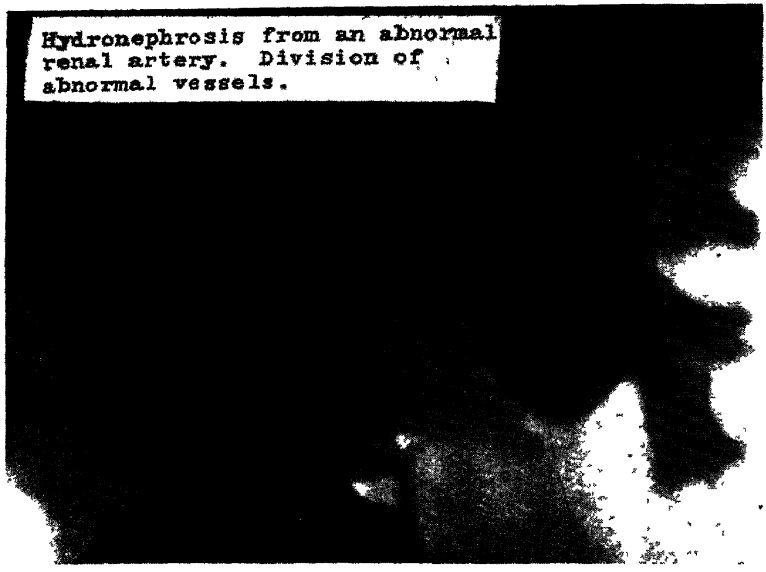

FIG. 432.

Treatment.—Early cases.—Division of the abnormal renal vessels between ligatures cures the condition. Some urologists disparage the operation, because after division of these vessels a small part of the lower pole of the kidney becomes infarcted. In our experience division of abnormal renal vessels has given exceptionally satisfactory results.

Cases of some standing.—The ureter becomes permanently constricted at the point where the vessels cross it. Here simple division of the abnormal vessels is insufficient. The ureter must be divided at the point of constriction, its upper end ligatured, and its lower end implanted into the lower part of the dilated renal pelvis.

Advanced cases.—Where the whole kidney is hydronephrotic, nephrectomy must be performed.

CONGENITAL CYSTIC KIDNEYS (POLYCYSTOMA)

are due to a failure of union of the metanephros with the tubules derived from the mesoblast. In 18 per cent. it is associated with congenital cystic liver.

Pathology.—The organs may reach an enormous size. While the usual outline of a kidney is preserved, the surface

presents an appearance which has been likened to a bunch of grapes (fig. 433). On section the renal parenchyma is riddled with cysts of varying sizes, some containing clear fluid, others thick brown material, and still others coagulated blood.

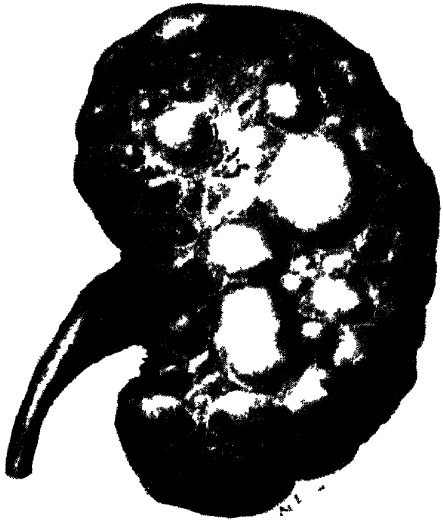

FIG. 433.—A congenital cystic kidney.

Clinical Features.—In the fœtus.—The kidneys may be so large as to obstruct labour.

In the child.—The bilateral tumours of congenital cystic kidney must be distinguished from those of bilateral renal sarcomata.

In the Adult.—There are five clinical types :

(*a*) *Insidious.*—The large "nobbly" kidneys when discovered in the course of a routine examination can hardly be mistaken.

(*b*) *Uræmia.*—The patient presents himself with symptoms of uræmia.

(*c*) *Nephroptosis.*—Especially on the right side, the very weight of the cystic kidney causes the organ to descend, and symptoms of nephroptosis may result.

(*d*) *Renal Tumour.*—One kidney contains larger cysts than the other, and gives rise to physical signs of a renal new-growth.

(*e*) *Hæmaturia.*—Congenital cystic kidney occasionally causes painless hæmaturia, a symptom which in this instance may even entrap the very elect.

There is no treatment for bilateral congenital cystic kidneys. When, through an error in diagnosis, a kidney thus diseased has been exposed by operation, the cysts may be punctured before the organ is replaced. In isolated cases where the disease is mainly unilateral, nephrectomy has been performed with lasting benefit. It is essential to

prove that the contra-lateral organ is normal, or almost so, before contemplating this measure.

SOLITARY CYST OF THE KIDNEY

Small cortical cysts, usually solitary, are often seen at necropsy. Small cysts cause no symptoms. Occasionally such cysts attain a large size. They can usually be excised without sacrificing the whole organ.

INJURIES TO THE KIDNEY

Injuries to the kidney are often divided into two classes :

" Slight."

Severe.

Although this classification is impressive, it is somewhat ambiguous, for slight initial symptoms sometimes accompany a severe renal laceration. Before definitely pronouncing a renal injury to be "slight," we should visualise the damage, and to-day, thanks to excretion pyelography, this is possible.

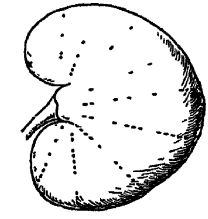

FIG. 434.—Diagram to show the usual lines of rupture of the kidney.

Nature of the Violence.—Blows or falls upon the loin are the most fruitful sources of renal injuries.

Rupture of the parenchyma appears to be often brought about by an increased intranephric hydraulic pressure at the moment of impact. This accounts for the fact that the tear or tears nearly always follow the line of the uriniferous tubules (fig. 434).

Clinical Features.—In "*slight*" *cases.*—1. There are no general signs after an arbitrary period, say of one hour, to allow of recovery from shock.

2. There are no local signs.

3. The only features which draw attention to the fact that the kidney has been damaged are a history of injury to the loin and blood in the urine.

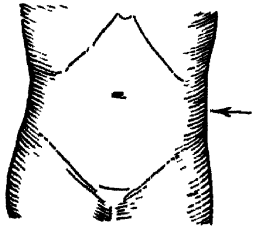

FIG. 435.

In severe cases.—There is rarely superficial bruising, but often a filling out of the normal contour of the loin is present on the affected side (fig. 435).

Hæmaturia is a cardinal sign of a damaged kidney, but it may not make its appearance until some hours after the

accident. If the hæmorrhage is profuse, it is liable to be followed by clot colic.

Severe Delayed Hæmaturia.—Sudden profuse hæmaturia may occur between the third and the fifth days in a patient who appeared, up to that time, to be progressing favourably. Delayed severe bleeding is due to a clot becoming dislodged.

Meteorism.—In many cases of severe renal injury, abdominal distension is seen. This is probably due to bruising of the overlying colon.

A perinephric hæmatoma causes a swelling in the loin, and tends to invade the iliac fossa.

Management and Treatment

Slight Injuries.—The patient should be put to bed, and kept there until all evidence of blood in the urine has disappeared. The urine must be saved, measured, and if at any time a specimen contains more blood than a previous one, this should be reported at once. An excretion pyelogram is sometimes valuable in estimating the extent of the injury. Urinary antiseptics are administered from the commencement and continued during convalescence.

Severe Cases.—It is imperative to keep an hourly pulse chart, and to save all specimens of urine duly labelled with the time of voiding. A cloth having been laid across the abdomen, sand-bags are placed on either side of the patient. An ice-bag is a valuable placebo. A large proportion of cases respond to expectant treatment. The minority require operation.

The indications for operation are :

The Hæmorrhage is so Severe or Continued as to threaten Life.—If the pulse-rate is rising, especially in spite of morphia, or if the blood in the urine is becoming more concentrated rather than lessening in quantity, the kidney must be explored. The lumbar route is chosen, and if the organ is found severely mutilated it should be removed. If an excretion pyelogram has been taken, we have pre-operative evidence not only of the extent of the tear but of the presence of a functioning kidney on the other side. If it has not been possible to take a pyelogram, the peritoneum in the anterior part of the lumbar wound must be opened, and the opposite kidney palpated before removing the damaged organ. In exceptional cases, when the lower pole is alone damaged, it may be possible to

perform partial nephrectomy. It is unlikely that when a kidney is so severely damaged as to warrant exploration, repair by suture would be trustworthy. Blood transfusion may be necessary.

Large Perinephric Hæmatoma.—When the hæmaturia is abating, and the general condition of the patient remains satisfactory but there is a large perinephric hæmatoma, this can be drained by an extraperitoneal incision in the iliac fossa without disturbing the kidney, which is no doubt by this time undergoing natural repair.

The recovery rate after all injuries of the kidney is very high, providing other organs are not damaged as well.

RARE INJURIES

Intraperitoneal rupture of the kidney has been recorded. The subject is usually an infant.

Rupture of a hydronephrosis may occur after a trivial injury, or even spontaneously. It usually results in a perirenal extravasation of fluid, but rupture into the peritoneum has occurred.

Rupture of the ureter can occur as the result of an accident causing hyperextension of the spine. The diagnosis is difficult, and seldom made until perirenal extravasation causes a swelling in the loin or the iliac fossa. The ruptured ureter can be united by stitches around a ureteric catheter, but difficulties in diagnosis usually preclude such treatment, which to be successful must be carried out comparatively early. In late cases, especially those in which infection has supervened, drainage of the extravasated fluid is all that can be done in the first instance.

Wounds or division of the ureter are not uncommon as an accident in pelvic surgery, particularly during a difficult hysterectomy. If the injury is recognised, the ureter can usually be repaired or its proximal end implanted into the bladder. Cases in which the accident is not recognised at the time must be treated on their merits.

Movable Kidney

That very rare condition, **floating kidney,** has been referred to under congenital abnormalities. Movable kidney is more common, but hardly so frequent as was considered ten or fifteen years ago.

Ætiology.—Because of atrophy of the perirenal fat the kidney becomes unduly mobile within the fascia of Zückerkandl. Repeated pregnancy and unscientific corsets are predisposing factors. Movable kidney is often but a part of a general visceroptosis.

Clinical Features.—Women are overwhelmingly more often affected, and in 90 per cent. of cases the unduly mobile organ is on the right. Various clinical types are encountered.

Symptomless Type.—A mobile kidney may be found in the course of a routine examination. Such patients are usually those with a long, thin abdomen, and they have at

least some degree of general visceroptosis. On no account must the patient be informed of the accidental finding, or she will probably soon become a prominent member of the neurasthenic type.

Painful Type.—There is a dragging pain in the right side, which is worse after standing for a long period and more pronounced when she is menstruating. The pain is relieved by lying down, and this is a notable and characteristic feature.

Crises.—Dietl of Vienna was the first to draw attention to the serious attacks of acute abdominal pain which occasionally arise from a movable kidney. These crises are of two kinds :

(*a*) *Renal Crises.*—The commencement of the ureter becomes acutely kinked (fig. 436) or rotation of the renal pedicle occurs. A temporary hydronephrosis develops with vomiting and renal colic. Suddenly the kink is rectified, the pain passes off, and the patient voids a large quantity of pale urine.

(*b*) *Pseudo-biliary Colic.*—The second part of the duodenum being an intimate extraperitoneal relation of the kidney, it will be appreciated that when the right kidney falls the duodenum can be dragged upon, and as a consequence the common bile duct becomes kinked. This will give rise to an attack of biliary colic with jaundice.

FIG. 436.—Profound nephroptosis with kinking of the ureter and distension of the renal pelvis. Nephropexy indicated.

Neurasthenic Type.—Neurasthenia is often an accompaniment of a movable kidney, and even if the kidney is fixed, symptoms continue in one form or another in most of these subjects.

Treatment.—*Palliative Treatment.*—Rest in bed for several weeks with a fattening diet and afterwards the use of a well-fitting abdominal belt improves, at least temporarily, a number of these patients.

Definite Contraindications to Operation.—(1) General visceroptosis. (2) Severe neurasthenia.

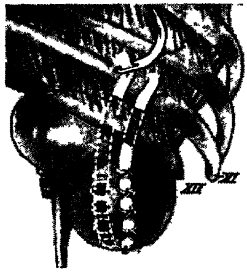

FIG. 437.—Nephropexy with a strip of fascia lata.

Indications for Operation.—(1) When renal or biliary crises have occurred. (2) When palliative treatment has failed

Nephropexy.—There are many varieties of technique. The most usual type of operation is: the kidney is exposed via the lumbar route, and decapsulation is performed. It is then slung to the twelfth rib and the surrounding muscles and fasciæ by means of sutures affixed to quadrants of the detached capsule. Nephropexy by means of a strip of fascia lata (fig. 437) is a good method.

HYDRONEPHROSIS

Sudden, complete, and permanent obstruction of a ureter does not cause hydronephrosis. Under such conditions the kidney ceases to function, and becomes gradually fibrous and contracted. Hydronephrosis is essentially the result of **partial** obstruction to the outflow of urine.

Pathology.—At first the renal pelvis becomes dilated, and gradually the whole substance of the kidney is destroyed by process of pressure atrophy. Ultimately the organ is transformed into a mere fibrous shell filled with fluid (fig. 438). Hydronephrosis may be unilateral or bilateral.

Unilateral hydronephrosis is either constant or intermittent, and always due to some form of ureteral obstruction.

Bilateral hydronephrosis is generally the result of some form of *urethral* obstruction, but it can also be caused by simultaneous partial occlusion of both ureters.

When, as is usually the case, the obstruction lies in the urethra, it is necessary to consider the mechanism by which the kidney became affected. In the first place the bladder hypertrophies, and the

obstruction is temporarily overcome. With this everyone is in agreement. The popular conception of bilateral hydronephrosis from urethral obstruction is that the bladder, after a time, ceases to hypertrophy, dilates, and by a process of back pressure the ureters dilate, and finally the kidneys become hydronephrotic. The second theory, which is more in keeping with modern investigations, is as follows. When muscular hypertrophy of the bladder occurs, the ureters, by reason of this hypertrophy, are partially obstructed in the intramural portion of their course. The narrowing of the lumina of the ureters at their termination is responsible for the hydronephrosis.

Ætiology.—In some cases of advanced unilateral hydronephrosis it is impossible to determine the cause. The pathological process has advanced too far. The principal causes of hydronephrosis are appended in the following table:

Unilateral

1. Aberrant renal vessels.
2. Kinks or stricture of the ureter.
3. Ureteric calculi.
4. Neoplasms of the kidney or ureter.

Bilateral

1. Atresia of the meatus, and, very rarely, phimosis.
2. Congenital valves of the male urethra.
3. Stricture, or other chronic interference with the lumen of the urethra.
4. Prostatic obstruction.
5. Malignant pelvic tumours invading both ureters (e.g. carcinoma of the cervix).

Clinical Features.—In *bilateral cases* there is little to call attention to the hydronephrosis other than the symptoms of the cause, e.g. stricture of the urethra and/or the symptoms of uræmia. It is unusual for bilateral hydronephrotic renal swellings to appear, for unless the obstruction is relieved the patient will die before the swellings are large enough to be palpable. The conclusive evidence of bilateral hydronephrosis lies in pyelographic demonstration.

In *unilateral cases* the initial symptoms are those of unilateral renal colic. As a result of an investigation the hydronephrosis is demonstrated by scientific methods,

notably pyelography (fig. 439). In late cases a renal swelling is palpable, but again it is necessary to prove its nature by pyelography.

Complications of a Hydronephrosis

Infection = Pyonephrosis.

Hæmorrhage into the Sac.—Severe hæmaturia sometimes accompanies this complication.

Rupture.—A hydronephrosis usually ruptures extraperitoneally. Cases of intraperitoneal rupture are recorded.

These complications are tabulated in order of frequency.

FIG. 438.—Renal type of hydronephrosis. All the renal parenchyma has been destroyed. (R.C.S. 148.1.)

FIG. 439.—A hydronephrosis injected with sodium iodide through a ureteric catheter (instrumental pyelography).

Treatment.—In early cases the cause must be removed. In later unilateral cases, when the other kidney has been shown to be healthy, nephrectomy is advised, but it must be emphasised that it is the modern tendency to remove a hydronephrotic kidney only when its parenchyma is completely, or nearly completely destroyed. In other cases the kidney is conserved by some form of plastic operation, which restores the patency of the lumen of the ureter,

such as dividing the ureter at the point of constriction near the pelvis, and implanting the distal end in the lower part of the dilated kidney pelvis. Conservative operations of this kind are sometimes rewarded by a partial regeneration of kidney parenchyma.

Renal Calculus

Varieties.—Stones found in the kidney usually belong to one of the following types :

Oxalate Calculus.—Popularly known as the mulberry, or hedgehog, stone, it is covered with sharp projections. These cause the kidney to bleed, and altered blood is precipitated on to the surface of the stone. Fig. 440 shows two oxalate calculi. The larger was removed from the right kidney and the smaller from the left of the same individual.



Fig. 440.—Oxalate calculi removed by operation.

The larger is black, owing to altered blood. The smaller is beginning to be discoloured around its sharp projections. These specimens illustrate clearly the process by which the oxalate calculus changes its complexion. Oxalate calculi cast an exceptionally good shadow, and this is fortunate, for often, by virtue of their spiked nature, they give rise to symptoms when comparatively small.

Phosphatic calculi are smooth and dirty white. In an alkaline urine they enlarge rapidly, and often fill the renal calyces, taking on their shape. A characteristic branched specimen is shown in fig. 441. Because they are smooth, these calculi give rise to few symptoms until they have

attained a large size. By reason of their size, rather than their density, they are demonstrated readily by X-rays.



FIG. 441.—Phosphatic calculi. Note the branched nature of one of the specimens.

Uratic calculi consist mainly of uric acid, sometimes accompanied by urates. They are hard and smooth, and since they are usually multiple (fig. 442), are typically faceted. Their colour varies from yellow to reddish brown. Pure uric acid calculi do not cast a shadow under the X-rays, but

¼ scale.

FIG. 442.—A cluster of uratic calculi removed from the lower pole of the left kidney of a woman of 45. Partial nephrectomy was performed because these stones had destroyed the lower pole. The kidney function was preserved

absolutely pure uric acid calculi are uncommon ; the majority contain enough oxalate crystals to render them opaque.

Stones composed entirely of bacteria are not very uncommon. They are soft and usually multiple.

Cystin calculus is soft like beeswax, but shows in the X-ray because of the sulphur it contains. Yellow when first removed, it changes on exposure to a greenish hue. Cystin stones are rare, and only occur in subjects with that inborn error of metabolism cystinuria.

Xanthin calculi are rarer still. They are smooth and round, and show a lamellar structure.

Indigo calculi are absurdly rare, but it is not unknown for them to be referred to in academic examinations. Blue in colour, they are derived from indican. The number of cases recorded can be counted on the fingers of one hand.

Ætiology.—Certain individuals have attacks of oxaluria or phosphaturia, while excessive deposits of urates are common from time to time in everybody, yet comparatively few suffer from urinary calculi. Even patients who habitually pass one of these substances in a concentrated form known as gravel often escape the misfortune of stone. For a true renal calculus to form, the crystals must become incorporated with organic matter. Speaking scientifically, a renal calculus is an irreversible colloidal adsorption product: irreversible because it cannot be dissolved in its original solution; colloidal because it has entered into organic combination with some colloidal substance such as fibrin; adsorption because a colloidal solution will take up more crystals than an inorganic solution.

Clinical observation has demonstrated that persons who live in certain localities are prone to stone; that there is a familial tendency to the disease; that residents in the tropics are affected more often than those dwelling in cool or cold climates; and that urinary stasis and infection directly predispose to stone. These are readily understandable and undisputed facts.

Clinical Features.—The symptoms of renal calculus are very variable, and the nature of the condition is sometimes obscure until an X-ray examination has been made.

Quiescent Calculus.—Some stones, especially those composed mainly of phosphates, lie dormant for a long period, the patient being unaware of their presence. Progressive destruction of the kidney is inevitable, and secondary infection occurs eventually in most instances.

The cardinal symptoms of renal calculus are pain and hæmaturia.

Pain is the leading symptom in 75 per cent. of cases. Three varieties are described:

Fixed renal pain is located in the renal angle posteriorly (fig. 443), or in the hypochondrium anteriorly. It is often worse on movement, particularly on walking upstairs. The patient may be unable to sleep on the diseased side (Fenwick).

Renal Colic.—Attacks of renal colic passing from loin to groin are characteristic (fig. 443). Renal colic sometimes culminates in STRANGURY, that is, an intense pain referred to

the tip of the urethra accompanied by the passage of a few drops of bloodstained urine.

Referred Pain.—In exceptional cases the pain of renal calculus may be referred :

(*a*) *To the bladder*, and take the form of bladder pain accompanied by urgent and frequent micturition.

(*b*) *To the corresponding testicle*, but this is usually accompanied by renal colic.

(*c*) *To the sole of the foot, the heel, or the thigh* of the corresponding side.

(*d*) *To the contralateral healthy organ* (the reno-renal reflex).

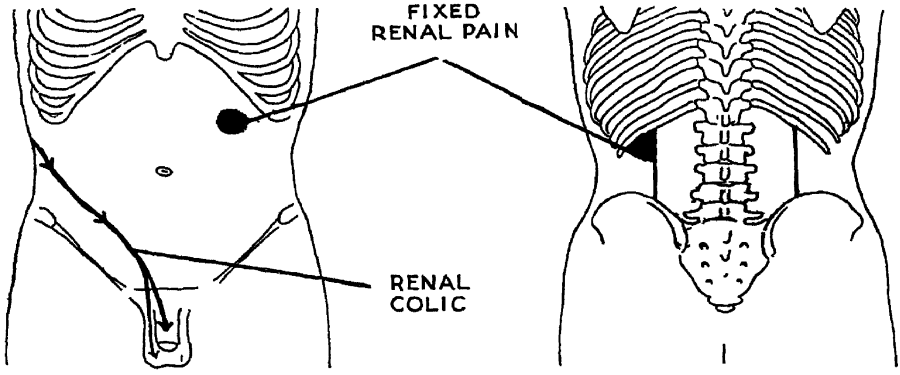

FIG. 443.—The usual distribution of renal pain.

Hæmaturia.—Under 50 per cent. of patients with renal calculus suffer from hæmaturia, but red blood corpuscles may be found in the urine by the microscope in nearly all cases when the blood is not apparent to the naked eye. When hæmaturia is a symptom it usually occurs in small quantities after an attack of pain. In rare cases hæmaturia is severe and is the leading, or only, symptom.

Pyuria.—Pus may be found in the urine, and is a frequent accompaniment of cases of renal calculus of considerable standing.

X-ray Examination.—So important is the X-ray examination in the diagnosis of the case that this will be a convenient place to mention some cardinal points connected with radiography for urinary calculus. Before the examination

the alimentary canal must be cleansed by the administration of a *vegetable* purgative, for minerals in the gut cast a shadow. The whole urinary tract, both kidneys, their ureters, and the bladder must be examined in every case. If a shadow is cast which *may* be a calculus in the kidney or ureter, the diagnosis can often be settled by re-examination after the passage of an opaque ureteric catheter, or by pyelography.

The following structures and substances from time to time cast a shadow which at first sight may appear to be a possible stone:

(i) Calcareous lumbar or mesenteric glands.
(ii) A concretion in the appendix.
(iii) Drugs in the alimentary canal, e.g. bismuth.
(iv) Phleboliths.
(v) The ossified tip of the twelfth rib or external arcuate ligament.
(vi) A chip fracture of the transverse process of a lumbar vertebra.



FIG. 444.—Stone in the pelvis of the right kidney.

The most characteristic location for a renal calculus is opposite the transverse process of the second lumbar vertebra (pelvis of kidney, fig. 444).

Treatment.—In the acute stage of calculus colic the patient should be ordered morphia and atropine in full dosage in accordance with his age. Plenty of bland fluids, such as barley water, should be imbibed, and urinary antiseptics are prescribed to prevent infection.

Nephrolithotomy.—As soon as the diagnosis is confidently established, and the other kidney has been proved to be functioning satisfactorily, renal calculi should be removed unless there is some definite contraindication to operation. The kidney is exposed in the loin and delivered.

If the stone is in the kidney substance it is located with a round-bodied sewing needle, which, when introduced into the kidney, will be felt to grate upon the stone. An incision of such a size as to permit removal is made directly over the stone. On no account should the whole kidney be sliced along "Brodel's line," as was the practice in days gone by,

for bisection mutilates the kidney, and invites serious post-operative hæmaturia. When the stone or stones have been extracted entirely, the wound in the kidney is carefully sutured with catgut. The suture line may be reinforced with a piece of muscle or a portion of perinephric fat.

If the stone is in the pelvis of the kidney, and that structure is accessible, the stone will be removed by opening the pelvis posteriorly (pyelotomy) rather than by traversing the parenchyma. After removal of the stone the edges of the wound are approximated by interrupted stitches of fine catgut, a flap of fatty tissue being brought over the suture line.

In specially equipped clinics it is possible to radiograph the exposed kidney. This ensures against any stone or portion of stone being left behind, and consequently reduces the number of so-called recurrences. The kidney is returned to its bed, and the wound sutured with drainage. The after-treatment is precisely that of a slight injury to the kidney (*q.v.*).

Complications of Renal Calculus

1. *Migration.*—The calculus may pass into the ureter, p. 464.

2. *Urinary Obstruction.*—Hydronephrosis (p. 454) or calculus anuria can arise.

3. *Infection* is a constant danger. All grades from pyelitis to pyonephrosis are possible.

Calculus Anuria

That the condition is one of anuria may be suspected when a patient has passed no urine for a considerable time, yet the signs of a distended bladder are wanting. The suspicion is confirmed by the passage of a catheter. Calculus anuria arises in one of the following ways :

1. Both ureters become blocked with stones.

2. A calculus becomes impacted in the ureter of a sole existing kidney, the other kidney being congenitally absent, previously removed, or destroyed by disease.

3. A calculus blocking one ureter and reflex anuria of the contralateral organ (rare).

Clinical Features.—*Period of Tolerance.*—The patient passes no urine, but remains in fairly good condition and does not necessarily experience pain, for a variable period up to four to six days. This is followed by uræmic convulsions and coma. The latter symptoms sometimes become manifest comparatively suddenly.

Calculus anuria is an urgent condition even before signs of uræmia have developed. An immediate X-ray examination



FIG. 445.—Stone impacted in the ureteric orifice as viewed through the cystoscope.



FIG. 446.—Cabot's method of performing nephrostomy.

may be most helpful. On the other hand, the shadows of the stones are not infrequently obscured by gaseous distension of the intestine, for full preparation of the patient is impossible. Cystoscopic examination sometimes yields valuable information ; for example, a stone may be seen wedged in a ureteric orifice (fig. 445), or œdema and hæmorrhagic exudate on one side will indicate the side which requires immediate relief. If stones are located in the pelvis of each kidney immediate operation is indicated, and the rule should be *to operate upon the side in which the patient last experienced pain,* for it is upon this side that the kidney is likely to be more potentially active. The operation should be one of nephrostomy, that is, placing a De Pezzer's catheter in the kidney pelvis in the manner shown in fig. 446. If the stone is accessible, it may be removed at the same time. In every

case nephrostomy should be attempted. If, by an unlikely mischance, the kidney explored is found to be diseased hopelessly, nephrostomy must be performed upon the other side.

The after-treatment consists in giving diuretics, and the best diuretic is an intravenous saline. Preparations should be made for blood transfusion, for sometimes the hæmorrhage from the incised œdematous kidney is excessive.

Ureteric Calculus

A stone in the ureter nearly always has its birth in the kidney, but authentic cases of primary ureteric calculus are on record. In 90 per cent. of cases the stone is single; it is frequently elongated, resembling a date stone in shape (fig. 447).

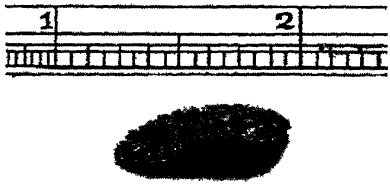

Fig. 447.—Ureteric calculus removed by operation.

Clinical Features. — When a stone descends into the ureter there is an attack of renal colic. This is repeated at longer or shorter intervals, until the stone is ejected into the bladder, or becomes impacted in the ureter. Should impaction occur the stone is usually arrested at one of the three points of anatomical constriction of the ureter, namely, at the outlet of the renal pelvis, at the brim of the bony pelvis, or at the entrance of the ureter into the bladder. The diagnosis is established by those methods which have just been detailed in the discussion on renal calculus. The passage of an opaque ureteric bougie is practically essential (fig. 448).

Treatment.—*Expectant.*—If the calculus is shown by the X-ray to be small, and the patient is having attacks of ureteric colic, there is every chance that the stone will be passed naturally. The patient is encouraged to drink large quantities of bland fluid; urinary antiseptics and antispasmodics, such as atropine gr. $\frac{1}{100}$ or better, tinct. ammi visnaga ʒi to ʒiii well diluted with water, t.d.s., are prescribed. The treatment is controlled by repeated radiographs.

Instrumental Treatment.—The passage of a ureteric bougie is occasionally attended by the expulsion of the stone. Various instruments are on the market for dilating the ureter through the cystoscope. If the stone is pouting through the ureteric orifice, it may be seized with special forceps through an operating cystoscope and extracted there and then.

Operative treatment is indicated :

(*a*) When expectant and instrumental treatments have failed.

(*b*) When it is judged that the stone is too large to pass naturally.

(*c*) When the stone has become impacted.

There should not be undue delay in removing a calculus which is not passing onward, and if an intravenous pyelogram shows that the kidney is dilated, the operation should be hurried forward, for, amongst other complications which may be expected is infection, which seriously jeopardises rapid convalescence after removal of the stone.

FIG. 448.—Stone in the ureter. Catheter passed alongside the stone.

Operation.—The most popular route for the removal of a ureteric calculus is the extraperitoneal. An incision is made in the line of the ureter, the external and internal oblique muscles are divided, likewise the transversalis. The peritoneum is then gently mobilised by gauze dissection until the dilated ureter is found adhering to its under surface. The stone is sought by palpation, and, if possible, is milked upwards or downwards to a convenient point for extraction. When this is not possible the ureter is opened and the stone drawn out by a scoop or forceps. Occasionally the stone is so firmly impacted that the only course is to incise the ureter directly over the stone. This practice, however, should be avoided whenever possible, for the ureter's lining membrane is damaged at this spot, and is less likely to heal quickly than when the incision is made through healthy tissue.

The opening into the ureter is always longitudinal, and after extraction of the stone it may be loosely approximated by a few interrupted stitches. The wound is drained, and there is a free leakage of urine for a week or more. During convalescence urinary antiseptics are administered. The mortality of this operation is very low, the end results are exceedingly satisfactory, and, if there are no stones left in the kidney, recurrence is almost unknown.

INFECTIONS OF THE KIDNEY

Pyelitis

By pyelitis is understood inflammation of the pelvis of the kidney without involvement of the renal parenchyma. In the majority of cases the Bacillus coli is the infecting agent, but streptococci, staphylococci, and the B. proteus are sometimes responsible.

Acute pyelitis is a common condition. Infection may be primary or secondary to some form of urinary obstruction. In primary cases women are more often affected, and the right side is much more often attacked. The diagnosis is difficult, for abdominal rigidity and tenderness are in evidence. Atypical cases are sometimes confounded with acute retrocæcal appendicitis. In typical examples of acute pyelitis the temperature is high—103° to 105° F. Rigors are usual, and there is frequency of micturition. In the early stages, when it is so imperative to make a correct diagnosis, the urine is clear. If, however, a catheter specimen is centrifuged and examined microscopically, pus cells can often be demonstrated.

Pyelitis of pregnancy usually commences during the fourth month, and is practically confined to the right kidney. The condition has been attributed to pressure upon the ureter of the enlarging uterus. The symptoms are similar to those of acute pyelitis. Excretion pyelography shows that the pelvis and ureters, especially the right, are always dilated during pregnancy (fig. 449).

Treatment of Acute Pyelitis.—When rigors are commencing, quinine in 5-grain doses t.d.s. may be ordered. If the pain is severe morphia is necessary. Liberal draughts of barley water should be imbibed. Unless the urine is

strongly alkaline, it is best to start by producing an alkaline tide by the following mixture :

℞ Pot Cit.	gr. xl
Tinct. Hyoscy.	♏ xx
Infus. Buchu.	ad. ℥ss

After the first two days, when the urine is thoroughly alkaline, an acid tide is commonly produced by giving sodium acid phosphate gr. 30 followed by urotropin gr. 5, but acid ammon. phos. is superior as an acidifier of the urine (see p. 468). The latter should be prescribed separately to avoid decomposition. We have found intravenous urotropin 5 c.c. of a 40 per cent. solution injected daily for six or seven days very efficacious. An autogenous vaccine is recommended for all cases which tend to become chronic.

FIG. 449 —Excretion pyelogram 1½ hours after an injection of uroselectan B, in a case of pyelitis of pregnancy. (D. Baird.)

Chronic Pyelitis.—The leading symptoms are frequency and pyuria. The treatment should be directed to removing the cause, prescribing urinary antiseptics, and administering an autogenous vaccine. In persistent cases, washing out the kidney pelvis through a ureteric catheter with a weak colloidal silver preparation is sometimes helpful.

Bacilluria is akin to chronic pyelitis, but there is no demonstrable lesion of the urinary tract. The patient continues to excrete pus and organisms in the urine. Urinary antiseptics and an autogenous vaccine should be persisted in, but the condition is often very chronic.

SOME URINARY ANTISEPTICS

Acid ammonium phosphate and ammonium chloride are superior as acidifiers of the urine to sodium acid phosphate. The following is a good prescription:

Acid Ammon. Phos.	gr. xx
Syr. Limonis	ss
Aq. ad.	ij

t.d.s. p.c.

Hexamine by mouth has stood the test of time as a good urinary antiseptic, and in a well-acidified urine it cures one-third of all cases of pyelitis and cystitis, *providing that there is no underlying surgical lesion.* When this drug is administered it should be given with ammonium chloride in the following mixture:

Ammon. Chloride	gr. xx
Hexamine	gr. x
Liquid ext. of Liquorice . . .	xxv
Aq. ad.	ij

Not only is ammonium chloride a better acidifier than sodium acid phosphate, but a mixture containing ammonium chloride and hexamine remains stable for more than two weeks, whereas, as is well known, when sodium acid phosphate is used the hexamine must be prescribed separately.

Neotropin.—The usual dose of neotropin is two dragées by mouth for four days, with copious draughts of barley water. The urine turns a brilliant orange. Neotropin is equally effective whether the urine be acid or alkaline.

Ketogenic Diet.—The treatment of intractable urinary infections by the use of ketogenic diet has received considerable attention. The production of ketonuria of a pH of 5·5 renders the urine highly bactericidal. For the technique of this treatment medical works should be consulted.

PYELONEPHRITIS

The old term for this condition was "surgical kidney," and no doubt in the days of unsterile catheterisation, when acute retention of urine was even more common than it is to-day, acute pyelonephritis was a frequent and dreaded condition. Pyelonephritis is also a frequent complication of cases of fractured spine with injury to the spinal cord.

While there is no dividing line between acute pyelitis and acute pyelonephritis, the latter condition much more often follows obstruction of the *lower* urinary tract with superadded infection. It is frequently bilateral and often fatal.

Morbid Anatomy.—If a kidney of a patient who has died from acute pyelonephritis is split longitudinally, we see under the capsule miliary abscesses due to infection of the

lymphatics. The whole parenchyma is swollen, and yellow streaks of pus can be seen following the lines of the uriniferous tubules.

Clinical Features.—The symptoms are similar to those of ultra-acute pyelitis. In addition the tongue is dry and furred, and the patient complains of intense thirst. Later, a low, muttering delirium, followed by coma, the result of combined septicæmia and uræmia, carries off the patient.

The treatment is largely preventive. For instance, it is a surgical crime to pass a catheter on a patient with acute retention without full aseptic ritual. Once the condition has developed the only treatment is to decompress the bladder slowly, if it is distended, and to follow the programme detailed for acute pyelitis.

Pyonephrosis

The kidney is simply a bag of pus. The condition is usually due to an infection of a hydronephrosis or the result of a continued suppurative process in the kidney.

The diagnosis is arrived at by proving that one kidney is entirely or almost entirely out of action. Excretion pyelography gives no shadow at all, or a very faint one, and this negative evidence is useful. By cystoscopy pus may be seen coming down the affected ureter, and dye introduced into the venous system does not appear on that side.

Treatment.—The orthodox treatment is to drain a pyonephrosis in the first instance, and later to perform nephrectomy. Owing to the great difficulties in excising the kidney, or rather the shell of the kidney, after long-continued suppuration, we are inclined to think that in some instances the small additional risk of performing primary nephrectomy should be taken.

CARBUNCLE OF THE KIDNEY

The source of origin of the organism is most often a cutaneous lesion, such as a boil, carbuncle, or whitlow, and the staphylococcus aureus is conveyed to the kidney via the blood-stream.

Morbid Anatomy.—On splitting open the kidney there is a necrotic mass of tissue, usually towards one pole.

Ætiology.—There is often a history of injury such as a blow upon the loin. If such a blow occurs while the patient is suffering from

a cutaneous staphylococcal lesion, a carbuncle of the kidney is liable to develop.

Clinical Features.—There is an ill-defined, tender swelling in the loin, persistent pyrexia, and leucocytosis. Pyelography may be helpful in determining the diagnosis.

The treatment, in most cases, should be nephrectomy.

Perinephric Abscess

In many instances the perinephric fat appears to be primarily attacked by blood-borne infection. Again, the infecting organism is frequently the staphylococcus aureus. In the majority of instances the kidney is unaffected, and remains healthy if the abscess is opened early. In the minority the perinephric infection is an extension of infection from the kidney. The early diagnosis of perinephric abscess is often very difficult. The symptoms are those of pyrexia, combined with tenderness and fullness in the loin. One should not wait for an obvious swelling in the loin, but explore as soon as the condition is strongly suspected. An incision is made in the loin, and the abscess drained.

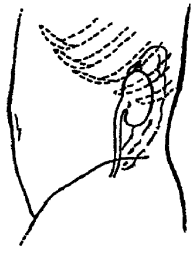

Fig. 450.—Perinephric abscess.

Renal Tuberculosis

Almost invariably one kidney is the primary seat of urinary tuberculosis. For a long period the disease is limited to this kidney, but eventually the tuberculous process spreads to other parts of the genito-urinary mechanism. Renal tuberculosis is usually blood-borne. It is possible for the kidney to excrete tubercle bacilli from the blood-stream without itself becoming diseased. Sometimes a clump of tubercle bacilli is arrested in the kidney during this process of excretion, and another case of renal tuberculosis has commenced.

Clinical Features.—The patient is often a young adult. The symptoms are very variable, and it requires an astute clinician to suspect their true cause in the early stages of the disease.

A. Cavernous form (very common).

"It tends to burst like a bombshell."

B. Caseous kidney.

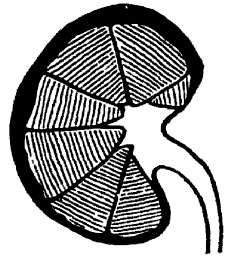

A caseous mass divided by fibrous septa.

C. Tuberculous ulcer (rare).



Hæmaturia a leading symptom.

D. Hydronephrosis (rare).



E. Pyonephrosis.

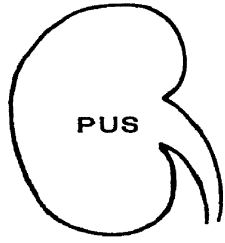

Secondary infection, B. coli, etc., very prone to supervene.

F. Pseudo-calculi.



On X-ray examination calcified tuberculous areas in the kidney simulate calculi.

G. Miliary.



A part of a general tuberculous process.

H. Chronic interstitial nephritis.

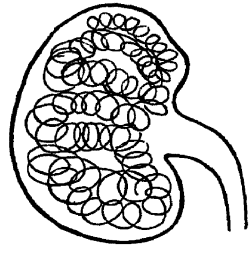

Found in subjects who die from severe extra-urinary tuberculous lesion.

I. Tuberculous perinephric abscess.

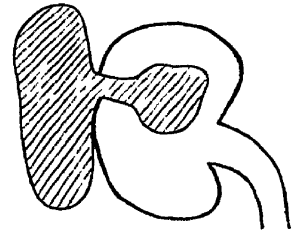

FIG. 451.—Types of tuberculous kidney (macroscopic pathology). In all cases the ureter is thicker than usual, and frequently it is also *shorter* (sclerosing periureteritis).

Frequency of micturition is perhaps the most characteristic symptom. The patient states he has to get up to pass urine several times during the night.

Pain.—(*a*) *Renal pain.*—In this case it takes the form of a dull, heavy ache in the loin, unrelieved by lying down. This symptom is infrequent.

(*b*) *Bladder pain* is more often in evidence. It comes on in attacks lasting two to three days, and the pain is referred to the tip of the penis. Bladder pain is due to a cavernous tuberculous focus (fig. 452) in the kidney bursting "like a bombshell" into the interior of the organ. The tuberculous débris is carried to the bladder and irritates it.

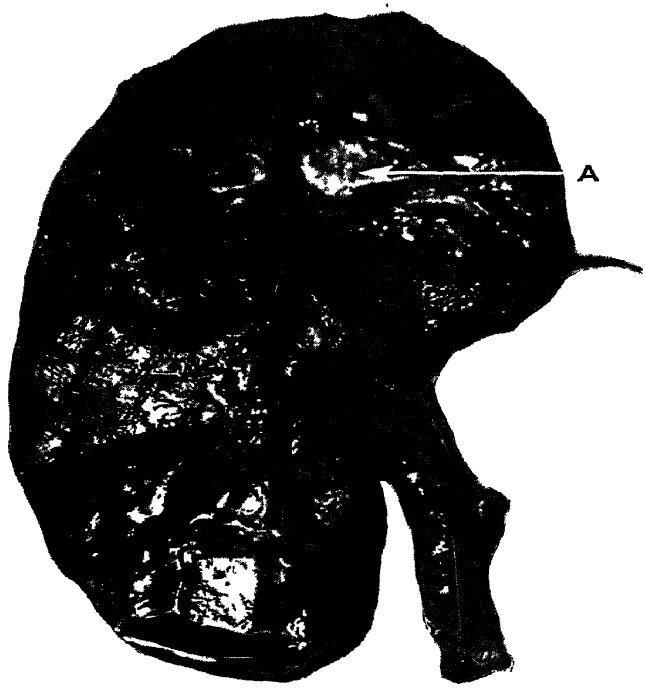

FIG. 452.—Cavernous type of urinary tuberculosis. There is a cavity filled with caseous material in the upper pole of the kidney (A). Note the greatly thickened ureter.

Hæmaturia may alone be present. It is rare, and occurs in that variety of tuberculous kidney shown in fig. 451.

Constitutional Symptoms.—Wasting and a raised evening temperature are usually late manifestations.

On Examination.—It is unusual for a tuberculous kidney to be palpable. When a patient with renal tuberculosis has an enlarged kidney which can be felt, it is by no means certain that this kidney is the one which is diseased, for compensatory hypertrophy of the contralateral

organ sometimes makes the healthy kidney both large and tender.

The line of the ureter, and (in the male) the prostate, vesicles, vas, and epididymis should be examined for thickening, which bespeaks tuberculous invasion of these parts.

Collecting Urine for Examination.—The meatus must be cleansed carefully to avoid contamination by the smegma bacillus which, like the tubercle bacillus, is acid-fast. A sterile catheter is used to draw off the specimen of urine. If the report, " pus and tubercle bacilli present," is returned from the laboratory, it is certain that we are dealing with a case of urinary tuberculosis. When tubercle bacilli without pus are found, it is possible that the organisms have been excreted by a healthy kidney.

On Cystoscopy.—The most typical picture is the " golf-hole " ureter. The ureteric orifice on the affected side is drawn up and gaping. This phenomenon is the direct result of sclerosing periureteritis. In earlier cases there may be only a little redness, pouting of the œdematous mucous membrane, or a slight outward displacement of the ureteric opening to indicate the side which is diseased. In still others the ureteric orifice is quite normal, though perhaps an efflux of pus may be seen or a delay of excretion of dye, which has been introduced into the venous system, noted. Ureteric catheters are passed, and specimens of urine obtained from each kidney. These specimens are sent to the laboratory for examination.

FIG. 453 —Note the irregular tuberculous ureter.

Pyelography often yields

valuable information (fig. 453). A cavitation in the kidney shadow is of ominous significance.

Treatment.—If it can be shown that the contralateral kidney is free from tuberculosis, the diseased kidney and ureter should be removed. The most elaborate conservative treatment under ideal conditions in a Solarium fails to cure renal tuberculosis. The results of nephro-ureterectomy are excellent and the operative mortality is now under 2 per cent.

THE SURGICAL TREATMENT OF BRIGHT'S DISEASE

Cases of acute parenchymatous nephritis with *threatened* uræmia may be benefited by renal decapsulation (Edebohl's operation). Each kidney is exposed, and its capsule opened by a longitudinal incision. The capsule is stripped off the kidney with a finger. This allows the kidney to swell, and permits the congested tubules to function.

The operation is quite useless in advanced uræmia, but if it is performed at the right time, it may be distinctly beneficial.

NEOPLASMS OF THE KIDNEY

Benign Neoplasms

Adenoma.—Pea-like cortical adenomata are sometimes found at necropsy. They give rise to no symptoms during life, and are of academic interest only.

An **angioma** is usually of the venous type, and may give rise to profuse hæmaturia. Fig. 454 shows a kidney containing a venous hæmangioma. The patient, who was a woman of 35, had attacks of painless hæmaturia extending over five years.



FIG. 454.—Angioma of the kidney. The kidney was excised for profuse painless hæmaturia.

Papilloma of the renal pelvis is similar

in structure to papilloma of the bladder. It tends to invade the kidney proper, and to take on malignant characteristics.

Benign tumours of the kidney are rare, and are only recognised after the organ has been extirpated. A good rule is "*all neoplasms of the kidney which can be recognised clinically should be considered malignant and treated as such.*"

Malignant Neoplasms

Grawitz's tumour (*syn.* hypernephroma) is the commonest neoplasm of the kidney (fig. 455). It may occur in any

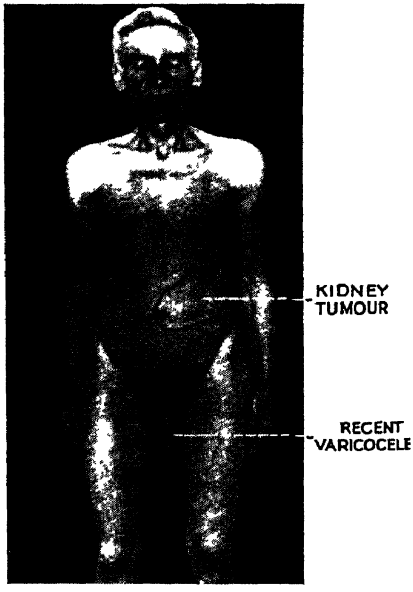

FIG. 455.—Grawitz's tumour (hypernephroma) in a patient aged 52.

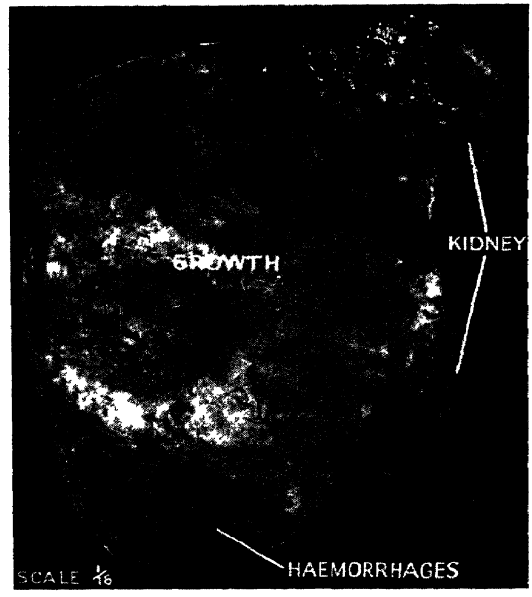

FIG. 456.—Grawitz's tumour (hypernephroma) removed successfully by the transabdominal route.

part of the renal parenchyma, but it is slightly more often found in the upper pole. On section, in its early stages, the tumour is found to be encapsulated. It is made up of polygonal cells containing lipoid material, which gives it a characteristic yellow hue. Encysted hæmorrhages (fig. 456) into its substance are common, and in this respect it simulates congenital cystic kidney, from which it may always be

distinguished macroscopically in the fresh state by its yellow colour. The growth remains encapsuled for a varying period. Eventually it always breaks its confines, and is prone to grow into the renal veins. Pieces of growth become



FIG. 457.—Carcinoma of the kidney. The organ was excised because of profuse hæmaturia.

detached, and are swept into the circulation when metastatic deposits become disseminated widely.

True carcinoma presents an appearance similar to carcinomata elsewhere (fig. 457).

Wilms's tumour (*syn.* "sarcoma" of the kidney) is a mixed tumour arising from the connective tissue of the kidney. In early infancy such tumours are sometimes bilateral, and were formerly thought to be sarcomata. In unilateral cases, which usually occur in children about the ages of 3 or 4 years, the tumour tends to remain encapsulated for several months. It grows rapidly, pushing aside the kidney rather than infiltrating it, and often reaches an enormous size. This tumour is very malignant once it has

broken its confines, and it metastasises both by way of lymphatics and the blood-stream.

Clinical Features.—Neoplasms of the kidney are divided into two great classes :

Those occurring in children between the ages of 1 and 5.

Those occurring in adults after the age of 40.

Between the ages of 5 and 40 malignant neoplasms of the kidney are uncommon.

Those occurring in the Adult (notably Grawitz's tumour). —The first sign is painless, profuse, intermittent hæmaturia. Clot colic may follow. The patient should be examined while the bleeding is in progress, and by cystoscopy it is possible to see from which side the blood is coming. Pyelography may be helpful in determining the diagnosis (fig. 458). It is exceptional to find a palpable renal swelling, although, on occasions, this is the leading symptom (see fig. 455). In the male a rapidly oncoming varicocele is a suspicious sign of a malignant kidney tumour (fig 455). Two conditions simulate a renal neoplasm to a point of nicety .

FIG 458.—Pyelogram in a case of malignant left kidney. The only symptom was painless hæmaturia. Note that the calyces, particularly the upper ones, are distorted by invasion of the growth.

(*a*) Hæmorrhage into a hydronephrosis.

(*b*) Congenital cystic kidney with hæmaturia.

Those occurring in Children.—Hæmaturia is conspicuous by its absence. In very young children bilateral renal tumours (Wilms's tumour) present a typical clinical picture. The kidneys grow to an enormous size, but unlike congenital cystic kidneys, they are comparatively smooth. The child

wastes ; its ribs soon become conspicuous, and the cachectic facies bespeaks the hopelessness of the condition.

Unilateral renal neoplasm occurs in somewhat older children (3 to 5). Pathologically the neoplasm is often a teratoma. Again hæmaturia is absent, and because, as we have seen, the tumour tends to grow within its capsule, pushing the rest of the kidney away, the reniform shape of the kidney is lost. On this account these tumours are difficult to diagnose, and on the left side they mimic an enlarged spleen.

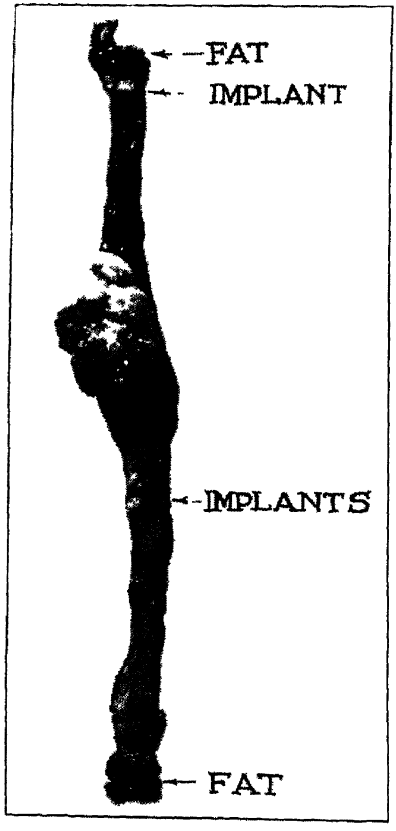

FIG. 459.—Primary carcinoma in an excised ureter. (Davis and Sacks.)

Treatment.—With early diagnosis nephrectomy offers a considerable hope of a cure. Without nephrectomy a malignant neoplasm is invariably and rapidly fatal. When the tumour is large, such as is the case in a unilateral Wilms's tumour, the abdominal route will be chosen for the removal of the organ.

Primary Carcinoma of the Ureter (fig. 459) is very rare and difficult to diagnose. A persistent defect in the line of the ureter on pyelography is the only guide. The symptoms simulate exactly those of a malignant kidney.

OPERATIONS UPON THE KIDNEY

Surgical Approach.—The kidney can be approached via the loin or through the abdomen. The indications for the latter route are very limited.

1. **The Posterior Route.**—The older method of exposing the kidney is by **Morris's incision.** The incision commences first below the angle made by the lower edge of the twelfth rib with the outer border of the erector spinæ, and it passes downwards and outwards towards the anterior superior iliac spine. Within the limits of the incision,

all muscular layers are incised until the extraperitoneal fat is reached. This incision is effective, but it gives rise to more bleeding, and is definitely more liable to be followed by post-operative hernia than its usurper:

Mayo's Incision.—This incision commences over the centre of the erector spinæ at the level of the upper border of the twelfth rib, and passes directly downwards for 3 in., where it curves outwards to form a ⌊ (fig. 460).

1. The erector spinæ sheath is incised vertically, and the erector spinæ muscle is retracted medially.
2. The deep aspect of the erector spinæ sheath is incised longitudinally.
3. The quadratus lumborum is retracted medially.
4. The extraperitoneal fat and peritoneum are pushed laterally.

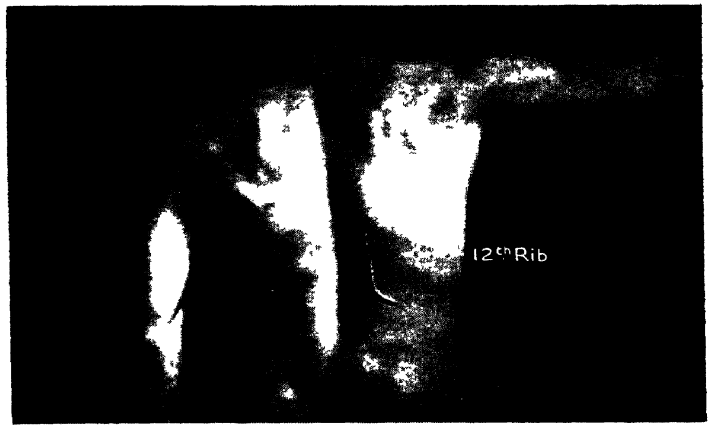

FIG. 460.—Mayo's incision.

5. The fascia of Zückerkandl is torn through, and the perirenal fat is cleaned by blunt dissection from the capsule of the kidney. During these manipulations the twelfth dorsal nerve is carefully preserved.

If more room is required ligaments uniting the twelfth rib to the vertebra are divided, and the twelfth rib is pulled upwards. If still more room is needed the twelfth rib may be excised subperiosteally.

2. **The Anterior Route.**—Transperitoneal approach to the kidney is limited to the removal of immense renal tumours. It should on no account be employed if there be any question of the lesion being infected. The usual incision is a T-shaped one, the vertical limb being over the rectus, and the horizontal limb passing outwards towards the loin. When the peritoneum has been opened, the first step is to mobilise the colon medially by incising the peritoneum over its lateral aspect. By gauze dissection the colon and the attached peritoneum are gently pushed towards the middle line and the kidney is exposed.

The operations upon the kidney are :

1. Nephrectomy.
2. Partial nephrectomy.
3. Nephrotomy—usually nephrolithotomy.
4. Nephrostomy.
5. Nephropexy.
6. Renal decapsulation.
7. Plastic operations upon the renal pelvis.

THE SUPRARENAL BODIES

Calcification of the Suprarenal.—A calcified suprarenal gland is difficult to interpret in an X-ray picture ; it is liable to be confused with a renal calculus. Areas of calcification in the suprarenals have been observed in Addison's disease.

Tumours of the Suprarenal Cortex.—Whether or no certain Grawitz's tumours arise in adrenal rests in the kidney is disputed by some. With that problem we have no concern here, but it is necessary to draw attention to a rare neoplasm occurring in the suprarenal body itself. This tumour arises in the zona fasciculata.

Clinical Features.—Little girls are the usual victims. Puberty is precipitated ; the child of 4 or 5 presents a full growth of pubic hair and well-developed breasts. In the case of a boy of 7, the child was bearded, and had to be shaved daily. Cases of successful removal of the tumour have been reported, but often this neoplasm is very malignant and secondaries soon appear in the liver, spleen, and in bones, notably the skull.

Occasionally tumours of the suprarenal arise in adult life when they are not associated with the above symptoms. A very large suprarenal tumour, which clinically resembled a spleen, was successfully extirpated from a middle-aged woman by C. E. Norbury.

Extirpation of the Left Suprarenal Body.—Le Riche advocates removal of one suprarenal body in the case of hyperadrenalism. The left is chosen because it is more easily removed than the right, which is in the proximity of the inferior vena cava. Left epinephrectomy has been practised in thrombo-angiitis obliterans, in Raynaud's disease, in spontaneous gangrene of the extremities, in epilepsy and in hirsuties in children. The suprarenal body is approached by an incision beneath the twelfth rib, which is resected.

Transplantation of the Suprarenal.—Several cases are on record where a suprarenal gland removed with full aseptic precautions shortly after death has been transplanted into the abdomen of a patient suffering from Addison's disease. This has been followed by a great improvement, even in advanced cases. It is a method which deserves greater recognition.

CHAPTER XXIV

THE BLADDER AND PROSTATE

Acute Retention of Urine

Acute retention is usually, more correctly speaking, acute on chronic retention, for it seldom occurs unheralded.

Ætiology.—While it must be emphasised that the condition is comparatively rare in women and children, the most frequent causes are :

In the male :

Prostatic enlargement.
Urethral stricture.
Acute urethritis.
Tabes dorsalis.

In the female :

Retroverted gravid uterus.
Disseminated sclerosis.
Hysteria.

In the male child :

Atresia of the meatus and phimosis.
Urethral or vesical calculus.

Rarer causes :

Post-operative retention.
Blood-clot in the bladder.
Foreign bodies in the bladder, urethra, or around the penis.
Rupture of the urethra.
Tumours of the bladder.
Spinal injuries and diseases.
Ropy mucus from cystitis.
Muscular atony from advanced age, over-distention of the organ, or certain poisons, notably belladonna.

The patient has not passed urine for some time, and is unable to do so. The full bladder can be made out by palpation and percussion above the symphysis pubis. An

attempt is made to elicit the cause of the retention. The floor of the urethra is palpated for induration of a stricture, the prostate is examined, and the reflexes are tested.

It is of paramount importance never to relieve, or attempt to relieve, acute retention and forthwith send the patient home. He must always be confined to bed immediately, and kept there for at least twenty-four hours after relief has been obtained. Once the patient is at home, or in hospital, if the general condition is good, the effect of administering a dose of morphia and a hot bath is tried. In a proportion

FIG. 461.—Bi-coudé catheter.

of cases the patient is able to pass urine into the bath. If this fails, catheterisation is attempted. This should always be performed with full aseptic ritual. A soft rubber catheter is used; if this is unsuccessful, and the case is one of a suspected enlarged prostate, a large bi-coudé gum-elastic catheter (fig. 461) is tried. On the other hand, should the case be one of stricture, a gum-elastic olivary catheter (fig. 462) is selected.

Once a catheter has entered the distended bladder the urine must be let out slowly, a few ounces at a time. While

FIG. 462.—Olivary catheter.

decompression is in progress the catheter may be fixed temporarily in the urethra, and in order to control the flow of urine a stopper is inserted into its mouth. Four ounces of urine are permitted to escape each hour until the bladder is empty. The catheter is then removed.

Decompression of the bladder can be carried out more evenly and more slowly, which is most desirable, if the mouth of the catheter is connected with a glass U-tube in the manner shown in fig. 465; or even better, with Kidd's U-tube (see fig. 467). The U-tube should be hung up at such a height that urine just trickles over when the patient coughs. If for any reason signs such as drowsiness indicate that the bladder is being emptied too quickly, no time should be lost in partially refilling the organ with normal saline and then starting the decompression anew.

If, after a reasonable attempt with catheters, the bladder has not been entered, one of two courses may be adopted, according to circumstances.

1. **Suprapubic Catheterisation.**—Under nitrous oxide or evipan anæsthesia the front of the distended bladder is exposed by a short suprapubic incision. Into the distended bladder is thrust a Malecot's catheter (fig. 463) stretched upon an introducer of which there are several patterns. Fig. 464 illustrates a simple bladder perforator which permits the catheter to be introduced without allowing the urine to gush

FIG. 463.—Malecot catheter.

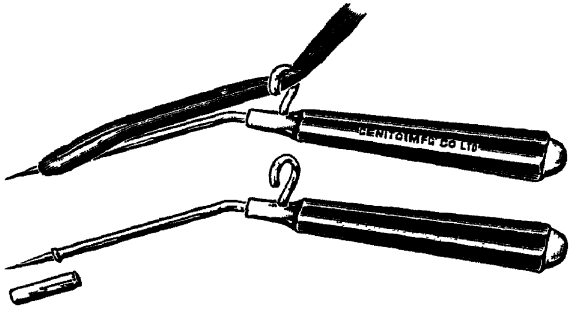

FIG. 464.—Apparatus for inserting a Malecot catheter into the exposed overfull bladder.

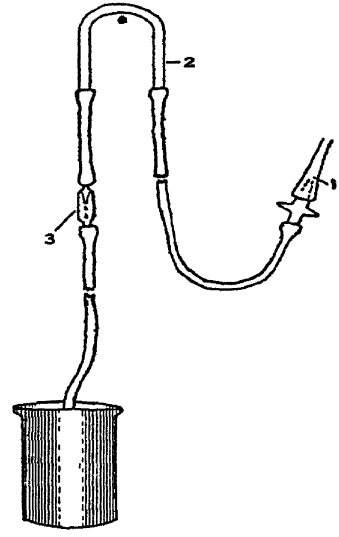

FIG. 465.—Home-made apparatus for decompressing the bladder. 1. Urethral catheter. 2. Glass tube bent in a bunsen flame. 3. A "dropper" from a saline infusion set.

forth. The cave of Retzius is provided with a drain and the wound is then closed. The end of the catheter, which has been clipped, is connected to Kidd's U-tube or to the home-made apparatus detailed in fig. 465. This allows the overfull bladder to be emptied slowly and steadily.

2. **Suprapubic Puncture with a Hollow Needle.**—Suprapubic puncture is a useful method of relieving acute retention when catheterisation has failed or the apparatus for introducing a suprapubic catheter cannot be readily obtained.

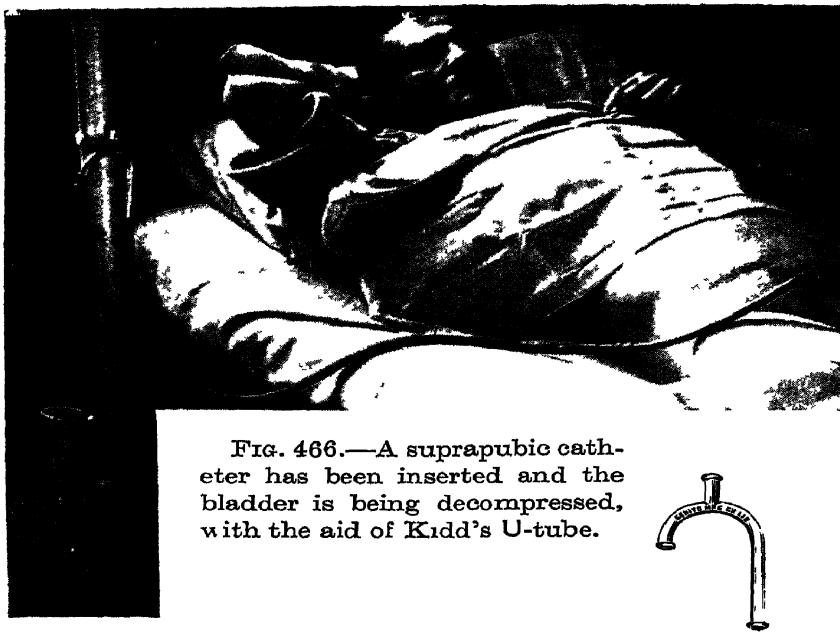

FIG. 466.—A suprapubic catheter has been inserted and the bladder is being decompressed, with the aid of Kidd's U-tube.

FIG. 467.—Kidd's U-tube.

The danger of this method is that if the bladder is allowed to refill after it has been punctured, leakage into the cave of Retzius may occur through the puncture hole. Used as a purely temporary expedient under extenuating circumstances, suprapubic puncture is a sound method of relieving urgent retention of urine.

RETENTION WITH OVERFLOW

Retention with overflow is referred to under the headings of "false incontinence" and "prostatic enlargement." The general principles which govern the treatment of this condition are similar to the foregoing, but decompression of the bladder must be carried out exceedingly slowly. Even so, and in spite of every care, the death-rate in this variety of retention of urine is very high.

INCONTINENCE OF URINE

Incontinence of urine is divided into two main varieties—*false* and *true*.

False Incontinence.—The bladder is full, the dribbling from the meatus being the overflow. False incontinence is observed chiefly in association with chronic retention from an enlarged prostate. It is met with also in some cases of injury or disease of the spinal cord interfering with the centre for micturition.

True incontinence is subdivided into two clinical varieties:

(*a*) The urine dribbles away without further distending the bladder.

(*b*) The bladder becomes partially distended, but the patient exercises inadequate control over the organ.

Type (*a*) is the result of extensive damage to the compressor urethræ. Difficult labour, rupture of the urethra, and perineal prostatectomy account for a certain number of cases. The remainder are due to organic spinal disease.

Type (*b*).—The chief sufferers are women and children.

In Women.—It is not uncommon for women who have borne children to lack complete bladder control. Expulsive acts, such as laughing or sneezing, may be sufficient to cause an escape of urine.

In Children.—This embraces that well-known clinical entity, nocturnal incontinence. The patient wets his bed. By the end of the second year the child should have control of the bladder. The causes of nocturnal incontinence are manifold, and belong properly to the domain of medicine. It is the surgeon's province to eliminate a mechanical cause in the urinary tract—a vesical calculus, cystitis, and a long prepuce are amongst many possible causes of local irritation. Circumcision is often advised, but the results are disappointing. If a thorough urinary investigation reveals no abnormality, the patient should be referred to a physician.

Ectopia Vesicæ

There is congenital absence of the anterior bladder wall. **The Ætiology** is unknown. An ingenious theory suggests

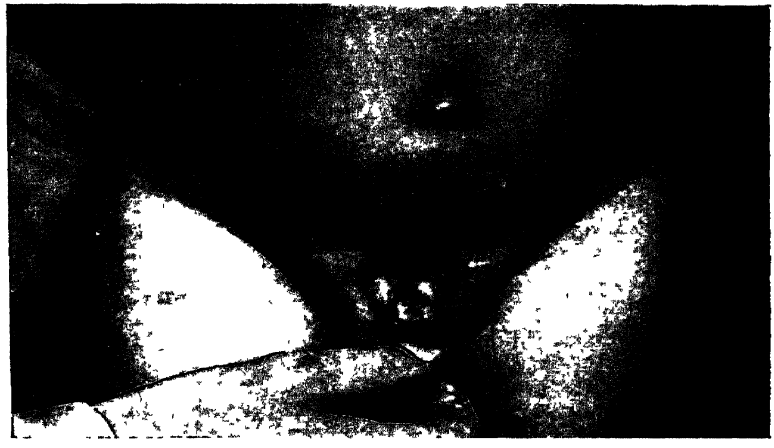

Fig. 468.—Ectopia vesicæ. (Professor Grey Turner.)

that the deformity is the result of intrauterine rupture of the fœtal bladder due to a congenital and complete urethral stricture. Such a theory is satisfying inasmuch as the condition cannot be explained embryologically.

Clinical Features.—The pubic bones do not meet in the middle line, and they are sometimes separated widely. On close inspection of the region it will be found that the upper

FIG. 469.—Showing the separation of the pubes in a case of ectopia vesicæ.

part of the exposed mucous membrane hangs as a fold covering the trigone. When this fold is lifted up the moist trigone will be displayed, and urine can be seen dripping from the ureteric orifices. The subjects of this deformity are stated to be usually males, but before secondary sexual characteristics are in evidence (as the scrotum is rudimentary and the testes intra-abdominal) it is a problem to which sex the patient belongs. Ectopia vesicæ is not a common condition.

Treatment.—The tendency to-day is to recommend operation during childhood. One advantage of this course is, the patient does not spend his school years smelling of urine and in a constant state of pubic irritation and infection.

Many operations have been devised, but most of them are of purely historical interest. The best procedure to-day is that of implanting the ureters into the pelvic colon by Coffey's method.

One ureter can be transplanted at a first operation or both transplanted at the same time. Urinary antiseptics must be administered freely. The constant danger, both immediate and remote, is an ascending infection from the bowel to the kidney, but in practice it is found that patients with ureters opening into the colon are not more prone to ascending infections than those with ureters opening on to the skin. When one compares the life of the patient with a successful transplantation—he is able to hold urine in the rectum for several hours—with that of the untreated, one is bound to favour operation. The best time for its performance is between the ages of 7 and 10 years. If operation is refused, the patient must wear a permanent urinal.

Anomalies of the Urachrus

[See the Umbilicus, p. 437.]

Diverticula of the Bladder

Ætiology.—Small multiple diverticula are sometimes associated with urethral obstruction, e.g. enlarged prostate or stricture. The majority of diverticula, however, are congenital. The predilection for the male sex suggests that the condition may be due to back pressure consequent upon congenital valvular urethral obstruction.

Pathology.—Bladder diverticula may be single or multiple. When multiple they are usually small, and arranged in groups of three or four. More usually they are single, and sometimes reach a large size. Cases are on record where the diverticulum was larger than the bladder itself. The walls of the sac are composed of mucous membrane surrounded by fibrous tissue and fat; they contain no muscle, and consequently cannot contract. Herein lies the chief danger of the condition, for once the urine within the pouch becomes infected, infection persists. This stagnant pool, in spite of all treatment, continues to infect and reinfect the main cavity of the bladder. While a diverticulum may occur in any part of the bladder, the seat of election is near one of the ureteric orifices. Rarely, a ureter opens into the diverticulum itself. The fundus of the diverticulum is frequently adherent to one or other of the pelvic viscera. By traction or pressure the diverticulum often obstructs that ureter in relationship to it, and a hydronephrosis on that side results.

Clinical Features.—The subjects of this condition are usually young men, but the patient may not present himself

until middle life, or later. An immense diverticulum may be felt as a swelling on abdominal examination, but there are usually no pathognomonic features directly referable to a bladder diverticulum. The most usual train of symptoms is intractable cystitis, with attacks of unilateral pyelitis. The diagnosis is made by cystoscopy. The gaping mouth of a diverticulum can be seen (fig. 471). The diagnosis is confirmed by filling the bladder with sodium iodide prior to a

FIG. 470.—Diverticulum of the bladder as shown by cystography.



FIG. 471.—Cystoscopic appearance of the orifice of a diverticulum of the bladder.

radiograph. The resulting cystograph will show the diverticulum (fig. 470).

Complications of a Bladder Diverticulum

1. Pressure on the ureter—hydronephrosis.
2. Infection of the stagnant urine in the diverticulum (common).
3. Calculus formation in the diverticulum.
4. Carcinoma developing from the mucosa lining the diverticulum.

Treatment.—The diverticulum should be excised (fig. 472). If infection has occurred, a preliminary course of treatment directed to mitigate the infection is undertaken.

Operation.—The surface of the bladder is exposed suprapubically. With the patient in high Trendelenburg's position, the diverticulum is



FIG. 472.—Diverticulum of the bladder excised in the case of a man of 29. (⅓ scale.)

dissected, if possible extraperitoneally. In the later stages of the dissection the bladder may be opened, and a finger passed into the pouch to facilitate the dissection of its deep attachments. Transplantation of one ureter may be necessary. When the diverticulum is free it is excised, together with a narrow cuff of the neighbouring bladder wall, which is afterwards approximated with sutures. Suprapubic drainage and drainage of the cave of Retzius completes the operation.

The after-treatment is directed to gently washing out the bladder. Urinary antiseptics will be continued for some months.

VESICO-INTESTINAL FISTULÆ

Ætiology.—A communication between the bladder and the bowel may result in one of the following ways :

1. *Congenital.*—The septum which divided the cloaca into rectum and bladder is incomplete.
2. *Traumatic.*—Penetrating wounds of the rectum.
   Difficult labour.
   Fractured pelvis.
3. *Inflammatory.*—Diverticulitis of the sigmoid.
   Appendix abscess.
   Ulceration around a foreign body in the bladder or the bowel.
4. *Malignant neoplasms* arising in the bowel, or, more rarely, in the bladder.

In addition to intractable cystitis *pneumaturia* is a leading symptom. The patient passes gas per urethram. "Diverticulitis is the commonest cause of pneumaturia" is a good surgical axiom, and serves to remind us that we may be dealing with a remediable condition. By cystoscopy the communication between the bladder and the bowel can sometimes be seen (fig. 473). A barium



FIG. 473.—Cystoscopic view in the case of a vesico-intestinal fistula. Bubbles of gas can be seen issuing from the orifice of the fistula.

meal and enema, also a sigmoidoscopical examination, are essential in most instances before arriving at the correct diagnosis.

Treatment.—In inflammatory conditions an endeavour must be made to separate and repair the two organs. In the case of diverticulitis a preliminary colostomy above the fistula is often advisable. In malignant cases a permanent colostomy will render the patient more comfortable.

Rupture of the Bladder

Rupture of the bladder may be :

Extraperitoneal (20 per cent.).

Intraperitoneal (80 per cent.).

Ætiology

(*a*) *External Violence.*

Blows upon the abdomen with the bladder full, particularly when the patient is inebriated.

As a complication of fractured pelvis.

As an accident in herniotomy, usually the lower operation for femoral hernia, unrecognised at the time.

(*b*) *Internal Violence.*—Lavage of the bladder, especially in old people, has been known to cause rupture when unskilfully performed. The same is true of the evacuator used after litholapaxy. Rupture of the bladder occasionally complicates difficult labour.

(*c*) *Spontaneous rupture* has been recorded in cases of gangrenous cystitis, from pressure of a drainage tube too long retained, and from ulceration of a bladder growth.

In all injuries to the trunk the first point to ascertain is whether the patient has passed urine since the accident. The initial shock in cases of rupture of the bladder may be slight. Many times a patient with this injury has been sent home, and subsequently a necropsy at the coroner's instigation has revealed urine in the peritoneal cavity. Except in utter smashes and perforation by fragments of bone, no rupture is possible unless the bladder is full.

Extraperitoneal Rupture (fig. 474).—Almost invariably, extraperitoneal rupture of the bladder is a complication of a fractured pelvis. Extravasation occurs into the cave of Retzius, causing a tender swelling above the pubes ; later the extravasated urine passes up the anterior abdominal wall between the fascia transversalis and the peritoneum. It is impossible to distinguish this lesion from an intrapelvic

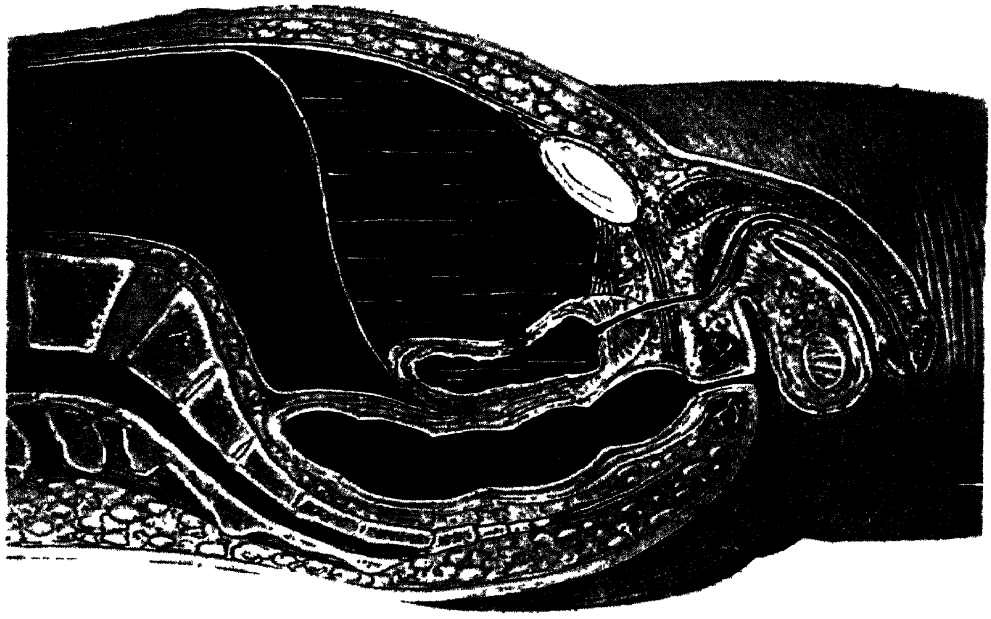

FIG. 474.—Extraperitoneal rupture of the bladder.

rupture of the urethra (*q.v.*) until the parts have been displayed by operation.

Intraperitoneal Rupture.—When an over-distended bladder ruptures, the desire to micturate passes off. If the amount of urine in the peritoneum is considerable, shifting dullness may be elicited. The patient passes little or no urine from the time of the accident, and when he is requested to do so he cannot. If there is delay in repairing the rent, peritonitis is sure to follow.

Investigation.—If a rupture of the bladder is *even suspected* every available means to prove or disprove the integrity of the bladder should be taken *at once*. When facilities are available an excretion pyelogram should be taken, for experience shows that after a few minutes the dye, which has been excreted by the kidneys, casts a good shadow of the bladder. In recorded cases the actual tear in the bladder wall has been visualised by this means. Whether this step has been possible or no, the patient should be

removed to the operating theatre, where all must be in readiness for proceeding with the operation should the diagnosis be confirmed. The operating table is tilted so that any fluid in the peritoneum gravitates into the pelvis. After carefully washing out the urethra, with full aseptic precautions, a catheter is passed. *If the rupture is intraperitoneal* the catheter passes readily, and the bladder will be found to be empty, or nearly so. Eight ounces of boric lotion or saline are allowed to gravitate through the catheter. If all, or a quantity of, the fluid is retained and cannot be recovered through the catheter, the diagnosis of intraperitoneal rupture is confirmed. *If the rupture is extraperitoneal* there is some difficulty in passing the catheter fully into the bladder, and a little blood or blood-stained fluid is withdrawn.

Treatment.—*Intraperitoneal Rupture.*—Lower laparotomy is performed. Urine is mopped up, after which the patient is placed in Trendelenburg's position. The rent is carefully sutured, and the operation completed by stitching a large drainage tube into a suprapubic incision in the bladder. The latter ensures intravesical tension being kept minimal during the healing of the bladder wound. If the case is an early one, the peritoneum may be closed completely, otherwise suprapubic peritoneal drainage is necessary.

Extraperitoneal Rupture.—Suprapubic cystotomy is performed, and the cave of Retzius drained. It is unnecessary to attempt to suture the tear, which heals readily under these circumstances.

Prognosis.—When operation is performed within twelve hours the mortality is approximately 11 per cent.; when operation is delayed to twenty-four hours the mortality rises to 55 per cent. As in the days of ancient Greece, when the condition was regarded as inevitably fatal, without operation the mortality is 100 per cent.

Vesical Calculus

The ætiology and physical characteristics of stone of the bladder are closely associated with those of renal calculus (p. 457).

Clinical Features.—Stone in the bladder is found particularly in children and in the elderly, males being eight times more often affected.

Pain comes on at the end of micturition, and is referred to the tip of the penis.

Frequency is a common, and the earliest, symptom. Unlike other forms of frequent micturition, it is not much in evidence during the night. After passing water the patient does not feel satisfied that the bladder is empty. Such



FIG. 475.—A stone in the bladder as viewed by a cystoscope.



FIG. 476.—The stone which was seen in fig. 475 after removal suprapubically from a girl of 16 (actual size).

symptoms are aggravated by certain jarring movements, such as sitting travelling in a train or bus. If the patient lies down the symptoms tend to pass off, for the stone falls away from the sensitive portion of the bladder, the trigone. Thus he usually sleeps peacefully through the night.

Hœmaturia.—The passage of a few drops of blood at the end of micturition is characteristic, and is due to the stone abrading the vascular trigone—a fact which accounts also for the pain.

Momentary interruption of the stream may be noted, but this is rare. So, also, in the adult, is acute retention from a vesical calculus.

In Children.—Screaming on micturition is a leading

symptom, and acute retention is not uncommon. We have come across cases where small boys have been unjustly chastised for persistent masturbation when stone in the bladder was the cause of the trouble.

Diagnosis of Vesical Calculus.—A large vesical calculus can sometimes be felt per rectum. "Sounding" the bladder has of recent years given place to the more comprehensive method of cystoscopy, whereby the stone is seen (figs. 475 and 476) instead of heard, and the condition of the bladder wall can be noted. Stones in a diverticulum of the bladder, or in a post-prostatic pouch, give few, if any, symptoms referable to the stone. Particularly in cases such as these an X-ray examination may prove valuable.



FIG. 477.—Canny Ryall's cystoscopic lithotrite. Showing stone between jaws of lithotrite.

Treatment.—A stone in the bladder should always be removed. This may be done by:

1. Litholapaxy.
2. Suprapubic cystostomy.

Canny Ryall's cystoscopic lithotrite enables the operator to watch the process of crushing the stone in the bladder (fig. 477), and this is obviously an advance on older methods. After the stone has been broken up, the fragments are removed by suction of an evacuator introduced through the meatus.

Contraindications to litholapaxy fall under three main headings:

Urethra.—Below the age of 10 years it is generally conceded the urethra is too narrow. An enlarged prostate or a urethral stricture also prevents the passage of the instrument with safety. The presence of urethritis would naturally deter the operator from choosing this route.

Bladder.—Considerable cystitis, a small fibrotic bladder, or when the stone is in a diverticulum, would all be conditions in which litholapaxy would be avoided.

The Stone.—A very large stone, a tiny stone, a very hard stone or a soft stone (cystin) are all unsuitable for removal by this method.

Especially in cases where there is an enlarged prostate or considerable cystitis, suprapubic cystostomy will always be advised, in order that the concomitant lesion may be treated also.

Suprapubic cystostomy as a means of removing a vesical calculus is excellent, but the convalescence is longer than that of litholapaxy.

Foreign Bodies in the Bladder

A piece of catheter may become broken off and remain in the bladder. Now that a "catheter life" is led by very few, and will soon be rightly entirely abolished, this accident is becoming a rare one. The variety of foreign bodies which have been removed from the bladder is astonishing. On one occasion we found a manicure stick, the sharp end of which had penetrated the bladder wall. On another occasion a hairpin encrusted with phosphates was removed. Both patients were females. The presence of such objects in the bladder is usually accounted for by sexual perversion.

Complications of a Foreign Body in the Bladder

1. Cystitis.
2. Perforation of the bladder wall.
3. Vesical calculus.

Treatment.—The foreign body should be removed without delay. Except in recent cases, where the object is small the suprapubic route should be chosen. In the exceptional case the body may be extracted by an operating cystoscope.

Cystitis

Cystitis is due to infection of the bladder by bacteria, which usually reach the organ : (1) by descending from the kidney ; (2) by ascending from the urethra.

It is possible that infection is sometimes carried thither by the blood-stream, and some consider that direct migration occurs from the bowel via the lymphatics. Cystitis also occurs when there is a direct communication between the bladder and the bowel (vesico-intestinal fistula, p. 489).

Pathology.—In *acute cystitis* the mucous membrane is red and congested. As a rule the base of the bladder is more

inflamed than the fundus. In ultra-acute cases portions of the mucosa may slough.

In *chronic cystitis* the mucosa becomes thickened, and tends to become covered with muco-pus and phosphates.

Clinical Features.—The three outstanding symptoms of cystitis are :

Pain, which is hypogastric and referred to the penis.

Frequency.

Pyuria.

Cystitis is usually a secondary phenomenon, secondary to urethral obstruction below, or to a pyonephrosis or pyelitis above. This being so, cystitis tends to undergo spontaneous cure if the cause is removed.

Investigation.—The urethra is examined for stricture, and enlargement of the prostate is excluded. A catheter specimen of urine is sent for bacteriological examination. By cystoscopy and excretion pyelography a primary focus in the kidney, or an abnormality of the bladder, such as a diverticulum or a vesico-intestinal fistula, is excluded. Cystoscopy, or any form of instrumentation, will be rigorously avoided in the early stages of an acute attack.

Treatment.—It should be an unwavering rule never to treat a case of cystitis seriously as such until it has been proved that it is not secondary, particularly to a lesion of the kidney.

In acute cases the patient must be put to bed. Plenty of bland fluids should be imbibed. Full doses of tincture of hyoscyamus are soothing, but when the pain is extreme, morphia is necessary. If the urine is acid, an alkaline mixture is prescribed. If alkaline, urotropine and a urinary acidifier are administered. For details of these prescriptions, see p. 468.

Four ounces of liquid paraffin introduced into the bladder through a catheter affords considerable relief when pain is almost intolerable. Its soothing effect lasts for several days.

In *chronic cases*, if the cystitis is secondary, treatment is directed to removing the cause. In primary cystitis treatment by urinary antiseptics is tried. Autogenous vaccines

are helpful. If these measures fail, the advisability of suprapubic cystostomy, which allows irrigation of the bladder and rest to the organ, should be seriously considered.

SPECIAL FORMS OF CYSTITIS

Tuberculous Cystitis.—Primary tuberculous cystitis probably never occurs. Eminent urologists are of the opinion that tuberculous cystitis is invariably secondary to some tuberculous focus in the genito-urinary tract.

Pathology.—Cystoscopy shows that early tuberculosis of the bladder nearly always commences around one ureter or in the neighbourhood of the trigone, which suggests that it is spread from the kidney or the prostate, etc. In long-standing cases there is much fibrosis, and the capacity of the bladder is so much reduced that it has earned the name of "thimble" bladder.

Treatment.—In *early cases*, particularly in those secondary to a tuberculous infection of the kidney, the bladder lesion heals readily once the primary focus has been removed.

In *advanced cases*, where the primary focus is undiscovered or irremovable, there is hardly a more unsatisfactory condition to treat. General treatment and tuberculin may be tried, but local treatment is mainly directed to relieving pain. Rovsing reported favourably on irrigating the bladder with 5 per cent. of phenol until the fluid came away clear, morphia being given to relieve the pain. Suprapubic cystostomy should be avoided as long as possible, for only too often tuberculous ulceration of the wound follows, but in the terminal stages of the disease a de Pezzer catheter sewn into the bladder suprapubically certainly renders the patient's life more tolerable.

B. coli cystitis tends to become chronic with acute exacerbation. Removal of a primary focus, not necessarily directly connected with the genito-urinary system, e.g. a chronically inflamed appendix, sometimes clears up the condition. Otherwise, faith must be placed in urinary antiseptics and an autogenous vaccine.

Typhoid cystitis may complicate the convalescence of an attack of typhoid fever. The treatment is that usual for cystitis, but as the symptoms may abate, yet typhoid bacilli continue to be passed in the urine, it is a public duty to be certain that the patient is bacteriologically, as well as symptomatically, cured.

Hunner's Ulcer (*syn.* Submucous Ulcer of the Bladder, Intramural Cystitis).—This is a clinical entity. The ulcer, if ulcer it may be called, is situated mainly in the submucosa and muscle coats, and often there is little to be seen on cystoscopy except a bleeding pin-point spot. It is somewhat more common in females, and inclines to be situated in the vertex rather than in the base of the bladder. It is always solitary. Ætiology is unknown, but it is thought to be associated with distal focal infection.

The symptoms are those of intractable cystitis. In one of our cases violent hæmaturia had been the principal symptom, and she was admitted with her bladder distended with blood-clot. In some cases it is difficult to distinguish this ulcer, which is inflammatory, from malignant disease, until a piece has been removed for histological examination.

The treatment is difficult. Irrigation of the bladder with mild antiseptics is tried at first. Later, if no improvement occurs, suprapubic cystostomy, combined with cauterisation, is often effective. In long-standing cases, particularly those situated in the vertex of the bladder, complete excision is practicable, and a more certain method of cure.

NEOPLASMS OF THE BLADDER

In the early stages all neoplasms of the bladder give rise to the same symptom—viz. painless, intermittent bright-red hæmaturia. If the hæmorrhage is profuse, clot retention may occur. Except in advanced malignant cases, pain is not in evidence.

Papilloma of the Bladder

In the beginning there is a single papilloma, which bleeds infrequently. If the warning initial hæmorrhages are heeded, the patient will be examined with a cystoscope and the growth will be discovered. It has the appearance of a small, red, sea anemone with waving tentacles, and is usually situated a little above one ureteric orifice. Unless the growth is destroyed, it will steadily increase in size. At the same time, daughter growths make their appearance by a process of "kiss cancer"; that is, an implantation occurs when the mucosa of the empty bladder contracts upon the original papilloma (fig. 478). As time goes on malignant changes are prone to occur. The papilloma becomes a carcinoma, invades the bladder wall, and gives rise to metastases.

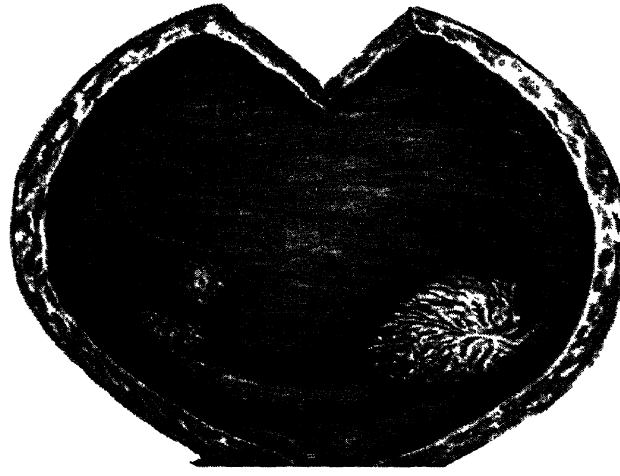

Fig. 478.—Multiple papillomata of the bladder.

Treatment.—*Cysto-diathermy.*—In comparatively early

stages cysto-diathermy is highly satisfactory. The papilloma is destroyed by fulguration applied through an operating cystoscope. With an electrode in contact with the growth, the latter is destroyed by the current. No anæsthetic is required for this treatment, but several sittings are usually necessary.

Excision.—The bladder may be opened suprapubically and the papilloma cut away, together with a small portion of healthy mucosa about its base. This form of treatment is only to be advised in the case of large growths.

BILHARZIA PAPILLOMA

Bilharzia papilloma is caused by a trematode worm, which enters the skin while bathing or standing in infected water. The ova of the adult female are deposited in the mucosa of the bladder and rectum. The ovum is contained in a yellow capsule which has a curved spike on its posterior end (fig. 479), and it is in this form that they are shed continually in the urine and the fæces of the infected. The disease is particularly rife in Lower Egypt, but outside Africa and China bilharziosis is almost unknown. In the bladder, this parasite gives rise to papilloma-like masses. The leading symptom is hæmaturia.

FIG. 479.—A bilharzia ovum.

Treatment.—The intravenous injection of tartar emetic introduced by Christopherson is a notable advance. To commence with, half a grain dissolved in 10 c.c. of normal saline is injected. The dose is increased by half a grain until the maximum of 2½ grains per injection is reached. A dose is given on alternate days until a total of 25 grains of tartar emetic has been administered. This ends a "course" which can be recommenced, if necessary, in a few weeks.

CARCINOMA OF THE BLADDER

Four varieties of carcinoma of the bladder exist:

1. **A malignant papilloma** is the commonest form. Most of these growths have innocent beginnings, as has been shown. They sometimes grow to an enormous size, and fill the whole bladder. On one occasion we removed one malignant papilloma weighing nearly 3 lb. In rapidly enlarging growths their vascular supply is outstripped, and they tend to become necrotic.

2. **The so-called bun-shaped tumour** is pedunculated. A toad-stool would be a more descriptive term. This type of growth is very satisfactory to remove.

3. **A carcinomatous ulcer.**

4. **A rapidly infiltrating growth,** fistulæ into neighbouring organs being a common complication.

It is a truism that if a growth of the bladder can be felt per rectum it is never innocent.

Treatment.—*Partial Cystectomy.*—The bladder is opened suprapubically, and after separating the peritoneum from the bladder, a portion of the whole thickness of the bladder wall, which includes the growth, and a cuff of surrounding healthy tissue is excised. The resulting defect is repaired by interrupted sutures. It is often necessary to transplant one ureter into another part of the bladder, clear of the suture line. Suprapubic drainage of the bladder and drainage of the cave of Retzius is installed.

When, as is unfortunately often the case, the growth invades the trigone extensively, partial cystectomy cannot be performed, and two possible courses are left.

Total Cystectomy.—The ureters are cut near their termination and transplanted into the colon or on to the surface of the skin. A few weeks later the whole bladder is removed. This operation has recently been perfected, and the results are encouraging.

Radium Treatment.—Suprapubic cystotomy is performed, and radium needles are inserted into the growth. The results of radium treatment in this situation is disappointing. The army of radium enthusiasts in vesical carcinoma of a few years ago have dwindled to a corporal's guard.

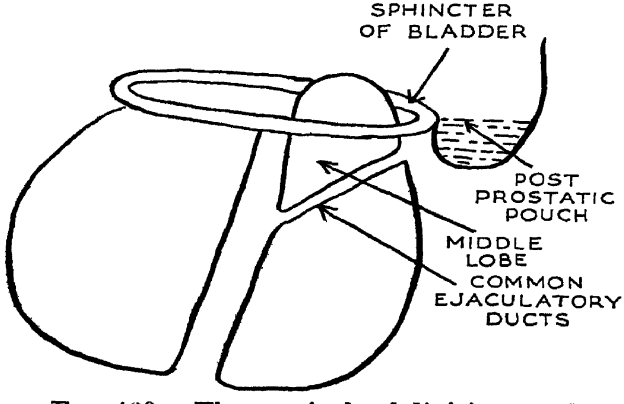

FIG. 480.—The surgical subdivisions and relationships of the prostate.

THE PROSTATE

In the first place it is essential to appreciate clearly certain relationships and divisions of the prostate set out in fig. 480. The middle lobe is

that part of the prostate included between the common ejaculatory ducts and the prostatic urethra. This middle lobe contains more secretory glandular element (as opposed to muscle and fibrous tissue) than the lateral lobes.

Secondary Effects of Prostatic Enlargement

On the Urethra.—The prostatic urethra is often lengthened because of upward growth, particularly of the middle lobe. Owing to fixation where the common ejaculatory ducts

Fig. 481.—Trabeculation of the bladder from prostatic obstruction. (Aschoff.)

pierce it, the elongated urethra tends to become kinked and thereby obstructed.

On the Bladder.—(*a*) The musculature of the bladder hypertrophies to overcome the obstruction. When viewed from within, bands of muscle fibres can be seen standing out—*trabeculation* (fig. 481). Between these hypertrophied bundles there are shallow depressions—potential diverticula, but because they are shallow the process is termed *saccula-*

tion. Unless the obstruction is relieved, a time comes when muscular tone gives out; muscular hypertrophy dwindles, and eventually gives place to atony, the tired muscle making no attempt to overcome the obstruction.

(*b*) *The Post-prostatic Pouch.*—When the middle lobe projects upwards into the bladder it acts as a dam to the last ounce or so of urine, which remains in what is termed the post-prostatic pouch. Uric-acid stones are prone to develop in this stagnant pool of residual urine (fig. 482).

(*c*) The enlarged prostate may compress the prostatic venous plexus, when, by cystoscopy, congested veins can be seen.



FIG. 482.—Calculi in a post-prostatic pouch behind the hypertrophied middle lobe of the prostate as viewed through the cystoscope. (Young.)

On the Kidneys.—All the evils of back pressure leading to bilateral hydronephrosis are at work. At the same time urinary stasis is predisposing to infection of the urinary tract.

On the Sexual Organs.—In the early stages of prostatic enlargement there is increased libido. Later impotence is the rule.

Ætiology of Prostatic Enlargement.—Of many theories which have been propounded, the following is the most practical. Prostatic enlargement is a benign neoplasm. As the prostate is composed essentially of fibrous tissue, muscle tissue, and glandular tissue, the neoplasm is a *fibromyo-adenoma.* It follows that should the glandular element (adenoma) predominate in the neoplasm, that part of the gland which is richest in secretory glandular tissue, to wit, the middle lobe, will be maximally affected. When the fibrous element of the neoplasm is most in evidence, the small, hard fibrous prostate is produced.

Clinical Features.—The patient is always over 50, except in tropical countries, where this disease has been noted as early as the forty-fifth year. It has been computed that

one man in five over the age of 50 has prostatic enlargement, but in only 15 per cent. of those affected are symptoms sufficiently aggravating to impel the patient to seek advice. There are six clinical types of sufferers of enlarged prostate who come for relief:

Type 1.—**Frequency and Dysuria.**—On enquiry the patient states that he finds it useless to strain (cf. urethral stricture, p. 518). Rather, he must first wait patiently with a relaxed abdomen for the stream to start. When it does start, the stream, instead of being projected, tends to fall directly. Frequency of micturition is a regular accompaniment of prostatic enlargement, even in cases uncomplicated by cystitis. A possible reason for this is that in the early stages an enlarged middle lobe acts as a foreign body and irritates the base of the bladder.

Type 2.—**Acute retention of urine** may be the first symptom to impel the patient to seek relief. It often comes on after over-indulgence in alcoholic liquors, particularly on a cold night.

Type 3.—**Retention with Overflow.**—The patient comes complaining that urine is constantly dribbling away. It is exceptional for him to have noticed the swelling caused by the distended bladder, and he experiences no pain.

Type 4.—**Hæmaturia.**—The first symptom may be alarming hæmaturia, due to rupture of a varicose vein at the base of the bladder.

Type 5 (*rare*).—**Uræmia.**—The patient presents himself with one or more of the signs of renal failure.

Type 6.—**Senile sexual hyperactivity** from prostatic irritation has many times landed a previously law-abiding citizen in the police or criminal court.

Treatment.—*Prostatectomy.*—It is of the highest importance that prostatectomy should neither be attempted in the presence of gross infection nor until it has been proved that renal function is adequate. Preliminary ligation and division of the vasa deferentia has banished the troublesome complication of post-operative epididimo orchitis. Attention to these fundamental points has considerably

reduced mortality. There are a variety of operative procedures.

One-stage Suprapubic Prostatectomy (Freyer).—The bladder is opened by a small suprapubic incision, and the prostate gland is enucleated with the finger (fig. 483). Hæmorrhage is controlled by washing out the bladder with hot lotion. Subsequently, the prostatic bed is packed with gauze or a hæmostatic rubber bag is inserted. The bladder is drained.

Two-stage Prostatectomy.—In the first place, suprapubic cystostomy is performed and a de Pezzer's catheter is inserted. At the second stage the prostate is removed, usually by the suprapubic route, but perineal prostatectomy may be performed in suitable cases. Two-stage prostatectomy has a large field of usefulness. It is indicated particularly in those cases complicated by cystitis or deficient renal function. The length of the interval between the two stages depends upon the general and local conditions. The second stage is postponed until the bladder is healthy, the renal function adequate, and the condition of the patient generally warrants undertaking a major operation.



FIG. 483.—An enlarged prostate enucleated by the suprapubic method.

One-stage "Open" Suprapubic Prostatectomy (Thomson-Walker).—The bladder is opened by a much larger incision than the foregoing, and the prostate is enucleated in the usual way. By the insertion of a special retractor the interior of the bladder is now displayed and the prostatic bed inspected. The torn edges of mucous membrane are trimmed, and any large bleeding vessel caught and ligatured. The raw edge at the junction of the prostatic bed with the bladder is encircled with a running hæmostatic suture.

Harris's Operation.—After the prostate has been removed and hæmostasis effected, the prostatic urethra is reconstructed. The bladder is then closed without drainage. A catheter passed from the meatus is left *in situ* for the first few days.

Perineal Prostatectomy (Young).—A special instrument known as a tractor is necessary, in order to draw the prostate towards the perineum. The patient is placed in the exaggerated lithotomy position, and the prostate exposed by a Λ incision. The prostatic

capsule is opened on either side and the gland dissected out. Hæmorrhage is controlled by packing the cavity, or by a hæmostatic bag, and the cavity closed in layers with drainage. This operation is particularly suited to small, fibrous prostates, but is used extensively in certain American clinics.

Transurethral Partial Prostatectomy.—With the prostatic electrotome (fig. 484) strips of the prostate can be excised under vision, leaving a prostatic urethra of adequate calibre. With McCarthy's apparatus hæmorrhage can be controlled by changing the cutting

FIG. 484.—McCarthy's visual prostatic electrotome.

loop for a button electrode. While opinion is not uniform, many consider that transurethral resection should be reserved for median bar obstruction, small fibrous prostates, and cases of incurable malignant disease—for by this method a part only of the neoplasm is removed.

RESULTS AND COMPLICATIONS OF PROSTATECTOMY

The mortality of prostatectomy has fallen steadily during the past twenty-five years. It now stands at about 5 to 7 per cent. for all cases, although a lower figure can be shown by surgeons especially experienced. In a series of 82 patients prostatectomised by Sir Peter Freyer, 31 lived ten years or longer and several attained the age of 90.

Immediate Complications.—*Hæmorrhage.*—Methods of controlling post-operative hæmorrhage have been alluded to.

Uræmia.—Prostatectomy should never be performed until the renal function has been proved to be adequate.

Post-operative Pneumonia and Cardiac Failure.—Local, spinal, and gas-oxygen anæsthesia have helped to minimise these complications.

Pulmonary Embolus.

Remote Complications.—*Post-operative stricture*, due to the formation of a shelf of scar tissue around the prostatic bed.

Incontinence of Urine.—Damage to the compressor urethræ during the perineal operation.

Urinary Fistula.—Either suprapubic or perineal, according to the type of operation.

Palliative Methods.—*Catheter Life.*—The dangers of repeated catheterisation, especially when performed by the patient himself, are far greater than a well-planned operation. To-day it is difficult to imagine any combination of circumstances which would incline a medical adviser to recommend a patient to lead a catheter life.

Permanent Suprapubic Drainage.—Attention has been called already to the value of suprapubic drainage as a preliminary measure. It may be months before the patient

is fit for the second stage. In the exceptional case, the second stage is postponed indefinitely. Permanent suprapubic drainage is preferable to a catheter life.

Other Methods.—From time to time reports are published of good results in cases of prostatic enlargement following non-operative measures. Amongst these are the application of X-rays, diathermy, and the administration of testicular extract and other hormones. In many cases some improvement apparently occurs, but only too often the postponed operation has to be undertaken eventually, and by this time under less favourable circumstances.

Contracture of the Neck of the Bladder

Contracture of the neck of the bladder is a common sequel of chronic cystitis, and gives rise to symptoms akin to prostatic enlargement. "Prostatism without enlargement of the prostate" is the key-note of the situation. Pathologically there may be circular cicatricial stenosis of the internal urinary meatus, or more commonly a *median bar*. The latter is a transverse ridge of fibrous and muscular tissue across the posterior edge of the internal meatus (fig. 485).



Fig. 485.—A median bar causing prostatic obstruction. (Young.)

Treatment.—The circular variety yields to regular dilatation with a curved Kollman's dilator. The prostatic bar is best removed by transurethral resection.

MALIGNANT DISEASE OF THE PROSTATE

Carcinoma

About 16 per cent. of all cases of enlarged prostate are carcinomatous. Like simple enlargement, cases of carcinoma of the prostate may be divided into various types met with in practice.

1. **The "Pathological."**—On histological examination of an apparently simple enlarged prostate which has been removed, it is found that a small percentage are carcinomatous. Perhaps 2 to 5 per cent. of all enucleated prostates are found to belong to this group.

2. **The Scirrhus.**—When examined per rectum the prostate feels stony-hard and irregular. The diagnosis is irrefutably confirmed when the bladder has been opened. From within the irregularity of the organ usually leaves no doubt as to the nature of the neoplasm.

3. **The Encephaloid.**—This variety was called by Guyon "pelvo-prostatic carcinoma." It infiltrates the pelvis rapidly, and mats the pelvic viscera into a conglomerated mass.

4. **The "Hidden."**—The first manifestation is a secondary growth in bone, perhaps complicated by spontaneous fracture. The vertebræ are most frequently affected, then the femur, os innominatum, ribs, sternum, and the remainder of the bones of the limbs.

In general the symptoms of carcinoma of the prostate are similar to those of simple enlargement, but pain is more in evidence. The pain is constant, and not definitely connected with micturition or defæcation, although it may be increased by both. In type 3 intractable sciatica is sometimes a leading feature.

Treatment.—The prognosis in carcinoma of the prostate is very poor, for usually the disease is advanced before the patient seeks relief. Radium has been tried without much success.

Excision of the prostate and its capsule has been performed in cases of carcinoma of the organ with some

success by Young and others. The mortality of this severe operation is considerable. Recurrence within two years is the rule in those who survive.

SARCOMA

Sarcoma of the prostate is so rare as to be of little practical importance. It usually occurs in boys, and must be distinguished from a large vesical calculus, with which it has been confused. The prognosis is practically hopeless.

Prostatitis

Acute prostatitis often complicates gonorrhœa, but sometimes it has nothing to do with a venereal infection. *B. coli* prostatitis attacks men who are run down and overworked; we have known several cases amongst the residents of hospital staffs. In severe cases acute prostatitis is ushered in with rigors, thirst, and much general malaise. The temperature is usually high. Dysuria and frequency are the rule, and acute retention may occur. In very acute cases a few drops of blood-stained urine are sometimes passed at the end of micturition. The diagnosis is seldom easy, the key to the situation being a rectal examination, when a hot, swollen, tender prostate will be discovered.

Treatment.—The patient is strictly confined to bed. Urinary antiseptics and antispasmodics are ordered. Hot rectal douches are prescribed by some, but they are painful. If acute retention supervenes, and is unrelieved by morphia and hypogastric fomentations, the question of the advisability of inserting a suprapubic catheter will arise, for urethral catheterisation aggravates the condition.

Prostatic Abscess

Prostatic abscess is a complication of the foregoing. Frequently a prostatic abscess bursts spontaneously into the urethra. Sometimes the abscess can be felt pointing into the rectum. It should not be allowed to burst posteriorly, for a urethro-rectal fistula is an unpleasant complication. A prostatic abscess should be drained through an incision in the perineum.

Chronic prostatitis is nearly always an aftermath of gonorrhœa. The symptoms are variable, and may be comparatively slight.

Frequency of micturition, scalding during the act, a heavy pain in the perineum, pain on defæcation or coitus are among the frequent complaints. Prostatorrhœa is sometimes in evidence, and also repeated nocturnal emissions. Neurasthenia is prone to complicate the case. Toxic symptoms—pains in muscles and joints—and general debility are not infrequent. Actual gonococcal rheumatism and gonococcal arthritis are recognised complications of chronic gonococcal prostatitis. The diagnosis is confirmed by prostatic massage, which has been preceded by washing out the anterior urethra. In chronic prostatitis "prostatic" threads and a muco-purulent exudate are expelled by the massage, and because the urethra has been washed out, we know that this discharge must have come from the prostate. The discharge is examined microscopically, but repeated examination may be necessary before the causative organism is found.

Treatment consists of posterior urethral irrigation and regular prostatic massage, combined with tonics, and general hygienic measures. Vaccines may be tried, but are disappointing. The condition is rebellious to treatment, and relapses are common.

Tuberculous Prostatitis.—Tuberculosis of the prostate is seldom, if ever, primary. It is an extension of tuberculosis in some other portion of the genito-urinary tract. The diagnosis rests upon finding hard tuberculous nodes in the prostatic gland. The treatment is directed to the original lesion, but only too often, by the time the prostate is involved, wide tuberculous dissemination through the genito-urinary system has taken place.

Prostatic Calculi

Prostatic calculi may originate in the gland or in the prostatic urethra.

Calculi originating in the Gland.—In many cases multiple prostatic calculi commence as calcification of copora amylacea.

Calculi originating in the Prostatic Urethra probably have their beginning in the kidney or bladder, and migrate, to become arrested in the prostatic urethra, where they continue to increase in size.

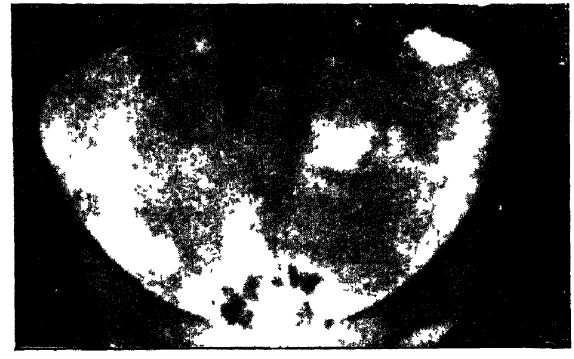

Fig. 486.—Multiple prostatic calculi. The most characteristic radiological finding is that the cluster of small stones is arranged in the form of a horse-shoe or ring (Swift Joly.)

Clinical features are often obscure, and

simulate, in some respects, prostatic enlargement. On rectal examination the stone or stones may be felt in the prostate. Multiple prostatic calculi have often been mistaken for carcinoma of the organ, and if there is the slightest doubt as to the latter diagnosis an X-ray is essential (fig. 486). Prostatic calculi are rich in calcium, and cast a good shadow.

Treatment.—The stone should be removed, either by way of the suprapubic or the perineal routes. They can also be dislodged by transurethral resection (p. 505). In some cases, where the calculi are embedded in the gland, the prostate is better removed.

CHAPTER XXV

THE URETHRA AND PENIS

THE DEVELOPMENT OF THE URETHRA

FROM the internal urinary meatus to the sinus pocularis the urethra is developed from the urogenital sinus. This portion of the male urethra corresponds to the entire female urethra. From the sinus pocularis (uterus masculinus) to the fossa navicularis the male urethra is derived from the medial labial folds, which also form the corpus spongiosum (fig. 487). The urethra traversing the glans is the last to be developed, and is formed by the downgrowth of a solid pencil of epiblast, which becomes canalised shortly before birth.

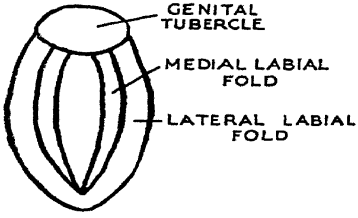

FIG. 487.—Arrangement of the uro-genital cleft and surrounding parts at the end of the second month The male and female external genitals are undifferentiated until the end of the *third* month.

CONGENITAL ABNORMALITIES OF THE URETHRA

Pin-hole Meatus.—Meatotomy is indicated. An injection of local anæsthesia is made into the glans immediately below the meatus, which is enlarged by a cut in a downward direction. A metal sound of suitable calibre is passed into the meatus each day for four or five days, and weekly dilatation for a month must be practised.

Congenital Strictures and Valves.—Congenital strictures occur particularly at the points where the developmental component parts of the urethra fuse. Thus they are found in the region of the sinus pocularis and the fossa navicularis. If the stricture is complete, or nearly so, the infant dies soon after birth, and necropsy shows bilateral hydronephrosis. Congenital strictures of moderate calibre are occasionally met with in infancy and childhood, and give rise to a train of ill-health, predisposition to attacks of

recurrent pyelitis, and sometimes a fatal termination from uræmia. The most puzzling variety of congenital stricture takes the form of symmetrical valves, which allow the ingress of a sound, but obstruct the outflow of urine. Congenital strictures are not excessively rare, but have only been recognised in recent years. The treatment follows that of strictures in general. The valves have been successfully excised with an electro-cautery through an endoscope.

Hypospadias

Hypospadias is the commonest congenital malformation of the urethra, and it occurs once in every 350 males (Mayo). Hypospadia glandis is its most frequent variety, and is due to a failure of tunnelisation of the glans (see embryology).

The external meatus is situated at some point upon the *under* surface of the penis (fig. 488) or in the perineum.

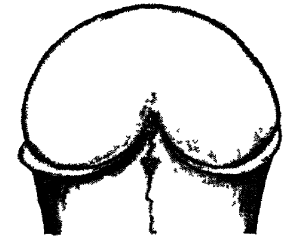

Fig. 488. — Hypospadia glandis. The external urinary meatus is situated in the floor of the urethra.

There are three varieties :

1. Hypospadia glandis.
2. Hypospadia penis.
3. Hypospadia perinealis.

Clinical Features. — The penis is often curved downwards, and atresia of the external abnormal urinary meatus is a frequent accompaniment. Gonorrhœa seems to occur more readily in patients with glandular hypospadias than in those with a normal penis. When the urethra is situated far back, the patient has to sit down to micturate. In these cases the possibility of contracting gonorrhœa is small, as also is the chance of the patient becoming a father.

Treatment.—If relief is sought only because of narrowing of the meatus, meatotomy, if combined with regular dilatation, is satisfactory. Plastic operations to restore the anatomy of the part can be undertaken. There are a variety of such operative procedures, and the cosmetic and utilitarian results are often excellent.

Epispadias

Unlike hypospadias, epispadias is exceedingly rare. There are epispadia glandis, epispadia penis, and epispadia totalis, which is usually associated with ectopia vesicæ. Epispadia glandis is the rarest type of this rare malformation. The urethral orifice is situated on

the dorsum, and the penis is usually curved upwards. Plastic operations to rectify the twist and restore normality can be undertaken.

RUPTURE OF THE URETHRA

Rupture of the urethra is divided into two great classes—rupture of the bulbous urethra, and rupture of the membranous urethra (fig. 489). Each is again redivided into complete and incomplete.

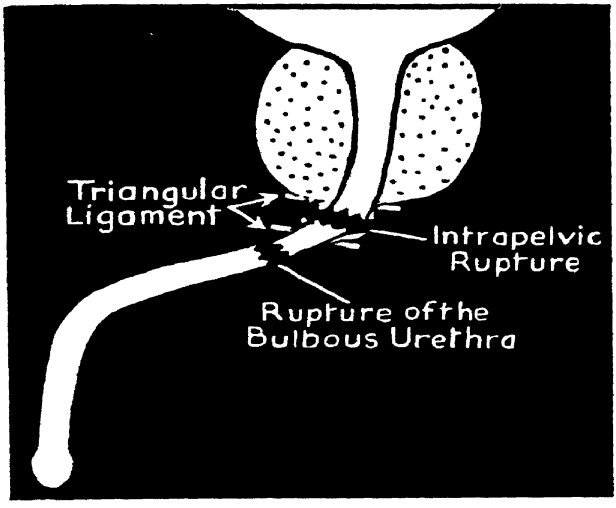

FIG. 489.—Showing the two distinct varieties of rupture of the urethra.

RUPTURE OF THE BULBOUS URETHRA

Rupture of the bulbous urethra is the more common accident. Almost without exception there is a history of a fall astride upon a projecting object.

Clinical Features.—The triad of signs of a ruptured bulbous urethra are urethral hæmorrhage, a perineal hæmatoma, and retention of urine, to which may be added a fourth—pain.

Preliminary Treatment and Investigation.—If the accident is suspected, in order to prevent the possibility of extravasation, the patient should be told not even to try to pass urine. No attempt should be made to catheterise him until he is in the operating theatre, where asepsis can be assured, and operation can be undertaken in necessary cases. When circumstances are extenuating, and the bladder is full, it should be emptied by suprapubic puncture until the patient can be admitted to a surgical service, where the following investigation is undertaken. The urethra is carefully washed out, and a bi-coudé catheter of moderate size passed along

the penile urethra, the beak of the catheter being directed strictly to the *roof* of the urethra. An attempt is made to pass the catheter gently through the damaged bulbous urethra.

If the rupture is incomplete the catheter will pass onwards into the bladder.

If the rupture is complete the catheter cannot be passed farther than the bulb, and its arrest synchronises with a flow of blood.

Treatment.—*Incomplete Rupture.*—Formerly a catheter was tied in, but so often did a stricture follow that this method, which yields good immediate results, has been given up. It is now agreed that a better method is to perform perineal section, thereby draining the urethra behind the rupture, and resting it during the process of natural repair.

Complete Rupture.—Immediate operation is imperative. The bladder is opened suprapubically, and a bougie passed into the internal urinary meatus. This permits the posterior end of the urethra being found during the next stage of the operation, which is: lithotomy position, incising the perineum directly in the middle line, locating the ends of the torn urethra, and uniting its roof. The wound is then lightly packed, and a de Pezzer catheter is sewn into the suprapubic cystotomy wound. The perineal wound and the floor of the urethra heals by granulation, and on the fourteenth day one well-lubricated Lister's sound is passed from the meatus. If the sound enters the bladder readily, the suprapubic drainage tube is removed.

Complications of Rupture of the Bulbous Urethra

Subcutaneous extravasation of urine occurs in complete rupture if the patient attempts to pass urine (see p. 517).

Stricture.—This common complication is largely due to superadded sepsis, often introduced by attempts to pass a catheter or tying in a catheter in cases of incomplete rupture.

Both these complications are largely preventable, and in this connection it is well to bear in mind the words of Rutherford Morison: "Rupture of the urethra is one of the most serious of accidents, and unless your skill can prevent

the development of a stricture, you are presiding at the opening of a life-long tragedy."

Intrapelvic Rupture of the Urethra

Intrapelvic rupture of the urethra is almost always accompanied by a fractured pelvis. A reference to fig. 490

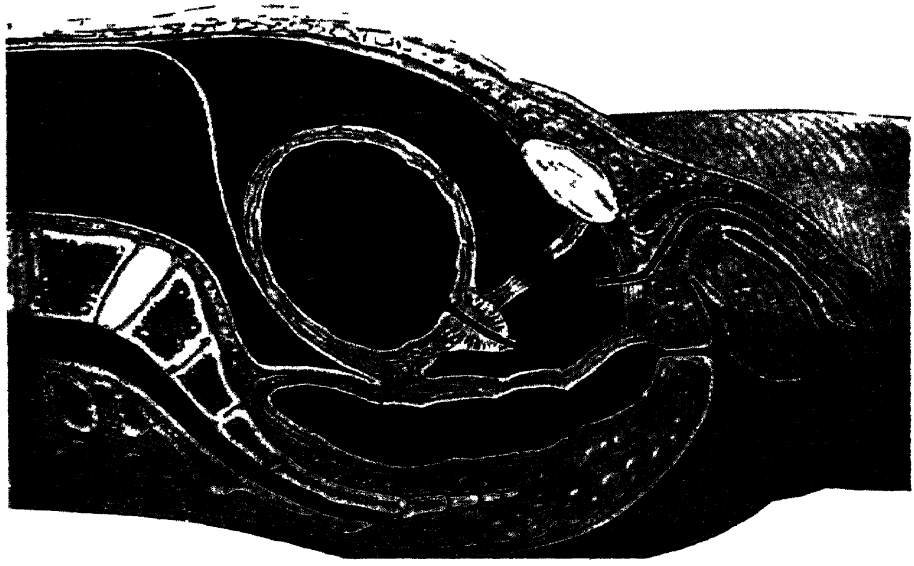

Fig. 490.—Intrapelvic rupture of the urethra. Note the rotation of the bladder backwards, due to the tearing of the pubo-prostatic ligaments.

shows the usual state of affairs. The pubo-prostatic ligaments are torn, and as a consequence the ends of the divided urethra are widely separated. It can be seen also that extravasation occurs into the pelvic fascia.

Diagnosis.—The signs of a fractured pelvis are usually evident. The patient has not passed urine since the accident, and the escape of blood from the meatus is a common occurrence. Extravasation occurs early into the pelvic fascia, and on examination a swelling may be felt in the hypogastrium.

Treatment.—The investigation of the case, as in the preceding type, should be undertaken in the operating theatre whenever possible. One should be mindful lest the passage of the catheter into the prevesical space and the withdrawal of a

few ounces of blood-stained urine from this situation should be mistaken for an entry into the bladder. The operation is commenced by making a suprapubic incision which opens up the cave of Retzius. As a rule it is only after this has been done that it is possible to distinguish between an extraperitoneal tear of the bladder (p. 490) and an

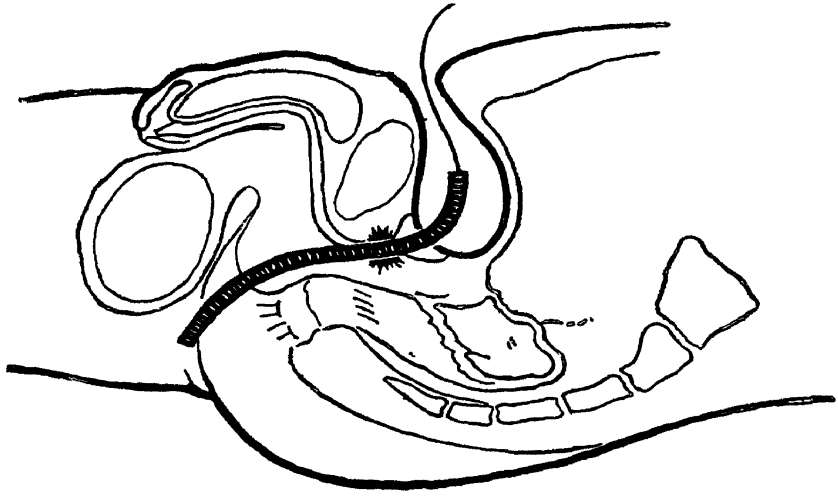

FIG. 491.—Complete intrapelvic rupture of the urethra. Backward displacement of the neck of the bladder corrected by an indwelling catheter. Note the silk attached to the catheter to facilitate changing.

intrapelvic rupture of the urethra. The guiding rule is, if the bladder is even moderately distended, the lesion must be situated below the vesical sphincter. Thus the diagnosis of intrapelvic rupture of the urethra is confirmed.

Direct suture of the urethra is out of the question, yet it is imperative to bring into direct apposition the widely separated ends of the urethra. This can be accomplished by inserting a retrograde catheter, and bringing it out in the perineum or if possible at the external urinary meatus (fig. 491). If a thread is attached to the vesical end of the catheter, it may be changed at regular intervals by the "railroad" method. Curiously, the membranous urethra does not show the same tendency to stricture formation as the bulbous, and the objection to the indwelling catheter,

which in this case is the only feasible method of treatment, is overruled.

Complications

Shock is much more pronounced than in rupture of the bulb, and this is due to the concomitant fracture of the pelvis.

Occlusion of the Urethra.—If the ends of the urethra are not approximated, the neck of the bladder and prostate become anchored in the position shown in fig. 490. This is not a stricture in the ordinary sense of the word—it is far worse—for the continuity of the urethra is interrupted for ever, and the patient doomed to a permanent suprapubic fistula.

Extravasation of Urine

The extravasation may be superficial or deep.

Superficial extravasation occurs in neglected cases of rupture of the bulbous urethra, and as a complication of periurethral abscess. The latter occurs at least twice as often as the former.

The extravasated urine cannot pass (1) behind the middle perineal point, because of the fusion of Colles's fascia with the anterior triangular ligament ; (2) into the thighs, for Scarpa's fascia blends with the pubic portion of the fascia lata just distal to Poupart's ligament ; (3) into the inguinal region, because of the inter-columnar fibres and fascia of the external oblique.

It therefore must pass (1) into the scrotum ; (2) into the subcutaneous tissues of the penis ; (3) up the abdominal wall in the subcutaneous planes.

In superficial extravasation a black patch on the glans penis is a harbinger of death (Sir Benjamin Brodie).

Treatment.— *In the Case of Extravasation Complicating Ruptures of the Bulbous Urethra.*—Multiple incisions are made of sufficient depth to penetrate the limiting fascia. By the time extravasation has occurred it is unlikely that the urethra can be repaired in the way described already (p. 514), for the sutures would simply cut out. It is therefore often advisable to adopt the sutureless operation of

Rutherford, which consists of opening the bladder, passing a retrograde catheter, followed by perineal section. A catheter is introduced from the meatus to the bladder, and the perineal wound is left widely open.

In the Case of Extravasation Complicating Periurethral Abscess.—Multiple incisions as above are made, and the bladder is drained by opening the urethra in the perineum behind the stricture.

Deep extravasation occurs in the case of extraperitoneal rupture of the bladder, rupture of the ureter, intrapelvic rupture of the urethra, and after suprapubic puncture, when the bladder has been allowed to refill. The urine spreads in the layers of the pelvic fascia, or in the retroperitoneal tissues.

Treatment.—When extravasation is proceeding from the bladder, it is necessary to drain the cave of Retzius, and to perform suprapubic cystostomy. The treatment of the various conditions which are associated with deep extravasation are considered in their appropriate sections.

URETHRAL STRICTURE

Urethral strictures are conveniently divided into the following varieties :

1. Congenital.
2. Post-gonorrhœal.
3. Traumatic.
4. Post-operative (following prostatectomy or amputation of the penis).
5. Pseudo-stricture { congestive. / spasmodic.

Post-gonorrhœal stricture constitutes fully 90 per cent. of all cases. The stricture may be in any part of the anterior urethra, but is most frequently situated (*a*) in the bulb ; (*b*) at the peno-scrotal junction ; (*c*) in the distal end of the spongy urethra, in that order. Multiple strictures are very frequent, and in a urethroscopic study of 87 consecutive cases we found that in over 30 per cent. the stricture was triple.

Clinical Features.—The leading symptom is dysuria. In contradistinction to prostatic obstruction, the patient finds he must strain to empty the bladder. Another distinguishing feature is the patient's age. He is often considerably younger than the prostatic sufferer, or the symptoms of dysuria date back to some time prior to the fiftieth



FIG. 492.—Urethroscopic appearances (*a*) Fine-bore stricture. (*b*) Moderate-bore stricture. (*c*) Crescentic stricture of the roof. (*d*) Stricture with false passage.

year. Diminution of the calibre of the stream of urine is an infrequent and unreliable symptom. In long-standing cases it is often possible to palpate the stricture from without as an induration in the urethral floor. The evil effects of urethral obstruction upon the bladder, ureters, and kidneys are similar to those of prostatic obstruction, and consequently it is unnecessary to reiterate them.

Urethroscopy.—Aero-urethroscopy has revolutionised the diagnosis of urethral stricture. Under air inflation of the urethra the stricture can be seen as a white scar of fibrous tissue, and its position in the urethra, the size of its contained lumen, and its dilatability can be judged (fig. 492). Often a stricture encircles the whole urethra, and the lumen is more or less centrally placed, but from time to time a variety of urethroscopic appearances are noted in individual cases; for instance, the stricture may take the form of a crescent.

False passages may be seen. They are recent penetrations of the urethra in front of the stricture due to unskilful attempts to pass a sound. False passages are particularly liable to bleed, and it is of paramount importance to cease urethroscopy if urethral hæmorrhage occurs, for fatal air embolus has resulted from air being pumped into the cavernous tissue through a urethral wound.

Treatment.—Dilatation.—Regular dilatation is a satisfactory form of treatment in the majority of instances, providing the patient attends regularly for treatment. Few, if any, urethral strictures are impassable, but it often requires patience to insinuate even the finest urethral guide. Dilatation should be carried out under local anæsthesia, induced by an instillation of borocaine into the urethra. The variety of instruments available is bewildering. We will confine our attention to four patterns which are especially useful.

(*a*) *Gum-elastic bougies* (French bougies) (fig. 493) should be the standard instruments in the early stages of treatment of all but the very finest strictures.

FIG. 493.—Gum-elastic bougie.

(*b*) *Lister's metal sounds* (English bougies) (fig. 494) are indicated after the second or third attendance of the patient, when it has been proved that the stricture is responding to

FIG. 494.—Lister's metal sound.

dilatation by the French bougies. There is no occasion ever to use the small-gauge Lister's sounds, $\frac{7}{9}$ being the smallest instrument we employ. Slender metal instruments are dangerous and unnecessary.

(*c*) *Kollman's dilator* (fig. 495) is used in the last stages of treatment to over-dilate the stricture. This instrument is also particularly useful in post-prostatic strictures. The illustration shows a curved Kollman's dilator. The straight pattern is used for strictures placed more anteriorly.



FIG. 495.—Kollman's curved urethral dilator.

Local anæsthesia must never be employed when the Kollman's dilators are used for fear of tearing the urethra.

(*d*) *Filiform bougies* are useful in very fine strictures. One can be passed under visual guidance by the operating urethroscope, or a number can be used by what is known as the "faggot" method (fig. 496).

Gradual dilatation at weekly intervals is the only form now generally employed. Continuous dilatation, whereby an instrument was tied in for twenty-four hours and then replaced by a larger one, always predisposes to infection. Before each dilatation the meatus is cleansed, and the anterior urethra washed out. In days gone by rigors commonly followed instrumentation; if the dilatation is performed aseptically, rigors are exceptional.[1]



FIG. 496.—"Faggot" method of introducing bougies through a stricture.

"Once a stricture, always a stricture" is an old surgical axiom. During a course of treatment the interval between attendance can be lengthened until finally, in favourable cases, the patient attends but once a year. A few strictures are cured by over-dilatation, but in the majority the patients must be kept under supervision for the remainder of their lives.

Internal urethrotomy is indicated, in the opinion of many, when the stricture or strictures are fine, and do not respond satisfactorily to dilatation. Before internal urethrotomy is undertaken, renal function must be tested and proved satisfactory, and the operation should never be performed in the presence of sepsis.



FIG. 497.—Thomson-Walker's urethrotome.

[1] Catheter and bougie gauges. The English gauge is an arbitrary one, and much confusion reigned until the Surgical Instrument Manufacturers' Association agreed upon a standard English catheter scale. Bougies apparently are not regularised in this way, and are variously numbered, viz. $\frac{8}{10}$ by some firms, $\frac{8}{11}$ by others.

Operation.—A fine urethral guide, "the pilot," is passed, in difficult cases preferably *before* the patient is anæsthetised. To the base of the pilot the urethrotome is attached by means of a screw. When the instrument is in place, the pilot curls up in the bladder. Along the groove in the urethrotome (fig. 497) the knife is passed and the stricture divided.

FIG. 498.—Mobilising the corpus spongiosum.

Excision of a Stricture.—Excision is indicated, particularly in long-standing, very indurated, solitary strictures in the bulb, especially those connected with a urethral fistula. Through a suitable incision upon the floor of the urethra, that part of the urethra containing the stricture is excised completely. The corpus spongiosum is mobilised (fig. 498) a short distance anteriorly, and this allows approximation of the cut ends of the urethra, which are united in a manner similar to that advised in complete traumatic rupture.

External Urethrotomy.—The principle of the operation is the division of the stricture through an external incision. This method, we consider, is seldom indicated. It is inferior to internal urethrotomy in that the convalescence is much longer, and only one stricture can be divided, whereas in many cases which require operation the stricture is triple. Lastly, even those with considerable experience in passing bougies sometimes find it difficult to pass instruments after external urethrotomy has been performed—the beak seems to get caught up in the perineum.

Rarer Forms of Urethral Stricture

Congenital stricture has been considered on p. 511.

Traumatic stricture follows unskilful or delayed treatment of rupture of the bulbous urethra. If dilatation is unsatisfactory, the question of excision of the stricture should arise, especially in boys.

The so-called stricture following rupture of the membranous urethra is often not a stricture at all, but a complete loss of continuity of the urethra (see fig. 490), and any form of treatment short of implanting the ureters into the bowel is hopeless. Prevention is the cure.

"**Post-prostatic**" **stricture** occasionally follows suprapubic prostatectomy. It is due to the formation of a shelf by prostatic capsule across the bed previously occupied by the prostate. The treatment in early cases is regular dilatation with the curved Kollman's dilator. In a number of cases the shelf must be excised by reopening the bladder.

Post-operative stricture occasionally follows partial or complete amputation of the penis. Methods of avoiding this complication are given in the section dealing with these operations. Regular dilatation is satisfactory.

Pseudo-stricture.—The so-called spasmodic and congestive strictures are symptomatic as opposed to organic, and it is doubtful if they should be classified as strictures, but this is conventional.

Congestive stricture is due to œdema of the urethra, and is a complication of acute urethritis.

Spasmodic stricture is due to spasm of the compressor urethra. It may occur reflexly after abdominal or pelvic operations.

Complications of Urethral Stricture

Retention of urine (p. 481).

Periurethral abscess (p. 524).

Urethral fistula (p. 524).

Urethral pouch (p. 525).

All the attendant evils of "back pressure," culminating in bilateral hydronephrosis, combined with a susceptibility to urinary infection and an increased liability to urinary calculus.

Hernia, hæmorrhoids, or rectal prolapse may be induced by the straining.

Operation.—A fine urethral guide, "the pilot," is passed, in difficult cases preferably *before* the patient is anæsthetised. To the base of the pilot the urethrotome is attached by means of a screw. When the instrument is in place, the pilot curls up in the bladder. Along the groove in the urethrotome (fig. 497) the knife is passed and the stricture divided.

FIG. 498.—Mobilising the corpus spongiosum.

Excision of a Stricture.—Excision is indicated, particularly in long-standing, very indurated, solitary strictures in the bulb, especially those connected with a urethral fistula. Through a suitable incision upon the floor of the urethra, that part of the urethra containing the stricture is excised completely. The corpus spongiosum is mobilised (fig. 498) a short distance anteriorly, and this allows approximation of the cut ends of the urethra, which are united in a manner similar to that advised in complete traumatic rupture.

stones, which are always phosphatic, may remain latent for long periods. The diagnosis is made by palpation from without, or, in the case of the deep urethra, by rectal examination. Urethroscopic and X-ray examinations are confirmatory aids to diagnosis in obscure cases.

Treatment.—A migrating calculus arrested in the prostatic urethra can usually be pushed into the bladder by a catheter, and there treated as a vesical calculus. A calculus arrested in the fossa navicularis is often expelled easily after meatotomy has been performed. A fixed calculus in the prostatic or membranous urethra requires perineal section for its extraction. Calculi in the penile urethra can sometimes be extracted by urethral forceps. When a stricture is present an incision in the urethral floor is often necessary, and through this the stone may be removed and the stricture divided.

URETHRAL DIVERTICULA

Urethral diverticula are of three varieties:

Congenital.

Due to increased intraurethral pressure behind the stricture.

Due to the long-continued presence of a urethral calculus.

In some cases it is a moot point whether the stone forms in a pre-existing diverticulum, or whether the pouch is the result of the urethral stone (fig. 500). In many cases the pouch can be seen, and those which are not obvious at first become so when the patient interrupts the stream of urine.

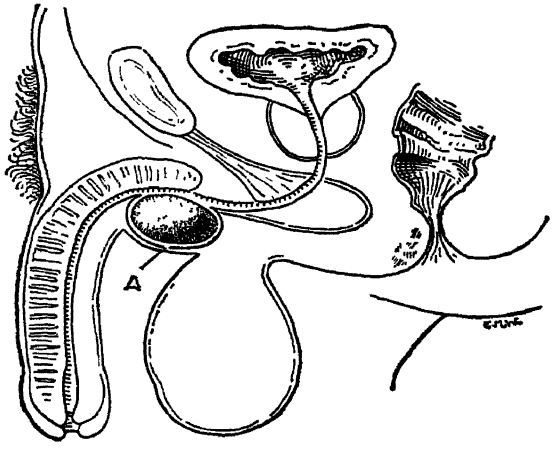

FIG. 500.—Stone in a urethral diverticulum (A). (Mouat.)

Treatment is excision of the sac and removal of the cause if it is obvious.

PAPILLOMA OF THE URETHRA

Papilloma of the urethra is uncommon. We encountered one excellent example in a man of 42. On retracting the foreskin a cauliflower mass presented itself which was found to be pedunculated, the narrow pedicle being attached to the roof of the urethra 1 in. from the meatus.

The treatment is excision of the base of the papilloma with an electro-cautery.

CARCINOMA OF THE URETHRA

Carcinoma of the urethra is excessively rare. In the only example which has come under our notice the patient had a perineal fistula of some years' standing, and no doubt the chronic infection associated with the fistula initiated the malignant change.

THE FEMALE URETHRA

The diseases of the female urethra are too often overlooked.

Stricture.—An adult female urethra which fails to admit freely a 20 French bougie is the seat of a urethral stricture. Sometimes the stricture will only admit a guide, and in these cases particularly acute retention of urine is prone to occur. Dilatation of the stricture yields satisfactory results. The recognition and treatment of a stricture often clears up an obscure case of dysuria.

Chronic urethritis is comparable to posterior urethritis in the male. Occasionally, like the latter, it gives rise to distant trouble, such as joint affections.

Granular urethritis can only be diagnosed with a cysto-urethroscope. and is a cause of frequent micturition and other symptoms which are sometimes wrongly ascribed to the internal generative organs.

Urethral caruncle is essentially due to an abrasion of the posterior part of the urethra accompanied by an infection. This raspberry-like, pedunculated mass is a granuloma springing from the posterior border of the meatus. Painful and frequent micturition and occasionally retention of urine are the chief symptoms. The treatment is excision, removing a **V**-shaped portion of mucosa about its base and bringing the cut edges of the incision together.

THE PENIS

CONGENITAL ABNORMALITIES

The penis may be very small, but it is rarely absent. Authentic cases of double-functional penis have been recorded. Webbed penis is another pathological curiosity, the organ being attached to the scrotum by a septum of skin. Shortness of the frænum occasionally gives rise to trouble, which is remedied by partial division of the structure.

PHIMOSIS

The prepuce cannot be retracted, or only with difficulty. Phimosis is usually congenital, but it can be acquired after

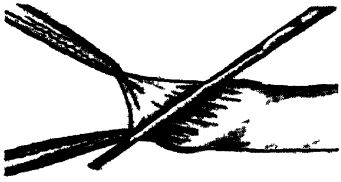

FIG. 501.—Circumcision. Applying the dressing forceps preparatory to excising the redundant skin.

preputial inflammation. Congenital phimosis can be treated in early infancy by forcibly stretching the prepuce or, at all times, by circumcision.

Circumcision.—Usually a general anæsthetic is given, but in adults infiltration of the prepuce with novocaine is entirely satisfactory, and is to be preferred.

Operation. — The prepuce is grasped in dressing forceps, which are inclined somewhat downwards (fig. 501). Redundant skin in front of the forceps is amputated with scissors. The forceps are removed, and the skin retracts, displaying the preputial mucosa covering the glans. A dorsal slit is made in this mucosal shroud, whereupon it can be peeled off the glans, smegma being brushed away with a swab. The mucosa is now trimmed to within a quarter of an inch of the corona. It remains to unite the cut edges of skin and mucosa to one another by fine, interrupted catgut sutures. The first stitch (fig. 502) includes the severed frænal artery, which it is usually necessary to clamp early in the operation. In babies the dressing is preferably Tinct. Benzoini Co. applied on a narrow strip of gauze. In adults it is well to prescribe full doses of bromide for forty-eight hours, and the more intelligent patient can be provided with an ethyl chloride spray to apply as necessary in event of priapism.



FIG. 502.—After the bleeding points have been ligatured the cut edges are approximated by interrupted suture beginning at the frænum. (Lowsley and Kirwin.)

PARAPHIMOSIS

The tight prepuce has been retracted, but cannot be returned, and it is constricting the glans which is engorged and œdematous. The diagnosis is apparent at a glance.



FIG. 503.—Reducing a paraphimosis.

Treatment.—A pad of cotton-wool soaked in a mixture of ·1 per cent. adrenaline and 10 per cent. cocaine can be applied for fifteen minutes, when, in a proportion of cases, reduction can be accomplished with ease. If it is difficult, forcible

reduction should be tried (fig. 503). If this is unsuccessful, a general anæsthetic must be given, and the constricting band nicked, after which forcible reduction will be successful. In all cases circumcision is necessary later.

Balanitis

Balanitis is an inflammation of the glans and the mucous lining of the prepuce. It may be acute or chronic.

Acute balanitis is seen usually in young men with a long foreskin. It may, or may not, be associated with a venereal infection, and a bacteriological examination of the exudate is advisable. When the prepuce can be retracted, bathing the parts with a weak solution of mercurochrome, together with instillations of hydrogen peroxide, soon clears up the condition. Hydrogen peroxide is valuable, because most of the causative organisms are anaerobic. When the prepuce cannot be retracted, it must be divided by a dorsal slit. Circumcision in the acute stage is bad surgery, for it invites a spreading infection.

Chronic balanitis is seen in elderly men who are neglectful of cleanliness. The prepuce is often indurated, and cannot be retracted owing to chronic inflammation. The treatment is similar to that of acute balanitis, although circumcision can often be safely performed in the first instance.

Leukoplakia of the penis, which is similar to the well-known condition on the tongue, is sometimes a complication of chronic balanitis.

PHAGADÆNA

Like cancrum oris, to which it is comparable, phagadæna is now rare, but hardly so rare as its counterpart in the mouth. It is a spreading gangrene of the penis which may involve the scrotum and even the abdominal wall. The initial lesion is often an acute balanitis or chancroid, and the determining factor is often some form of surgical intervention, notably circumcision during the acute stage.

Conservative treatment is advisable in the first instance. If the glans sloughs, severe secondary hæmorrhage is probable, and to avoid this partial amputation of the penis with the actual cautery becomes necessary.

CHORDEE

Chordee is due to an inflammatory effusion into the corpus spongiosum or corpora cavernosa. As a consequence the erect organ is bent downwards or laterally. In the acute stage erections are very painful. Chordee is not a common condition, and is usually a complication of acute urethritis.

Treatment.—An ethyl chloride spray is useful in preventing erection, and bromides are prescribed internally. After the acute attack has subsided the cavernous tissue is sometimes left permanently damaged by fibrosis, causing deformity of the organ.

PERSISTENT PRIAPISM

The penis remains erect, and is painful. Such is a symptom in a number of divergent conditions, prominent amongst which are

spinal injury or disease, lymphatic leukæmia, arterio-sclerosis, and damage to the corpora cavernosa. The treatment is similar to that of chordee, but if the usual remedies are ineffective, there should be no hesitation in taking an aspirating syringe, inserting it into the corpora cavernosa, and deflating the organ by withdrawing blood. Aspiration can be repeated as necessary.

FIG. 504.—Venereal warts. (Lowsley and Kirwin.)

HUNTERIAN CHANCRE

The penis is the site of election of a primary chancre.

VENEREAL WART (fig. 504)

Venereal warts are situated in the coronal sulcus. They are not necessarily associated with venereal disease, but rather with a chronic balanitis. The best treatment is circumcision, combined with excision of the wart-bearing area.

PENILE HERPES

Herpes zoster, following the course of the ilio-inguinal nerve, may attack the penis, but it is very rare. Catarrhal herpes is more common, and vesicles are present on the glans penis. The chief importance of the condition is the liability of it being confused with venereal infection.

Treatment is an application of simple boric lotion. The condition soon clears up, but catarrhal herpes is apt to recur.

SOFT CHANCRE (*syn.* SOFT SORE, CHANCROID)

is due to an infection by Ducrey's bacillus. The edges of the soft sore do not rise abruptly from the surrounding skin, but slope away gently into the adjacent parts. It can be diagnosed on clinical grounds, but only after exclusion of syphilis by appropriate tests. The differential diagnosis between hard and soft sores is often very difficult, because they may be present simultaneously in the same individual. The incubation period of soft sore is much shorter than that of syphilis, and by the fifth day after infection the lesion is fully developed.

Treatment.—Some mild chancroids heal under ordinary antiseptic dressings. The majority require cauterisation. This can be accomplished by the electro-cautery after cocainisation. Cauterisation destroys Ducrey's bacilli, and when the scabs separate there is a healthy granulating surface which soon heals under antiseptic dressings.

Bubo

Infection with Ducrey's bacillus is often complicated by suppurative adenitis of the glands of the groin. Untreated, the pus becomes superficial, and gives rise to a chancroid of the groin.

Treatment.—Some advocate complete excision of the glands of the groin before they break down. After the glands have been excised, the cavity is smeared with B.I.P.P. and closed. When suppuration has occurred, aspiration may be tried. If this does not abort the process, vertical incision and drainage must be carried out.

GRANULOMA INGUINALE

From the standpoint of differential diagnosis this is a convenient point to mention granuloma inguinale, which is often looked upon as a tropical disease, but which, nevertheless, is occasionally met with in temperate climates. The infecting organism is a Donovan body.

Clinical Features.—Beginning as a small papule, ulceration soon takes place, and the typical lesion is a bright red exuberant overgrowth of granulation tissue, which untreated spreads from the groin to the penis and scrotum. It is very chronic, and the diagnosis is confirmed by finding the Donovan bodies in smears from the lesion.

Treatment.—Local applications of all kinds are absolutely useless. Vaccines fail regularly. Recurrence invariably takes place after excision, and intravenous arsenical preparations prove of no curative value. The specific treatment is now established. It is the intravenous injection of a 1 per cent. solution of tartar emetic. About a dozen injections covering a period of six or eight weeks are usually necessary to complete a cure.

FRACTURE OF THE PENIS

Fracture of the penis is a very uncommon accident. Following trauma the erect organ suddenly becomes flaccid. The extravasation of blood, which is considerable, causes great pain and swelling. In recent cases incision, clearing out blood-clot, and suture of the ruptured corpus cavernosum has yielded good results.

STRANGULATION OF THE PENIS BY RINGS

Removal is prevented by venous engorgement. Consequently aspiration of the corpora cavernosa may assist in removal of the ring in early cases, otherwise the services of a blacksmith must be sought.

Carcinoma of the Penis

Except in Chinese and Malayans the penis is a comparatively uncommon site for cancer.

Pathology.—Two forms exist, the papilliferous (fig. 505) and the ulcer, which are comparable to those of the tongue. Like the latter, the penile manifestations have also definite

pre-carcinomatous beginnings. The papilliferous variety begins in a venereal wart, and the ulcer is often associated with leukoplakia of the glans penis, which in turn is an aftermath of chronic balanitis. The papilliferous type is slightly less malignant, but in both dissemination to the inguinal glands occurs regularly. Distant metastatic deposits are infrequent, even late in the course of the disease.

Clinical Features.—Carcinoma of the penis rarely develops in the circumcised, but to go farther, and to assert that it is confined entirely to the uncircumcised, is inaccurate.



FIG. 505.—Carcinoma of the penis. Circumcision has been performed, displaying a papilliferous type of growth.

In order to establish the diagnosis it may be necessary to slit up the prepuce. The inguinal glands should be examined by palpation, and usually will be found much enlarged. While invasion of these glands by carcinoma does occur regularly and early, it must be borne in mind that much of the enormity is due to superadded sepsis.

Untreated, the whole glans becomes a fungating and particularly foul-smelling mass. Later, the inguinal glands fungate through the skin of the groin, and death relieves the victim, often suddenly, by torrential hæmorrhage following erosion of the external iliac artery.

Treatment.—In all remediable cases it is advisable to dissect completely the inguinal glands, and there is much to be said for doing this three weeks before attacking the local lesion by one of the following methods.

Radium.—For early cases, when the primary lesion is less than half an inch in diameter, the insertion of radon seeds is satisfactory, and has the great advantage of preserving the organ. For more advanced cases radium in any form cannot be recommended.

Partial Amputation of the Penis.—As the result of a follow up, we came to the conclusion that this was a poor method of treatment. Nearly every patient died within a year following the operation. Psychologically, the mutilated organ is probably more disturbing to the patient than emasculation. If consent cannot be obtained for complete amputation, radium should be tried.

Complete amputation of the penis, which includes the separation and removal of the corpora cavernosa from the pubic bones and division of the corpus spongiosum as far back as to leave only half an inch protruding from the skin wound, gives good end results. Patients have been shown to be alive six years or more after this operation. The complication of post-operative stricture is circumvented by making no attempt to suture the cut corpus spongiosum, which contains the urethra, to the skin edges, but to leave, as has been mentioned, half an inch of the structure protruding. As F. Kidd points out, if the penis has to be removed, it is better to remove the testes too, and thereby spare the exphallated patient lustful desire.

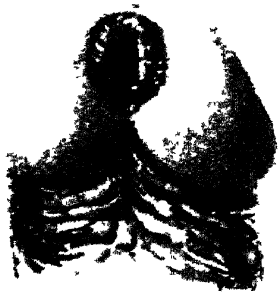

FIG. 506.—Paget's disease of the glans penis. (Susman.)

Paget's Disease of the Penis (fig. 506).—"I have seen a persistent rawness of the glans like a long-standing balanitis followed by cancer of the substance of the penis" (Sir James Paget). Though very rare, it is possible that penile Paget's disease escapes detection until an actual carcinoma has developed. Radon seeds should prove useful in treatment.

CHAPTER XXVI

THE TESTES, INCLUDING THE SPERMATIC CORDS, VESICULÆ SEMINALES, AND THE SCROTUM

HYDROCELE

A HYDROCELE is a collection of serous fluid in some part of the processus vaginalis, usually in the tunica.

Ætiology.—A hydrocele can appear in conjunction with some demonstrable pathological condition of the corresponding testis; such is termed a "secondary hydrocele." More usually the condition arises spontaneously, and its pathogenesis is uncertain. The trend of current opinion attributes the effusion to trauma or to bygone low-grade bacterial invasion.

Hydrocele fluid is amber coloured, and registers a specific gravity of 1022 to 1024. It contains water, inorganic salts, 6 per cent. of albumin, and a quantity of fibrinogen. The last constituent confers upon the fluid a characteristic feature. If the contents of a hydrocele are allowed to run through a canula into a receptacle, the fluid does *not* clot, but if a few drops of blood which have come into contact with cut tissues are stirred into even a large quantity of hydrocele fluid, the whole clots firmly. In old-standing cases the fluid is sometimes rich in cholesterol, and occasionally tyrosin crystals are found.

There are seven anatomical varieties of hydrocele.

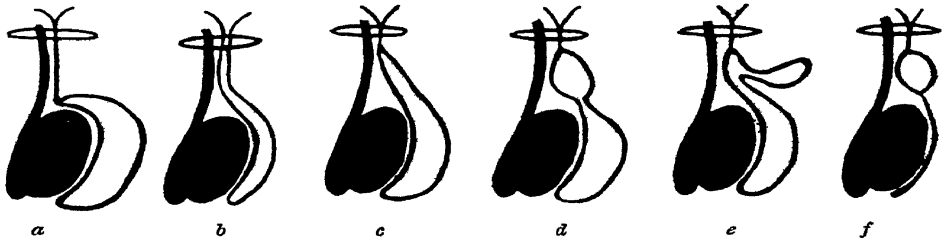

FIG. 307.—(*a*) Vaginal hydrocele. (*b*) Congenital hydrocele. (*c*) Infantile hydrocele. (*d*) Hour-glass hydrocele. (*e*) Bilocular hydrocele. (*f*) Encysted hydrocele of the cord.

GOLDEN DIAGNOSTIC RULE FOR ALL HYDROCELES

At least 99 out of every 100 hydroceles are translucent. On examination it is possible "to get above the swelling."

1. **The vaginal hydrocele** is at least six times more common than all the other varieties put together. Vaginal hydrocele often appears in middle-aged or elderly men, but it is not uncommon in early childhood, or indeed at any time of life. The condition is particularly common in tropical countries. The only complaint of the patient is the swelling, and occasionally he does not seek relief until the sac has attained enormous dimensions.

2. **Congenital Hydrocele.**—The processus vaginalis communicates with the peritoneal cavity. Usually the communicating orifice is too small for the development of a hernia. When the scrotum is elevated the fluid disappears within the abdominal cavity, usually slowly, but it returns when the erect posture is resumed. Especially in bilateral cases, ascites or serous tuberculous peritonitis should be suspected.

3. **Infantile hydrocele** does not necessarily appear in infants. The tunica vaginalis and the processus vaginalis are distended right up to the internal abdominal ring, but the sac has no connection with the general peritoneal cavity.

4. **Hour-glass hydrocele**
5. **Bilocular hydrocele**

are but variations of the foregoing, and little more than pathological curiosities.

6. **Encysted Hydrocele of the Cord.**—This fairly common condition causes some confusion in diagnosis. There is a smooth, oval swelling (fig. 508) associated with the spermatic

FIG. 508.—Encysted hydrocele of the cord removed by operation.

cord. When such a swelling is situated at the external abdominal ring it is very liable to be mistaken for an irreducible inguinal hernia. If, with gentle traction upon the testis, the swelling moves downwards, the diagnosis of hydrocele of the cord is confirmed.

7. **Hydrocele of the canal of Nück** is a condition comparable to the foregoing. It occurs in females, the cyst being in relationship to the round ligament. Unlike a hydrocele of the cord, a hydrocele of the canal of Nück is always wholly, or partially, in the inguinal canal.

COMPLICATIONS OF A HYDROCELE

1. **Rupture,** usually traumatic, but possibly spontaneous. After absorption of the fluid, on rare occasions a cure results.
2. **Hernia of the hydrocele sac** sometimes occurs in old-standing cases. Tension of fluid within the tunica causes herniation of a portion of the sac through some of the coverings of the testis (fig. 509).
3. **Transformation into a hæmatocele** may occur spontaneously, or as the result of trauma (see p. 552).
4. **Calcification** of the sac wall sometimes occurs in long-standing cases.
5. **Inflammation.**—Considering the carelessness with which hydroceles are sometimes tapped, it is remarkable that infection occurs so rarely.

FIG. 509.—A hernia of a hydrocele through some of its coverings.

Treatment.—*Tapping.*—After transillumination the swelling is made tense. A fine trocar and canula, or what is often better, a lumbar puncture needle, is inserted into an unquestionably translucent area. By this means the fluid is evacuated. After a varying interval the sac usually refills. Many patients seem content to be relieved at regular intervals in this way.

FIG. 510.—Tapping a hydrocele.

Tapping and Injection is a method of treatment which is gaining in popularity. It is often effective in

thin-walled hydroceles. The fluid is evacuated by tapping and the interior of the sac washed out with normal saline. Two or three c.c. of quinine urethane are injected and the sclerosing fluid is massaged into every corner of the sac. A suspensory bandage is worn. The fluid usually reaccumulates. One week later the process is repeated. If necessary, a third injection is given at an interval of three weeks.

Subtotal Excision.—The sac wall is excised, with the exception of the rim attached to the testis. Cautery excision is the best method of ensuring hæmostasis. Complete enucleation of the whole sac is possible in the case of encysted hydrocele of the cord or hydrocele of the canal of Nück.

Jaboulay's Operation.—An incision is made into the upper part of the sac, which is turned inside out, and maintained everted by suitably placed sutures. This method is less used than formerly; it is applicable only to thin-walled hydroceles, which can be treated by injection.

In all operations for hydrocele hæmostasis must be perfect, and after the operation the scrotum must be firmly supported, otherwise the troublesome complication of scrotal hæmatoma is prone to follow.

RARER AFFECTIONS OF THE TUNICA VAGINALIS

Secondary Hydrocele.—Attention is again directed to the effusion into the tunica vaginalis which accompanies certain affections of the testis. It is a frequent associate of acute and chronic orchitis. It is nearly always present in the syphilitic affections of the testis, and occasionally complicates malignant disease of the organ. Often the question as to whether a hydrocele is or is not secondary to some underlying disease of the testis can only be settled after the hydrocele has been tapped. Secondary hydroceles rarely attain a large size, and in the case of acute orchitis they sometimes subside *pari passu* with the primary lesion.

Chylous hydrocele is seen in tropical countries, and is due to filarial parasites. Acute cases should be treated by rest, while chronic cases respond to the usual operations for hydrocele.

Hydrocele of a Hernial Sac.—The neck of a hernial sac may become plugged with omentum or by adhesions, and a hydrocele results.

Acute epidemic funiculitis is due to a streptococcal thrombophlebitis of the pampiniform plexus. An acute hydrocele is a regular accompaniment. The general symptoms are often grave, and unless surgical treatment is resorted to early, death results from septicæmia. Operation is imperative before the fourth day if death is to be averted. The operation recommended by Bird is to open freely the tunica vaginalis and separate the constituents of the cord

with the finger, leaving the wound open. This disease is rare. Epidemics have occurred in Egypt and India, but it is not unknown in Europe (Castellani).

Cysts connected with the Epididymis

Spermatocele is a unilocular retention cyst derived from some portion of the sperm-conducting mechanism of the epididymis.

Ætiology.—It is not possible to dogmatise upon the exact origin. A blocked vas efferens would account for the condition; on the other hand, it is impossible to dispute a claim that a spermatocele arises from one of those vestigial structures depicted in fig. 512, providing always that the remnant in question is connected with the sperm-conducting mechanism.

Clinical Features.—A spermatocele is nearly always situated in the head of the epididymis, and is therefore above and behind the body of the testis. Filled with barley-water-like fluid containing spermatozoa, the swelling is typically softer than other cysts occurring within the scrotum. Spermatoceles give rise to few symptoms, and are usually small and unobtrusive. More rarely they are large enough to attract notice. Sometimes the patient presents himself because he believes he has a third testicle, but, as Sir Robert Liston (1784–1847) remarked, "these patients flatter themselves in thinking they are unduly provided" (fig. 511).



Fig. 511.—A large spermatocele.

Treatment.—Small spermatoceles should be left alone. Larger ones can be aspirated and injected, or excised.

Cysts of the Epididymis.—A cyst of the epididymis, filled with crystal-clear fluid (as opposed to the barley-water-like fluid of a spermatocele or the amber-coloured fluid of a vaginal hydrocele), is a common clinical entity.

Ætiology.—A cyst of the epididymis can arise as a retention cyst or a cystic degeneration of:

(*a*) The pedunculated hydatid of Morgagni.
(*b*) The sessile hydatid of Morgagni.
(*c*) The vas aberrans of Haller, inferior or superior.
(*d*) The paradidymis, or organ of Giraldés.
(*e*) A blocked vas efferens (fig. 512).

Clinical Features.—Cysts of the epididymis are usually found in middle life, and are often bilateral. They are translucent, tense, and often consist of an aggregation of a number of small cysts (fig. 513). Like spermatoceles, they are situated often above and behind the body of the testis. Not infrequently a vaginal hydrocele is present in addition.

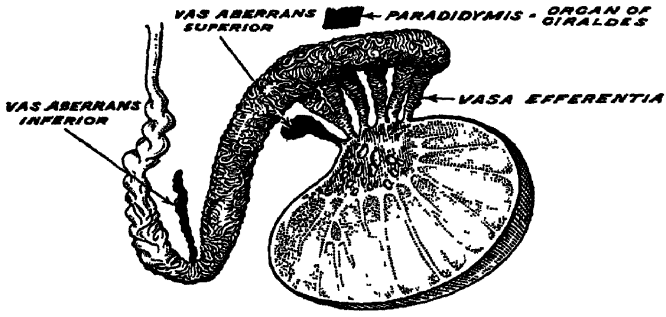

FIG. 512.—Structures from which spermatoceles and other cysts of the epididymis arise. The sessile and pedunculated hydatids are not shown.

Treatment.—When large, or when symptoms are present, the cysts should be excised. Cautery excision minimises the occurrence of a post-operative scrotal hæmatoma. Owing to their multilocular nature, cysts of the epididymis are unsuited to treatment by injection.

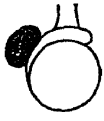

FIG. 513.—Cyst of the epididymis.

Cyst of one of the hydatids of Morgagni (fig. 514) is a separate clinical entity. It forms a small, globular swelling at the superior pole of the testis. It is usually unilateral, and in the case of the pedunculated hydatid it sometimes undergoes axial rotation and produces acute symptoms akin to those of mild torsion of the testis.

FIG. 514.—Cyst of the hydatid of Morgagni.

INJURIES TO THE TESTIS

1. **Hæmatocele.**—Hæmorrhage into the tunica vaginalis may result from a blow. It also sometimes occurs after tapping a hydrocele. Absorption of blood from the tunica vaginalis is slow and uncertain. It is far better to remove promptly the blood and blood-clot, and to perform at the same time an operation for the cure of the hydrocele. Hæmorrhage into a hydrocele may occur from a trivial injury, or even spontaneously. An old clotted hæmatocele generally proves a diagnostic riddle. It is referred to on p. 552.

2. **Laceration of the testis** is a rare accident, and even when the damage is severe, repair is nearly always possible.

Congenital Abnormalities

1. **Anorchism.**—Complete absence of the testes is exceedingly rare.

2. **Anterior inversion** is said to be present in one in every twenty males. The epididymis is in front, and the body of the testis and the tunica vaginalis behind. When the testis is diseased this anomaly causes much confusion in diagnosis, and is referred to on p. 552.

3. **Maldescended Testis.**—This important subject must be discussed fully.

Maldescended Testis

Under this heading are included two conditions :

Imperfect Descent.—The testis is arrested in some part of its path to the scrotum.

Ectopic Testis.—The testis is abnormally placed outside this path.

Development of the Testes.—The testes are developed in the abdomen. Their blood-supply comes from the aorta at the level of the twelfth dorsal vertebra, and their nerve-supply from the tenth dorsal segment. During the early months of fœtal life they descend to the internal abdominal ring. They pass through the rings during the seventh and eighth months (fig. 515), and reach the bottom of the scrotum just before birth. The later stages of descent depend upon the development of the *gubernaculum*. This unique structure, which is derived from mesoblast, is packed with proliferating cells which grow rapidly through the inguinal region. The gubernaculum (= a rudder) was first described and so named in 1762 by John Hunter, who evidently believed that its function was to guide the testis into the scrotum. There is no evidence to support the view that the gubernaculum exercises traction upon the testis ; why and how the testes descend is still problematical. Possibly intra-abdominal pressure due to accumulated meconium rises sufficiently by the eighth month to expel the testis down the inguinal canal. Normally the left testis descends a little earlier than the right.

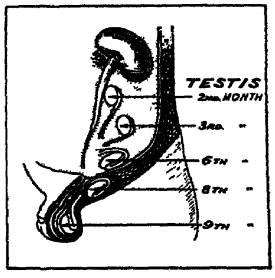

Fig. 515.

Imperfectly Descended Testis

Pathology.—Until shortly before puberty an imperfectly descended testis differs little, if at all, from its normally-placed counterpart. About this time changes occur, the

most obvious being that the body and the epididymis begin to separate. By the time early manhood is reached this separation is unmistakable (fig. 516). The external secretory mechanism of the imperfectly descended organ never functions satisfactorily.



FIG. 516.—Characteristic separation of the epididymis from the body of the testis. Specimen from a man of 23.

Sir Astley Cooper rightly taught that patients with bilateral retained testes were usually sterile, whereupon one of his pupils, a cryptorchid, left the room and committed suicide. At the necropsy which followed motile spermatozoa were demonstrated. It is therefore unsafe to deny parentage to those with retained testes.

Nevertheless the power of spermatogenesis of the imperfectly descended organ is usually negligible ; on the other hand, its internal secretory activity approaches normal. Even in cryptorchids secondary sexual characters appear.

If an imperfectly descended testis is brought down satisfactorily *before puberty* it usually develops and functions fully.

FIG. 517.—Maldescent of the left testis. Showing the shrivelled appearance of the scrotum on the affected side.

Clinical Features of Imperfect Descent.—Maldescended testis may occur on one or both sides. Double incomplete descent is more uncommon than single, and arrested descent occurs more commonly on the right side. There are various degrees of incomplete descent. The testis may be :

1. Retained in the abdomen. When both testes are within the peritoneal cavity, the patient is known as a cryptorchid.
2. In the inguinal canal.

3. At the external abdominal ring.

Only very rarely does a testis reach the scrotum by its own initiative if it has failed to do so by the end of the first year.

Important Definition.—An imperfectly descended testis is one which cannot be made to touch the bottom of the scrotum. In little boys, when the cremaster muscle contracts, the testis may be pulled into the inguinal canal, and this has beguiled the clinician time and again. In such cases, by gentle manipulation, the organ can be replaced fully in the scrotum.

Symptoms and Complications.—There may be no symptoms, particularly in the case of an intra-abdominal testis. *Pain* may be a symptom ; inguinal and ectopic testes are particularly liable to repeated *injury*, and this may cause pain and tenderness to the organ. It is often an *associated hernia* which compels the patient to seek surgical aid. *Torsion* is more liable to occur in the maldescended organ. There is hardly a subject in surgery upon which there is greater controversy than the question of frequency of *malignant disease* supervening in a maldescended testis. This debatable point is referred to again on p. 550.

Treatment.—The chances of a maldescended testis completing its descent after the first year are very slender indeed—so slender as not to justify a hopeful attitude where anxious parents are concerned. Intra-abdominal testes, unless giving rise to symptoms, should be left alone. Ectopic testes and extra-abdominal maldescended testes should in most cases be treated by operation. Within limits, the younger the patient the better the prospect of replacing the organ in its normal position by operation. Except in the case of ectopic testis, which, on account of its comparatively long cord, is often extremely remediable, the chances of successful orchidopexy after the age of 16 are remote.

1. **Orchidopexy.**—The principles of the operation are as follows. By way of an inguinal incision the testis, seemingly in a peritoneal sac, is exposed. The processus vaginalis having been opened, the cord lying beneath it is carefully dissected from the sac. Separation of the spermatic vessels is continued up behind the peritoneum, past

the internal abdominal ring. When the cord has been freed it is thereby lengthened. The peritoneum is closed at the internal abdominal ring. The sac is cut away, except the lower part, which is stitched about the testis to form a tunica vaginalis. The scrotum is deepened with the finger and a testis placed therein. It is kept in position by a number of ingenious contrivances, amongst which are:

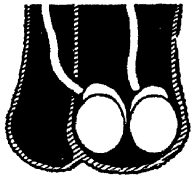

FIG. 518.—Transseptal orchidopexy (Ombrédonne's operation).

(*a*) A tension suture passing from the tunica albuginea, through the scrotum, and tied around a roll of gauze.

(*b*) The testis is passed through an aperture in the septum dartos (fig. 518).

(*c*) An internal splint of silver wire is fixed to the pubic bone on the one hand and the lowest part of the tunica albuginia on the other with a catgut stitch in each case. This splint is removed twelve days later under local anæsthesia through a stab incision in the scrotum.

(*d*) Torek's operation is illustrated in fig. 519. After six months or less the testis and the scrotum are freed from the thigh.

When a hernia exists it is repaired during the course of the operation.

2. **Orchidectomy** is indicated particularly when the other testis is normal, and the cord too short to allow replacement of the maldescended organ in the scrotum.

FIG. 519.—Torek's operation. At a future date, some months later, when the cord has become adequately and permanently stretched and thereby lengthened, the scrotum and testis are detached from the thigh.

3. **Orchido-cœlioplasty** (abdominal replacement of the organ) is very seldom justifiable. Occasions arise when it is the only method of preserving a supply of internal testicular secretion and secluding an organ exposed constantly to injury.

Ectopic Testis

An ectopic testis may be found :

1. Above and to the outer side of the external abdominal ring.
2. In the perineum.
3. At the root of the penis.
4. Over Poupart's ligament.
5. In Scarpa's triangle.
6. Over the pubis.

The first two positions are relatively common.

Unlike the imperfectly descended testis, an ectopic organ often develops fully. Its main hazard is that owing to its position it is liable to injury.

Ætiology.—To explain the appearance of the testis in these anomalous positions, C. B. Lockwood, in 1887, advanced the ingenious theory of many gubernacular tails. His theory postulates that in ectopic testis the main scrotal tail becomes broken. As a consequence the testis, adrift from its usual mooring, follows one of the accessory rudders. Lockwood stated that the accessory gubernacula depicted in fig. 520 could be demonstrated in the fœtus ; a fact which other workers have been unable to substantiate.

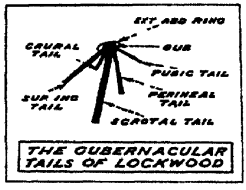

Fig. 520.

Treatment.—Of necessity many ectopic testes have a comparatively long spermatic cord. On this account they are replaced readily in the scrotum.

Torsion of the Testis

Torsion of the testis is a comparatively rare emergency. It is often associated with imperfect descent. Torsion of a fully descended testis also occurs. The factors which favour axial rotation are depicted in fig. 521.

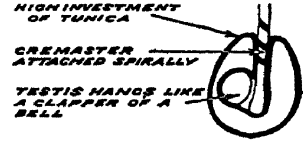

Fig. 521.

Clinical Features.—The patient, usually a boy or young man, experiences sudden or agonising pain in the groin, and vomits. Upon theoretical grounds one might think that the diagnosis is simple, but nothing could be farther from the truth, for it is practically impossible to distinguish *torsion of a maldescended testis*

from a strangulated inguinal hernia. The fact that the side of the scrotum is empty and œdematous is certainly in favour of the tender lump at the external abdominal ring being the testis with its cord twisted, but it is impossible to rule out a tense strangulated inguinal hernia until the parts have been displayed by operation. *Torsion of a completely descended testis* is a less difficult problem. Sometimes the actual twists in the cord can be felt, when the diagnosis is established. At other times the condition can be mimicked exactly by a small, tense, strangulated hernia compressing the cord and causing congestion of the pampiniform plexus, the result of which is a tender, œdematous testis on that side. Torsion of the fully descended testis can also simulate closely acute epididymo-orchitis; even the temperature is raised slightly — 99°F.—after the lapse of a few hours.

FIG. 522.—Torsion of the testis from a boy of 15. The testis was in the inguinal canal and it was thought to be a case of strangulated inguinal hernia.

(See also Torsion of a Cyst of the Hydatid of Morgagni, p. 538.)

Recurrent torsion with spontaneous rectification occurs. We met with such a case in a young soldier. On the occasion upon which we saw him—the fourth attack within six months—spontaneous rectification took place in the jolting ambulance which conveyed him from his camp. As a result of the repeated interference with its blood-supply, the affected testis had become much smaller than its fellow. The excised testis proved to be particularly fibrotic.

Treatment.—Immediate operation is indicated. In early cases it may be possible to untwist the cord and fix the organ in an anatomically correct position. As a rule, orchidectomy must be performed (fig. 522).

ACUTE EPIDIDYMO-ORCHITIS

No attempt will be made to segregate epididymitis from orchitis, for to do so is unprofitable and confusing.

Infection usually arrives via the vas from the posterior urethra. A large number of examples are due to an extension of gonorrhœal posterior urethritis. Common as this is,

it is unjustifiable to jump to a conclusion that a given case is gonorrhœal in origin, for, as set out below, other organisms give rise to this condition.

Clinical Features.—The attack is inaugurated with malaise, pyrexia, and perhaps a rigor. The testicle becomes swollen and acutely tender, and a sympathetic acute hydrocele is a frequent accompaniment. In the premonitory stages, when inflammation is proceeding along the vas deferens, pain may be referred to the abdomen, and on the right side this has been mistaken for appendicitis.

Acute epididymo-orchitis of mumps develops in about 18 per cent. of males suffering from mumps when the parotid inflammation is waning. The testis, usually the right, becomes swollen and painful. Rarely, the testicular precede the salivary manifestations.

Resolution occurs regularly, but in fully 55 per cent. of cases atrophy of the testis follows. It often takes many months for signs of testicular atrophy to become apparent.

Acute B. Coli Epididymo-orchitis.—Epididymo-orchitis due to B. coli sometimes occurs idiopathically, especially in individuals run-down with overwork. The constitutional symptoms are sometimes alarming. Suppuration is not usual.

Acute staphylococcal epididymo-orchitis usually develops in the course of a general staphylococcal infection.

Acute typhoid and paratyphoid epididymo-orchitis is an uncommon complication of typhoid fevers. Suppuration is usual.

Acute Tuberculous Epididymo-orchitis.—In a few cases tuberculosis of the testis is ushered in as an acute epididymo-orchitis.

Acute Post-operative Epididymo-orchitis.—Previously this was a serious and frequent complication of prostatectomy. It has been practically abolished by preliminary vasectomy (see p. 503).

Treatment of Acute Epididymo-orchitis.—The patient must be confined to bed. Urethral washes and instrumentation should be eschewed rigorously. The scrotum is supported by a sling formed by broad adhesive attached across the thighs (fig. 523). Upon the sling is placed a nest of cotton wool, and in this the inflamed organ rests. Fomentations are prescribed by some surgeons ; others apply an ice-pack. Aspiration of a

FIG. 523.—Treatment of acute epididymo-orchitis. A splint for the testicles. Broad adhesive is applied to the thighs as shown.

FIG. 524.—Decapsulation of the epididymis by a cruciform incision.

secondary hydrocele helps to lessen acute pain.

If palliative treatment does not bring relief within a few days, there is a growing tendency to abandon purely conservative measures in favour of decapsulation of the epididymis (fig. 524). This relieves unnecessary suffering and tends to prevent recurrence, chronicity, male sterility, and even testicular atrophy.

If suppuration occurs, drainage is necessary. Atrophy of the testis may follow as a remote complication in any case of orchitis.

CHRONIC EPIDIDYMO-ORCHITIS

Acute epididymo-orchitis does not often become chronic. In gonorrhœal cases the so-called chronic variety is rather recurrent subacute retrograde infection from a purulent seminal vesicle. Recognising this fact, attention should be directed to the concomitant vesiculitis (see p. 554).

TUBERCULOUS EPIDIDYMO-ORCHITIS

Acute tuberculous epididymo-orchitis has been referred to already. It is comparatively rare and often misdiagnosed in the first instance.

Chronic tuberculous epididymo-orchitis is common. The maximal incidence is during the third and fourth decades of life. Many of the physical signs of tuberculous disease of the testicle are discussed in the differential diagnosis of testicular swellings (p. 551). The epididymis is mainly involved, and the first sign is often a nodule in the globus minor. Later the whole epididymis becomes craggy (fig. 525), and the body of the organ may become implicated. Even in the early stages of the disease the vas becomes palpably thickened and beaded. Often the corresponding vesicle is involved—indeed, some authorities teach that the primary focus is



FIG. 525.—The physical signs recorded in a case of tuberculous epididymitis.

always in the vesicle. Untreated, the disease runs a chronic course. It tends to spread to the other genito-urinary organs, notably the prostate and the testicle of the other side. Locally the epididymis becomes adherent to the skin of the scrotum posteriorly. Abscess and sinus formations are common.

Treatment.—In the early stages *conservative treatment* is indicated, and in a fair proportion of cases is rewarded with a cure. Among the more important of the non-operative measures is *heliotherapy*, both natural and artificial, and both local and general. The testis must be supported, and protected from injury. So long as the patient is improving, conservative treatment should be continued.

Operative treatment also gives good results, even in cases which have failed to respond to conservative measures, providing the disease has not disseminated through the lower genito-urinary tract. Operation is indicated particularly when scrotal sinuses are present, yet one testis alone is diseased.

Ligature and division of the vas on the affected side, and the opposite vas in addition when either seminal vesicle is involved, is a sound measure for preventing spread of the disease. This slight operation should receive early consideration and may be looked upon as almost a necessary adjuvant to conservative treatment.

Epididymectomy with or without anastomosis of the divided ends is practised, especially on the Continent. It is a good method of treatment when the disease is strictly limited to the tail of the epididymis.

Orchidectomy with partial scrotectomy is especially valuable in unilateral cases with sinus formation. The operation should be conducted in two parts. First the cord is exposed in the inguinal region and divided between ligatures. The inguinal incision is now closed. The second part of the operation consists of excising the diseased portion of scrotum and removing with it the now detached testis. In this way we are spared the possibility of carrying the infection into the inguinal region.

If the corresponding vesicle is diseased, this should be excised (p. 555). Results have been improved by vesiculectomy, thereby ridding the patient of what in many cases is undoubtedly the primary focus.

Syphilitic Epididymo-orchitis

Congenital Syphilis.—When a congenital syphilitic reaches puberty a number of misfortunes befall him (p. 30). Syphilitic orchitis, which is bilateral and painless, is perhaps the least of these.

Secondary syphilitic epididymo-orchitis is very uncommon. It occurs about six months after the infection. As opposed to gonorrhœal and other forms of chronic epididymo-orchitis, it is the globus *major* which is maximally affected.

Tertiary Syphilitic Epididymo-orchitis.—1. *Fibrosis of the testis* is rivalled only by mesaortitis as the best macroscopical post-mortem evidence of syphilis. On bisecting the testis, scar tissue is seen within.

2. *Gumma.*—The body of the testis is primarily involved. (fig 526). It is enlarged evenly and stonyhard. The clinical features of gumma of the testis are discussed in the differential diagnosis of testicular swellings (p. 551).



FIG. 526.—Gumma of the testis.

The treatment in all cases is that of constitutional anti-syphilitic treatment. Most gummata under such treatment disappear like dew before the sun. In the few rebellious cases the dense fibrosis prevents resolution, and for this reason orchidectomy is performed.

FUNGUS TESTIS

There is herniation of diseased testicular substance through the tunica albuginea and through the overlying scrotum. A mass of fungating tissue presents not unlike a breaking-down neoplasm. Fungus testis is nearly always inflammatory, and is the result of an abscess within the tunica albuginea bursting forwards. The fungating mass is composed of unhealthy granulation tissue. Occasionally, but atypically, the condition is gummatous in origin.

The treatment is partial scrotectomy with orchidectomy, performed after the manner described for tuberculous epididymo-orchitis with sinuses (p. 546).

MALIGNANT DISEASE OF THE TESTICLE

Pathology.—Under the heading "malignant testis" are arranged a group of new-growths of this organ made up as follows:

	Per cent.	
Teratoma	50	
Carcinoma [1]	49	
Sarcoma	1	(H. Dew)

[1] This variety is known in some clinics as a seminoma.

In general it may be stated that malignant disease of the testis is an extremely fatal condition, metastases occurring mainly via the lymphatic stream. As with other teratomata, the malignancy of the tumour varies. There are cases in which dissemination is postponed, but not for long.

FIG. 527.—Teratoma of the testis. (Sir John Thomson-Walker.)

Clinical Features.—Malignant disease of the testis is distinctly uncommon. It occurs at any age, from the infant in arms to past the eightieth year. The maximal incidence is during the years of sexual activity. Teratomata appear earlier than carcinomata.

The part played by trauma is a disputed one. In nearly 50 per cent. of cases there is the history of a blow, and this still further complicates the differential diagnosis between neoplasm and old clotted hæmatocele. Another hotly disputed question is whether malignant disease is more prone to attack a maldescended testis. Statistical evidence strongly favours the belief that the maldescended organ is more frequently attacked; it can be said that malignant tumours are slightly more common in the maldescended organ.

An important consideration is the principal location of metastatic deposits in this disease. Without doubt the para-aortic glands at the level of the origin of the spermatic arteries bear the brunt of neoplastic invasion. Thus it comes about that the abdomen, particularly the upper abdomen, should be palpated for enlarged glands (fig. 528).

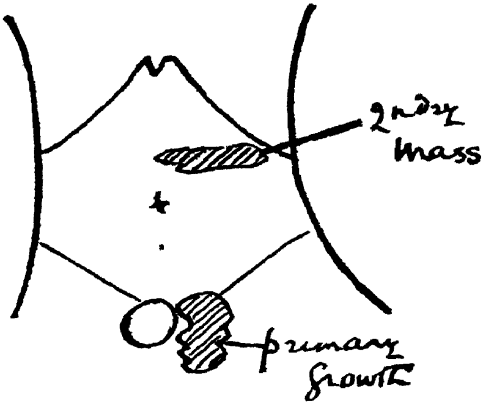

FIG. 528.—Record of the findings in a case of malignant left testis. Note the position of the mass of secondary glands.

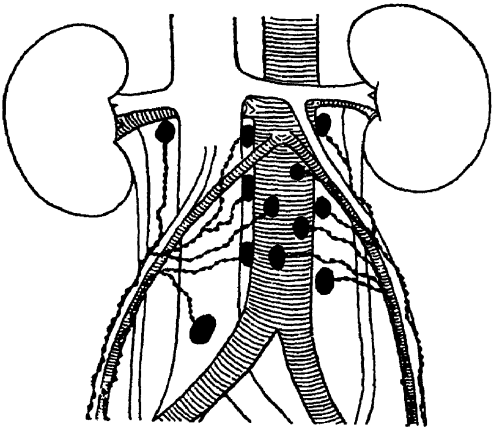

FIG. 529. — The lymphatic glands into which the lymph from the testis drains. (After Jamieson and Dobson.)

The other leading features of malignant testis are discussed in the differential diagnosis of solid testicular swellings, p. 551. They are grouped together in this way because we have found it most helpful both from practical and theoretical standpoints.

Treatment.—*Palliative Orchidectomy.*—Excision of the testis is carried out, dividing the cord as high as possible. The remote results of the measure are very depressing. Quite 85 per cent. of the patients die of dissemination of the disease within three years.

Radical Operation.—The patient lies on the sound side. Orchidectomy is performed, the cord being clamped and divided with a cautery. The diagnosis is confirmed, and then instruments and gloves are changed. Through an extension of the incision in the groin towards the tip of the twelfth rib the lymphatic glands are dissected along the spermatic artery right up to its origin. The whole dissection is extra-peritoneal. The radical operation promises better results.

Prophylactic deep X-ray treatment is advisable in all cases. The carcinoma (seminoma) is far more radiosensitive than the teratoma.

Differential Diagnosis of Testicular Swellings

When presented with a case of a swelling of the testis which is neither acutely inflamed nor wholly translucent, the clinician is faced with a problem, for a differential diagnosis must be made between the following conditions :

1. Syphilitic orchitis (gumma).
2. Tuberculous epididymo-orchitis.
3. Neoplasm.
4. Old clotted hæmatocele.

From a systematic examination the differential diagnosis is arrived at by a correlation of physical signs in the following way :

SYPHILITIC ORCHITIS (HISTORY OF WEEKS)

Skin of Scrotum.—At first normal, it becomes adherent in front. Later, there is a wash-leather slough in this situation.
Body of Testis.—Uniformly enlarged.
Epididymis.—Normal.
Vas.—Normal.
Testicular Sensation.—Lost early.
" *Weighing the Testis.*"—Organ feels light.
Secondary Hydrocele.—Nearly always present.
Rectal Examination.—Negative.

TUBERCULOUS EPIDIDYMO-ORCHITIS (HISTORY OF MONTHS)

Skin of Scrotum.—Tends to become adherent low down posteriorly.
Body of Testis.—Normal.
Epididymis.—Enlarged and nodular—" craggy."
Vas.—Thickened and beaded.
Testicular Sensation.—Present.
" *Weighing the Testis.*"—Without value.
Secondary Hydrocele.—Present in 30 per cent. of cases.
Rectal Examination.—Prostate and vesicle may contain tuberculous nodes.

MALIGNANT TESTIS

Skin of Scrotum.—Normal at first, then large dilated veins can be seen. Finally, may become adherent anywhere, but this is very rare.

Body of Testis.—Enlarged uniformly at first. Later nodular and bulging.

Epididymis.—As the tumour enlarges it becomes flattened out and cannot be felt.

Vas.—Normal.

Testicular Sensation.—Lost late.

"*Weighing the Testis.*"—Organ feels heavy.

Secondary Hydrocele.—Present in 15 per cent. of cases.

Rectal Examination.—Negative.

CONDITIONS CLOSELY SIMULATING MALIGNANT TESTIS

Hæmatocele of some standing may simulate testicular neoplasm in every particular, and probably most surgeons of experience have removed a hæmatocele in the belief that they were dealing with a neoplasm. This accounts for the comparatively large number of specimens of old clotted hæmatocele which adorn the shelves of pathological museums (fig. 530).



FIG. 530.—An old clotted hæmatocele. The long-standing pressure has flattened the testis.

Tuberculosis of an anteverted testis is another trap awaiting the diagnostician in this field. The craggy epididymis, lying, in this case, in front of the testis, obviously invites the assumption that it is the body of the testis which is affected, and such a condition has been mistaken repeatedly for malignant disease. Conversely malignant disease of the epididymis, a rare condition, is nearly always diagnosed as tuberculosis until it is too late to remedy.

It will be realised that testicular swellings are often difficult to diagnose correctly. If malignant disease cannot

be ruled out definitely, there should not be the slightest hesitation in exposing the testis to the light of day. This can be done readily under local anæsthesia. By the more general adoption of this principle it is hoped that testicular tumours will be diagnosed earlier than at present.

Male Sterility

The causes of male sterility are as follows:

1. **Impotence.**—Inability to perform the sexual act may be due to (*a*) Malformations or loss of the penis. (*b*) Psychic causes, for further information on which works on sexual psychology should be consulted.

2. **Absence of Spermatozoa in the Semen.**—A cryptorchid is usually potent, but sterile. Prolonged X-ray exposure is among the causes of azoöspermia.

3. **Aspermia.**—Because of a mechanical fault in the male conducting apparatus, the semen may not reach the vagina. Leading examples are a urethral fistula, a tight stricture, and obliteration by scar tissue of the lumina of both vasa efferentia or both common ejaculatory ducts. The commonest cause of male sterility is bygone epididymo-orchitis, with its aftermath of cicatricial obliteration of some part of the lumen of the vas. When other means have failed Hagner's operation is occasionally successful. By means of sutures of the finest silver wire the epididymis is anastomosed to a healthy portion of vas above the stricture.

"Rejuvenation"

With a view to prolonging man's span of useful existence, attempts have been made to enhance or augment the internal secretion of the testis, which wanes with advancing years. Two methods have been tried.

1. **Steinach's Operation.**—As a result of experiments on rats, Steinach showed that when the vas is ligatured the interstitial cells of the testis multiply, and the old, sleepy rat becomes more active. Applying this knowledge to man, the vasa have been divided between ligatures under local anæsthesia. At first extravagant results of the success of this method were reported, but now the general concensus of opinion is that as a means of rejuvenation the operation is of little if any value.

2. **Voronoff's Operation.**—The testis of an anthropoid ape is grafted into man in the following way. The testis of an ape is removed aseptically and the epididymis cut away. The body of the testis is divided into four equal parts. The recipient's tunica vaginalis is opened and the tunica albuginia is scarified in two places. Two of the similar grafts are then applied, sutured in position, and the coverings of the testis closed over them. A similar procedure is carried out on the contra-lateral side. There is no question that the grafts function for a time. Human maldescended testes removed at operation have been utilised for the same purpose.

There is certainly a remarkable increase in vitality in many

recipients of a testicular graft. The good results are usually somewhat transient, but the method appears one which justifies an extended trial.

Vesiculæ Seminales

Acute vesiculitis is usually an extension of a gonococcal infection. The treatment is similar to that of acute prostatitis. In cases of closed abscess the vesicle must be drained.

Vesiculotomy.—The vesicles are exposed by an incision as for perineal prostatectomy. The affected vesicle is opened and drained.

Chronic Vesiculitis.—Again, this is usually an aftermath of posterior urethritis. Some cases of chronic gonorrhœa are maintained by infection lurking in the vesicle. The diagnosis is made by rectal examination, when an enlarged, tender swelling in the position of the vesicle can be palpated. If the condition does not respond to "stripping" by a finger in the rectum, lavage of the vesicle by the method

Fig. 531.—A seminal vesiculogram.

immediately to be described often rids the patient of the infection.

Vasotomy.—The cord is exposed by a small incision over the external abdominal ring. The vas is isolated and canalised with a hollow needle. The vesicle is washed out with not more than 2 c.c. of a 5 per cent. solution of argyrol or 1 per cent. solution of mercurochrome. The vas is left temporarily fixed in the subcutis, so that it may be re-exposed and the operation repeated four times or more in the course of a week, during which time the patient is confined to bed. After the final injection the vas is allowed to drop back.

Seminal Vesiculography.—It is sometimes necessary to know if the common ejaculatory ducts are patent. This information can be obtained by catheterising the common ejaculatory ducts through a

special posterior urethroscope. Sodium iodide is then injected up the catheter and a vesiculograph taken. The same information can be obtained more easily by vasotomy and injection of an opaque medium (fig. 531).

Tuberculous vesiculitis is often associated with tuberculous epididymo-orchitis, and other, more widespread, genito-urinary tuberculosis. There is considerable evidence that in many cases the vesicle is the primary focus, and it is abundantly clear that it is useless to remove a tuberculous testis and leave a correspondingly infected vesicle. Tuberculous vesiculitis does not respond to conservative treatment, and the results of excision of the vesicle are encouraging.

Vesiculectomy by the Inguinal Route.—Through an ample inguinal incision which opens the inguinal canal the vas is isolated and traced backwards by dissecting up the peritoneum. This will lead to the vesicle, which is freed by dissection and excised. The operation is not excessively difficult, and results are satisfactory.

Varicocele

A varicocele is a varicose condition of the veins of the pampiniform plexus. From 5 to 10 per cent. of males between puberty and the age of 35 have some degree of pampiniform varicosity on the left side. In almost all cases it is the left side which is affected ; occasionally both sides are involved, but it is most exceptional for the right side to be affected alone.

The cause of the predilection for the left side is disputed, and the following theories have been advanced :

1. The left spermatic vein enters the left renal vein at a right angle, while the right spermatic vein enters the vena cava obliquely.
2. The left testis is lower in the scrotum than the right.
3. A loaded sigmoid colon is liable to press upon and obstruct the left spermatic vein.
4. Most men " dress " on the left.

Clinical Features.—Usually symptoms are entirely absent. In a proportion of cases the patient experiences a dragging pain on the left side. When the varicocele is comparatively small and the symptoms are considerable, the possibility of neurasthenia should be considered ; indeed, when a patient presents himself with many complaints concerning a varicocele, the possibility of a neurasthenic element should always engage the clinician's attention. The diagnosis is

simple. The left side of the scrotum hangs lower than normal (fig. 532), and the impression gained on palpation of the varicose plexus has been aptly likened to a bag of worms. When the patient lies down and the scrotum is elevated, the veins will be emptied by gravity and the opportunity of comparing the size of the left testis with its fellow should be taken. In long-standing cases of varicocele the left testis is somewhat smaller and softer than the right, due to a minor degree of atrophy. A comparatively rapid onset of varicocele is suggestive of a renal or supra-renal tumour, and the kidney region should be palpated in such cases.

FIG. 532.—Varicocele. (Macewen's *Text-book of Surgery*.)

The phenomenon is a rare one, and some confusion has arisen as to which side the varicocele appears. To clarify the situation we quote Sir Henry Morris: "In 1884 I drew attention to a varicocele which had appeared and gradually increased with the growth of a left supra-renal malignant tumour. I have since then seen varicocele associated with a cancer of the right kidney, which disappeared on the second day after nephrectomy."

Treatment.—A suspensory bandage, a cold bath in the morning, and reassurance that there is nothing to worry about, is all that is necessary in most instances. Candidates for the public services must be operated upon to conform with the regulations. Cases in which the varicocele is large and the testis hangs low are often distinctly benefited by operation. Small varicoceles should be left alone or treated by injection.

Injection.—The injection treatment of varicocele is very successful. In most cases one treatment is all that is necessary. The reaction is often intense, but the result is never

FIG. 533.—The treatment of varicocele by injection.

in doubt. The patient stands and the upper part of the scrotum is cleansed with alcohol. A small bunch of veins is taken up between the finger and thumb, and, using 2 c.c. of a 5 per cent. solution of sodium morrhuate in a syringe armed with a particularly sharp needle, the injection is made from above downwards just below the external abdominal ring (fig. 533). The pampiniform plexus is entered at several points by a few short jabs of the needle. The patient then

FIG. 534.—An operation for varicocele. The distal stump is suspended through the external abdominal ring as is shown in the right-hand figure. The inset shows the relationship after the suspension ligature has been tied (after M. F. Campbell).

lies down and the puncture is sealed with collodion. A suspensory bandage is worn for some weeks.

Operation gives good results only when it is performed carefully in properly selected cases (see p. 555).

Technique.—The cord is exposed by a short incision over the external abdominal ring. A little more than three-quarters of the circumference of the pampiniform plexus is separated from the remainder lying in the proximity of the vas. The isolated venous mass is divided between clamps, and the proximal end securely ligatured, using a transfixing suture. The proximal end is now allowed to fall back, and it retracts within the inguinal canal. An inch and a half, or more, of the distal end is resected and ligatured. The ends of the ligature are left long, and passed through the aponeurosis of the external oblique from within the external abdominal ring, as shown in fig. 534. The testis is suspended, and the skin incision is closed. This method is preferable to others, as it prevents drag on the spermatic cord. In cases where the scrotum



FIG. 535.—A mule spinner at work. (A. H. Southam.)

is pendulous an elliptically shaped portion of its base is resected and the cut edges approximated. The now compact left scrotal compartment aids in supporting the testis from below.

The chief post-operative complication—the development of a hydrocele—is mitigated by avoiding rough handling of the testis during the operation.

THE SCROTUM

The primary surgical affections of the scrotum are few.

Sebaceous cysts are common in the skin of the scrotum, and are prone to suppurate. When they do so the odour emitted is particularly obnoxious. We have seen a suppurating scrotal sebaceous cyst mistaken for malignant disease, which calls to mind Cock's peculiar tumour, p. 561.

Idiopathic Gangrene of the Scrotum (syn. Fournier's Gangrene).—Arises without apparent cause—first involving the scrotum, then extending along those planes so well known in urinary extravasation. The entire scrotal coverings slough, leaving the testes bared to their tunica hanging exposed though remarkably free from gangrene.

Treatment.—The gangrenous portions of the scrotum must be excised and incisions made into the infected inguinal region. Irrigations with a weak solution of potassium permanganate are instituted at regular intervals.

FIG. 536.—Carcinoma of the scrotum. (Macewen's *Textbook of Surgery*.)

Carcinoma of the Scrotum.—In days gone by this disease was almost confined to chimney-sweeps, and it still goes by the name of "chimney-sweep cancer." It must be noted that to-day the chief victims of this affection are "mule spinners" (fig. 535), and workers in tar and paraffin.

Clinical Features.—The growth commences in a wart or

an ulcer (fig. 536). As it advances it may involve the underlying testis.

Treatment.—The glands of *both* groins should be excised completely and the growth, together with a considerable margin of healthy tissue, excised. In cases with pronounced secondary infection, it is wise to conduct the operation in two stages at an interval of two or three weeks.

Elephantiasis of the Scrotum. — Filarial elephantiasis is often encountered in tropical countries, and the scrotum is the part most frequently attacked.

FIG. 537.—Filarial elephantiasis of the scrotum (inflammatory type). The scars of many previous attacks of acute inflammation can be seen.
(After Sir Frank Connor.)

There are three types of filarial scrotal elephantiasis:

Passive, which is indurated and slowly growing.

Lymphatic, which is soft and vascular.

Inflammatory, which is subject to attacks of severe inflammation at regular intervals.

The last is the commonest (fig. 537).

Treatment is essentially surgical. Excision of the mass affords great relief to the sufferer.



FIG. 538.

Technique.—An important consideration in removing enormous scrotal tumours is the position of the patient upon the operating table. He should lie horizontally with his legs hanging over the side of the table and his feet supported on chairs (fig. 538). This gives excellent exposure and allows the mass to be rolled. After the scrotum has been excised the testes are accommodated one behind the other in the perinæum and the bared shaft of the penis is skin grafted.

CHAPTER XXVII

THE HEAD

The Scalp

The **scalp** consists of five layers—skin, subcutaneous tissue, epicranial aponeurosis, into which is inserted the occipito-frontalis muscle, a loose areolar layer, and the pericranium. The scalp is well supplied with blood-vessels, and the walls of the arteries are adherent to the fibrous tissue in the subcutaneous layer. Therefore scalp wounds bleed freely, as the muscular coat of a divided artery cannot retract readily when the vessel is severed.

Owing to its rich blood-supply wounds of the scalp heal readily, and portions of scalp which are avulsed retain their vitality in a surprising manner. Many cases are on record in which the scalp had been almost completely avulsed, but after it was cleansed and sutured into position, union occurred in a satisfactory manner.

A hæmatoma of the scalp situated under the epicranial aponeurosis spreads extensively, and is only limited by the attachment of the aponeurosis around the base of the calvarium. Should the hæmatoma occur under the pericranium, it is limited by the suture lines which border the underlying bone, and to which the pericranium is attached.

Infection of the scalp is limited in a similar manner. If a wound involves the loose areolar layer, infection is only circumscribed by the attachment of the epicranial aponeurosis, and may therefore extend from the superior curved line of the occipital bone behind to the supra-orbital ridge in front, and laterally is bounded by the zygomatic arch, temporal ridge, and upper border of the mastoid process. As such extensive infection is possible, the subaponeurotic areolar

tissue is sometimes termed the "dangerous area." In the event of infection, dependent incisions should be made parallel to the main vessels and nerves, of sufficient depth to reach the areolar layer.

The following are the more important pathological conditions which affect the scalp:

Sebaceous cysts (*syn.* Wens), which are often multiple. If neglected, cysts may grow as large as hens' eggs, in which case pressure interferes with the blood-supply to the overlying scalp, which becomes bald (fig. 539).

FIG. 539.—Sebaceous cysts of the scalp.

Infection of these cysts is common, in which case the contents are peculiarly putrid. Should the cyst break down an ulcer results, formerly known as "Cock's peculiar tumour," which somewhat resembles an epithelioma, but the edges are not characteristically everted, nor is the base indurated.

Lipomata occasionally arise from the fatty tissue incorporated with the areolar layer, and therefore they lie under the epicranial aponeurosis. As they are only separated from the skull by the pericranium, pressure atrophy of the underlying bone follows in long-standing cases, and on pushing aside the lobulated edge of the tumour, the margin of a saucer-like depression in the bone is readily palpable (fig. 17).

Cirsoid aneurism is a rare condition, but of importance owing to difficulty in treatment. It is due to dilatation of the arteries, which open more or less directly into venous spaces. Capillary nævi are sometimes seen in the overlying skin. The condition usually affects the superficial temporal artery and its branches, and as it increases in size the underlying bone becomes thinned, and the hair over the

tumour falls out. The tendency for these tumours is to enlarge slowly, so that eventually ulceration occurs, which is likely to be followed by fatal hæmorrhage.

Treatment consists in extirpation of the tumour in the early stages. If its size forbids such radical treatment, then the main vessels are ligatured, often at successive operations. Too long an interval must not elapse between operations, as collateral circulation is speedily established. Ligature of one or both external carotid arteries is sometimes advisable, so as to facilitate the local treatment of the tumour.

Dermoid cysts are not uncommon, and are most frequently seen over the external angular process. Occasionally they do not appear until the child is a few years old, and they occasionally communicate with the subdural space by a narrow neck, which passes through the underlying bone, and in this case an impulse can sometimes be detected when the child coughs. As this neck tends to constrict and close, it is wise to defer removal until after puberty, so as to lessen the risk of opening the dura mater, which leads to escape of cerebro-spinal fluid, and the possible development of meningitis.

Papillomata are common, and cause discomfort on combing the hair. Constant irritation of this nature, or pressure of a hat, encourages the development of malignant disease.

Fibrosarcoma occasionally occurs, perhaps in connection with a scar. Thorough excision is indicated, otherwise recurrence with increased malignancy is probable.

Epithelioma of the scalp is not common, and presents no special features.

Melanomata may be unrecognised, owing to the small primary growth being hidden by hair, until the presence of secondary deposits leads to a careful examination for some possible primary tumour.

The Skull

A meningocele consists of a protrusion of a pouch of dura mater through a congenital defect in the skull. The usual situations are the root of the nose, over the occipital bone, or in connection with the anterior fontanelle. Very occasionally they appear through the base of the skull, in which situation they have been mistaken for nasal polypi, and attempted removal has resulted in fatal meningitis. A meningocele is present at birth, and forms a tense rounded

pedunculated swelling, which is translucent, and occasionally yields an impulse when the child cries or coughs.

An *encephalocele* is a similar condition, but some portion of the brain is also extruded (fig. 540). Should this cerebral extrusion contain part of a ventricle, the condition is known as a hydrencephalocele. In this condition, as well as an encephalocele, pulsation is usually present, but in many instances the child is still-born, or succumbs at an early age. Some degree of idiocy or deformity is likely to be associated with misplacement of brain tissue.

FIG. 540 — Occipital encephalocele, containing the bulk of the cerebellum. (John Fraser)

The treatment of a meningocele and its allied conditions consists of protection from injury. Should the swelling increase in size out of proportion to the child's natural growth, then an attempt should be made to remove it, and close the cranial defect. Otherwise the enlargement will result in pressure atrophy of the skin and ulceration, and will be followed by rupture and meningitis.

In the case of a small meningocele, subsequent growth of the skull sometimes occludes the neck of the sac, in which case a cyst remains which is non-pulsatile and unaffected by coughing.

Hydrocephalus either occurs during infancy, or follows obstruction of the cerebro-spinal circulation in the adult. *Congenital hydrocephalus* is possibly due to birth injury, which causes bleeding into the subarachnoid space. Corpuscles then gain entrance to the arachnoid villi, and so impede the absorption of cerebro-spinal fluid. Another theory alleges that excessive secretion of cerebro-spinal fluid is the cause. The shape of the skull in the case of "congenital" hydrocephalus depends upon the stage of

cranial development at the time of the onset of the condition. Should the cause be still active after closure of the sagittal suture, the frontal and occipital regions are affected (fig. 541); if the lambdoid suture is closed when the disease commences, then bulging occurs chiefly in the frontal region.



FIG. 541.—Advanced hydrocephalus in a child, who also suffered from osteogenesis imperfecta. (R C.S. Museum, 4100.1.)

The treatment of this type of hydrocephalus is eminently disappointing. Such procedures as tapping a lateral ventricle, combined with elastic pressure or ligature of the common carotid artery, appear to be useless. In less advanced cases the child may survive and become a useful member of society, for, if the cerebral cortex is not unduly thinned, the intellect appears to be adequate.

Acquired hydrocephalus is due to obstruction of the outflow of cerebro-spinal fluid from the subarachnoid space. Inflammation may obstruct the foramina in the roof of the fourth ventricle, or a tumour occasionally distorts or occludes the aqueduct of Sylvius. In a few cases improvement has followed exploration. A subtentorial decompression is performed, and the cerebellum displaced upwards so as to expose the medulla. The cisterna magna is opened, and the bulging roof of the fourth ventricle incised. Strands of silk or a tube of decalcified bone are used in order to maintain a communication between the ventricular system and the subarachnoid space.

Inflammation of Cranial Bones

Acute.—*Pericranitis* is likely to follow inflammation of the overlying areolar tissue. Necrosis of bone and thrombosis of emissary veins are troublesome and dangerous complications.

Osteomyelitis occurs as a result of :

(i) Direct infection, such as a compound fracture.

(ii) Local extension, e.g. from the frontal sinus or mastoid antrum. Osteomyelitis appears to be particularly liable to follow operations on an acute frontal sinusitis. The diplöe is sometimes infected as a result of cellulitis of the scalp, and more rarely from an extradural abscess.

(iii) Blood-borne. As in the case of acute osteomyelitis in any bone, an intra-osseous extravasation of blood following trauma occasionally becomes infected by circulating organisms.

Acute osteomyelitis of the skull is a serious condition. Infective thrombosis is likely to spread to the cranial sinuses, and other grave complications are meningitis and intracranial suppuration.

Treatment consists in wide excision of bone, both tables being removed if intracranial infection is suspected. If the acute infection abates, patience must be exercised to ensure that sequestra are completely separated before they are removed, as chiselling them out is liable to cause infection of otherwise healthy bone. When a probe indicates that a sequestrum is completely loose, the sinus is enlarged, and the dead bone lifted out.

Chronic.—*Tuberculous* disease of the skull is uncommon, but occasionally occurs in association with tuberculous lesions elsewhere. As with other bones, the infection commences either in the pericranium or in the medulla, i.e. the diplöe. The diseased bone should be removed widely, otherwise abscesses are likely to form and erode the scalp. Secondary infection occurs at an early stage owing to the depth of the hair follicles.

Syphilitic pericranitis in civilised countries is a rare affection.

Localised swellings occasionally occur, which are slightly tender and fixed to the bone. Under suitable treatment disappearance is usual, although a small bony swelling

occasionally remains. Further stages are described on p. 803.

New-growth

Innocent tumours are rare. An ivory osteoma occasionally arises in the region of an air sinus, and has been described on p. 819.

Malignant new growths resemble, in variety, those of other bones. Pericranial sarcoma forms a bun-shaped tumour, the consistency of which depends upon its vascularity and rate of growth. Thus it may be pulsatile or almost bony hard (fig. 542). Sarcoma or myeloma very occasionally develops in the diplöe.

Fig. 542.—Osteo-sarcoma of the skull. (R.C.S Museum, 1657.1.)

The commonest malignant tumour is secondary carcinoma. The breast, bronchus, and thyroid are most often the seat of the primary growth. Secondary growths of the skull are usually very vascular, and pulsate when the outer table is eroded. They have been mistaken for sebaceous cysts, owing to a somewhat careless examination, and attempts at removal cause considerable hæmorrhage.

Fractures

Vault.—These are caused by direct injury, indirect violence radiating from the base, or compression. This last cause operates when a degree of pressure is brought to bear on the skull which exceeds its limit of elasticity, and scalp

or even skin is sometimes nipped by the fractured bone when the skull springs back to its former position.

Fractures of the vault are either fissured, depressed, or elevated.

(i) FISSURED.—A *simple* fissured fracture can only be diagnosed definitely by means of an X-ray (fig. 543). In every case of head injury which in the opinion of the surgeon may have been sufficiently severe to cause a fracture, a radiograph



FIG. 543.—Typical fissured fracture involving the occipital and parietal bones.

should be taken, partly as a guide to subsequent treatment, and also to show that "reasonable skill and care" has been observed, in the event of subsequent legal proceedings. The treatment of an uncomplicated fissured fracture resolves itself into confining the patient to bed for three weeks, and such length of convalescence as the mentality and occupation of the patient may seem to require. This rather long period is justified on the assumption that a force sufficient to fracture the skull must of necessity have affected the brain. During this period of treatment, particularly in the early

days, a careful watch is kept for the onset of cerebral complications, such as compression or irritation.

In the large majority of cases patients with simple fissured fractures, in the absence of immediate complications, make a complete and permanent recovery.

It must, however, be stated that in about 5 per cent. of cases suffering from simple fissured fracture, subsequent complications develop. These include persistent headache, Jacksonian epilepsy, and mental deterioration. Some surgeons therefore recommend craniotomy in selected cases, on the grounds that a small spicule of bone, or a localised hæmatoma, is sometimes present, and unless removed is a potential source of cortical irritation. It is urged in favour of exploration that convalescence is not lengthened, the operative risk is negligible, and that if irritative phenomena develop at a later date, operation is unlikely to afford relief, as cortical changes will probably have supervened.

Therefore, if the fracture is limited in extent, the patient otherwise healthy, and a capable surgeon and efficient theatre are available, exploration is advised. Occasionally an unsuspected lesion is discovered and can be remedied, in which case the risk of subsequent complications is diminished.

A *compound* fissured fracture has been mistaken for a normal suture line. A moment's reflection should be sufficient to decide whether the suspected lesion corresponds anatomically to a cranial suture, and furthermore, a suture line is irregular, and free from oozing blood. The majority of compound fissured fractures are visible at the bottom of the wound, but all scalp wounds should be explored as extensively as necessary so that the presence of a fracture is not overlooked.

As compound fissured fractures are potentially infected, emergency operation is necessary. The edges of the scalp wound are excised, and the wound rendered as aseptic as possible. The skull is opened with a half-inch trephine, the pin being placed in such a position that the disc of bone to be removed incorporates the line of fracture. Any spicules of bone or extradural clot are removed, and in the event of subsequent infection, an exit is provided for intracranial inflammatory exudates. Drainage is provided if subsequent infection appears to be probable, owing to lapse of time since the injury or contamination of the wound.

The prognosis of a compound fracture of the skull depends upon associated injury to intracranial contents, and also upon the integrity of the dura mater. If this membrane is torn, a barrier to infection of the brain and meninges is removed, and fatal inflammation of these structures is a grave possibility. Therefore, should a subdural hæmorrhage be revealed on trephining the skull, the surgeon is called upon to decide whether the dura mater should be incised in order to evacuate the clot, or whether this procedure is unjustifiable on account of the risk of infection. No definite rule can be laid down, each case must be judged on its merits, and the graver risk, i.e. of compression or infection, avoided.

(ii) DEPRESSED.—*Simple* depressed fractures are rare, as the scalp is relatively non-elastic, and an injury sufficiently severe to fracture and depress the bone is almost certain to lacerate the tough overlying scalp. A hæmatoma in the deeper layers of the scalp is likely to simulate closely a depressed fracture, as the blood clots round the periphery. On palpation, the edge of this clot resembles the edge of normal bone surrounding a depressed fracture, but the edge of the clot can sometimes be indented by the finger-nail. In the absence of intracranial complications, delay of a few hours is of little moment, so that a radiograph can be utilised in order to distinguish the two conditions.

The treatment of a simple depressed fracture consists in elevation, and removal or reposition of bone. A flap of scalp is turned down, and in most cases it is impossible to elevate the depressed bone without making a trephine opening through which an elevator can be passed and used to prise up the fragment. The pin of the trephine must always rest on sound bone. If the elevated fragment retains its pericranial attachment, it is replaced in its original position. Detached fragments of bone should be removed, as even mild infection is likely to convert them into sequestra.

Sufficient bone must be removed to allow free inspection of the underlying dura mater. If a subdural hæmatoma is present, and cerebral pulsation is diminished, the dura mater should be incised and the blood evacuated. The incision in the dura mater may be sutured by fine catgut stitches, or a flap of fascia lata applied to the incision becomes adherent and closes the dura mater. In simple

fractures the risk of infection should be negligible, and therefore incision of the dura mater is not fraught with danger, as in the case of compound fractures.

Pond-shaped depressions occur in infants, as a result of prolonged pressure of the head against the promontory during birth, or during the ensuing months by direct injury. If no improvement follows after a few months, or if signs of compression are evident, the depression should be elevated. The simplest method of performing this is by means of a guarded gimlet, i.e. silk is wound around the gimlet to within a quarter of an inch of its point. A small incision is made over the centre of the depression, and the skull is perforated by the gimlet. An aneurism needle is introduced through the aperture, and by this means traction is applied to the depressed bone. The elastic skull of the infant readily yields, and springs back to its normal position.

Compound depressed fractures are the most common variety of these injuries to the vault, but many of these injuries are immediately or rapidly fatal, and so are of interest to the coroner rather than to the surgeon (fig. 544). Diagnosis is usually obvious, and if brain substance has escaped, it is unmistakable. Treatment is a matter of urgency, as infection rapidly becomes established.

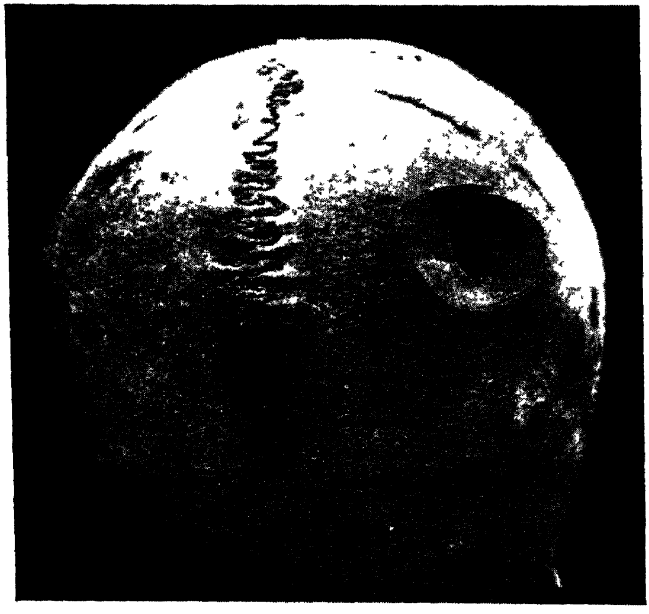

FIG. 544.—Skull found on the veldt in South Africa, showing depressed fracture, presumably compound. It was probably caused by a Zulu knobkerry. (R.C.S. Museum, 3278.1.)

Treatment therefore entails immediate operation, unless other injuries render the patient's condition hopeless. The edges of the wound are excised and the deeper structures explored. If bone is completely detached, or grossly contaminated with dirt or foreign material, it is removed, otherwise fragments are elevated, and the wound closed or drained according to circumstances.

(iii) ELEVATED.—Elevation of bone occasionally results from a blow with a heavy cutting instrument. Such fractures were not uncommon in former wars, when swords and cutlasses were used for other than ceremonial purposes. They are of necessity compound, and treatment is conducted on general principles.

Base.—Fractures of the base are caused as follows :

(i) *Direct Injury.*—The roof of the orbit is surprisingly thin, and has been perforated accidentally by umbrella ferrules, slate pencils, and other similar objects. A compound fracture of the base of the skull is likely to follow discharge of a fire-arm through the mouth (as in cases with suicidal tendencies).

(ii) *Indirect Injury.*—A fall on the buttocks, or a blow on the jaw, sometimes transmits sufficient force to the base of the skull to cause fracture. In rare cases the condyle of the jaw is driven into the middle fossa.

(iii) *Irradiation.*—In a few cases the fracture primarily affects the vault of the skull, and extends to the base.

(iv) *Compression.*—As in the case of the vault, a fracture of the base may be due to compression of the skull beyond its limit of elasticity.

Fractures of the base extend along the lines of least resistance, and therefore usually connect foramina, and are deflected by buttresses of bone.

CLINICAL FEATURES.—The essential features are :

(i) *Escape of cranial contents*, i.e. blood, brain, or cerebrospinal fluid, which leaks along the torn dural sheaths of the nerves. Perilymph and endolymph escape, if the fracture involves the internal ear, but are unrecognisable.

(ii) *Injury to Cranial Nerves.*—All the cranial nerves are liable to be involved, with the exception of the twelfth, as the anterior condyloid foramen is protected by a ridge of bone.

Concussion, cerebral compression, and other injuries to the brain are not evidence of a fractured base, but are complications which commonly occur.

Anterior Fossa

(i) Escape of Cranial Contents.—Epistaxis occurs if the cribriform plate is involved. Should the fracture extend into the orbit, an effusion of blood follows.

This is distinguished from a "black eye" by the following features:
(*a*) The skin round the orbit is not damaged.
(*b*) The orbital effusion occurs some hours after the injury.
(*c*) The eye is sometimes pushed forwards, as the extravasation occurs into the tissues at the back of the orbit.
(*d*) This extravasation impedes the action of ocular muscles, and consequently movements of the eyeball are limited.
(*e*) Should subconjunctival hæmorrhage follow, the patch is wedge-shaped with the apex in front, and the posterior limit cannot be seen.

Cerebro-spinal fluid is likely to trickle through the cribriform plate, often in surprising quantities, a condition formerly known as "traumatic rhinorrhœa." Very occasionally, if the bone is extensively damaged, the brain extrudes into the orbit or nose.

(ii) Injury to Nerves.—The olfactory nerve is frequently torn, but unless its fellow is also damaged, the injury is likely to pass unrecognised. The optic nerve usually escapes injury, even if the line of fracture passes through the optic foramen, on account of the relatively large size of this aperture. The third, fourth, first division of the fifth, and the sixth nerves are all occasionally involved as they pass through the sphenoidal fissure.

Middle Fossa

(i) Escape of Cranial Contents.—Epistaxis occurs if the fracture involves the basi-sphenoid. As in the case of the alveolar border of the jaws, the muco-periosteum of the base of the skull is closely adherent to the bone, therefore a fracture is nearly always associated with tearing of the muco-periosteum, and is consequently of the compound variety.

Escape of cerebro-spinal fluid and blood from the ear is

common. Slight bleeding originates from a torn tympanic membrane, the tympanic plexus, or separation of the bony and cartilaginous portions of the external auditory meatus. More serious hæmorrhage follows injury to the petrosal sinuses, the lateral sinus, or the middle meningeal vessels.

Brain substance very occasionally escapes through the ear or roof of the nose.

(ii) Injury to Nerves.—The facial nerve is commonly injured at the time of the accident. In the majority of cases the involvement is only temporary, and is due to concussion, or extra- or intra-neural hæmorrhage. Occasionally the nerve is torn, and paralysis is permanent. In some cases paresis develops some days or weeks after the injury, and is then due to involvement in fibrous tissue. The eighth nerve is sometimes injured, in which case deafness follows. The sixth nerve, which passes across the middle fossa, is occasionally implicated.

Posterior Fossa

(i) Escape of Cranial Contents.—Blood, cerebro-spinal fluid, or even brain may escape into the posterior part of the naso-pharynx, through the basi-occiput. A common feature to be observed a few days after the accident is extravasation of blood in the suboccipital region. This appears either as a boggy swelling of the nape of the neck or as a discoloration below the superior curved line, posterior to the mastoid process.

(ii) Injury to Nerves.—The ninth, tenth, and eleventh nerves are occasionally damaged as they traverse the jugular foramen. As stated above, the hypoglossal nerve escapes injury.

Treatment.—As in the case of all head injuries, the patient is confined to bed in subdued surroundings. Should epistaxis persist, dried blood is removed from the nose, and the nares lightly packed with gauze moistened in a mild antiseptic. Escape of blood from the ear is treated on similar lines, except that a sterile pad is placed over the ear, as even light packing may possibly obstruct the meatus, and so predispose to cerebral compression. In very rare cases

the flow of blood is so free and persistent as to indicate damage to a large vessel. The middle fossa is then opened by trephining above the ear, and efforts are made to deal directly with the bleeding sinus or artery.

Urotropine should be given ; it is excreted by the cerebro-spinal fluid, and acts as a mild antiseptic. It can be administered intravenously, if so desired.

THE BRAIN AND MEMBRANES

Inflammatory Conditions

Acute infective meningitis is most commonly due to compound fractures of the skull. It occasionally follows spread from some neighbouring focus of infection, such as osteomyelitis of the skull or inflammation of an air sinus. Cerebro-spinal fever spreading through the cribriform plate from the nose is another example of local extension. Blood-borne infections occasionally reach the meninges; for instance, staphylococci in cases of acute osteomyelitis, or pneumococci following pneumonia.

Clinical features are ushered in with headache and vomiting. Severe constitutional symptoms follow, and if meninges over the convexity are affected, convulsions, delirium, and photophobia are in evidence. Should the base of the brain be chiefly involved, head retraction, optic neuritis, and implication of cranial nerves are the main features.

Treatment consists in dealing with any causative lesion, e.g. an infected middle ear. In all cases the head is shaved, ice or cold compresses are applied, and lumbar or cisternal puncture is performed as often as is deemed necessary. Urotropine is given and serum therapy considered, but, as must be expected, recovery in a case of generalised meningitis is most exceptional.

Extradural Abscess.—The causes of an extradural abscess resemble those of acute infective meningitis. A compound fracture, especially in the event of inefficient drainage, is a common cause, as is also extension from an accessory air sinus or the middle ear. In the case of the middle ear, infection most commonly reaches the extradural space by spreading through the tegmen tympani. Following a frontal sinusitis, a surprisingly large collection of pus occasionally collects behind the frontal bone, infection having passed through the posterior wall of the sinus.

Blood-borne infection accounts for a few cases. A blow on the head causes an extradural hæmorrhage, which becomes infected by circulating organisms. A low-grade

osteomyelitis sometimes affects the overlying bone, and the scalp in its turn becomes inflamed and œdematous. This condition was described by Percival Pott as a "puffy tumour," and the tender, œdematous, and adherent area of scalp, particularly if associated with any cerebral symptoms, should always raise the suspicion of a possible extradural abscess.

The symptoms of an extradural abscess depend upon its situation, size, and the rate at which it enlarges. Drowsiness, bradycardia, and other evidence of cerebral compression are usual, and focal signs depend upon the site of the abscess. If a local focus of infection exists in the scalp or cranium, it is probable that the abscess is situated in the underlying brain.

Treatment consists in drainage, the method of approach depending on the cause of the abscess. If due to some pre-existing focus of infection, it is wise to deal with the cause, and follow the track along which infection has extended. Thus, if an abscess is apparently a complication of otitis media, the middle ear is explored, and the tegmen tympani removed. Similarly, a sequestrum of the skull should suggest a subjacent abscess, if signs of intracranial infection supervene.

In the unusual cases where no clue exists as to the cause of the abscess, the skull is trephined over the suspected area. If adequate and timely drainage is provided, the prognosis of an extradural abscess is hopeful.

Cerebral Abscess

Cerebral abscesses are either acute, subacute, or chronic. From the surgical standpoint the subacute type is the most important.

Acute.—Usually follow compound fractures, or such local inflammatory conditions as osteomyelitis of the skull. A diffuse infection follows, affecting the meninges as well as the cortex of the brain. If the brain has been penetrated by a fragment of bone or a foreign body, an abscess occasionally occurs in its substance, and as it enlarges the brain may be extruded through the cranial defect. The appearance of a hernia cerebri following a compound fracture always suggests the possibility of intracranial suppuration.

General symptoms of infection are evident, combined with those of cerebral irritation and increased intracranial pressure. Treatment

is directed towards the provision of suitable drainage, but unless efficient localisation has occurred, recovery is unlikely.

Subacute.—The usual cause of this condition is infection spreading from the middle ear or air sinuses (fig. 545).

FIG. 545.—A cerebellar abscess following otitis media. (R.C.S. Museum, 6641.1.)

More rarely such conditions as penetrating wounds or pyæmia cause a subacute abscess.

In the case of extension from the middle ear or frontal sinus, the inflammation usually spreads directly to the brain through the covering membranes, which become adherent to the bone. Occasionally an extradural abscess first forms, and if evacuation is delayed, infection is liable to extend through the membranes to the brain. When the abscess is opened a layer of apparently healthy brain is found frequently between the cavity and the surface, in which case the infection has extended along the vessels entering the cortex.

Clinical Features.—(i) *Signs of Infection.*—The temperature and pulse-rate tend to be elevated, but as the abscess enlarges, so intracranial pressure rises also, with consequent lowering of temperature and slowing of the pulse. Therefore the chart frequently shows variations which depend upon whether toxæmia or increased intracranial pressure are

in the ascendancy. Leucocytosis is present, but its significance must be discounted if some other infective condition is also present.

(ii) *Increased Intracranial Pressure.*—Headache, irritability, drowsiness, and vomiting are commonly in evidence. Papillœdema can usually be detected, especially if the abscess is subtentorial, or of moderate duration.

(iii) *Focal Signs.*—These depend on the site of the abscess. The more important signs are considered in connection with tumours (p. 586). In the case of abscesses due to otitis media, three out of five are in the temporo-sphenoidal lobe, and the remainder are in the cerebellum.

In every case of suspected cerebral abscess, it is obviously of great importance to examine all possible sources of infection. In many cases the probable cause of the mischief is evident, but it should be remembered that discharge from an ear may cease when intracranial complications develop. Also any hindrance to discharge, as by inspissated pus, predisposes to the extension of infection along deeper channels.

Treatment.—Any probable focus of infection is explored. Thus the bone in the neighbourhood of a fracture is removed, or the middle ear is explored. It is obviously desirable to drain an abscess via the path of infection, which is surrounded by protective adhesions, as the risk of contaminating the subdural space is thereby diminished. Also the path of infection is a guide to the abscess, and so facilitates its discovery.

In the case of an abscess due to otitis media, the middle ear and, if necessary, the mastoid antrum are opened. Usually a sinus is discovered which leads either backwards to the posterior fossa or upwards through the tegmen tympani to the middle fossa. The sinus is enlarged, and the dura mater, which is adherent to the bone, is incised. The brain is exposed, and if no abscess is evident, a pair of fine sinus forceps is gently introduced into the brain and opened sufficiently to allow pus, if present, to escape. Attempts to discover pus with an aspirating needle are not to

be recommended, as the pus is frequently too thick in consistency to flow along the needle. When the abscess is evacuated, a rigid tube is inserted into the cavity—glass, decalcified bone, or even a tracheotomy tube are all satisfactory. A soft rubber tube is liable to be compressed by transmitted pressure from the brain. Lateral holes are to be avoided, as brain tissue insinuates itself into them, and is consequently avulsed when the tube is withdrawn. The tube is retained until discharge has entirely ceased, so as to minimise the risk of subsequent development of a residual abscess.

Occasionally the condition of the patient may be such that an extensive operation is undesirable, in which case an abscess arising from ear disease is drained through a suitably placed trephine opening. If an abscess is suspected in the temporo-sphenoidal lobe, an opening is made ¾ in. above the centre of the external auditory meatus. In the case of a cerebellar abscess the opening is situated 1 in. behind the meatus, and ¼ in. below Reid's base-line, which passes backwards from the lower margin of the orbit and through the centre of the external auditory meatus.

Chronic.—Abscess of the brain is an occasional complication of chronic pulmonary infection, such as bronchiectasis or empyema. The clinical features resemble those of a cerebral tumour. The fibrous wall of the abscess cavity may be nearly ½ in. in thickness, and in some cases the chronicity is explained by the discovery of a streptothrix in the pus.

If situated in an accessible position an attempt should be made to drain the abscess, but usually it is situated deeply in the brain, and is consequently difficult to locate.

CEREBRAL INJURIES

Injuries to the brain include concussion, compression, and contusion or laceration. Frequently these conditions coexist.

Concussion (*syn.* Stunning)

Theories.—(i) A blow on the head causes a momentary indentation of the elastic skull. This sudden reduction of the cranial capacity squeezes blood out of the skull, and so a temporary cerebral anæmia results, with cessation of function.

(ii) Sudden reduction of the cranial capacity, and consequent pressure on the brain, compresses the cerebro-spinal fluid in the lateral ventricles. This is forced along the aqueduct of Sylvius, so that a sudden wave of cerebro-spinal fluid impinges on the floor of the fourth ventricle, beneath which the vital centres are situated. This theory may be associated with the one above.

(iii) Punctate hæmorrhages are alleged to occur, but this theory introduces the possible features of compression also.

(iv) A theory which held sway in former years suggested that the sudden blow causes dendrites to retract, in the manner of the tentacles of sea anemones when disturbed. Interruption of stimuli and interference of function result.

Clinical Features.—These vary with the intensity of the concussion, and include all grades of severity, from momentary dizziness to prolonged unconsciousness and death, although concussion alone is probably never fatal.

A summary of the features of a case of moderate severity is tabulated below, and for the purposes of comparison those of cerebral compression are included :

	Concussion.	*Compression.*
General condition .	Unconscious, gradually regains consciousness.	In a classical case, concussion, then lucid interval, followed by increasing drowsiness and coma.
Appearance . .	Pale and shallow respirations.	Flushed, respirations become stertorous.
Pulse . . .	Increased in rate and feeble.	Slow and "bounding." Rapid and feeble when cardiovascular centre begins to fail.
Temperature. .	Subnormal.	Unequal on the two sides.
Musculature . .	Relaxed, reflexes diminished or absent.	Varies on the two sides.
Sphincters . .	May be incontinent.	Become incontinent.
Pupils . . .	Moderately dilated, equal, react sluggishly.	On side of injury, pupil contracts, and later dilates. The opposite side follows.

After a variable interval of unconsciousness, signs of reaction usually become evident. Respirations are deeper, the pulse increases in tension, and the face becomes flushed. The patient frequently turns on to his side, and the fact that he is in strange surroundings gradually dawns on his returning consciousness. Vomiting is usual, and is due to cerebral hyperæmia, which raises the intracranial pressure.

Features of grave significance are the persistence of unconsciousness for more than twenty-four hours, a pulse which increases in rate and diminishes in tension, and pyrexia. Treatment involves the seclusion of the patient in bed, with perhaps one low pillow. A cold compress is placed on the head and protected hot-water bottles round the body and limbs. The pulse is recorded at hourly intervals, and a careful watch kept for evidence of compression, which may develop with no "lucid interval." Calomel is given if the patient can swallow. Severe headache occasionally follows, which is usually relieved by the reduction of intracranial tension. This can be effected by introducing into the rectum 3 oz. of magnesium sulphate in 6 oz. of water, or the intravenous injection of glucose or hypertonic saline. In otherwise intractable cases, a lumbar puncture is often effective.

Prolonged convalescence is needed, account being taken of the severity of the injury, the mental make-up of the patient, and the amount of worry and concentration associated with his occupation.

After a severe head injury it is probable that the potential efficiency of the brain is always lessened. Such sequelæ as neurasthenia, irritability, lack of concentration, forgetfulness, etc., are common, and sometimes persist. In worse cases, such obvious mental deterioration as melancholia, delusional insanity, and dementia necessitate seclusion in a mental home. One curious effect which occasionally follows a head injury is increased susceptibility to alcohol, and more than one unfortunate person has only discovered this when arrested for drunkenness after some very minor "celebration."

Cerebral Compression

Compression immediately following trauma is due to depressed bone, extravasated blood, cerebral œdema, or a foreign body. If due to such conditions as depression of bone, evidence of compression is likely to follow the injury immediately. In other cases, such as compression following extra-dural hæmorrhage, concussion first occurs, followed by a period of improvement, after which the patient becomes drowsy, and lapses again into unconsciousness. Thus, an unconscious footballer has been carried off the field of play, but recovered sufficiently to finish the match. Headache and drowsiness supervened, so that he retired to bed

at an early hour, and was later found to be dead from middle meningeal hæmorrhage. Similar tragedies have occurred in police-stations, particularly as a head injury sometimes causes temporary excitement. Persons alleged to be drunk have been locked in cells, and the unconsciousness and stertorous breathing of compression mistaken for a drunken stupor.

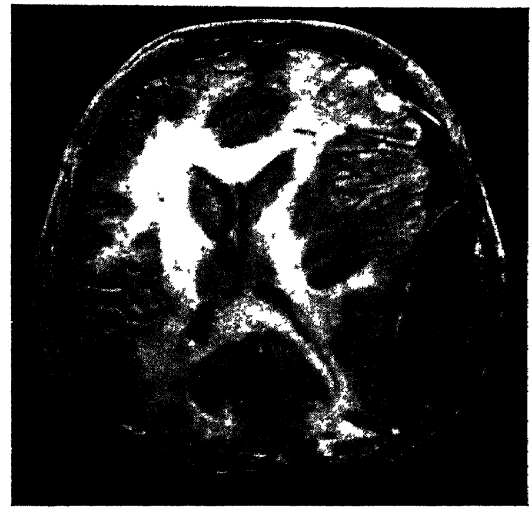

FIG. 546.—Extra-dural hæmorrhage, due to rupture of the middle meningeal artery. (R.C.S. Museum, 4853.1.)

Middle meningeal hæmorrhage (fig. 546) furnishes an example of compression, the features of which are as follows:

General Condition.—The patient becomes increasingly drowsy, and is more and more difficult to rouse. Coma follows, and unless the pressure is relieved, death is inevitable.

Appearance.—The face is flushed, and the facial muscles on the opposite side of the injury become paralysed, so that the cheek "flaps" as the patient breathes. Later both cheeks are paralysed. Respirations are deep, and when the palatal muscles are paralysed stertor follows. Breathing gradually becomes more difficult and laboured, and sometimes ends as Cheyne-Stokes's type.

Pulse.—The rate steadily falls, and the blood-pressure rises, so that the pulse is slow and bounding. This is due to efforts on the part of the cardio-vascular centre to maintain an adequate cerebral circulation. Eventually cerebral anæmia, due to the rising intracranial pressure, becomes so pronounced that the cardio-vascular centre fails. This is evinced by an abrupt rise of pulse-rate and lowering of blood-pressure, and death is then imminent.

Musculature.—Irritation of the cortex by suffused blood causes spasticity of the muscles on the opposite side of the body, preceded by twitching. As the pressure increases the motor cells are rendered anæmic and cease to function, so that the muscles innervated by them are flaccid and reflexes are lost. At the same time pressure is transmitted to the motor cells of the opposite side, and the consequent irritation causes spasticity of muscles on the side of the damaged vessel. As pressure of increasing intensity is transmitted across the brain, the cells on the opposite side

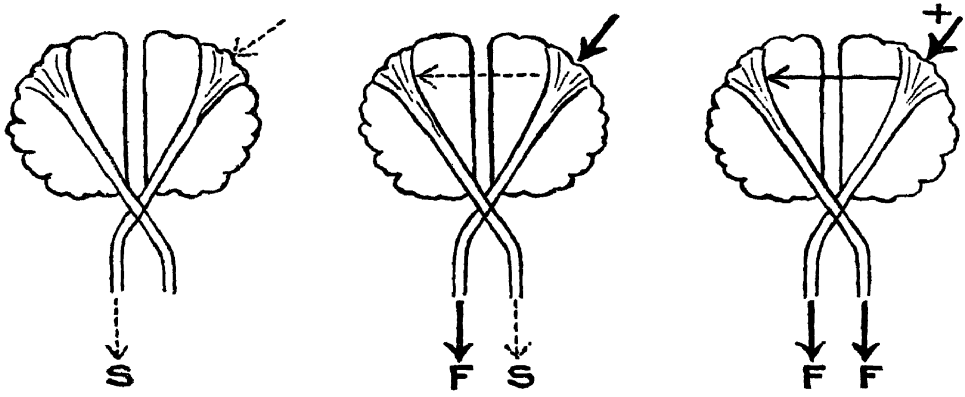

FIG. 547.—Diagram to illustrate effects of increasing unilateral pressure on the motor tracts. The dotted arrow indicates irritative pressure, and the dark arrow severe pressure. S = spastic, and F = flaccid paralysis.

of the injury cease to function, so that the muscles on the same side as the injury become flaccid.

Pupils.—Irritation of the third nerve causes the pupil on the side of the injury to contract. As pressure increases, paralysis supervenes, so that dilatation follows from unbalanced action of the sympathetic. Usually at this stage transmitted pressure to the other side causes irritation of the third nerve, so that the pupil becomes contracted. Eventually, increasing transmitted pressure causes paralysis of the opposite third nerve, and gradual dilatation supervenes, with finally dilatation and fixity of both pupils.

Temperature is sometimes unequal on the two sides of the body, being elevated on the opposite side to the

injury. A sudden rise of temperature occasionally precedes death.

Sphincters.—As coma deepens, incontinence supervenes.

Treatment.—In any case of compression a careful examination must be conducted in order to determine the nature and site of the lesion. If possible a history is obtained, such as the details of an accident. The head is examined for evidence of injury or fracture, and the pupils and musculature probably give some indication as to the site of the lesion. A lumbar puncture is sometimes of assistance in distinguishing extra- from intradural hæmorrhage; in the latter case the cerebro-spinal fluid is likely to contain blood.

Surgical measures must be adopted without delay, appropriate to the type of injury. Depressed fractures are elevated, and efforts are made to discover and arrest intracranial hæmorrhage.

If it appears that the **middle meningeal vessels** are damaged operation is undertaken as follows:

The head is shaved completely, and a point marked on the skull by means of a bradawl, either 1½ or 2 in. behind the external angular process, and above the zygoma. The actual measurement depends on the distance between the orbit and the ear, which varies considerably. This point lies over the anterior branch of the artery. It is wise at the same time to indicate the site of the posterior branch at the junction of two lines, one passing horizontally backwards from the upper margin of the orbit, and the other vertically upwards from the back of the mastoid process. A horseshoe incision is made down to the bone, commencing ½ in. above the external angular process (to avoid the branch of the facial nerve which supplies the orbicularis palpebrarum and forehead muscles). The incision passes upwards for about 3 in., and descends immediately in front of the ear. With a raspatory the scalp is separated from the skull, so that the teeth of the trephine will not be clogged with pericranium. The bradawl mark is identified, and the skull is opened with a ¾- or 1-in. trephine. If the diagnosis is correct, blood-clot is encountered, which is disintegrated with a sharp spoon and washed away with saline. If necessary the opening is enlarged with nibbling forceps.

As the operation field is cleared, the bleeding point may be encountered, which is either the artery or vein. A fine, curved needle is passed under the vessel, carrying thread, with which both ends of the vessel are ligatured. Care must be taken not to pierce the dura mater, as a thin-walled cerebral vein is easily scratched. Occasionally the vessel is found to be lying in a bony canal, in which case the canal is plugged with Horsley's wax or a sharpened match stick. Should no damaged vessel be found, the opening in the skull is enlarged downwards and forwards along the line of the artery, until

the base of the skull is reached. If no bleeding point is discovered and blood wells up from the middle fossa, it is probable that the base is fractured. Further attempts to find the bleeding point should be abandoned in favour of ligature of the external carotid artery between the superior thyroid and lingual branches.

If no clot or hæmorrhage is displayed when the skull is opened, the opposite side should be explored. If no abnormality is revealed, the posterior branch on the original side is exposed by turning down a second flap behind the original one. The posterior branch is damaged in about 5 per cent. of cases.

The prognosis of middle meningeal hæmorrhage is poor, owing to the frequent association of other intracranial injuries. Failure of the dura mater to expand after removal of the clot is an unfavourable sign.

Intradural hæmorrhage follows laceration of cerebral veins or sinuses. Localisation is often difficult, as signs are equivocal, owing to the diffuse nature of the hæmorrhage. Also the "lucid interval" which is so characteristic of extradural hæmorrhage is absent. Should features of cerebral compression become increasingly pronounced, the skull must be opened over the probable situation of the bleeding. If subdural hæmorrhage has occurred, the dura shows diminished pulsation, and is dark blue in colour. The dura is carefully opened, the clot evacuated, and if a bleeding point is encountered, the hæmorrhage is arrested. A vein is ligatured, and a sinus dealt with by a small gauze pack, or preferably, if the flap contains muscle, a small portion is excised and inserted between the sinus and the bone. This avoids the necessity for removal, diminishes the risk of infection, and a surprisingly small amount of pressure is required to collapse the walls of the sinus. Hæmorrhage from the superior longitudinal sinus is characterised by twitchings and spasms on both sides of the body, commencing in the lower limbs. This is due to pressure exerted by the extravasated blood interfering with the venous return from the upper part of the Rolandic areas, and as the pressure increases the spasms become widespread.

Cerebral Irritation

Cerebral irritation is due to œdema, bruising or laceration of the cortex, and is particularly likely to follow falls on to

the back of the head, in which the frontal lobes are damaged by *contre-coup*.

The patient is usually concussed for a variable period, and on his recovery he exhibits irritability of mind, and the body assumes a position of flexion (fig. 548). Interference of any kind is resented verbally or even forcibly, and the patient remains curled up in bed, the knees being drawn up, and the arms flexed. The temperature tends to be slightly but irregularly raised, and the pulse is normal in rate and low in tension,

FIG. 548.—Cerebral irritation. The patient has turned away from the light.

unless the condition is complicated by compression. Improvement is indicated by a tendency to turn on the back, and the patient becomes more tolerant to his surroundings.

Recovery may be apparently complete, but in these cases it is doubtful if the potential capabilities ever return to normal. More commonly some symptoms persist, such as irritability, depression, lack of concentration or judgment, and amnesia regarding the accident or events immediately before or afterwards. In worse cases dementia or other forms of insanity necessitate seclusion in a mental hospital.

Treatment demands a minimal amount of disturbance, but sufficient nourishment must be administered, and attention paid to the bladder and bowels, although often excreta are passed into the bed. Sedatives are prescribed if necessary, and if tolerated, an ice bag to the head is useful. The patient sometimes takes food if left by the bedside, and may use a urine bottle if one is within reach.

Cerebral Tumour

Cerebral "tumours" include such conditions as cysts, gummata, tuberculomata, and chronic abscesses.

Tumours arise in connection with the meninges, nerve sheaths, or in the cerebral substance. The commoner tumours are as follows:

Meninges.—Meningioma (*syn.* endothelioma), psammoma, tuberculoma, blood and arachnoid cysts.

Nerve Sheaths.—Fibroma of the auditory nerve, fibro-sarcoma.

Brain.—Glioma, gliomatous cyst, gumma, chronic abscess, secondary growths.

Clinical Features.—These are dependent upon the actual site of the tumour and the disturbance produced by increased intracranial pressure.

(i) *Focal or Localising Features.*—A knowledge of the functions of different parts of the brain is essential for the accurate localisation of the site of a tumour. For example, a tumour which interferes with the cerebellum causes vertigo, nystagmus, inco-ordination, and a tendency to fall to the same side as the tumour, owing to ataxia and hypotonicity of muscles. Should the Rolandic area be implicated, the corresponding muscles on the opposite side are rendered paretic, and if the cortex is irritated, spasms and twitchings precede the paresis. Involvement of Broca's area results in motor aphasia, and hemianopia suggests a lesion of the occipital lobe. The frontal area is relatively "silent," and a tumour in this situation sometimes attains large dimensions without producing definite localising symptoms (fig. 549). A fibroma growing from the sheath of the eighth nerve is likely to cause deafness and cerebellar disturbances.

(ii) *General Pressure Effects.*—These include headache, vomiting, papillœdema progressing to blindness, bradycardia, and retarded cerebration. The headache is aggravated by coughing and straining, which promote cerebral congestion. Vomiting is not preceded by nausea, or related to food, but, like sea-sickness, sometimes follows change of

posture. Papillœdema is especially prone to occur with subtentorial tumours, and is usually worse on the affected side. The symptoms of increased intracranial pressure are relieved by rectal magnesium sulphate or intravenous hypertonic saline.

Investigation.—The prognosis and treatment of a cerebral tumour depend upon its site and nature.

(i) *Site.*—The following methods of investigation assist in localising the tumour :

(*a*) Palpation of the Head.—In about 1 per cent. of cases

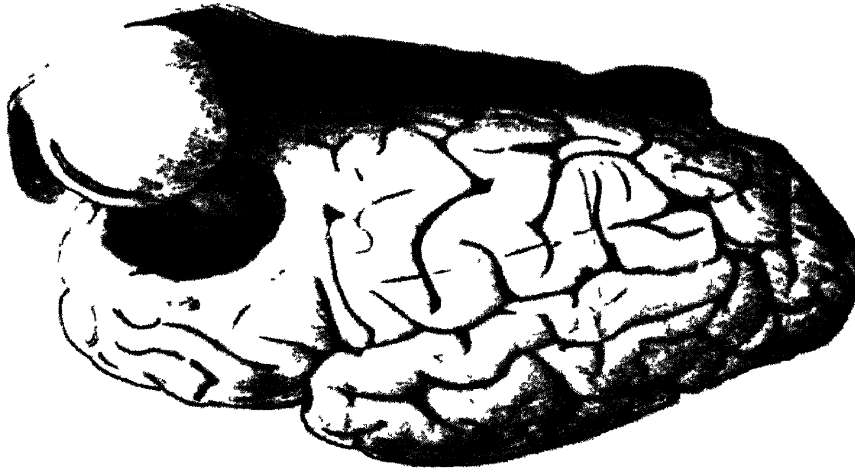

FIG 549.—A large meningioma arising from the dura mater over the frontal lobe. (R.C.S. Museum, 1454.1.)

some change in the skull is detected over the tumour. Hyperostosis occurs over a vascular tumour, while thinning or even erosion is sometimes evident if the tumour is avascular, as in the case of a hydatid cyst.

(*b*) Neurological examination, which includes the cranial nerves and their nuclei, nerve tracts, reflexes, and cortical centres. In some cases this suffices to localise accurately the position of the tumour, as in the case of an auditory nerve tumour, which causes unilateral deafness and cerebellar symptoms.

(*c*) A radiograph occasionally demonstrates thickening or

thinning which is not sufficiently advanced to be palpable. Some tumours are so calcified that they are opaque, as in the case of a suprasellar cyst, or a psammoma. A calcified pineal gland may be pushed across the midline by a tumour in the opposite side of the brain. An auditory nerve tumour, which grows slowly, characteristically expands the internal auditory meatus. A stereoscopic radiograph is a valuable help in visualising the site of an opaque tumour. The outline of the lateral ventricle can be sometimes visualised in a ventriculograph following the injection of air through a small trephine hole. The replacement of cerebro-spinal fluid by air must be accomplished very slowly, otherwise the choroid plexus is likely to ooze.

(ii) *Nature*.—(*a*) The Age of the Patient. Tuberculomata are likely to occur in children, while meningiomata are usually found in young adults. Gummata and secondary deposits appear later in life. Cysts and chronic abscesses occur at any age.

(*b*) History is sometimes suggestive. Symptoms which slowly progress, perhaps for years, are probably caused by an innocent tumour, such as a meningioma. Intermittent symptoms, possibly varying with the general health of the patient, may be ascribed to a chronic infective condition or a tuberculoma. A malignant tumour, such as a glio-sarcoma or secondary carcinoma, causes symptoms which sometimes progress in an alarming manner.

(*c*) Examination of the Patient. In a child other signs of tuberculosis will suggest a tuberculoma. The presence of bronchiectasis should arouse suspicions of a chronic abscess. A gumma or secondary tumour would be suspected if other signs of syphilis or a primary growth are discovered.

(*d*) Accessory Investigations. The W.R. must always be tested, and blood examination may also reveal eosinophilia or leucocytosis, which are suggestive of hydatid cyst or chronic abscess respectively. Examination of cerebro-spinal fluid is sometimes of value, and evidence of syphilis or tuberculous disease is sometimes discovered. In the latter case an increase of small lymphocytes is found. In the case

of increased subtentorial pressure, only a few cubic centimetres of fluid should be withdrawn, otherwise the medulla is liable to be forced into the spinal canal, with consequent risk of death from pressure on the cardio-respiratory centres.

Treatment.—It is stated that about 7 per cent. of intracranial tumours are removable. In the large majority of cases either the site or nature of the tumour precludes other than palliative measures. However, treatment in the majority of cases consists in an osteoplastic craniotomy over the supposed site of the tumour. If it is discovered that the tumour cannot be removed, then the overlying bone is excised, so that a decompression is performed over the situation of maximum intracranial pressure. If the tumour is clinically irremovable, on account of its site or nature, as in the case of a secondary deposit, then a suitable decompression is performed, if possible before the onset of permanent cerebral damage, such as blindness. The symptoms of intracranial pressure can be alleviated for perhaps as long as two days by dehydration. Either hypertonic saline (20 c.c. of a 30 per cent. solution) is injected intravenously, or magnesium sulphate (3 oz. in 6 oz. of water) is given per rectum. The intake of fluids is restricted. These methods of lowering the pressure are useful as a preoperative measure. In cases where absence of pulsation of the dura mater indicates considerably increased intracranial pressure, hypertonic intravenous saline can be given with benefit on the operating table.

Craniotomy.—Local anæsthesia, with 2 per cent. novocaine, or intratracheal anæsthesia, is used. A flap incision is made over the suspected site of the tumour. This is best accomplished in stages. The assistant exerts digital pressure, with the fingers of each hand on either side of the proposed incision, and the surgeon incises the scalp between the fingers. Before the assistant relaxes pressure, the surgeon picks up the epicranial aponeurosis on either side with artery forceps at quarter-inch intervals. These are folded back so that the vessels in the scalp are bent on themselves, and each bunch of four or five forceps is secured by means of a rubber ring. By degrees the requisite incision is made, and an extensive exposure can be obtained almost bloodlessly with patience, and a large number of forceps. The scalp is separated from the skull just sufficiently to allow the bone to be trephined at each corner of the suggested osteoplastic flap. A ½-in. trephine is usually adequate, and needless to

say, the pin is removed after a groove is cut in the bone. Brisk venous oozing occurs when the diploic area is entered, and a seeker or blunt end of a needle is useful in determining when the dura mater is reached.

When the four trephine holes are completed the intervening bone between them is divided by means of a Gigli's saw. The dura mater is first separated from the skull, and a grooved introducer insinuated through adjacent holes. The saw is passed along the groove, and the bone divided (fig. 550). The cut should be made so as to slightly bevel the bone, so that in the event of replacement of the entire flap, there will be no tendency for the bone to sink beneath its normal level. The bone forming the base of the flap is only partially

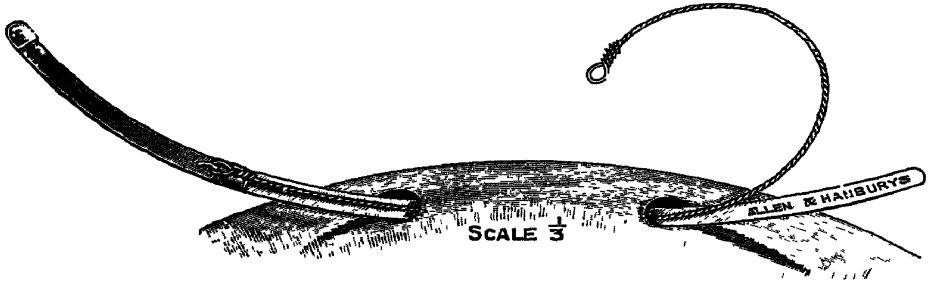

FIG. 550.—Introduction of Gigli's saw by means of a guide, which is passed through adjacent trephine holes.

divided, as complete division will inevitably score the soft parts in the flap. When damage to the scalp appears to be imminent, the remainder of the bone is fractured by inserting a raspatory under the upper border of the bone flap, and applying leverage. The osteoplastic flap is now turned down, and, after examination for any abnormality of the bone, it is wrapped in gauze moistened with warm saline.

The exposed dura mater is inspected, and the absence or degree of pulsation is noted, also the presence of any local discoloration or congestion which sometimes accompany a meningeal tumour. If the dura mater is tense and pulseless, intravenous hypertonic saline may be given, or a few cubic centimetres of cerebro-spinal fluid withdrawn from a lateral ventricle with a fine needle. The dura mater is nicked with a tenotomy knife, and opened by a crucial incision. Any meningeal vessels which cross the path of the proposed incision are previously underrun and ligatured with fine thread. If a tumour is now exposed, its relations are ascertained, and if possible it is removed. A meningioma which lies in a depression in the cortex is readily excised with the portion of dura mater from which it grows. If no tumour is visible, the exposed convolutions are gently palpated, and any suspicious area is explored with a needle. If fluid is withdrawn its character is noted. Probably it is either cerebro-spinal fluid from a distended lateral ventricle, which suggests a deep-seated tumour causing internal hydrocephalus, or else fluid from a gliomatous cyst. In the latter case the fluid is yellowish from altered blood, and slightly viscid in consistency. In either case discretion must

be exercised in the withdrawal of fluid, and only sufficient removed to relieve excessive tension. Otherwise oozing is likely to follow from the choroid plexus in the case of a ventricle, or from the wall of a gliomatous cyst. Some surgeons recommend the injection of 5 c.c. of 2 per cent. formalin into a cyst, in the hope of destroying some of the tumour cells. Radon seeds have been implanted in the wall of a cyst, and in malignant tumours, but with doubtful results.

If needling of a suspicious convolution reveals no fluid, it is probable that a solid growth lies beneath the cortex. The brain substance is then incised in the hope that a tumour will be discovered. Even so the outlook is not promising, as nearly all tumours in the brain substance are malignant, but temporary relief may follow extrusion of part of the tumour.

In the few cases where a tumour is satisfactorily removed, the dura mater is sutured with fine catgut, although many surgeons now consider this to be unnecessary. Even if part of the membrane has been excised, reformation occurs within a few weeks, so that fascial grafts, which were formerly used to remedy the defect, can be dispensed with. The complete osteoplastic flap is replaced and stitched securely in position, the silkworm sutures serving to control hæmorrhage.

In the majority of cases, the tumour is irremovable (or possibly not discovered), or a cyst is merely aspirated. The bone on the osteoplastic flap is then stripped from its pericranial attachment, and the soft parts stitched back into position. The craniotomy thus becomes a decompression.

Should a tuberculoma be suspected, general treatment is instigated, as attempt to remove these tumours is liable to result in dissemination, and death from tuberculous meningitis. Should such symptoms as failing vision or increasing headache persist, then a decompression should be performed, and general measures continued.

DECOMPRESSION OF THE POSTERIOR FOSSA

Intratracheal anæsthesia is advisable, and the head is completely flexed and suitably supported.

The incision most commonly employed is the "crossbow," the horizontal portion of which passes from the base of one mastoid process to the other at a level just below the superior curved lines. The vertical part of the incision passes downward in the midline from the external occipital protuberance to the level of the fourth or fifth cervical spinous process. Owing to division of the occipital nerves, this incision is followed by prolonged anæsthesia of the back of the scalp, and therefore some surgeons prefer a midline incision which commences at about the centre of the vertex and passes downwards to the fifth cervical spine. The soft tissues can be stripped sufficiently from the bone to allow adequate exposure.

In either case, muscles are separated from the bone with a raspatory until the mastoid processes are exposed laterally, and the posterior rim of the foramen magnum and the arch of the atlas are seen at the bottom of the wound. Free bleeding occurs from emissary veins, but is conveniently arrested by means of Horsley's wax.

A ½-in. trephine is applied to the skull in the angle between the superior curved line and the occipital ridge, and a disc of bone

removed. This procedure is repeated on the opposite side, and by means of a Gigli's saw the intervening bridge of bone is removed. Entrance to the posterior fossa now having been gained, the occipital bone is nibbled away as far as the mastoid processes laterally, and downwards so as to include the rim of the foramen magnum. It is advisable also to remove the arch of the atlas, so that subsequent backward bulging of the cerebellum will not compress the medulla against this bony ring, with consequent risk of respiratory failure owing to pressure on the medullary centre.

Should considerable intradural tension be present, as indicated by absence of pulsation, intravenous hypertonic saline should be given, or the upper margin of the flap may be pushed upwards, and a small trephine hole made above the lateral sinus. Through this aperture the lateral ventricle can be tapped with a needle, and a few cubic centimetres of cerebro-spinal fluid withdrawn. These precautions diminish the risk of sudden backward displacement of the brain and consequent pressure on the medulla.

The dura mater is now opened as follows. The occipital sinus is underrun with two sutures at the level of the foramen magnum, and divided between these ligatures, although in many cases pressure has collapsed and emptied the sinus. Incisions are now made in the dura mater in an upward and outward direction on either side so that a triangular flap is turned upwards. The cerebellum is thus exposed, and the posterior fossa is open to exploration. The operation is completed by apposing and suturing the original scalp incision.

In the case of a tumour the site of which is known, such as an auditory nerve fibroma, the corresponding half of the posterior fossa is first removed. Should the tumour be irremovable, the bone on the opposite side is then nibbled away, and the arch of the atlas excised, so that a complete decompression is obtained.

The Pituitary Body

Development and Structure.—This small body, which plays a part in metabolism out of all proportion to its size (5–10 grains), is composed of four portions :

Pars anterior, or anterior lobe, is developed from Rathke's pouch, which is a tubular outgrowth from the roof of the embryonic pharynx. It is composed of two varieties of cells, chromophobe and chromophil. The latter are either eosinophil or basophil, according to their staining reaction. The anterior lobe is well supplied with blood, and its secretion passes directly into the blood-stream.

Pars intermedia.—This portion, with the pars nervosa, comprises the posterior lobe. The pars intermedia is derived from cells of Rathke's pouch, and is represented by a compressed layer of tissue containing clear cells ; in the spaces between the cells colloid material is found, which contains granules. These granules pass through the pars nervosa into the third ventricle. Their function is unknown.

Pars tuberalis.—This is also formed from an off-shoot of the embryonic pharynx. It comprises a mass of cells which encircle the pituitary stalk, and spread thence over the adjacent tuber cinereum,

which is an eminence of grey matter forming part of the floor of the third ventricle, and from the centre of which the pituitary stalk, or infundibulum, is attached. The pars tuberalis is composed of vesicles which contain colloid material.

Pars nervosa, or posterior lobe, arises as an outgrowth from the embryonic brain, and during fœtal life contains a cavity which communicates through the infundibulum with the third ventricle. It is only in mammalia that this portion becomes associated with the remainder of the pituitary body. The pars nervosa contains neuroglial and ependymal cells, and is less vascular than the remainder of the pituitary body.

Function.—During recent years important facts have been added to our knowledge of the functions of the various portions of the pituitary body, but many points still require elucidation. The present state of our knowledge is summarised as follows:

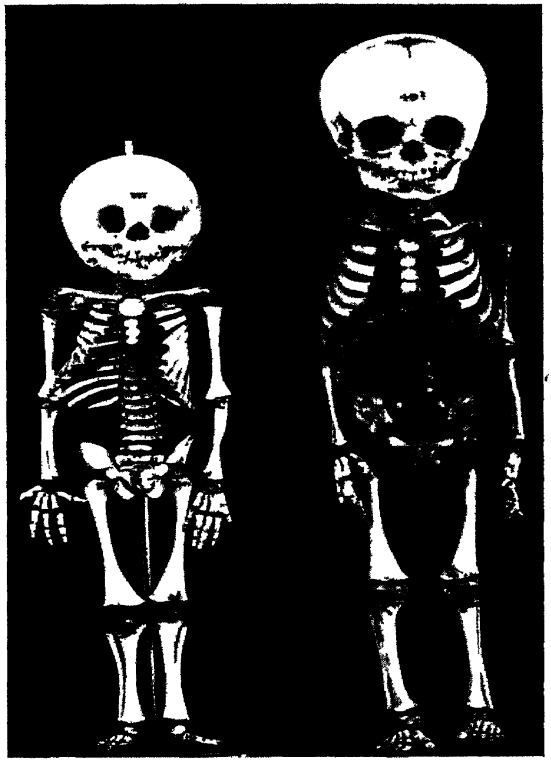

FIG. 551. — *Left.* — Skeleton of "Madame Crachami," who was exhibited as "The Sicilian Dwarf" Aged 9 years, height, 19·8 inches. An example of Loram's syndrome. (R.C.S. Museum, 4175.1.) *Right.*—Skeleton of a normal infant, aged 16 months, for comparison. (R.C.S. Museum, 49.1.)

Pars anterior.—This is concerned chiefly with skeletal growth, and development of the reproductive organs. The cells which regulate growth or sexual activity are probably those of the chromophil type, as these are increased or diminished in numbers according to whether hyper- or hypo-pituitarism is in evidence.

Over-activity of the anterior lobe in children causes gigantism, while patients whose epiphyses have united develop acromegaly. Acromegaly is characterised by

thickening of the subcutaneous tissues, particularly of the face and hands, and overgrowth of certain bones. The normal ridges on the skull are unduly prominent, and an interstitial increase of growth occurs in the mandible, which becomes prognathic, and the teeth separate. Kyphosis occurs in the thoracic region. The phalanges are enlarged, and may develop irregular bony outgrowths. Although acromegaly commences with hyperpituitarism it ends with hypopituitarism, as indicated by loss of sexual activity, deposition of subcutaneous fat, and increasing asthenia.

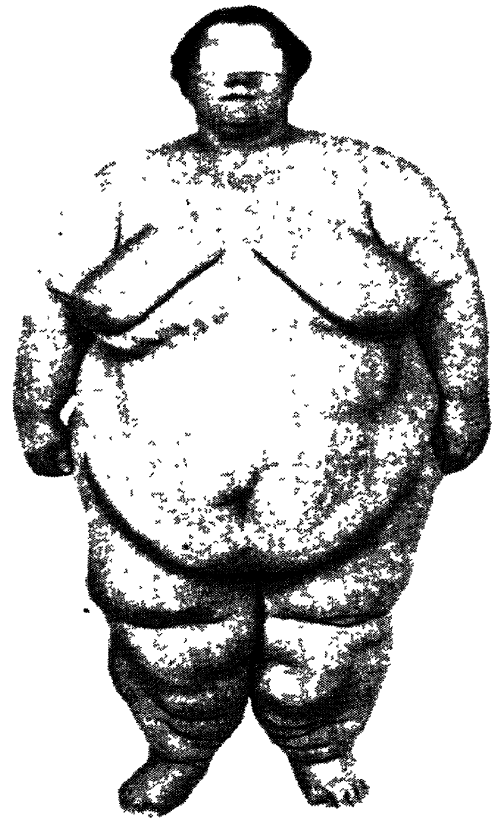

FIG. 552.—Dercum's disease. The patient was 42 years of age, and weighed 372 lb. Radiograph showed enlarged sella turcica. (By the courtesy of George R. Murray and *The Practitioner*.)

Deficiency of the anterior lobe in childhood results in dwarfism (Lorain's syndrome) (fig. 551). The bones retain their normal proportion, but the skeleton is a miniature of the normal. Epiphyses unite at a later period than usual. Secondary sexual characteristics are absent, and in the male the voice remains high-pitched, as the vocal cords do not lengthen. This condition is uncommon, but examples are sometimes exhibited at a circus.

Cushing has recently described a syndrome which is associated with a basophil adenoma of the anterior lobe. The first symptom is impotence in a male, and amenorrhœa in a female. Fat accumulates on the trunk and head and neck, but the limbs remain normal. The hair is redistributed, and baldness of the scalp occurs while the face becomes hirsute. Pigmentation of the skin and kyphosis develop, and in the later stages there is rise of blood-pressure and glycosuria.

Pars tuberalis.—Derangement of this portion of the pituitary body is alleged to result in diabetes insipidus. As the pars tuberalis is in such intimate relationship with the floor of the third ventricle, it is a matter of conjecture whether the polyuria is due to interference with the brain or this portion of the pituitary.

Pars nervosa.—The posterior lobe exercises a profound influence on sexual function and carbohydrate metabolism.

Deficiency in childhood results in Fröhlich's syndrome, or dystrophia adiposa genitalis. The sexual organs are ill-developed, and fat is deposited more or less generally, but particularly around the bust and hips. There is an increased sugar tolerance, and the basal metabolism is lowered. Dercum's disease is alleged to be due to deficiency of the pars nervosa in adults.

This rare condition is almost confined to females, and in addition to a general deposition of fat, local deposits also occur (fig. 552). These fatty tumours are sometimes painful, and in these cases the term "adiposis dolorosa" has been applied.

Tumours.—Tumours of the pituitary body vary according to their nature, position, and the portion of the gland from which they arise.

Adenoma, the commonest variety, is an intrasellar tumour which arises in the pars anterior. These tumours occur after the age of 20, and cause expansion of the sella turcica (fig. 553). The optic chiasma is liable to be compressed, in which case bitemporal hemianopia results.

The tumour is sometimes situated farther forward, so that one optic nerve is affected. If in a posterior position, one or other optic tract is involved, giving rise to homonymous hemianopia. Other nerves which may be affected by pressure are the trigeminal, causing paræsthesia and later pain, and the oculo-motor nerves, which lie in the outer wall of the

sella turcica. Eventually the cavernous sinus is almost obliterated, so that the ophthalmic veins become engorged, and proptosis results. Pressure upwards on the base of the brain is liable to cause glycosuria, diabetes insipidus (*vide supra*), or internal hydrocephalus, from interference with the circulation of cerebro-spinal fluid through the third ventricle.

The adenoma arises from either the chromophobe or chromophil cells. The former is the more common, and the tumour furnishes no secretion, but merely compresses the active remains of the gland. The symptoms are therefore those of anterior lobe deficiency. Chromophil adenomata are associated with the features of increased activity, and therefore these cells are presumed to be capable of secretion. As the patient is usually an adult, acromegaly results.

Cranio-pharyngeal tumours are derived from remains of Rathke's pouch, which lie immediately beneath the dia-

FIG. 553.—Enlargement of the sella turcica caused by a pituitary adenoma.

phragma sellæ. The original cells are squamous in origin, and cystic degeneration commonly occurs, in which case the tumour becomes a suprasellar cyst.

These suprasellar tumours usually occur during the second decade, and are inert as regards function. Symptoms are entirely due to local pressure effects, particularly upon the

optic chiasma. Glycosuria may subsequently develop, but pressure upon the pituitary body and consequent deficiency of secretion only occurs at a late stage.

A radiograph is often conclusive in confirming the presence of a suprasellar tumour. The majority contain sufficient calcium to render themselves opaque to X-rays, and a stereoscopic radiograph indicates their exact position. At a later stage the dorsum sellæ and the clinoid processes are eroded, but there is no expansion of the sella turcica.

Adeno-carcinoma very occasionally occurs in middle life, and consists of a vascular tumour composed of chromophobe cells. Adjacent bone is destroyed, and nerves are involved. If the patient survives for a sufficient period, metastases disseminate by the blood-stream.

Mixed adenomata have been described, composed of both chromophobe and chromophil cells, the latter of the eosinophil type. The former cells produce deficiency by exerting pressure on their neighbours, while the eosinophil cells compensate for this destruction by hypersecretion. These tumours therefore present confusing features in relation to secretion, but local pressure effects ensue.

Treatment.—Surgical intervention should only be contemplated in the event of intolerable headache, or symptoms due to local pressure effects, such as impending blindness or neuralgia following involvement of the trigeminal nerve. It is of the utmost importance to distinguish between a suprasellar and an intrasellar cyst, and as mentioned above, the age of the patient, the clinical features, and a radiograph all assist in making a correct diagnosis.

An *intrasellar* tumour is usually approached by the trans-sphenoidal route, either under general or local anæsthesia. The inferior turbinate bones are removed, and submucous resection of the nasal septum allows approach to the sphenoidal air sinus. A special speculum is utilised in order to retract the muco-periosteal flaps, and the sphenoidal air cells are removed piecemeal, so as to open the sella turcica. This procedure allows extension of a tumour in a downward direction, and so relieves pressure on the structures in the sella turcica and on the base of the brain. No attempt should be made to remove a tumour by this route, owing to the intimate relationship of the cavernous sinus and internal carotid arteries. Headache and visual disturbances rapidly improve, and if necessary this procedure can be repeated at a later date.

Suprasellar tumours are removed through an osteoplastic flap, which is turned outwards in the frontal region. The operation should be performed on the side of the blinder eye. The incision commences an inch above the zygomatic process of the temporal bone, and passes inwards, following the upper margin of the eyebrow. It is then

carried vertically upwards for 4 inches, and outwards to the anterior and upper part of the temporal fossa. Trephine holes are made at each corner of this rectangular incision. Care must be taken not to open the frontal sinus while making the lower and inner trephine opening. Usually the intact mucoperiosteum can be separated from the bone and pushed downwards. If the sinus is inadvertently opened the osteoplastic flap can be completed, but the remainder of the operation must be postponed for ten days in order to avoid the risk of meningitis.

The trephine holes are connected with a Gigli's saw, and the osteoplastic flap turned outwards. The exposed dura mater is separated from the orbital plate. At this stage of the operation the patient's head should be hyperextended (Rose's position), so that the weight of the brain causes it to fall away from the anterior fossa. The dura is separated as far as the lesser wing of the sphenoid, and then divided with a tenotomy knife. The optic nerve is identified and followed backwards to the chiasma and sella turcica. The cyst or tumour is then removed, usually piecemeal, but as completely as possible. A successful operation should be followed by complete cure provided that local pressure has not permanently damaged adjacent nerves, particularly the optic.

This method of approach has also been utilised to allow implantation of radon seeds into intrasellar tumours, with some measure of success.

CHAPTER XXVIII

THE SPINE

Sprains in connection with the spinal column are of common occurrence. Spinal ligaments are sometimes injured as a result of a sudden jolt, as in car or railway accidents. Fibres of spinal muscles are occasionally torn by excessive muscular contraction, as in attempting to lift heavy weights, or damage may result from a direct injury. In either case severe localised pain follows, accentuated by any movement which stretches the damaged structure. Palpation reveals a tender spot, and if muscular fibres are torn, some bogginess is often detected, due to extravasation of blood. An exact diagnosis is usually difficult, but an X-ray excludes or reveals injury to bone. Treatment consists in rest and cold applications, followed a few days later by massage and graduated movements. The time required for complete recovery is often surprisingly long, particularly if litigation is pending. In more severe injuries the ligamentum subflavum is occasionally torn, and hæmatorachis is then likely to follow. Laminectomy is sometimes indicated in these cases (*vide infra*).

Dislocation

A *true* dislocation can only occur in the cervical region, as the oblique and vertical direction of the articular processes in the dorsal and lumbar regions respectively do not permit of dislocation without fracture.

Dislocation following hanging occurs between the atlas and the axis. Forward displacement of the atlas follows rupture of the transverse ligament, or less commonly fracture of the odontoid process. As a general rule (fig. 554) death occurs immediately owing to compression

of the cord, and is due to shock and paralysis of all the muscles of respiration. Dislocation at this level has also occurred as a result of lifting a child by means of the hands encircling the neck from behind.

Dislocations at a lower level most commonly occur between the fifth and sixth vertebræ. The classical cause of this accident is diving into shallow water, which causes excessive flexion of the upper part of the spinal column. The inferior articular process of the fifth vertebra is forced



FIG. 554.—Radiograph taken through the open mouth, showing fracture of the base of the odontoid process. The cord was not injured. (Mr. W. H. Gabriel's case.)

over the front margin of the superior articular process of the sixth. The condition can occur on one or both sides.

If the dislocation is unilateral, the face is turned towards the opposite side, and movement is restricted. Severe pain may be referred along the nerve root, which is nipped in the intervertebral notch. The dislocation is usually readily reduced under general anæsthesia, by further flexion of the head, followed by lateral flexion towards the opposite side. If reduction fails, the joint should be exposed, and a minimum of bone removed in order to allow unlocking. If the dislocation is unreduced, pain and deformity will persist.

Involvement of the spinal cord is uncommon in the case of one-sided dislocations. Bilateral dislocations are serious injuries, in that some degree of associated damage to the

cord often occurs, usually of a complete nature. In rare and fortunate cases, owing to the large size of the spinal canal, the cord escapes serious injury.

In bilateral cases the head is displaced forwards, and obvious deformity is present. Pain is referred down the neck and arms on both sides.

TREATMENT consists in a very careful attempt at reduction, for even if complete paraplegia is present, it is possible that the cord involvement is partially due to spinal shock, or to pressure of the displaced bone or extravasated blood. An anæsthetic is given, and traction exerted on the flexed head, counter-traction being applied to the shoulders by an assistant. If this manœuvre fails, then open operation is performed. If a further attempt at reduction under direct vision fails, then a minimal amount of bone is removed from the articular processes until unlocking is possible. The articular processes should then be fixed by means of a wire loop in order to prevent recurrence. (Associated injuries to the spinal cord are discussed on p. 604.)

FRACTURES

Incomplete fractures are those which do not interfere with the continuity of the spinal column. They include the spinous and transverse processes, laminæ, and fissures or compression of a vertebral body. Fractures of the processes or laminæ are due to direct violence. The most common situation for fracture of a spinous process is the dorsal region, where these processes are relatively long. Localised pain and perhaps crepitus suggest the nature of the injury, which is verified by a radiograph. Fracture of the transverse processes occurs most usually in the lumbar region, where these processes are long and comparatively unprotected. Injury to the corresponding kidney is a frequent accompaniment. Fracture of a lamina may be associated with depression of bone and consequent involvement of the underlying cord, in which case laminectomy is indicated.

Compression fractures of a vertebral body may cause immediate damage to the cord, otherwise persistence of pain usually demands an X-ray examination which reveals the nature of the injury. In

a few cases, where the symptoms are slight or the condition has been overlooked, a rarefying osteitis develops some months later—a condition sometimes known as Kümmell's disease. Pain, deformity, or cord involvement leads to an X-ray examination, which reveals rarefaction and collapse of the body of a vertebra, usually in the lumbar region (fig. 555). Support to the spine is necessary for one year, although Albee's bone-graft operation finds favour with some surgeons.

Complete fractures arise as a result of direct or indirect violence. In the former case the injury occurs at any

FIG. 555.—Kummell's disease affecting the first lumbar vertebra.

level, but fractures due to indirect violence are usually in the cervico-dorsal or dorsi-lumbar regions. The separation most commonly occurs through an intervertebral disc, which carries with it a portion of the front of the vertebral body below. Therefore the injury is in reality a fracture-dislocation.

Damage to the spinal cord is due to the displacement forwards of the upper part of the spine, so that the cord is pressed against the body of the vertebra below the lesion. In the adult the spinal cord ends at the level of the lower border of the body of the first lumbar vertebra, hence lesions above this level are likely to be associated with cord injury, while fracture below the first lumbar vertebra

may be complicated by injury to the cauda equina or some of its component parts. The cord is sometimes completely crushed, although the dura mater is not perceptibly damaged.

The prognosis of fracture of the spine depends on the level and extent of injury to the spinal cord. If the cord is totally destroyed the following changes occur:

(*a*) *Sensory.*—Complete anæsthesia at and below the level of the lesion, with hyperæsthesia of the segment above, due to irritation by the disintegrating cord.

At a higher level dissociation of sensation occasionally occurs, due to blood passing upwards within the central canal of the cord and interfering with the adjacent fibres which conduct temperature and pain. This phenomenon therefore resembles the sensory changes associated with syringomyelia, and is of academic interest only.

(*b*) *Motor.*—Complete paralysis of all muscles below the site of the lesion. After spinal shock has abated, spasticity and contractures may follow, as the lesion is of the upper neurone type. At the actual site of the lesion the anterior horn cells are crushed, and therefore flaccid paralysis occurs and continues in connection with the muscles supplied by that segment. This is followed by rapid wasting and reaction of degeneration. The segment above the lesion is irritated by disintegration of the crushed cord, and therefore the muscles innervated by this segment are spastic.

(*c*) *Reflexes.*—All superficial and deep reflexes disappear, but after about three weeks, extensor responses reappear in an exaggerated form, and a "mass reflex" appears. Thus an effort to obtain a plantar reflex causes excessive contraction of the muscles of the leg and thigh, and possibly automatic emptying of the bladder. This "mass reflex" is an unequivocal sign that the cord is irreparably destroyed.

(*d*) *Visceral.*—During the period of spinal shock incontinence is present, but within a few hours the sphincter regains its tone and retention supervenes. Unless relieved the bladder becomes overdistended, and the musculature overstretched and permanently damaged. If this calamity

is allowed to occur the urine dribbles away from the overflowing bladder, and even if the bladder is emptied by a catheter the power of contractibility is lost. If overdistension is prevented, and the patient survives, then micturition will probably become automatic, i.e. the bladder empties itself when the intravesical tension reaches a certain level, or the automatic micturition may be stimulated by such procedures as scratching the thigh, or prostatic massage.

Similarly, the anal sphincter is temporarily paralysed, but after recovery from shock a state of spasm supervenes, which encourages constipation. The centre for both the bladder and the rectum is situated in the lumbar enlargement, damage to which is followed by true and permanent incontinence of fæces and urine.

(*e*) *Trophic.*—Severe trophic changes are liable to occur in parts which suffer from deranged innervation. Bedsores are common, and are a frequent contributory cause of death. Ghastly destruction of tissue sometimes follows paraplegia, the buttocks slough, and necrosis of the sacrum occurs, even in spite of every prophylactic measure. Fortunately, the patient is often entirely unaware of the condition. Similarly, cystitis in the case of a paralysed bladder may be followed by extensive sloughing of the mucosa.

The phenomena which follow cord injuries at different levels are summarised as follows :

Cervical.—If above the fifth segment all the respiratory muscles are paralysed, including the diaphragm, which receives its motor supply from the phrenic nerve, mainly the C iv segment.

If the fifth segment is injured the arms are completely paralysed. A lesion of the sixth segment results in the arms being abducted and externally rotated, with the forearms flexed and supinated. This position is due to irritation of the fifth segment, and consequent spasticity of the muscles innervated by it, the most important being the deltoid, spinati, biceps, brachialis anticus, and supinators. Similarly, a lesion through the seventh segment causes irritation of the sixth, with spasticity of the serratus magnus, part of the pectorals, and the pronators ; consequently, the arms are drawn forwards and adducted, the forearms being flexed by the pronator radii teres and pronated by both this muscle and the pronator quadratus.

Dorsal.—Injury at the level of the second dorsal segment is liable to cause contraction of the pupils owing to irritation of the oculo-pupillary fibres, which leave the spinal cord at the segment above.

Also hyperæsthesia may extend along the inner side of the arms. At lower levels a band of hyperæsthesia is usually detected encircling the trunk, and is present one segment above the site of the injury. Destruction of the cord at any level above the mid-dorsal region results in paralysis of the abdominal muscles, but below this level the paralysis is partial, depending on the actual site of injury.

Lumbar.—The lumbar enlargement corresponds to the twelfth dorsal and first lumbar vertebræ, and it contains the centre for nervous control of the urinary bladder. An injury above this level prevents inhibitory impulses from the cortex reaching the centre, and after a period of retention, due to spinal shock, automatic micturition occurs. If the lumbar enlargement, or the nerves passing from it to the bladder (principally the third and fourth sacral), are damaged, then absolute incontinence follows from paralysis of the sphincter.

Also the centre for defæcation is situated in the lumbar enlargement, damage to which is followed by a patulous anus and incontinence of fæces.

Cauda Equina.—Injuries to the nerves in the spinal canal below the level of the lumbar enlargement give rise to a degree of disability which corresponds with the actual nerves involved. If the lesion occurs just below the formation of the cauda equina the legs and perineal muscles are completely paralysed, also anæsthesia of the legs and a saddle-shaped area in the perinæum are present. As mentioned above, the patient will suffer from true incontinence of fæces and urine. Injury at a lower level will not affect nerves which arise from the upper lumbar segments, e.g. the anterior crural, obturator, genito-crural, so that corresponding groups of muscles are spared, and anæsthesia of the legs is incomplete. Thus, if the anterior crural nerve is intact, sensation remains on the front of the thigh, and along the distribution of the internal saphenous nerve, i.e. the inner side of the leg and foot as far as the ball of the big toe.

Partial lesion of the cord occasionally occurs, in which case the motor elements are more liable to remain affected than the sensory. This is explained by the fact that the anterior portion of the cord suffers most, as it is pressed against the body of the vertebra below the injury, and this part of the cord is composed chiefly of motor fibres and anterior horn cells.

Clinical Features.—Evidence or history of an accident of some violence is probably obtainable. Profound shock frequently accompanies the injury, but the patient may be able to state that he has severe pain in the back, or girdle pains encircling the body, or that he "feels dead" below a certain level.

On examination the utmost gentleness must be exercised in order that a cord which has escaped injury, or which is only partially damaged, is not further injured. Deformity of the vertebral column may be noticed, but if the patient has been turned on to his back "recoil" usually follows,

and the spinal column regains its alignment. In cases due to direct injury local bruising or extravasation is commonly seen.

Paraplegia and anæsthesia extending from the level of the lesion are usually present and are either due to spinal concussion, or pressure on or actual crushing of the cord. A more detailed examination is postponed until the patient is safely installed in a suitable bed, and a programme has been outlined for his subsequent treatment. If considered desirable a radiograph is taken, with due precautions regarding any necessary movement of the patient.

Treatment.—First-aid treatment consists of transport of the patient, face downwards, on a rigid stretcher, care being taken that he is lifted without bending or torsion of the unstable spine. Morphia should be given to alleviate shock and anxiety. On arrival at his destination a bed provided with a "three-piece" mattress should be in readiness, which facilitates nursing, as the central portion can be withdrawn with a minimum of disturbance to the patient.

Symptomatic treatment is now instituted, while recovery from general or spinal shock is awaited. It is essential that overdistension of the bladder is avoided, otherwise, if the spinal cord recovers, permanent paralysis of the bladder will remain, or if the cord is irremediably damaged, micturition will never become automatic. Catheterisation is the usual method of treatment. Utmost aseptic precautions must be taken, and irrigation of the anterior urethra with weak antiseptics (e.g. oxycyanide of mercury 1 : 4,000) prior to catheterisation is an additional safeguard. Expulsion of urine by suprapubic pressure was a war-time expedient, but in civil practice more deliberate measures have replaced this procedure. In spite of every precaution cystitis often develops, and some surgeons then recommend suprapubic cystostomy in order to obviate retention and so discourage infection ascending to kidneys.

The possibility of bedsores should be a constant bogy to the nursing staff, and although these sometimes develop in spite of every precaution, prophylactic measures should never

be relaxed. Ring pillows are used to protect parts which are necessarily subjected to pressure, and when union of the fracture is sufficiently strong a water bed should be substituted for the mattress. The skin is kept scrupulously clean, and hardened by some suitable preparation, e.g. brandy and white of egg, eau de Cologne, or 1 per cent. aqueous solution of formalin, and dusted with antiseptic powder, bismuth subgallate, otherwise known as Dermatol, being very suitable for this purpose. If bedsores develop they are treated according to their nature and depth, but destruction of tissue sometimes continues in a most distressing manner.

Attention to the bowels is necessary, and purgatives or enemata should be administered. If meteorism is allowed to occur, upward displacement of the diaphragm causes pulmonary embarrassment. Hypostatic pneumonia is a grave danger, particularly if important accessory muscles of respiration are paralysed, e.g. abdominal muscles, in which case coughing and expectoration are hampered. At a later date contracture of muscles should be discouraged by frequently straightening the limbs.

Spinal shock should show some evidence of abatement at the end of forty-eight hours. If no sign of recovery is evident after the expiration of this period, then the prognosis is gloomy, and hopelessness is confirmed by the subsequent development of "mass reflex" (*vide supra*).

The method of election for the treatment of fractures of the vertebral bodies is immobilisation by plaster in a position of hyperextension.

The fracture is caused by excessive flexion of the spine, and hyperextension corrects this deformity, and relieves any existing pressure on the cord or nerves. In some cases no anæsthetic is necessary, but if advisable general, or local and paravertebral, anæsthesia is administered. Hyperextension is effected by laying the patient prone between two tables, the one which supports the head and arms being 12–18 inches higher than the table on which the legs and pelvis rest. The trunk is covered with a stockinette vest, and the plaster is applied from the pelvis below to the axillæ



FIG 556 —Application of plaster for fractured spine. (*La Presse médicale.*)

above (fig. 556). In the absence of cord involvement, ambulation and arm and leg exercises are commenced in a few days. A completely crushed vertebra consolidates slowly, so the jacket must be worn from four to six months. In cases of paraplegia, the hyperextension relieves compression and consequent anæmia of the cord, and in the absence of transection the paraplegia and root symptoms usually disappear (fig. 557).



FIG. 557.—*Left.*—Crush fracture of the fourth lumbar vertebra, with total paraplegia and fourth lumbar root palsy. *Right.*—After reduction by hyperextension and plaster. The paraplegia recovered in a few weeks, and the root palsy in twelve months. (By the courtesy of R. Watson Jones and the *B.M.J.*)

Laminectomy as a rule yields disappointing results, but should be considered in the following instances :

(i) Paraplegia partially recovers, and then "marks time." This suggests that complete recovery of function is prevented by some mechanical cause, such as depressed bone or blood-clot. This type of case yields the best results from operative treatment.

(ii) Damage to the cord is incomplete at the time of the accident, and remains stationary.

(iii) The cord lesion is incomplete or non-existent at the time of the accident, but progresses or develops later. An example of this type is the "gravitation paraplegia," described by Thorburn, due to hæmorrhage within the spinal canal filling the canal from below upwards. Laminectomy may reveal the source of the bleeding and permit of its arrest.

(iv) Lesions of the cauda equina, as the anterior roots may be sutured with some prospect of success. Division of a posterior root results in degeneration of intramedullary and non-medullated fibres, and consequently regeneration is impossible.

It must be emphasised that laminectomy performed as a speculative measure in cases where paraplegia is complete from the time of the injury is to be condemned strongly.

Complications.—Death may result immediately from shock, or from cessation of respiration if the lesion is above the fifth cervical segment.

Hypostatic pneumonia is liable to develop after a few days, especially if the lesion is sufficiently high to cause paralysis of abdominal and intercostal muscles.

Ascending myelitis occasionally occurs (p. 610).

Cystitis has been mentioned, and infection from the bladder is prone to infect the kidneys, causing death from pyelonephritis (*syn.* surgical kidneys). Necropsy reveals the renal cortex and pelvis studded with abscesses and areas of acute inflammation.

Allusion has been made to bedsores, which hasten death owing to toxic absorption. Meningitis serosa circumscripta more commonly follows an injury of less severity than a fracture, but does occasionally occur. This condition is due to a traumatic meningitis which is followed by adhesions and a localised collection of fluid between the meninges. It is of little importance if the spinal cord is otherwise involved.

If the patient recovers, traumatic neurasthenia may persist as a troublesome sequela, in which case complaint is

made of lassitude and indefinite pains in the back. Cure sometimes follows satisfactory litigation.

Fracture of the manubrium sterni is occasionally associated with fracture-dislocation of the dorsal spine.

Injuries to the Spinal Cord

The spinal cord is frequently implicated in association with injury to the spinal column.

The commoner injuries to the cord are as follows :

Spinal Concussion.—In severe cases complete paraplegia and anæsthesia follow, and it is then impossible to distinguish concussion from a gross cord injury, e.g. a crush. In milder cases temporary paresis results, with weakness of sphincteric control.

Treatment is symptomatic, and consists of careful nursing, including attention to the skin, bladder, and bowels. If the case is merely one of concussion, some return of voluntary power or sensation is usually evident within forty-eight hours.

As time passes without improvement, the prognosis becomes increasingly gloomy, until the development of " mass reflex " indicates irremediable destruction of the cord.

Myelitis sometimes follows spinal injury (although it more commonly occurs as a complication of such conditions as gastric ulcer or grave anæmia). Severe local and referred pain occurs, with paraplegia. As the cord disintegrates these features spread upwards. Thus the upraised arms so typical of a lesion of the sixth cervical segment (p. 604) gradually collapse, as the fifth segment is destroyed. If the patient survives for a sufficient time, spinal myelitis tends to spread upwards, so as to cause death from respiratory failure or bulbar paralysis.

Hæmorrhage occurs either in the cord itself, or as an extramedullary condition, and in the latter case the blood either escapes into the cerebro-spinal fluid, or outside the dura mater, as in the case of a torn ligamentum subflavum. Extradural hæmorrhage may gradually fill the spinal canal from below upwards, causing progressive irritation of the cord, followed by paraplegia (Thorburn's gravitation paraplegia). Intradural hæmorrhage is indicated by the presence of blood in the cerebro-spinal fluid following a lumbar puncture.

Intramedullary hæmorrhage causes symptoms which immediately follow the injury. Destruction of the anterior horn cells causes a flaccid paralysis of the muscles concerned, while irritation of the pyramidal tracts results in some spasticity of the spinal muscles or legs. Pain and irritation are much less in evidence than in cases of extramedullary hæmorrhage.

Treatment in the first instance is symptomatic, and lumbar puncture is useful in order to detect intradural hæmorrhage. In certain cases laminectomy may be considered (p. 609).

Meningitis.—Acute infective meningitis is likely to follow a penetrating wound, or is an occasional and unfortunate complication of laminectomy. Severe constitutional disturbances follow, with local and referred pain, hyperæsthesia, muscular spasms, and increased reflexes. Extension to the basal meninges is usual, and then death inevitably results. Chronic meningitis sometimes follows a local injury, and occasionally leads to the condition dignified by the title of "Meningitis serosa circumscripta." This is characterised by the formation of a subdural cyst or cysts, which gives rise to features somewhat resembling a tumour, some months after the receipt of injury. Laminectomy and removal of the cyst is followed by considerable relief or cure.

Neurasthenia is a frequent sequela of spinal injury, and is either of the generalised type, or referred particularly to the spine. In the latter case vague pains in the back, localised areas of hyperæsthesia, and girdle pains are the main features. The erstwhile term of "railway spine" is now somewhat obsolete, as motor-buses and trams contribute their quota of cases.

Treatment is often disappointing. After an adequate period of rest more energetic treatment is substituted, including massage and exercises, reinforced with tonics. Satisfactory litigation sometimes results in a cure, even in stubborn cases.

Osteoarthritis.—This troublesome complaint is occasion-

ally alleged to be caused by an injury to the spine. Probably in the majority of cases the osteoarthritis was already present and discovered when a radiograph was taken to exclude a bony lesion following an injury. In the case of a patient seeking compensation, it is only fair to assume that a pre-existing osteoarthritis can be aggravated by injury to the spinal column.

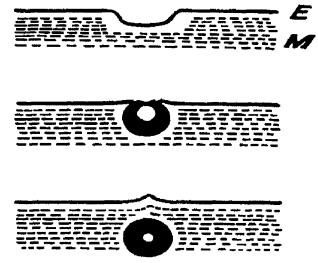

FIG. 558.—Development of the spinal cord. E = epiblast, M = mesoblast.

SPINA BIFIDA

Embryology.—During the second week of intra-uterine life a longitudinal furrow appears on the dorsum of the embryo, this groove being formed by involution of the epiblast. The margins of the groove unite, so that it becomes converted into a tube, from which the nervous system is developed. This epiblastic tube becomes separated from the surface by mesoblast, which grows over it from either side, and from which are developed the vertebræ, spinal muscles, membranes, etc. (fig. 558). In each segment bars of cartilage appear on either side of the neural tube, which during the fourth month fuse with each other to form the vertebral arches. Failure of fusion of these arches gives rise to spina bifida, which is frequently associated with maldevelopment of the spinal cord and membranes. The incidence of spina bifida, excluding occulta, is ·1 per cent. of all births.

FIG. 559.—X-ray of a myelomeningocele after replacement of fluid by oxygen. The spinal cord is seen entering the sac, and nerve roots are passing from it to re-enter the vertebral canal. (*Medical Annual*, 1931.)

The types of spina bifida are as follows :

(i) *Spina Bifida Occulta.*—Due to failure of the neural arches to unite, but there is no protrusion of cord or membranes. Frequently only one vertebra is affected, usually in the lumbar region. Unless a patch of hair or a depression in the skin is present, either of which should suggest the condition, the deficiency

is only recognised if a radiograph is taken for some other reason, when absence of the spinolaminar segment is noticed.

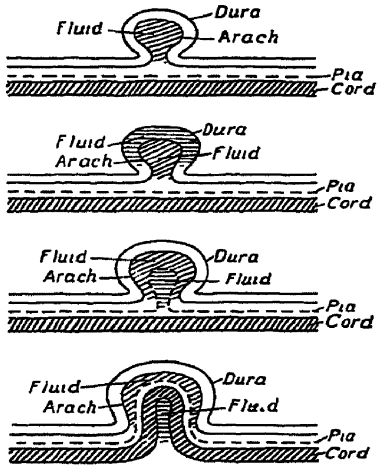

FIG. 560.—Illustrating the various types of meningoceles. (*Medical Annual*, 1931.)

(ii) *Meningocele.*—Is essentially a protrusion of meninges containing fluid, through a defect in the spinolaminar segment (fig. 559). Three types certainly exist, and possibly in rare cases a portion of cord is protruded into the sac (fig. 560).

(iii) *Meningo-myelocele.* — The normally developed spinal cord or cauda equina lies in the sac, and may be adherent to the posterior aspect (fig. 561). The cord or nerves can be seen as black shadows on transillumination.

(iv) *Syringo-myelocele.* — The rarest type of spina bifida, in which the central canal of the cord is dilated and lies within the sac, together with the nerves arising from it. This type is sometimes termed a myelocystocele.



FIG. 561.—A typical meningocele, which was successfully excised.

(v) *Myelocele* results from arrest of development at the time of closure of the neural furrow. In the lumbo-sacral region an elliptical raw surface is seen, which consists of the un-united groove, and at the upper end the central canal opens on the surface and discharges cerebro-spinal fluid.

With the exception of spina bifida occulta, myelocele is the most common type of spina bifida, but many cases are stillborn, and therefore of no clinical interest. If the child is born alive death ensues within a few days, from infection of the cord and meninges.

For practical purposes interest centres round meningoceles and meningo-myeloceles. The two conditions are distinguishable on transillumination, and a depression in the skin due to adherent cord or nerves is sometimes seen in a meningo-myelocele. Interference with the spinal cord or nerves is likely to be associated in either condition. This is obviously liable to be more severe in cases of meningo-myeloceles, in which condition bilateral talipes with trophic changes are common, and in more advanced cases extensive paralysis of the legs and incontinence are present.

If associated nervous phenomena are present the diagnosis of spina bifida is obvious. Cases of meningocele without nerve involvement may present difficulty, especially if occurring in the cervical region. Moreover, a fatty pad occasionally lies over the sac, and thereby masks its physical features. A radiograph will indicate deficiency of neural arches in doubtful cases (fig. 562).

Treatment.—Operation is necessary if the sac increases in size at a rate out of proportion to the child's growth, as it is obvious that the skin over the sac will become gradually thinner and atrophic from increasing pressure, until it finally gives way. The surgeon should therefore interfere while the integument is still healthy.

In other cases the sac should be protected by means of a celluloid cup, and events awaited. Operative interference is not without risk, and if performed under the age of two years shock is considerable and a fatal issue may result from immediate infection or following a persistent sinus from which cerebro-spinal fluid escapes. Moreover, some otherwise successful cases have subsequently developed hydrocephalus.

Operation entails exposure of the sac by means of an incision to one side of the midline. The sac is opened and

redundant membrane excised. If the cord or nerves are adherent they are mobilised if possible, otherwise they are separated with a strip of attached membrane or skin and replaced in the vertebral canal.

Membranes are sutured over the cord, the sutures being placed on the opposite side to that of the skin incision. Spinal muscles are approximated, and the wound is rein-

FIG. 562.—Spina bifida, showing cleft in the spinolaminar segment of the fifth lumbar vertebra, and absence of the posterior part of the sacrum.

forced with flaps of sheath from the erector spinæ muscles. We have seen no good results arise from such procedures as tapping, or the injection of irritants, e.g. Morton's fluid, and in these days of aseptic surgery operation is to be preferred if interference is necessary.

A complication of spina bifida occulta consists of nervous phenomena arising during growth, usually between the ninth and twenty-fourth years. The explanation of this late development of symptoms is that a fibrous band, the membrana reuniens, connects the skin with either the spinal cord, nerves, or membranes. In the early months of fœtal life the spinal cord ends opposite the coccyx, at birth the cord extends to the third lumbar vertebra, and in adult

life to the lower border of the first lumbar vertebra. Thus as the spinal canal grows away from the spinal cord traction is liable to be exerted by the fibrous band upon the membrane, nerves, or cord itself. The symptoms which follow include weakness or sensory disturbances in the legs, incomplete control of the sphincters, or perforating ulcers of the feet. It should be a golden rule that in all patients who present themselves with symptoms referable to the lower limbs or sphincters, a methodical examination is made of the vertebral column. As already mentioned, a lipoma or tuft of hair may suggest the presence of an underlying defect, but in any case a radiograph will reveal the absence of one or more neural arches.

The onset of nerve symptoms is a definite indication for operation. On the under-surface of the skin or deep fascia a tough fibrous band is encountered, which is traced down to the point where it passes through the bony cleft and is attached to the dura mater. The dural sheath is opened, and if the band is adherent to the nerves or cord, separation is effected and the band excised.

Successful removal of a band is likely to be rewarded by improvement in the nervous symptoms, especially if these symptoms have not appeared until adolescence.

Inflammatory Diseases

Acute osteomyelitis occasionally occurs, either in connection with the epiphysis for the body of the vertebra, or more rarely, with one of the epiphyses from which the neural arch develops. The main features are severe constitutional disturbances, associated with local pain and tenderness. If the disease commences in a neural arch, some local evidence of inflammation is often detected, and invites exploration. Acute osteomyelitis of a vertebral body is usually discovered at necropsy, and has been mistaken for spinal meningitis, acute appendicitis, acute pancreatitis, and other abdominal conditions.

In cases of acute osteomyelitis of a lamina, free removal of bone is indicated, and the wound only partially closed. Attempts have been made to deal with osteomyelitis of a vertebral body in the cervical area by means of an incision behind the sterno-mastoid muscle. If the focus of infection is in the dorsal or lumbar regions, efficient drainage is difficult to obtain even if the condition is suspected.

Tuberculous disease (*syn. Pott's disease*) occurs at any age, but in more than half the cases children in the first decade are affected. The most common region is from the tenth dorsal to the third lumbar vertebra.

The disease commences either in the body of the vertebra, or in the periosteum under the anterior common ligament.

The endosteal type nearly always affects children, and commences in the anterior part of a vertebra. This is due to the fact that the

infection is blood-borne and the nutrient artery enters the vertebral body on the posterior aspect, so that organisms are arrested in the capillary loops by which the anterior part of the bone is nourished. As the epiphyseal plates are incomplete, infection readily spreads to adjacent vertebræ.

Owing to rarefaction and destruction the front of the affected vertebræ collapses, but the posterior part is held rigid by interlocking of the articular processes, and an angular deformity results (fig. 563).

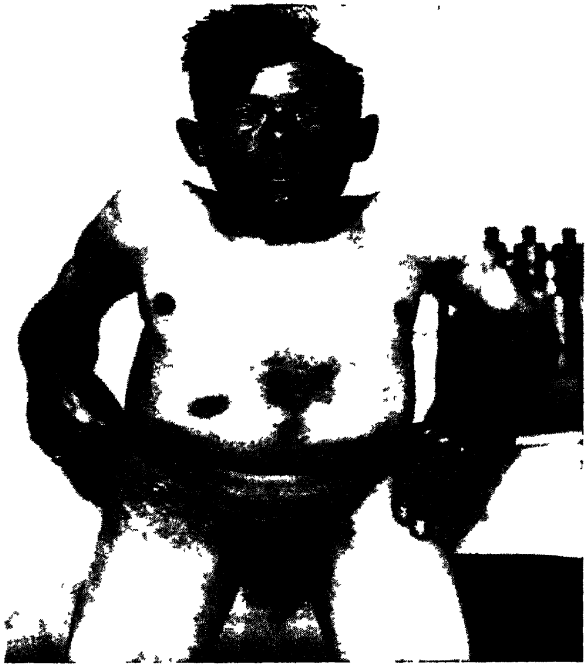

FIG. 563.—Typical hunchback of Pott's disease, with a psoas abscess pointing below Poupart's ligament.

The periosteal type affects adults, and causes erosion of the anterior aspect of several vertebral bodies, so that a gradual curvature results.

Clinical Features.—These vary to some extent according to the site of the disease, but in any situation the following features are likely to be in evidence.

Symptoms.—The general symptoms include lassitude, asthenia, and if the patient is a child, fretfulness and peevishness.

Pain and deformity comprise the local symptoms, either of which may first be noticed. Pain occurs as a local ache, or is referred along the spinal nerves which correspond to the affected segments. Deformity occurs in the early stages if the bodies are affected, and is sometimes the first indication of the disease. Kyphosis is the most common type (fig. 564), but scoliosis occasionally occurs.

Signs.—A systematic examination of the whole of the spinal column must be made.

Rigidity is a constant sign, and inability or unwillingness to bend the back is well demonstrated by requesting a patient to pick up an article from the floor, in which case the knees are bent and the patient assumes a squatting

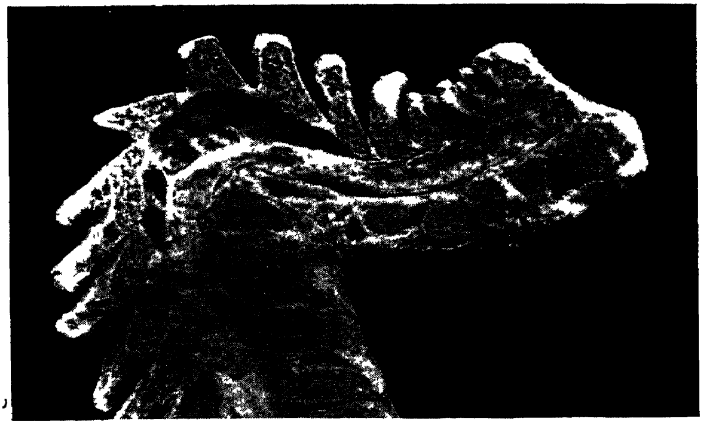

FIG. 564.—Pott's disease, with gross angular curvature.

position. Active movements of flexion, extension, and lateral rotation are carried out, and if no abnormal restriction is discovered the possibility of Pott's disease is remote.

Deformity is either a symptom or a sign, and if more than slight it has probably already been noticed by the patient or, if a child, by its mother or nurse.

Abscess formation is a common feature with Pott's disease ; the site and direction depend upon the portion of the spine affected (*vide infra*).

Paraplegia is seen less frequently than formerly, owing to earlier diagnosis and more efficient treatment. It is rarely if ever due to deformity, as the cord adapts itself to this slow process. It arises as a result of pachymeningitis, or pressure by granulation tissue, abscess, or possibly a portion of necrosed bone. Spasticity of the legs is the first symptom of threatening paraplegia, and may even be the first evidence of spinal caries. Sensory disturbance and loss of sphincteric control follow.

Features of the disease at different levels:

Cervical Region.—The body of the second cervical vertebra is occasionally affected, or even the odontoid process, which represents the body of the atlas. Pain is experienced over the distribution of the second cervical nerve, and the head is fixed owing to spasm of the suboccipital muscles. The transverse ligament or the odontoid process is liable to become eroded, and in either case the head may suddenly slip forwards with immediate fatal results.

If vertebræ at a lower level are affected pain is experienced over the distribution of the corresponding spinal nerves. A retropharyngeal abscess sometimes occurs, and may be seen or palpated. The pus erodes the longus colli muscle, and lies beneath the prevertebral fascia, as distinguished from an acute abscess (see p. 192), which is submucous.

The abscess either tracks laterally and appears in the posterior triangle, or in the case of the lower cervical vertebræ, it passes downwards beneath the fascia into the thorax. If allowed to persist, the prevertebral fascia is destroyed, and cases have occurred where the abscess has burst into a pharynx. Even if the patient is not suffocated secondary infection follows, with its attendant evils. Therefore a retropharyngeal abscess must be evacuated as soon as it is recognised, by an incision behind the sternomastoid muscle, which is displaced forwards with the carotid sheath. After evacuation the muscles, fascia, platysma, and skin are carefully and completely closed in separate layers. A radiograph of the upper four cervical vertebræ should be taken through the open mouth, so that the vertebral bodies are not obscured by the lower jaw.

Thoracic Region.—If the first dorsal vertebra is affected pain is referred along the inner side of the arm, at a lower level intercostal neuralgia is likely, and abdominal pain and rigidity sometimes follow involvement of the eighth to the twelfth dorsal vertebræ (the appendix has been removed in such cases !).

Abscesses sometimes remain in the mediastinum, where they are visible in a radiograph. In other cases they track along an intercostal nerve, and either follow the posterior branch and so appear in the back, or pass forwards to come to the surface with the lateral cutaneous branch. The psoas muscle is attached to the twelfth dorsal body, and a psoas abscess sometimes follows disease of that bone.

Lumbar Region.—Pain is referred to the lower part of the abdominal wall or down the lower limb. Abscesses are likely to appear in one of three situations—the lumbar region, the psoas sheath, or in the pelvis. A lumbar abscess is due to pus



FIG. 565.—Old-standing tuberculous disease of the second lumbar vertebra, with calcified psoas abscesses.

tracking along the posterior branch of one of the spinal nerves. It appears at the outer border of the erector spinæ muscle, or in the triangle of Petit (fig. 566).

The psoas muscle is attached to all the lumbar vertebræ, and an abscess within its sheath is common (fig. 565). The swelling is first palpable in the iliac fossa, from whence the pus burrows beneath Poupart's ligament, on the outer side of the external iliac artery.

FIG. 566.—Pott's disease showing kyphosis and a lumbar abscess.

Fluctuation can usually be transmitted from that portion of the abscess above the ligament to the collection of pus below, and *vice versa*. The abscess then may extend beneath the femoral vessels to appear at the saphenous opening, where it simulates a femoral hernia, especially as an impulse occurs on coughing owing to the contraction of the abdominal muscles compressing pus in the iliac fossa, and forcing an additional quantity downwards beneath Poupart's ligament. In other cases the abscess follows the external circumflex vessels, and appears in the region of the great trochanter.

A pelvic abscess occasionally follows disease of the lower lumbar vertebræ, and pus then either passes along the inferior hæmorrhoidal vessels into the ischio-rectal fossa, or escapes into the buttock by accompanying structures passing through the sacro-iliac foramen.

Complications.—(*a*) *General.*—Miliary tuberculosis occasionally occurs, as it may with any active tuberculous affection. Should abscesses discharge on the surface secondary infection causes a varying degree of toxæmia, which, if prolonged, may culminate in amyloid disease.

(*b*) *Local.*—Paraplegia has already been mentioned. Abscess formation is not necessarily of serious import, and, with the exception of retropharyngeal abscess, no active measures are required, because the pus absorbs if the causative lesion responds to treatment. However, if the abscess is enlarging in size or threatening to involve the skin, steps must be taken to prevent rupture, which is inevitably followed by secondary infection. Aspiration is performed, usually with a wide-bore needle, which is thrust obliquely through adjacent healthy skin. In the case of a psoas abscess the puncture is made 1 in. above and internal to the anterior superior spine. In order to obtain a valvular puncture, the skin should be made to "slide" on the deep fascia before insertion of the needle. When evacuation is nearly complete the yellowish pus becomes pink in colour, owing to oozing from the unsupported capillaries of the granulation tissue in the abscess wall. Four drachms of 10 per cent. iodoform in glycerine may be injected into the cavity before the needle is withdrawn. Larger quantities have caused iodoform poisoning in susceptible patients. If the abscess reforms rapidly, incision and gentle curettage are advisable, after which the cavity is mopped out with spirit, and the walls smeared with B.I.P.P. Careful closure of the incision is essential. A black line at the junction of teeth and gums occasionally follows absorption of the bismuth.

Treatment.—General treatment is conducted as for any tuberculous affection, and is best carried out at a recognised institution or sanatorium.

Local treatment aims at securing immobilisation of the spine in order to encourage ankylosis. In some cases

weight-extension is also applied in order to correct or minimise deformity.

Fixation of the spine is obtainable by two methods, conservative or operative.

Conservative methods of obtaining immobilisation are numerous, and depend upon the age of the patient, the stage of the disease, and the preferences of the individual surgeon. If considerable deformity exists treatment should commence with weight extension, e.g. strapping is applied to each leg, and connected with a suitable weight by means of a cord passing over pulleys, which are fixed to the bottom of the bed. Counter-extension is obtained either



FIG. 567.—Whitman's frame, consisting of a double inclined plane with corset and leg-pieces by which the child is fixed in position.

by tilting up the foot of the bed, or by means of an axillary band which is fixed to the top of the bed.

Plaster of Paris jackets are applied when the deformity is overcome sufficiently, or if deformity is negligible treatment is commenced by the application of a jacket. If the disease affects the cervical spine the jacket is continued well up under the chin in front and as high as the occipital tuberosity behind, while if the dorsal or lumbar regions are affected the plaster extends from the axillæ to below the iliac crests. In all cases bony prominences are carefully padded, and a window is cut over the epigastrium to allow movement of abdominal muscles, and also to lighten the plaster. As the disease becomes quiescent less stringent methods of immobilisation are substituted. Thus a plaster bed is suitable for adults, and is moulded to the back while the patient lies upon his face. Further correction of any existing deformity can be obtained by means of pads suit-

ably arranged. Children are conveniently treated by means of a Bradford or Whitman's frame, in which they can be transported as necessary, e.g. for sun or ultra-violet-ray treatment. As improvement progresses a modified apparatus is provided, so that the spine is supported while the patient can enjoy some liberty. A specially fitted celluloid jacket or a Taylor's brace is suitable, and if necessary an extension is fitted so as to steady the cervical vertebræ and support the head. These spinal supports are gradually discarded after a period of six to twelve months has elapsed after the last sign or symptom of the disease has disappeared.

Operative Treatment.—This aims at supporting the spine by means of an internal splint so that practically complete immobilisation is secured. Hibb's operation consists in splitting a requisite number of spinous processes, and turning either half upwards and downwards so as to interlock with the split processes of adjacent vertebræ. In successful cases a rigid bar of callus extends along the required length in the spinal furrow. This operation has been abandoned by most surgeons in favour of Albee's method, which is simpler and more uniformly successful, although it involves an operation on the leg in addition to the spine.

The diseased portion of the spine, together with two vertebræ above and below, are exposed. The muscles, periosteum, and a flake of bone at the base of the spinous process are separated from the neural arch and spinous process of these exposed vertebræ (fig. 568). The bed so prepared is rendered hæmostatic by means of a hot saline pack. A graft of sufficient length is then cut from the subcutaneous surface of a tibia, by means of a double-bladed, electro-motor saw. Iced saline should be dripped on the saw during use to prevent the heat arising from friction exerting a deleterious effect upon bone cells. The graft is taken from the tibia and held in the prepared bed by pressure of the separated muscles, which are firmly sutured back into position with stout catgut.

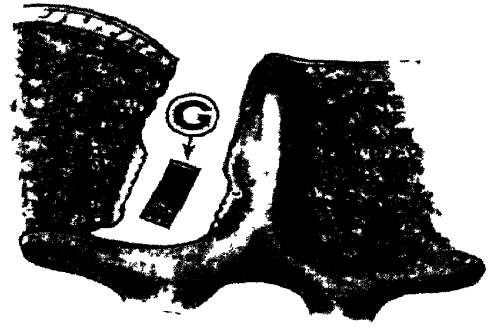

FIG. 568.—G = graft, inserted between spinous process and muscles.

Until the wound has healed the patient is nursed in a box splint, which allows him to be turned on his face at intervals. In about fourteen days a plaster of Paris jacket is fitted, and three months later this is removed and a celluloid jacket or other suitable support is applied. After another six months this is gradually discarded, and cure should be effected about one year after the operation.

The value of Albee's operation has provided a fruitful subject for discussion. It certainly provides more efficient fixation of the diseased spine than conservative measures, and in satisfactory cases it is a time-saving procedure. Perhaps the general consensus of opinion may be summarised as follows :

Bone grafting should be considered, provided—

(i) The affected region is other than cervical. (The most suitable region is the lumbar or lumbo-sacral.)

(ii) The patient is sufficiently robust, and the skin of the operation field is healthy. (A tuberculous abscess can be incised, mopped out, and otherwise ignored.)

(iii) The patient has at least reached the age of puberty. In younger children time is of relative unimportance, and conservative measures are usually satisfactory. Also it is possible that the graft will limit growth of the vertebræ to which it becomes fixed.

Spondylitis

Widespread inflammation of the spinal muscles, ligaments, or bones occasionally occurs, due to various and sometimes obscure causes. Those which appear to be separate clinical entities are as follows :

Gonococcal, resembles the periarticular type of arthritis which sometimes occurs in the feet. The spinal ligaments are chiefly affected, giving rise to pain and stiffness. This type usually responds, although unreadily, to appropriate treatment, which includes vaccines.

Rheumatic, which may be associated with myalgia, fibrositis, etc., elsewhere. Ligaments and muscles become stiff and contracted, but no marked bony changes are obvious in a radiograph.

Osteoarthritic, a painful and intractable condition which is predisposed to by injury, laborious occupations, exposure, and possibly by toxæmia from some focus of infection. It is commonly met with in elderly people, especially males. The pathological changes occurring in the spinal joints resemble those of osteoarthritis elsewhere, and in addition fibrosis of muscles and ossification of spinal ligaments occur (fig. 569). Two types of this disease are described—the cervico-dorsal,

in which the costo-transverse joints are also affected, and the lumbar, which is also associated with osteoarthritis of the hip, shoulder, and possibly other joints. The main symptoms are pain, stiffness, and deformity. Pain is either restricted to the affected area, or referred along spinal

FIG. 569.—Advanced spondylitis, showing kyphosis and ossification of the anterior common ligament. (R.C.S. 4823.1.)

nerves. These may be compressed as a result of absorption of intervertebral discs and consequent approximation of vertebræ, or by pressure of osteophytes. Stiffness follows degeneration of the joints and fibrosis of ligaments and muscles. At a late stage of the disease extensive ossification of ligaments results in complete immobility of spine, the so-called "poker back." Deformity takes the form of

kyphosis, which may be so extreme that the patient while standing cannot raise his eyes from the ground.

Treatment consists in a thorough search for any focus of infection. Massage, ionisation, radiant heat, protein shock, and other lines of treatment devised to relieve osteoarthritis are exhibited, but the disease usually progresses slowly but steadily.

Sacralisation of the lowest lumbar vertebra is a condition which is now recognised as pathological. The transverse process of the vertebra is elongated, so that it is in contact with the lateral mass of the sacrum. Lateral flexion of the spine causes nipping of the soft tissues between the bones, or pressure on the fifth lumbar nerve which passes below the enlarged transverse process. The resulting pain is relieved by extension of the spine or by recumbency. Treatment is difficult, but a pelvic support sometimes relieves symptoms. Manipulation is occasionally useful, and osteopaths are well aware of the condition. Operative interference and removal of part of the transverse process is a last resort.

Tumours of the Vertebral Column

Innocent tumours are extremely rare, although exostoses, chondromata, osteomata, and fibromata have all been described. The symptoms which arise simulate those of extradural tumours, and a radiograph may demonstrate them. Malignant tumours of the spine are primary or secondary.

Primary sarcoma is uncommon, and is most frequent in children and young adults. The neural arches are usually affected, and therefore a palpable swelling is often detectable. Complete removal of the tumour is rarely possible, and usually only palliative treatment, i.e. a spinal support, deep X-ray therapy, and analgesics, is possible.

Secondary deposits in the spine are unfortunately of common occurrence, and more than half the cases follow carcinoma of the breast. The other organs which, on becoming carcinomatous, often disseminate to bone, contribute their quota. These include the kidney, prostate, bronchus, and thyroid. Periosteal sarcoma of any bone may also give rise to a secondary deposit in the spine. Metastases nearly always affect the body of the vertebra.

In the large majority of cases pain is the first, and for a long period the only symptom. The pain occurs at the site

of the disease, and later becomes girdle in type, or radiates along one or more limbs. Probably at this stage the patient is treated for lumbago, sciatica, abdominal disorders, and may even be subjected to operation. The pain increases in intensity and is aggravated by movement, so that the patient may remain crouched on a chair or huddled up in bed for hours at a time. Cord symptoms appear at any time. One of our patients, who had evinced no sign of vertebral involvement, developed complete paraplegia on the first occasion she left her bed after removal of a breast for carcinoma. More commonly the onset of paraplegia is ushered in with increased reflexes and spasticity, but cord involvement is usually complete in a few weeks, and is followed by cystitis, pyelonephritis, bedsores, and death.

Treatment of secondary deposits necessitates a support to the spine, analgesics, and endeavouring to alleviate symptoms as they arise. The posterior nerve roots, or antero-lateral tracts, have been divided in order to relieve agonising pain.

Tumours in the Spinal Canal

This group includes extradural, intradural, and intramedullary tumours.

Extradural tumours are very rare, but lipomata and fibromata both occur. As these tumours are innocent and slowly growing, symptoms are present for a long period before pressure on the cord is sufficient to interfere with its function. Vague motor or sensory disturbances, which often remit and are variable, are suggestive of this condition.

Extramedullary growths, the most common of spinal tumours, include psammoma, endothelioma, tuberculoma, fibroma, and fibrosarcoma. Paræsthesia followed by pain, due to irritation of a posterior root, is the first symptom. As a rule a definite interval of some months elapses before cord symptoms appear, which may resemble those which arise from hemi-section (Brown-Séquard), i.e. pressure of the tumour on one side of the cord causes motor paresis and loss of sensation on the same side of the body, while

on the opposite side sensibility to pain and temperature is diminished, and possibly tactile sensation also.

Confusion is particularly likely to occur in the case of primary new-growth, as with a secondary neoplasm the primary source is usually discoverable.

As mentioned in connection with secondary deposits in the vertebræ, root pains often cause early errors of diagnosis.

Intramedullary tumours are usually malignant, and are commonly sarcomatous or glio-sarcomatous. Other varieties include tuberculoma, cyst, and endothelioma, which have probably originated from invagination of the pia mater which lies in the posterior spinal sulcus, or else have become embedded in the cord. More than half the intramedullary tumours occur in the cervical portion of the cord.

The symptoms which arise from an intramedullary tumour depend upon the actual site of its origin. Usually motor and sensory symptoms synchronise, e.g. paresis of one limb accompanied by sensations of heat or cold. Root pains are not likely to appear until later, so that intramedullary tumours are not usually painful in the early stages.

Recognition of the Level of the Tumour

A careful clinical examination is of paramount importance, and in some sites it is possible to locate accurately the affected segment. Accessory means of investigation include the electrical reactions of muscles, radiography, and lumbar puncture.

Clinical Examination.—Includes sensory disturbances, paresis, and wasting of muscles, exaggeration or diminution of reflexes, and condition of sphincters. Root pains and hyperæsthesia are among the most reliable signs of the upper level of the neoplasm, and of the side on which it lies. In addition to symptoms arising from interference with the ascending and descending tracts, disease of different segments of the cord gives rise to disturbances depending on the particular function of that particular portion.

The more important localising features are as follows :

Upper Cervical.—Tumours in this region are usually rapidly fatal

from involvement of the phrenic nerve centres, and interference with the medulla sometimes causes cardiac irregularity and hyperpyrexia. Involvement of the oculo-pupillary fibres which pass down to their nucleus in the first dorsal segment results in myosis, narrowing of the palpebral fissure, and enophthalmos. Neuralgic pains are likely to occur over the mastoid and occipital regions, the neck, supraclavicular or acromial areas, or down the arms.

Lower Cervical and Upper Dorsal.—Pupillary changes are likely if the tumour is situated at or above the first dorsal segment. Interference with the anterior horn cells from the fifth cervical to the first dorsal segments causes paralysis and wasting of characteristic groups of muscles (p. 651). Perhaps the most striking example is a tumour at the level of the first dorsal segment, which causes wasting of the small muscles of the hand and oculo-pupillary signs.

Examination of reflexes may yield valuable information. If the supinator reflex is absent the tumour is situated at the level of the fifth or sixth cervical segment, while absence of the triceps jerk indicates interference with the seventh segment. A tumour in the lower cervical or first dorsal area is likely to cause pain radiating down the arms. Below this level, intercostal neuralgia or girdle pains will probably be a prominent symptom.

Lower Dorsal.—Interference with the cord between the eighth and twelfth dorsal segments is likely to cause loss of upper or lower abdominal reflexes. Paresis of muscles is sometimes present, and if unilateral, a striking bulge of one-half of the abdominal wall is noticeable when the patient coughs.

Irritation of the seventh to the twelfth posterior roots causes a variety of abdominal symptoms, usually indefinite but persistent, and is a fruitful source of diagnostic errors.

Lumbar Cord.—Disturbances of the rectal and bladder sphincters are common. If the tumour is situated at or below the level of the second lumbar segment one or both knee-jerks is diminished or absent. The cremasteric reflex is abolished if the tumour involves the upper part of the lumbar cord. Involvement of centres from which the lumbar plexus is derived causes paralysis and wasting of corresponding muscles. Owing to the comparatively small size of the lumbar and sacral segments of the cord, sacral nerves are commonly affected in addition to the lower lumbar.

Cauda Equina.—Pain occurs in the back, and extends to the perineum, genitals, and backs of the thighs. Sensory loss usually occurs over the distribution of the sacral nerves, and the lower the tumour is situated the smaller is the area of anæsthesia. Bladder and rectal disturbances are usual, and paresis of muscles depends upon the actual nerves involved.

Electrical Reactions.—Should pressure or infiltration by the tumour interfere with the anterior horn cells, then the muscles innervated by these cells undergo a lower motor neurone paralysis. Hence the absence of reaction of a muscle or group of muscles to faradic current may be an important clue to the situation of the tumour.

Radiography.—The introduction of 1 c.c. of lipiodol into the cisterna magna will demonstrate spinal block, if the tumour is sufficiently large to cause obstruction. The lipiodol gravitates downwards until it is arrested by the tumour, and the site of the block can then be seen in a radiograph. If confirmation is deemed necessary the lipiodol can be injected by lumbar puncture, and the radiograph taken after the patient has been in the Trendelenburg position for some hours.

This method is secondary in importance to clinical examination, and we have seen cases where a complete block was apparently present, but at operation no adequate cause was discovered.

Lumbar Puncture.—If the tumour interferes with the cerebro-spinal circulation, the fluid below is frequently yellow in colour, and contains an increased amount of protein. Examination of the intradural pressure by means of a manometer attached to the needle sometimes shows difference of pressure in the cisterna magna and the lumbar region. Although this is of little value in locating the site of a tumour, it is important in confirming its presence.

As spinal tumours presumably will increase in size, the natural result of their presence is to destroy the cord sooner or later. Laminectomy is performed as soon as the presence of a tumour is diagnosed and its situation located. The prognosis is much more favourable than in the case of cerebral tumours, as about 50 per cent. of spinal tumours are removable.

As in the case of cerebral tumours, the possibility of the lesion being syphilitic in nature receives due consideration.

Laminectomy

The indications for laminectomy are as follows :

1. **Traumatic.**—These have already been considered, and it must be emphasised that injury associated with a complete lesion of the cord is a definite contraindication.

2. **Inflammatory.**—Acute osteomyelitis of a neural arch is treated by removal of the affected bone.

Paraplegia complicating Pott's disease occasionally re-

quires laminectomy if recumbency (if necessary combined with extension) fails to relieve the cord symptoms.

3. **Neoplasm.**—Provided that the condition of the patient is satisfactory, laminectomy is performed for all tumours within the spinal canal. "Tumour" includes such conditions as tuberculomata and cysts. Occasionally new-growth of the spinal column justifies exploration.

4. **Division of Posterior Nerve Roots.**—This procedure has been adopted in order to relieve severe pain, for the gastric crises of tabes dorsalis, and also to diminish muscular spasm in cases of spastic paraplegia (*syn.* Little's disease). Posterior rhizotomy for the relief of pain is now superseded by sympathetic ganglionectomy, or by division of the antero-lateral tracts. Gastric crises, which have failed to respond to less drastic measures, are sometimes greatly benefited by division of the seventh, to and including the eleventh posterior roots on the left side (Sir William Thornburn).

Cases of spastic paraplegia are usually improved by manipulation, division of peripheral nerves (e.g. the obturator) and muscles, etc., so that posterior rhizotomy is rarely necessary. If this formidable operation is contemplated the surgeon must be sure that the patient is sufficiently intelligent to co-operate in treatment, and re-educate the muscles subsequent to the operation.

5. **Division of the Antero-lateral Tracts.**—This operation was devised by Spiller and Martin for the relief of pain due to an irremovable new-growth. The cord is exposed above the site of the lesion, and the antero-lateral tracts are divided to a depth of 2 mm. as they lie between the denticulate ligament and the anterior root. A deeper incision will involve the pyramidal tract. If the pain is unilateral in origin, the tract on the opposite side only need be divided. The patient must be warned against unconscious injury or burns of the anæsthetised areas.

Operation.—If laminectomy is to be performed for the attempted removal of a tumour, the discrepancy which exists regarding the level of the affected segment of the cord, and the corresponding vertebra, must be considered. Owing to the disparity in the length of the spinal cord and vertebral column, it must be remembered that a segment in the cervical region lies one vertebra above its corresponding vertebral body. In the upper dorsal region the tumour will be two vertebræ, and in the lower dorsal three vertebræ, above the corresponding vertebral body.

In estimating these levels by palpation of the spinous processes, it must not be forgotten that in the dorsal region the processes overlap the vertebra below. Thus, presuming a tumour is localised to the ninth dorsal segment, it should be opposite the tip of the fifth spinous process, i.e. three vertebræ higher on account of the shortness of the cord as compared with the spinal column, and one vertebra higher because of the obliquity of the spinous process.

Lipiodol, as already mentioned, is sometimes of value in localising the level of a tumour.

Intratracheal anæsthesia is desirable, and the patient is usually placed in the prone position, with a sandbag under the sternum and pelvis. If the laminectomy is in the nature of an exploration, a

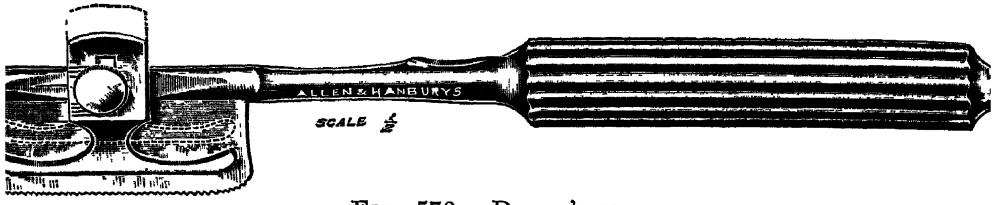

FIG. 570.—Doyen's saw.

midline incision is advisable, as it can be prolonged in either direction if necessary. Otherwise a flap is preferable. Muscles are separated from the spinous processes and neural arches with a raspatory, and an occasional touch with a scalpel, and venous hæmorrhage controlled by means of hot saline packs. When sufficient vertebræ are exposed the interspinous ligaments are divided, and spinous processes removed by means of angled bone forceps. The neural arches are then divided on either side with a Doyen's saw, which is guarded so as to avoid possible injury to the cord (fig. 570). Owing to the obliquity of the pedicles the direction of the saw-cut must be forwards and *inwards* (fig. 571). A small trephine and laminectomy forceps are favoured by some surgeons as a means of removing the laminæ. When the arches are divided the ligamentum subflavum is cut across above and below, and the laminæ removed. Projecting portions of neural arches are conveniently removed with a Hudson's guillotine, the blade of which cuts upwards, so as to avoid risk of injury to the cord (fig. 572).

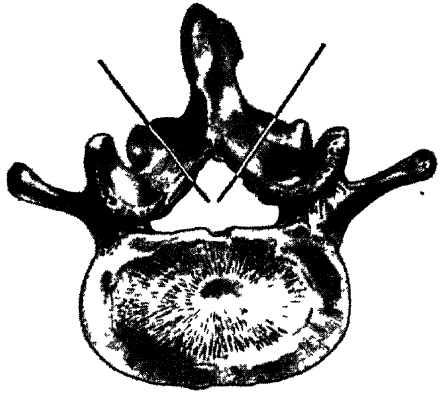

FIG. 571.—Indicating direction of saw-cut necessary for division of neural arches.

The dura mater is now exposed, and the presence of a tumour, and the degree of pulsation or discolouration, are noticed. Unless some pathological condition is found the dura is opened. This is done by steadying the membrane with tenaculum forceps or a stitch, nicking it with a tenotome, and then slitting it up with guarded scissors, or by means of a grooved director and a scalpel. The divided dura is held

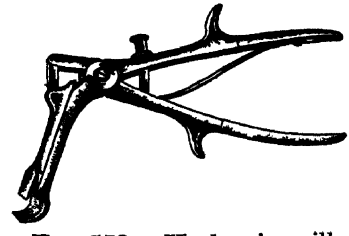

FIG. 572.—Hudson's guillotine forceps for laminectomy.

aside by means of a stitch or mosquito forceps, and the exposed structures are inspected. Should it be deemed necessary to inspect the anterior part of the cord, one of the prolongations of the ligamentum denticulatum is grasped with forceps, and traction then permits of rotation of the cord. If an intramedullary tumour is seen, it should be dealt with by Elsberg's method of extrusion, i.e. a vertical incision is made through the cord down to the tumour, the wound closed, and events awaited. It is hoped that within two weeks the symptoms will definitely improve, which indicates that the tumour is being extruded from the cord. When improvement ceases, the wound is reopened and the tumour removed.

After exploration is completed the dura mater is closed with a continuous silk or linen suture, the spinal muscles are firmly sutured together, and the skin closed with interrupted stitches.

Lumbar Puncture

This procedure is adopted for the following reasons :

1. **Diagnostic,** e.g. meningitis, gold test for syphilis, to disclose intradural hæmorrhage.

2. **Therapeutic,** e.g. to introduce magnesium sulphate or antitetanic serum for tetanus, or salvarsanised serum for syphilis. Also for reduction of intrathecal pressure.

3. **Anæsthesia,** e.g. stovaine, novocaine, spinocaine, etc., are introduced for the purpose of producing anæsthesia. Spinocaine is composed of novocaine (100 mg. in each c.c.) and strychnine. The dose varies from 1 c.c. for children under six years of age to 3 c.c. for adults. A pressor substance, such as ephedrine (gr. $\frac{1}{2}$–$\frac{3}{4}$) is sometimes given intramuscularly in order to maintain the blood pressure.

It will be remembered that at birth the cord extends to the third lumbar vertebra. In the adult it terminates opposite the lower border of the body of the first lumbar vertebra, and therefore the dural sac can be safely punctured at any site between the second lumbar interspace and the fifth lumbar vertebra. The nerves of the cauda equina are so arranged that a space of 2 mm. to 5 mm. in width exists between the roots on either side, and it is into this space that the needle used should penetrate.

A line connecting the highest parts of the iliac crests passes over the fourth lumbar spine, so that a needle entered just above or below should pass through the third or fourth

lumbar interspaces respectively. The depth to which the needle passes varies from 1 cm. in a small child to 10 cm. in a fat adult. If the patient is self-controlled, a small amount of local anæsthetic is desirable, although not imperative, but in the case of children or patients afflicted with tetanus a general anæsthetic is necessary. Flexion of the spine widens the spaces between the neural arches. The needle used should be of medium bore (about 18 to 20 gauge) as the aperture resulting from puncture with a wide needle will allow subsequent escape of cerebro-spinal fluid, with consequent persistent headaches. Also the bevel of the needle must be short, so that there is no danger of part of the opening remaining outside the dura mater. As the needle and stylet are entered, the resistance of the tough ligamentum subflavum is encountered. A little extra pressure perforates this structure, and on withdrawal of the stylet the cerebro-spinal fluid should flow from the needle. If only a few drops of blood escape, in all probability the point of the needle is lying in the spinal canal outside the dural sheath, and the blood is escaping from the spinal veins. The needle should then be withdrawn, washed out in saline solution, and reinserted. Occasionally when the dura is penetrated, sudden pain shooting down one leg is experienced. This is due to the needle having come in contact with one of the nerves of the cauda equina, and is of no significance. A manometer, attached to the needle, is useful in estimating the cerebro-spinal pressure, the normal being from 8 mm. to 10 mm. of mercury. The pressure is increased in such conditions as meningitis, cerebral or spinal tumour, and intracranial hæmorrhages. Care must always be taken that not more than 25 c.c. of fluid are removed at the time in cases of increased pressure, otherwise the medulla is liable to become wedged in the foramen magnum with fatal consequences, owing to interference with the vital centres.

Sacral Puncture

The sacral epidural space may be entered through the large triangular opening on the dorsum of the bone, and sacral anæsthesia obtained by the injection into the space of 20 c.c. of 1 per cent.

novocaine. Operations on the rectum and anal margin can then be performed painlessly.

To perform sacral puncture the median crest of the sacrum is palpated until the depression caused by the sacral opening is recognised. A lumbar puncture needle is introduced directly forwards until the ligaments covering the opening are pierced, after which the direction of the needle is changed so that it passes vertically upwards within the sacral canal (fig. 573). In order to ensure that the point of the needle is within the epidural space, it is wise to inject a few c.c. of normal saline; if the needle has not penetrated the canal, infiltration of the subcutaneous tissues will be evident, in which case it is withdrawn and a fresh attempt is made. The needle should not be inserted to a greater depth than 6 cm., otherwise the dura mater, which terminates opposite the second or third sacral vertebra, is in danger of perforation.

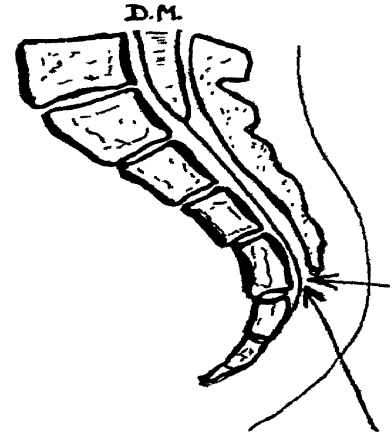

FIG. 573.—Indicating direction of needle in performing a sacral puncture.

CHAPTER XXIX

NERVES

NERVES are injured as a result of contusion, concussion, compression, friction, rupture, or division.

Contusion of a nerve is sometimes associated with an extravasation of blood within its sheath. Temporary paræsthesia and paresis follow, and recovery is usually complete.

Concussion follows vibratory effects, such as the passage of a missile of high velocity through tissues adjacent to the nerve. No apparent lesion of the nerve can be detected, and recovery usually ensues.

Compression is caused by pressure of crutches, callus formation, bony abnormalities such as cervical ribs, also splints, and tumours. The first symptoms are usually due to paræsthesia, and consist of numbness and tingling along the distribution of the nerve, followed by neuralgic pain. Paresis occurs later, but complete paralysis and wasting of muscles are uncommon unless the compression is prolonged. Protopathic loss of sensation may be greater than epicritic. If the cause is otherwise irremovable, operative measures may be necessary, e.g. excision of a cervical rib, or freeing a nerve from callus. Sensory symptoms are thereby relieved, but if interstitial fibrosis has occurred as a result of prolonged pressure, motor disability is likely to persist.

Friction may interfere with nervous function, owing to the development of a patch of fibrosis within the nerve. It is an uncommon cause of nerve injury, but sometimes follows cubitus valgus, the carrying angle being so increased that the internal condyle acts as a pulley across which the ulnar nerve passes. This condition has arisen as long as seventeen years after the initial bony injury, the clinical features resembling those of compression. Treatment consists in

transplanting the ulnar nerve to the front of the internal condyle, care being taken that the nerve is not kinked by the rigid lower border of the internal intermuscular septum, and that motor branches are not divided.

Rupture of a nerve occurs as a complication of a dislocation fracture, or of excessive stretching, as in the case of the brachial plexus. The sheath of the nerve sometimes remains intact, when natural repair not uncommonly follows.

Treatment consists in relaxing paralysed muscles, and if recovery does not commence within a reasonable time, exploration should be undertaken, but owing to retraction of nerve fibres and fibrosis following extravasation of blood, the results are unsatisfactory.

Division of a nerve is either *complete* or *incomplete*. If division is complete, the results are immediate or remote.

Immediate results following division of a mixed nerve are paralysis of muscles supplied by the nerve, a varying area of anæsthesia depending on the amount of overlap of neighbouring nerves, and vasomotor changes, the part supplied by the nerve becoming temporarily hyperæmic, but later colder and anæmic.

Remote.—(*a*) *Nerve.*—Retraction of the divided ends occurs, the intervening gap being filled with blood. This eventually organises, and during this process nerve fibres grow distally, and if unable to unite with divided peripheral fibres, become coiled up, the resulting mass of fibrous and nervous tissue forming a false neuroma. Proximally, Wallerian degeneration occurs, the medullary sheath degenerates, and the myelin is removed by leucocytes, within a month. Axis cylinders disappear, and neurilemma cells proliferate, so that the nerve is represented by a fibrous strand.

(*b*) *Muscles.*—Paralysis occurs, to be followed by wasting. Stretching of paralysed tendons will readily occur, unless strict relaxation is rigorously maintained.

Response to faradic stimulation is lost within three weeks, while galvanic response may remain for years, the contraction being sluggish, and the anodal closure is greater

than the cathodal. This reaction of degeneration is of practical importance, as its presence indicates that suture of the divided nerve is necessary if muscular power is to be regained.

(*c*) *Sensation.*—Epicritic sensation consists in the appreciation of light touch, discrimination of compass points, and limits of temperature between 22° C. and 38° C. Protopathic sensation includes painful stimuli, and wider degrees of temperature, whereas deep sensation is concerned with pressure, the position of joints, and movements of muscles and tendons.

Division of a mixed nerve causes a loss of all three forms of sensation to a varying extent, which may be much less than the anatomical distribution of the nerve, owing to overlap of adjacent nerves. Except in the case of posterior spinal roots the area of protopathic loss is less than that of epicritic. The fibres conveying deep sensation accompany the motor branches of the nerve ; thus, if a purely sensory nerve is divided, epicritic and protopathic sensations only are lost.

(*d*) *Trophic and Vasomotor.*—Transient vaso-dilatation is followed by diminution of the circulation, so that the affected parts become cold and readily ulcerate. The skin becomes dry and nails wrinkled, and absorption of small bones and ankylosis of joints eventually occurs. In children lack of development of the part tends to follow.

Incomplete division of a nerve gives rise to a central or lateral neuroma. Effects vary according to the extent of the injury. Fibres supplying certain muscles are often constant in position, and hence are more liable to injury if their position exposes them to trauma. Thus partial division of the great sciatic nerve affects the external popliteal portion nine times more commonly than the internal popliteal, which passes down on the inner and deeper aspect of the great sciatic nerve.

Partial lesion of the median or internal popliteal nerve, or any infected wound in the distribution of these nerves, may give rise to the distressing, but fortunately rare, condition of *causalgia*, which is characterised by intense burning pain and trophic changes. The

condition is alleged to be due to an interstitial fibrosis spreading along the nerve and compressing the nervi nervorum. (See also p. 666.)

Treatment.—*Primary suture* is the ideal method of treatment, and should be carried out in all cases, provided there is no infection present. If a wound is so situated, e.g. in front of the wrist, that important nerves have possibly been divided, careful exploration is necessary, so that division of the nerve is not overlooked when the wound is sutured.

The two ends of the divided nerve are identified, and any ragged shreds of sheath are removed in order to obviate their interposition between the nerve fibres. A non-cutting needle carrying fine plain catgut or thread is used, and stitches are inserted through the sheath of the nerve, care being taken to avoid torsion. Owing to the recent nature of the injury, very little traction is required in order to secure apposition.

If considered desirable, the nerve is embedded in muscle, or a flap of deep fascia is wrapped around it. Hæmostasis is essential, both in order to obviate fibrosis, and also to diminish the risk of infection, either blood-borne, or from organisms already present in the wound. The limb is fixed in such a position that the nerve is relaxed and care is taken to prevent stretching of paralysed muscles and tendons.

Secondary Suture.—This operation is performed under the following circumstances :

(1) If infection of the wound has occurred or is inevitable. In this case the ends of the divided nerve are approximated by one stitch in order to prevent retraction and subsequent difficulty in identifying the two ends at a later date. Excessive stitching merely confines infection, which readily spreads within the nerve sheath and causes widespread fibrosis.

During the period between the initial injury and secondary suture, paralysed muscles must be carefully supported, and their tone maintained by massage, electrical treatment, etc. Some months must be allowed to elapse in order that infection may be overcome. Latent infection can often be revealed by means of a radiant heat bath and vigorous massage, and, if present, tenderness or induration follows, in which case a further period of rest must be imposed, and vaccines are sometimes of value in raising the patient's resistance.

(2) In cases of suspected concussion or contusion, time must elapse in order to allow these conditions to be distinguished from an anatomical division. Movements produced by unaffected muscles must not mislead the observer. Thus in a case of musculo-spiral paralysis, the fingers can be extended by the interosseous and lumbrical muscles, provided that the hand is supported. Also vicarious movements may be performed by adjacent muscles, e.g. in the case of division of the median nerve, the adductors of the thumb, acting in conjunction with the externor ossis metacarpi pollicis muscle, can produce opposition of the thumb.

Concussion and contusion of a nerve are unlikely to cause complete physiological division of a nerve for more than one week. If this time has elapsed without improvement, and if R.D. supervenes, then exploration of the nerve is indicated.

Operation.—A tourniquet renders the operation easier, but must be released before the wound is closed, as absolute hæmostasis is highly desirable. The two ends of the nerve are identified, the incision being prolonged sufficiently to expose the nerve well above and below the seat of injury, in such a position that its normal anatomical relations are not obscured by scar tissue. The two ends of the nerve are freed, and traumatic neuromata removed by means of a scalpel or safety-razor blade held in forceps. Scissors should not be used, as the nerve is crushed thereby. Slices are removed from the ends of the nerve until the projecting fibres are seen, and blood freely oozes from the cut surface. Apposition of the two ends is accomplished by the following manœuvres :

(*a*) *Posture.*—The limb being held in a suitable position.

(*b*) *Mobilisation.*—The two ends are dissected from surrounding structures, care being taken that important motor branches are not injured.

(*c*) *Transposition.*—e.g. the musculo-spiral nerve is brought in front of the humerus, or the ulnar nerve in front of the internal condyle.

(*d*) *Nerve Anchoring.*—If it is obvious that the two ends of a divided nerve cannot be brought together, on account of excessive loss of tissue or retraction, then the two untrimmed ends are approximated as closely as possible by tension stitches, the position of the limb being such that approximation is facilitated. Subsequently the nerve is stretched by gradually straightening the limb, and at a second operation the two ends may be brought together.

(*e*) *Resection of Bone.*—This extensive procedure may be justifiable if nerve injury is associated with an ununited fracture, which also needs operative measures, e.g. in the case of the musculo-spiral nerve and a fractured humerus.

Approximation having been obtained by one of the above pro-

cedures, sutures are introduced through the nerve sheath. Non-irritating material should be used, and plain catgut is adequate if tension is slight. Should approximation be difficult, fine thread is preferable to chromic or tanninised catgut, as chemicals act as powerful irritants to the sensitive nerve fibres, and therefore encourage fibrosis. Torsion of the nerve ends must be avoided, so that, as far as possible, proximal nerve fibres will join with their corresponding distal fibres. " Shunting " is thus avoided, and delay due to re-education of groups of muscles is obviated. If much fibrosis is present, a new path can be constructed for the sutured nerve by opening a muscle sheath, and embedding the nerve among the muscle fibres, or a strip of fascia later may be wrapped around the nerve and stitched in position. A final inspection is made to confirm absolute hæmostasis, and the limb placed in a suitable position to prevent any strain on the sutured nerve.

Results of Nerve Suture.—This depends on many factors which may be summarised as follows :

1. **Pre-operative.**—(*a*) *The Nerve Affected.*—Suture of nerves which supply muscles whose actions are intricate usually give disappointing results ; thus, recovery of palmar muscles, after suture of an ulnar nerve, may be negligible. On the other hand, muscles which perform coarse movements, e.g. those supplied by the musculo-spiral nerve, often, to all appearances, recover completely.

(*b*) *Infection.*—Not only causes delay before subsiding, but some degree of interstitial neuritis will result, and further damage to the nerve may be caused by contraction of surrounding scar tissue.

(*c*) *Time.*—Primary suture naturally gives better results than secondary, as less time elapses before normal impulses stimulate the muscles, and trophic phenomena are less advanced.

(*d*) *Pre-operative Treatment.*—If muscles and tendons have been allowed to stretch, or if the tone of the muscles has been neglected, then the chances of recovery are correspondingly diminished.

2. **Operative.**—This consists of attention to the details already mentioned, e.g. hæmostasis, prevention of torsion and tension, preparation of suitable bed, etc.

3. **Post-operative.**—(*a*) *Absence of Infection.*—If the wound is already infected, or if infection supervenes, or being already present lights up again, then little improvement is likely.

(*b*) *After-treatment.*—Consists in continuance of the relaxation of paralysed muscles, massage, electrical treatment, and muscular effort gradually increased as muscles recover their power.

(*c*) *Co-operation of the Patient.*—This important factor must be remembered, and the patient given every encouragement during his long and tedious convalescence.

(*d*) *Vicarious Movements.*—Although the physiological results of nerve suture may be poor, yet adjacent muscles often take upon themselves some of the functions of those which are paralysed, e.g. if the hamstrings are paralysed, and flexion of the knee thereby affected, the sartorious and gracilis muscles hypertrophy, and partially compensate for this deficiency. Thus the functional result of a nerve injury is often more satisfactory than the physiological recovery would suggest.

In the case of successful suture of a nerve, apparent return of

sensation is usually experienced within a few days, much to the surprise and gratification of the patient. He must be warned against optimism, as this phantom return disappears in two or three weeks, but true regeneration of the nerve follows at the rate of about 1 mm. per day. A pause of weeks or months occurs while the highly specialised sensory terminals and motor end-plates recover. Thus the time necessary for recovery depends to some extent on the site of injury and the length of nerve along which regeneration must occur. The first evidence of regeneration is a return of protopathic sensation, followed by epicritic. Motor recovery is slower than sensory. Even although motor recovery is disappointing, and restoration of sensation incomplete, yet trophic changes often improve to a marked extent, and healed sores and ulcers compensate to some extent for deficient motor and sensory recovery. As an example regarding the rate of recovery, an average length of time which lapses following primary suture of an ulnar nerve at the wrist would be six months for epicritic, and up to two years for the paralysed muscles, the recovery of which will always be incomplete. The progress of regeneration can be estimated by Tinel's sign. The course of a nerve is lightly percussed, e.g. with a patella hammer, from below upwards. When the level to which regeneration has occurred is reached, a sensation of tingling is experienced.

Irremediable Injury.—If suture is impossible on account of loss of tissue or wide separation of the ends of a divided nerve, the following procedures may be adopted :

(*a*) *Nerve anastomosis*, part of the hypoglossal nerve is occasionally united to the distal end of the facial nerve.

(*b*) *Tendon transplantation*, e.g. in the case of musculo-spiral paralysis, tendons and muscles of the forearm are transplanted into the extensor group.

(*c*) *Arthrodesis*, e.g. in the case of injury to the sciatic nerve, arthrodesis of the flail ankle joint will render it stable and rigid.

(*d*) *Amputation*, for persistent sores and ulcers on the foot, particularly if growth is impaired.

CHAPTER XXX

SPECIAL NERVES

Cranial Nerves

The **Olfactory Nerve** is liable to be injured by fractures passing through the cribriform plate, resulting in anosmia of the corresponding side.

The **Optic Nerve** may be damaged by fractures involving the optic foramen, or by compression by blood or inflammatory exudates in the orbit. Involvement by tumours or aneurisms is rare. Blindness of the corresponding eye results, but contraction of the pupil occurs if the opposite retina is stimulated.

The **Third Nerve** is sometimes involved by tumours, trauma, or aneurism, either in the skull, sphenoidal fissure, or the orbit. If a complete lesion is present, the following features are noticed :

(*a*) Ptosis of the upper eyelid, owing to paralysis of the levator palpebræ superioris.

(*b*) Proptosis, owing to paralysis of the majority of the ocular muscles, which normally exercise traction on the eyeball.

(*c*) Mydriasis, as the sympathetic fibres are unopposed, and cause unhampered dilatation of the pupil.

(*d*) Loss of accommodation, owing to paralysis of the ciliary muscle.

(*e*) External strabismus, with a slight downward inclination of the eyeball, due to unopposed action of the external rectus and superior oblique muscles. Owing to their close association, other nerves passing to the orbit may also be involved.

The **Fourth Nerve** supplies the superior oblique muscle,

and is rarely involved alone. Deficient movement of the eye in a downward and outward direction may be noticed.

The **Fifth Nerve** or its branches are sometimes injured, and sensory disturbances follow (p. 744). The main surgical importance of this nerve lies in its susceptibility to neuralgia, a condition known as *tic douloureux*. Trigeminal neuralgia occurs more commonly in females, and appears to be increasing in frequency. Pain usually commences in the infra-orbital or inferior dental nerve, and extends to the remaining branches of the superior and inferior maxillary nerves, the ophthalmic division usually escaping. Spasms of pain are precipitated by any external stimulus, such as a draught, brushing the teeth, or washing, and eventually the patient hardly dares to eat or speak. The condition varies with the general health of the patient, and intermissions occur, but the general tendency, at any rate for two or three years, is one of progress, so that the patient may become a morphomaniac or even suicidal. Treatment consists in a thorough search for any source of reflex irritation, and in the exhibition of analgesics. The patient must guard against exposure to cold or damp, and the general health must be maintained. If the condition persists, injection should be attempted.

Injection is made into the affected nerve or directly into the Gasserian ganglion. The ganglion is reached either laterally via the sigmoid notch, the mouth being gagged open, or anteriorly below the zygoma. Local infiltration should be used rather than general anæsthesia, as the patient's sensations are a guide to the position of the needle. One c.c. of 80 per cent. alcohol is injected just within the foramen ovale. If the needle is inserted too far within the skull, or if an excess of alcohol is used, some of the fluid may trickle over the superior border of the petrous bone and destroy the facial and auditory nerves. Anæsthesia of the face, nose, and cheek indicates successful injection. Relief follows immediately, and may last from six months to two years. Repeated injections are often necessary, and are made with increasing difficulty on account of fibrosis around the foramen ovale, but each injection further destroys the nerve, and in any case the disease, having reached a climax, tends to decrease in severity. If injection fails to give relief, the sensory root of the Gasserian ganglion should be divided.

Division of the sensory root has superseded ganglionectomy, as it is a simpler procedure, and the motor root is spared. The temporal fossa is exposed by a suitable incision and the skull is opened. The dura mater is separated from the floor of the middle fossa until the middle meningeal artery is seen emerging from the foramen spinosum.

The foramen is plugged with wax or a matchstick, and the artery is divided. The inferior maxillary nerve is then identified as it passes backwards from the foramen ovale to the cave of Meckel. A special retractor (fig. 574) is inserted, and an incision is made in the dural

FIG. 574.—Retractor for exposure of Gasserian ganglion, with electric light.

sheath of the ganglion. The cerebro-spinal fluid which escapes is patiently mopped away with pledgets of cotton-wool. The sensory root is then traced backwards to the apex of the petrous bone, and is distinguished from the ganglion itself by its loose texture and parallel fibres. The root is supported on a blunt hook and divided with a suitable knife (fig. 575). The motor root lies deep to the

FIG. 575.—Angled knife for dividing the sensory root of the fifth nerve.

sensory fibres, and if necessary for the purposes of identification, it may be stimulated, when the fibres of the temporal muscle exposed in the wound will contract. Complete and permanent relief follows an efficient operation. Cases have been reported in which excision of the superior and middle cervical sympathetic ganglia have yielded good results.

The **Sixth Nerve** is slender, and has a long intracranial course. It is sometimes involved in cases of prolonged intracranial pressure, and it may be interfered with in association with other ocular nerves, either in the cavernous sinus, sphenoidal fissure, or orbit. The external rectus muscle is paralysed, and internal strabismus results.

The **Seventh Nerve** is involved by a variety of causes, which can be summarised as follows:

1. *Intracranial.*—Lesions within the skull are supranuclear, nuclear, or infranuclear. Supranuclear lesions are uncommon, and are due to injury, gumma, or new growth. They are characterised by involvement of only the lower half of the face, as the occipito-frontalis and orbicularis palpebrarum muscles enjoy bilateral innervation. Nuclear lesions are due to hæmorrhage or thrombosis, the face on the same side being affected, and also the opposite arm and leg, as the motor decussation takes place at a lower level.

An infranuclear lesion may result from pressure of a tumour, e.g. of the cerebello-pontine angle, in which case involvement of the auditory nerve and cerebellum are usually evident.

2. *Cranial.*—The commonest causes of involvement of the intercranial portion of the facial nerve are fractures of the base, and middle ear disease. In cases of fracture involvement may be immediate, usually due to hæmorrhage within the sheath of the nerve, in which case recovery is probable. Involvement after a few weeks is due to pressure by callus, and the prognosis should be guarded. Facial paralysis as a complication of middle ear disease sometimes follows injury if an operation on the mastoid antrum is performed. Compression within the aqueduct of Fallopius occasionally follows chronic inflammation.

In cases of involvement of the cranial portion of the facial nerve, some paralysis of the palatal muscles may occur, due to interference with the petrosal nerves. Hyperacusis results from paralysis of the stapedius muscle, and if injury occurs between the geniculate ganglion and the iter chordæ posticus, interference with the chorda tympani nerve will result in loss of taste in the corresponding half of the tongue.

3. *Extracranial.*—Either the facial nerve or its branches are sometimes injured outside the skull. The nerve itself is commonly involved in Bell's palsy. This condition is due to neuritis of the nerve, and may follow some well-remembered exposure. Swelling within the sheath of the nerve extends into the stylo-mastoid foramen, and consequently the nerve is compressed within the bony canal. Absorption of exudate usually occurs before the pressure has been sufficiently prolonged to damage the nerve permanently, but in about 3 per cent. of cases paralysis remains. Tetanus arising from a wound in the distribution of the facial nerve sometimes causes paralysis, the cause being similar to that operating in Bell's palsy. Malignant tumours of the parotid gland are likely to infiltrate the facial nerve, and this involvement is an important diagnostic sign in distinguishing simple and malignant tumours.

Branches of the facial nerve are injured either accidentally, e.g. broken windscreens, or by ill-placed operation incisions. It should be needless to say that operations on the parotid gland for the removal of tumours or drainage of abscesses should be performed through incisions parallel to the main divisions of the nerve.

As a result of facial paralysis the face is flat and expressionless, and in attempting to close the eye the eyeball turns upwards and outwards. Corneal ulceration may follow from exposure. Epiphora occurs owing to drooping of the lower eyelid. Whistling is impossible, as the cheek merely flaps, and food collects between the gums and cheek. Treatment is directed to any cause, and the angle of the mouth should be supported by means of a malleable rod covered with rubber tubing. This is bent like an "S"; the upper curve hooks around the ear, and the lower passes into the mouth. If desired, a special appliance can be obtained for this purpose (fig. 576). Electrical treatment and massage should be maintained as long as recovery is likely to occur, after which nerve anastomosis with the hypoglossal nerve might be considered.

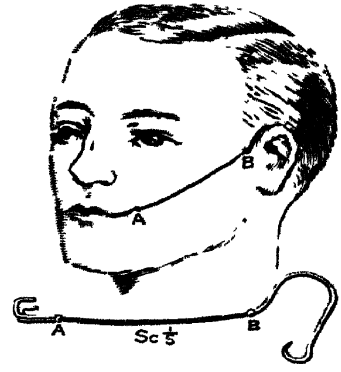

FIG. 576.—Chain and hooks for the support of muscles in a case of facial paralysis.

The **Eighth Nerve** may be involved in fractures of the middle fossa, or compressed by a tumour, e.g. of the auditory nerve sheath, in which case unilateral deafness is sometimes the first symptom.

The **Ninth Nerve** is occasionally injured by a fracture involving the jugular fossa. Some dysphagia may occur from paresis of the constrictor muscles, and trophic ulceration of that side of the tongue has been ascribed to injury of the glosso-pharyngeal nerve.

The **Tenth Nerve** may be damaged in association with a fractured base, or crushed by a ligature which includes it as

well as the internal jugular vein or common carotid artery. Œdema of the lung has followed in some cases, but injury to one vagus nerve is unlikely to cause more than a temporary tachycardia. In doubtful cases examination of the laryngeal muscles will reveal vagal injury if such is present. Irritation of the nerve by a ligature which is not sufficiently tight to destroy it causes an intractable and distressing cough from laryngeal spasm.

The *recurrent laryngeal nerve* is extremely susceptible, and is often temporarily involved in operations on the thyroid gland, either by traction, or pressure by traumatic œdema. Complete involvement sometimes follows division or inclusion by a ligature at operation, infiltration by neoplasm of the thyroid gland or œsophagus, and on the left side pressure by an aneurism of the aortic arch. Partial involvement affects the abduction fibres, which are more susceptible than those which supply the adductor muscles, and thus if partial involvement is bilateral, stridor results, and tracheotomy may be required. Complete involvement results in paralysis of both abductors and adductors, and consequent paralysis of the corresponding vocal cord in the half-way or cadaveric position. The opposite vocal cord increases its range of mobility, so that it reaches across the mid-line and closes the glottis, but little alteration in the voice is noticed.

Hysterical aphonia sometimes follows a sudden shock or violent emotion. It is readily distinguished from true paralysis by the fact that, although the patient can only whisper, yet coughing is readily performed on request.

The **Eleventh Nerve** is rarely damaged by fractures involving the jugular fossa. More commonly it is injured during operations on the neck, particularly in the removal of tuberculous glands which often entirely surround the nerve. The nerve passes downwards and backwards at right angles to the centre of a line connecting the angle of the jaw and the mastoid process, and emerges from the posterior border of the sterno-mastoid muscle at the junction of the upper third and lower two-thirds; it then passes

across the posterior triangle, and disappears under cover of the trapezius muscle. Division of the nerve in the anterior triangle results in only partial paralysis of the trapezius and sterno-mastoid muscles, as the trapezius receives an additional supply from the third and fourth cranial nerves, and the sterno-mastoid from the second and third. If injury occurs in the posterior triangle the trapezius alone is affected. On inspection slight drooping of the shoulder is seen, and wasting of the trapezius is obvious (fig. 557).

FIG. 577.—Wasting of the left trapezius following injury to the spinal accessory nerve.

The integrity of the sterno-mastoid muscle is tested by placing a hand under the patient's chin and requesting him to flex his head. Palpation will then detect the rigid band of muscle if contraction is normal. Injury of the nerves to the trapezius results in inability to elevate the arm further when it is abducted to a right angle by the deltoid muscle. If the branches to the muscle from the third and fourth cervical nerves are intact, about 20° elevation from the right-angled position is possible.

If division of the spinal accessory nerve is recognised at operation, primary suture should be performed. Secondary suture is unlikely to be successful on account of retraction of the ends and difficulty in identifying them in scar tissue.

The **Twelfth Nerve** escapes in fractures of the base of the skull, as the anterior condyloid foramen is protected by a bony ridge which diverts a fissure towards the foramen

magnum. Nevertheless, it is commonly endangered in cervical operations, especially those for removal of tuberculous glands. Hemiatrophy of the tongue occurs, the corresponding side of the tongue being shrivelled and wrinkled. On protrusion the tongue is pushed towards the paralysed side.

Spinal Nerves

Injuries of the **Cervical Plexus** are uncommon, although muscular branches, e.g. to the trapezius and sterno-mastoid muscles, are occasionally damaged during operations on the neck.

The **Phrenic Nerve** is commonly evulsed in order to collapse the base of a lung, in such cases as bronchiectasis or basal tuberculosis. The operation is sometimes combined with thoracoplasty or with artificial pneumothorax.

Division of the nerve, as first practised, frequently gave disappointing results, for an accessory phrenic nerve, arising either from the fifth cervical nerve, or the nerve to the subclavius, is present in 20 to 30 per cent. of cases, and joins the main nerve between the first rib and the root of the lung. Thus *evulsion* is now universally practised, the nerve being exposed as it lies on the scalenus anticus muscle, seized with Spencer Wells' forceps, divided, and the distal end slowly twisted and withdrawn from the thorax. About 4 in. of nerve is then removed, and any bleeding from the accompanying artery soon ceases spontaneously. Subsequent X-rays indicate the degree of post-operative elevation of the diaphragm, which varies between 1 and 3 in., depending on the amount of accessory nerve-supply it receives from the lower intercostal nerves, and the presence of adhesions. The volume of the lung is diminished by about one-third.

The phrenic nerve on the right side passes between a group of glands below the inferior branch of the pulmonary vein, while the left phrenic has no glandular relations. Involvement of the glands secondary to malignant disease of the lungs is a frequent cause of compression of the right nerve and consequent paralysis of the right half of the diaphragm (fig. 578).

FIG. 578.—Elevation of the diaphragm following involvement of the right phrenic nerve by malignant glands. The primary bronchial growth is indicated by arrows.

Brachial Plexus lesions are either complete or partial.

Complete lesions are rare, as an injury of sufficient severity to damage all the roots of the plexus will probably inflict fatal injuries on adjacent important structures. In the rare event of a complete lesion, anæsthesia of the upper limb is present except over areas supplied by the supra-acromial branches of the cervical plexus and the intercosto-humeral nerve. Complete paralysis is present of arm and scapular muscles, except that in the case of tears of the plexus the lesion is usually distal to the site at which the nerve of Bell and the nerve to the rhomboid arise, and consequently the serratus magnus and rhomboid muscles escape.

Incomplete lesions, if due to stabs or cuts, are liable to affect any of the roots, the clinical features depending on the nerves divided. The commonest type of injury is due

to traction or pressure, and affects either the upper or lower portions of the plexus.

Although the segmental innervation of the arm muscles is probably somewhat inconsistent, the following table summarises a distribution which is commonly accepted :

Nerve	*Muscles*
C. v	Rhomboids, spinati, deltoid, teres minor, coracobrachialis, biceps, brachialis anticus, supinator longus and brevis.
C. vi	Pectoralis major and minor, subscapularis, latissimus dorsi, teres major, serratus magnus, triceps, pronator radii teres, pronator quadratus.
C. vii	The extensors and flexors of the wrist.
C. viii	The extensors and flexors of the fingers.
D. i	The small muscles of the hand.

Upper Lesion (Erb).—This injury is due to excessive displacement of the head, depression of the shoulder, or a combination of these two conditions. Thus, it not uncommonly occurs during a difficult confinement, and in adults may be due to weights falling on the shoulder. The fifth and sometimes the sixth cervical roots are involved. The muscles affected are the biceps, brachialis anticus, supinator longus and brevis, spinati and deltoid, and thus the limb, internally rotated by the unopposed subscapularis, hangs by the side with the forearm pronated, in the well-known "tip" position (fig. 694). Sensory changes are absent, if only the fifth nerve is involved, but if the sixth nerve is also damaged, then an area of anæsthesia is present over the outer side of the arm.

Lower Lesion (Klumpke).—The lower nerve trunks or the inner cord are injured either above the clavicle, e.g. by pressure of a cervical rib, or classically by inclusion with the subclavian artery in a ligature, or in the axilla, as by an unreduced dislocation of the humerus. In either case, the inner portion of the plexus is involved, and wasting of all the small muscles of the hand occurs, together with sensory changes along the inner side of the forearm and the inner three and a half fingers, owing to interference with the ulnar and inner head of the median nerves.

Nerve roots may be avulsed from the spinal cord, as in the case of a falling person clutching at an object and hyper-

abducting his arm. The first dorsal root is usually affected, paralysis of the intrinsic muscles of the hand resulting, with anæsthesia of the inner three and a half fingers in front, and inner one and a half behind, protopathic loss being greater than epicritic, as the lesion is one of the nerve roots. In addition, the oculo-pupillary fibres, which pass along the dorsal nerves to the rami communicantes, and so to the cervical sympathetic, are also affected, and thus contraction of the pupil and recession of the eyeball follow, the latter condition being attributed to paralysis of the muscle of Müller, which bridges the sphenoidal fissure. Hæmorrhage sometimes occurs in the spinal cord, due to evulsion of the nerve root, and is followed by irritation of the pyramidal tract and consequent spasticity of the leg of the same side.

The treatment of injuries to the brachial plexus follows the principles already indicated. Open wounds are immediately explored, and nerves sutured if possible. Subcutaneous injuries are at first treated on expectant lines, paralysed muscles being relaxed. Thus, in the case of an Erb's paralysis, the arm should be fixed in a position of right-angled abduction and eversion, to relax the deltoid and subscapularis, the forearm being flexed and supinated in order to relax the biceps, brachialis anticus, and supinators. Commonly, for convenience, the arm is merely bandaged across the chest, but if recovery is prolonged, the price paid for convenience is paresis of the deltoid and spinati muscles, which are not relaxed in this position.

The commonest subcutaneous lesion of the plexus is intraneural hæmorrhage, due to rupture of the sheath of the affected nerve or nerves, in which case more or less complete recovery ensues. More serious lesions, in which nerves themselves are torn, demand efforts at surgical repair, although the results are indifferent.

The brachial plexus is exposed by an incision along the posterior border of the sterno-mastoid. If necessary the incision may be carried backwards along the middle third of the clavicle, or, if complete exposure of the plexus is desirable, the original incision is prolonged over the clavicle, which is drilled for subsequent wiring, and divided. The weight of the arm separates the ends of the divided clavicle, and the plexus is freely exposed. Three difficulties now

confront the surgeon. The first is fibrosis and matting together of structures due to organisation of extravasated blood. When torn nerves are recognised and dissected from their fibrous bed, approximation is difficult on account of retraction, and posture can give but limited assistance. Finally, rupture commonly occurs where nerves fuse or divide, so that accurate apposition is a difficult problem, in that it may be necessary to suture two roots to one trunk.

Peripheral Nerves

The **Circumflex Nerve** passes through the quadrilateral space, and winds around the shaft of the humerus about one finger's breadth below the centre of the deltoid muscle. It is injured by a direct blow, or involved by a fracture or dislocation of the upper end of the humerus.

The deltoid muscle is paralysed and wastes rapidly (fig. 579), and a patch of anæsthesia over the outer side of the

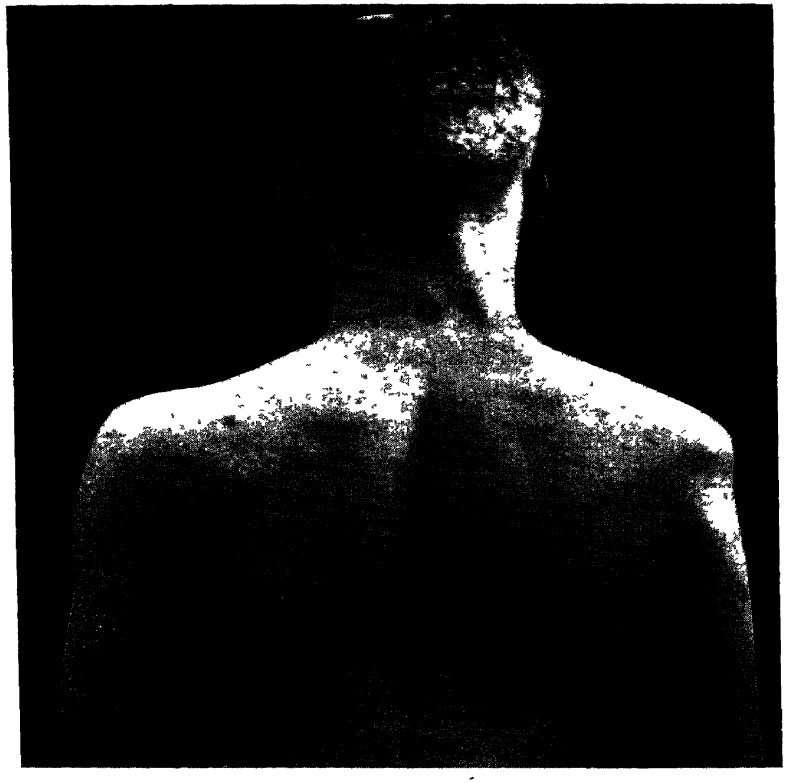

Fig. 579.—Wasting of the right deltoid muscle, due to injury of the circumflex nerve, following dislocation of the shoulder.

arm distinguishes this condition from a partial lesion of the fifth cervical nerve. Involvement of the teres minor is unrecognisable.

Recovery commences soon if the cause of the compression is removed, provided that in the meantime the arm has been supported in right-angled abduction.

The **Nerve of Bell** has been injured by blows on the shoulder, or during operations on the breast, or chest wall, as it lies on the inner wall of the axilla. Paralysis of the serratus magnus allows "winging" of the scapula, i.e. the vertebral border and inferior angle are unduly prominent. The "lunge" stroke of fencing is dependent on the serratus magnus, and this and similar movements, such as pushing forward with the arm, are deficient. Owing to inability to rotate the scapula on the chest wall, difficulty is experienced in raising the arm above a right angle from a position in front of the body.

Suture of the nerve is sometimes possible. Otherwise, if sufficient disability exists, the scapula may be steadied by a slip of pectoralis major muscle, which is detached from the humerus and fixed to the inferior angle of the scapula.

The **Musculo-spiral Nerve** is commonly injured. The classical sites are the axilla and the musculo-spiral groove.

1. Injury in the **axilla** follows :

(i) Crutch palsy : all crutches should have hand-grips, and length should be carefully adjusted, especially if use is likely to be prolonged. Paresis has occurred after only an hour's use with faulty crutches.

(ii) Fractures and dislocations of the upper end of the humerus, or by attempts at their reduction.

(iii) Rarely by pressure of an aneurism, or new growths.

Clinical Features.—(*a*) *Motor*.—The triceps and extensors of the wrist and fingers are paralysed, and consequently inability to extend the elbow, wrist, and fingers results, and drop wrist is present. If the hand is supported, as by resting it upon the table, extension of the fingers can be produced by the action of the lumbricals and interoseii, which are inserted into the extensor expansions. The supinator

longus and brevis are also paralysed, but supination is ably performed by the biceps. The supinator longus muscle is tested readily by endeavouring to flex the semi-prone forearm against resistance, and if the muscle is active the contraction is visible, and the rigid muscle is also easily palpable.

(*b*) *Sensory.*—Epicritic anæsthesia occasionally occurs over the back of the hand, thumb, and outer two and a half fingers, with the exception of the nail beds, which are supplied by the median nerve. This area of anæsthesia is usually reduced to a patch at the ball of the thumb, owing to overlap by the musculo-cutaneous nerve. Protopathic sensation is lost over a smaller area than epicritic.

(*c*) *Trophic.*—These are usually trivial.

2 Injury in the **musculo-spiral** groove is due to :

(i) Pressure, e.g. of the arm on the edge of the operating table, especially in Trendelenburg's position, or " Saturday night " paralysis, due to the enjoyment of a heavy sleep with the arm over the sharp back of a kitchen chair. Prolonged application of a tourniquet may involve the musculo-spiral nerve, and possibly the median and ulnar nerves as well.

(ii) Fracture of the shaft of the humerus, immediate involvement of the nerve occurring in about 8 per cent. of cases. It is often overlooked owing to the more obvious fracture overshadowing the nerve injury, in which case involvement in callus is usually blamed, rather than oversight of the surgeon. Actually, involvement in callus is a rare event.

(iii) The nerve is liable to be overstretched during operations on the humerus, e.g. in dealing with an ununited fracture.

(iv) " Intramuscular " injections of drugs have been given into the musculo-spiral nerve.

Clinical Features.— (*a*) *Motor.*—These are similar to those following injury in the axilla, except that the triceps and anconeus muscles escape.

(*b*) *Sensory.*—If the external cutaneous branch escapes, anæsthesia will be limited to a patch over the ball of the thumb.

(*c*) *Trophic.*—These are slight.

The *posterior interosseous nerve* may be injured as a result of fracture or dislocation of the upper end of the radius, or in operations performed to deal with these conditions. Paralysis of the extensors of the wrist and fingers results. Division of the radial nerve in the upper third of the forearm is symptomless. Below this position the musculo-cutaneous nerve joins the radial, and the division then causes anæsthesia over the ball of the thumb.

The **Median Nerve** is classically injured at the wrist or elbow.

1. Injuries at the **elbow** are due to fractures of the lower end of the humerus or dislocations of the elbow joint. A tourniquet endangers the nerve at any level in the arm, in which case other nerves, particularly the musculo-spiral, which lies closest to the bone, will also be involved.

Clinical Features.—(*a*) *Motor.*—The pronators of the forearm and flexors of the wrist and fingers, with the exception of the flexor carpi ulnaris and the inner part of the flexor profundus digitorum, will be paralysed. Thus hyperextension occurs at the metacarpo-phalangeal joints. The index finger is also extended at the phalangeal joints—the "pointing index"—but the other fingers are partially flexed owing to the action of that portion of the flexor profundus digitorum which is supplied by the ulnar nerve. Flexion of the terminal phalanx of the thumb is impossible, owing to paralysis of the flexor longus digitorum. The muscles of the thenar eminence are wasted and paralysed, and on inspection the eminence is flattened, so that the metacarpal bone of the thumb is apparently on the same plane as the other metacarpal bones—the so-called "Simian" or "ape-like" hand. Paralysis of the two outer lumbricals is unrecognisable.

(*b*) *Sensory.*—Epicritic sensation is lost over the thumb and outer two and a half fingers in front, and corresponding nail beds. Protopathic loss is less, and muscular sense may be impaired to a degree corresponding with the paralysed muscles.

(*c*) *Trophic.*—Obvious trophic changes are usually seen in the hand and affected fingers.

2. Injuries at the **wrist** are comparatively common, and are due to cuts from a variety of causes, e.g. windscreens, bursting bottles, or "smash and grab" raids. Fractures of the lower end of the radius, if associated with much deformity, are sometimes complicated by injury to the median nerve.

Clinical Features.—(*a*) *Motor.*—The muscles of the thenar eminence are paralysed and wasted. Thus the "Simian" appearance develops, and apposition of the thumb is imperfect.

(*b*) Epicritic and protopathic losses resemble those following an injury at the elbow. Muscular sense is not impaired if tendons are not severed. Thus, as no striking muscular deficiency occurs, and as no part of the hand is completely anæsthetic, a divided median nerve at the wrist may be readily overlooked, particularly in those who use epicritic sensation but little, e.g. a horny-handed labourer.

(*c*) *Trophic.*—These occur, as with an injury at the elbow.

The poor prognosis associated with division of the median nerve is rendered even more gloomy if tendons are also divided.

The **Ulnar Nerve** is also classically injured at the elbow and wrist.

Injuries at the **elbow** are due to the following causes :

(i) Fractures in the region of the internal condyle.

(ii) Excision of the elbow joint.

(iii) Cubitus valgus, due to old injury of the humerus and increase of the "carrying angle." Hence the nerve is unduly exposed, and friction occurs as the groove on the internal condyle becomes a pulley, and continuous friction results in interstitial neuritis. This condition may occur many years after the original injury, and anterior transposition of the nerve is sometimes necessary.

Clinical Features.—(*a*) *Motor.*—The flexor carpi ulnaris and inner portion of the flexor profundus digitorum are

paralysed. Normally, on flexion of the wrist, the tendon of the flexor carpi ulnaris is readily palpable just above its insertion into the pisiform bone, but when the muscle is paralysed the tendon is impalpable, and wasting causes flattening of the inner border of the forearm. Weakness of the flexor profundus digitorum results in hyperextension of the little, ring, and slightly of the middle fingers at the metacarpo-phalangeal joints.

Paralysis of the small muscles of the hand also results, with the exception of the thenar muscles and outer two lumbricals. Considerable wasting occurs, which is particularly obvious in the interosseous spaces and along the inner border of the hand, the normal curve being lost. Inability to abduct and adduct the fingers results, and adduction of the thumb is weak.

(*b*) *Sensory.*—Epicritic sensation is lost over the inner one and a half fingers in front and behind. Protopathic loss is somewhat less.

(*c*) *Trophic.*—These changes are usually well marked.

Injury at the **wrist** is due to the same causes as those enumerated in connection with the median nerve. The ulnar nerve passes in front of the anterior annular ligament, and therefore is liable to be injured by more superficial injuries.

Clinical Features.—(*a*) *Motor.*—Paralysis and wasting of small muscles of the hand, as described above.

(*b*) *Sensory.*—The dorsal cutaneous branch of the ulnar nerve leaves the main trunk about 2½ in. above the styloid process of the ulna. Sensation is therefore lost only on the anterior aspect of the inner one and a half fingers.

(*c*) *Trophic.*—Correspond to the area of sensory loss.

The **Twelfth Dorsal Nerve**, as in the case of the intercostal nerves, is sometimes implicated by severe neuralgia, which may be associated with herpes zoster. Neuralgia of the twelfth nerve is occasionally due to pressure by an elongated twelfth rib, and has been cured by removal of the costal tip. More commonly the nerve is implicated by a suture during a kidney operation, or by subsequent scar tissue. Resulting

pain is occasionally sufficiently severe to necessitate exposure and division or evulsion of the nerve.

The **Ilio-inguinal Nerve** may be damaged in a gridiron incision, although with care the nerve should be avoided. If drainage tubes are inserted through the incision, the resulting scar tissue may implicate the nerve. Weakness of the conjoined tendon and muscles protecting the internal abdominal ring results, with consequent predisposition to the formation of a direct hernia (fig. 580).

FIG. 580.—A direct inguinal hernia which followed appendicectomy with drainage, through a gridiron incision, one year previously.

The **External Cutaneous Nerve** is occasionally pinched as it passes through the deep fascia of the thigh, especially in muscular subjects. Resection of the nerve is sometimes necessary to rid the patient of pain or paræsthesia (fig. 581).



FIG. 581 —Area of anæsthesia following resection of the external cutaneous nerve. The scar of the operation is visible.

The **Great Sciatic Nerve** is occasionally injured by wounds, fractures, or injection of drugs. The component nerves in the pelvis may be involved by fracture, tumour, or aneurism. Injury in the upper part of the thigh sometimes complicates deep wounds or posterior dislocation of the hip joint. If the lesion is above the origin of branches to the hamstrings, the following features will be present :

(*a*) *Motor*.—The flexors of the knee

are paralysed, but weak flexion is possible owing to the sartorius and gracilis muscles. Complete paralysis exists below the knee, and drop foot results from gravity.

(*b*) *Sensory.*—Complete loss below the knee, with the exception of the skin supplied by the long saphenous nerve, i.e. a strip along the inner side of the leg extending along the inner border of the foot to the ball of the big toe.

(*c*) *Trophic.*—Especially on the sole of the foot and toes.

Partial involvement of the great sciatic affects the external popliteal portion nine times as commonly as the internal popliteal ; a possible explanation of this disproportional incidence is that the external popliteal fibres are the more superficial.

The **External Popliteal Nerve** is injured by the following means :

(i) Subcutaneous tenotomy of the biceps tendon.

(ii) Fracture or excision of the upper end of the fibula.

(iii) Pressure, as by a tightly fitting MacIntyre's splint.

(iv) Cuts, such as scythe wounds.

Clinical Features.—(*a*) *Motor.*—Complete paralysis of the extensor and peroneal groups of muscles, with resulting talipes equino-varus.

(*b*) *Sensory.*—Anæsthesia on the outer side of the leg in its lower two-thirds, and of the dorsal aspects of all the toes, with the exception of the outer side of the little toe, which is supplied by the external saphenous nerve, one contributory branch of which—the ramus communicans tibialis—escapes.

(*c*) *Trophic.*—Corresponding to the sensory loss.

The **Internal Popliteal Nerve** is but rarely injured on account of its protected position. The calf muscles and muscles of the sole are paralysed, and talipes calcaneo-valgus may result. The sole is anæsthetic, and trophic changes usually marked. Causalgia occasionally follows a partial injury of the nerve, or injury to one of its branches.

THE SYMPATHETIC NERVOUS SYSTEM

Anatomy.—The sympathetic nervous system is composed of preganglionic fibres, ganglionated trunks, and postganglionic fibres.

Preganglionic fibres are axons of the "connector" cells situated in the lateral horns, which are present in the grey matter of the dorsal and upper two or three lumbar segments of the spinal cord. These medullated fibres pass from the anterior roots of the dorsal and upper lumbar spinal nerves (white rami communicantes) and join the ganglionated trunk. Here some form synapses, while others pass through the ganglia to reach visceral ganglia and plexuses. Finally, preganglionic fibres pass to the medulla of the suprarenal gland (which is developed from nerve tissue, and therefore the medulla itself represents the synapse and postganglionic fibres).

The **ganglionated trunks** of the sympathetic lie upon the sides of the bodies of the vertebræ, and extend from the skull to the coccyx. In the cervical region the ganglia are condensed to three in number. The dorsal ganglia number eleven or twelve, the upper one of which is closely connected with the inferior cervical ganglion, and forms the stellate ganglion. The lumbar and sacral ganglia usually number four in each region.

In addition to the ganglionated trunk, visceral ganglia also exist, e.g. the cœliac, superior and inferior mesenteric. To these ganglia the splanchnic nerves pass from the lower six dorsal ganglia of the sympathetic trunk. These splanchnic nerves contain preganglionic fibres which have traversed the ganglia of the sympathetic cord.

The **postganglionic** or second relay of fibres are non-medullated, and originate in the trunk and visceral ganglia from cells (termed excitor cells) which form synapses with the preganglionic fibres. These postganglionic fibres innervate the sweat glands, pilomotor muscles, vessels, viscera, and other structures influenced by the sympathetic system. In addition, from all the ganglia of the sympathetic trunk, two or more grey rami communicantes pass to each spinal nerve.

A central sympathetic nucleus exists in the region of the diencephalon, and is influenced by stimuli from the higher centres. Clinical evidence shows that a tumour which interferes with the anterior and superior portions of the thalami causes sympathetic derangement (Penfold).

The function of the sympathetic nervous system is to deal with emotional and physiological emergencies. In normal circumstances the endocrine glands are capable of counteracting minor variations. The sympathetic system is designed to prepare the animal for defence. Thus the blood-pressure is raised and pulse-rate increased so as to maintain the circulation at a high pitch of efficiency, and contraction of the spleen forces an excess of red cells into the circulation so as to assist in oxygenation, which is supplemented by dilatation of the bronchioles. The pilomotor muscles contract and cause the "hair to stand on end," which is a useful phenomenon in the case of an animal, as its apparent size and ferocity are increased. In order to maintain muscular efficiency glucose is set free from the liver, and exophthalmos and dilatation of the pupil widen the visual fields. The unstriped muscle of the intestine is relaxed in order to prevent waste of energy by peristalsis, and sweating assists in preventing a deleterious rise of temperature. The supply of adrenaline is increased so that reaction already commenced by stimulation of the sympathetic is augmented and maintained.

The **parasympathetic** system has its origin in the brain and sacral region. Cranial parasympathetic fibres pass to the pupil, salivary glands, the heart, and alimentary canal, including its developmental outgrowths, i.e. lungs, liver, and pancreas. Parasympathetic impulses stimulate the secretion of saliva and cause contraction of the pupil. It is secretory and motor to the alimentary canal, and inhibitory to the heart.

The sacral portion of the parasympathetic system is concerned with the "emptying processes." Thus it supplies motor impulses to the rectum and bladder, and is concerned with penile erection.

The above summary explains two important clinical observations. Firstly, in cases of ileus a spinal anæsthetic frequently results in a copious motion, and in doubtful cases the effect of a spinal anæsthetic is a useful method of discriminating between mechanical and paralytic obstruction. The beneficial effects of spinal anæsthesia are due to paralysis of the inhibitory sympathetic fibres, with the result that the motor parasympathetic impulses are unopposed.

Secondly, the fall of blood-pressure which occurs during spinal anæsthesia is due to paralysis of the vaso-constrictor nerves. This can be to some extent counteracted by an intramuscular injection of ephedrin (gr. ½ - ¾).

Indications for Operation

I. To Improve Circulation

Sympathectomy, by removing the influence of vaso-constrictors, allows dilatation of the corresponding blood-vessels. This chiefly concerns the smaller arteries, which contain a large proportion of unstriped muscle in their walls, and the large vessels are but little affected. Also pathological changes in the coats of the vessels are liable to impair very seriously their power of dilating, and therefore pre-operative tests are necessary in order to estimate the capacity for dilatation.

Tests for Vasodilatation

(i) **Protein Shock.**—Muscle extracts or 50 millions of triple typhoid vaccine (typhoid and paratyphoid A and B) are injected intravenously, and the resultant rise of temperature in the mouth and extremities is noted.

Brown's vasomotor index is calculated by subtracting the rise in temperature of the skin from that in the mouth, and dividing that figure from the rise of temperature in the mouth. For example, the mouth temperature rises 2° and the temperature of the foot 14°, subtracting these (12) and dividing by the rise of temperature in the mouth (2), it is found that the vasomotor index is 6. The greater the index the greater is the capacity of the vessels to dilate and the better the prognosis, while a negligible rise contraindicates operation.

(ii) **Anæsthesia of the Sympathetic.**—In the case of the lower limbs a spinal anæsthetic which reaches to the level of the umbilicus

inhibits vasoconstrictor impulses to the legs. An ordinary bath thermometer bandaged between the first and second toes will give a rough indication of alteration of temperature, but a precise method is by means of thermocouples, which can be attached at different levels on the limb and so indicate the condition of vessels at the various levels.

Sympathetic fibres to the upper limb can be anæsthetised by injection from behind of 5 c.c. of 1 per cent. novocaine below the necks of the first and second ribs. The stellate and upper dorsal ganglia are thus reached and vasoconstrictor impulses to the arm are interrupted. Intraneural injection of a peripheral nerve has the same effect over the area of distribution of the nerve. Thus the brachial plexus, or ulnar nerve at the elbow, can be injected with 2 per cent. novocaine and the effect upon the vessels noted.

(iii) **Heating the Body.**—The patient sits in a chamber constructed of non-conducting material so that his head and wrists or ankles protrude, the basis of the investigation being the estimation of the reflex dilatation produced by heating the body. The hands are cooled by immersion in water at 15° C., the temperature of the room being maintained at that level, and the patient is sealed in the chamber. The temperature of the chamber is raised to 50°, and by means of an electric thermometer the effect upon the peripheral circulation is accurately estimated.

Thrombo-angiitis obliterans (*syn.* Buerger's disease), which is a progressive condition, erroneously stated to be commoner in Russian Jews. It affects mainly the lower limbs, and usually terminates in gangrene, and is associated with severe pain and sometimes with intermittent claudication. Two factors are present—vasospasm, and thickening of the arterial wall which may progress to obliteration. It is possible that the primary condition is one of spasm, which interferes with the circulation through the vasa vasorum, and consequently the nutrition of the arterial wall is impaired and degeneration follows.

In suitable cases lumbar ganglionectomy relieves pain and promotes the healing of ulcers, but prognosis must be guarded, as many cases, after remarkable initial improvement, are apt to relapse, although pain is always greatly relieved.

Raynaud's disease, which is practically confined to females and usually commences in early adult life. Paroxysmal attacks of vasospasm occur in the hands, and are precipitated by cold and occasionally by emotion. As a result the hands become cold and cyanosed, and are incapable of finer movements, and the attacks are also accompanied by aching

pain of considerable severity. As the attack passes off, the hands become red and a burning sensation replaces the previous numbness. Eventually superficial necrosis occurs, the tips of the fingers undergo dry gangrene and the distal parts of the terminal phalanges are absorbed. In some cases scleroderma affects the hands and face.

The immediate results of ganglionectomy in Raynaud's disease are good, but after a few weeks the susceptibility to cold returns although cyanosis is not so severe as before the operation, the attacks are of shorter duration and are not painful. This partial relapse is an indication that the underlying cause of Raynaud's disease is not in the sympathetic system, but is due to some abnormality in the smaller arteries and arterioles; sympathectomy apparently lowers the threshold at which spasm occurs. From the practical point of view, ganglionectomy is a very satisfactory palliative procedure in Raynaud's disease, especially if performed before the onset of scleroderma, ulceration, and absorption of the terminal phalanges.

Infantile Paralysis.—The improvement in the circulation which follows ganglionectomy has improved shortening in the limb of a growing child. Trophic sores and ulcers are encouraged to heal, but in some of the published cases the improvement has only been of a temporary nature.

Other Conditions.—Selected cases of scleroderma, in which the hands or face are principally affected, are improved by cervicothoracic ganglionectomy. The pain and stiffness of polyarticular osteoarthritis are alleviated by a suitable ganglionectomy, and some cases of retinitis pigmentosa with narrowing of the visual field have improved after removal of the first and second cervical ganglia. Extensive gastric ulcers, which are unsuitable for gastrectomy owing to local or general reasons, have been improved by removal or alcoholic injection of the plexus around the cœliac artery. Pain is relieved and healing encouraged by consequent improvement of the blood-supply. This operation might be considered as an adjunct to temporary jejunostomy in selected cases.

II. Painful Conditions

In the case of hollow viscera, pain is probably caused by stretching of the muscular coat resulting from intravisceral tension, and similarly, increased tension in hollow viscera stretches the fibrous capsule. The relief of pain which

follows ganglionectomy in the case of the limbs is probably due to an increased blood-supply.

Causalgia is a condition in which paroxysmal attacks of pain follow infected wounds, especially in the region of the distribution of the median and posterior tibial nerves. The pain is burning in character, and relieved by wearing wet gloves or socks. As in the case of trigeminal neuralgia, a paroxysm is liable to be precipitated by sudden stimuli, such as a sudden noise or unexpected occurrence. Hyperæsthesia, wasting, and trophic changes are associated symptoms. Some cases of causalgia tend to recover gradually, but the condition is so distressing that surgical alleviation is highly desirable. Periarterial sympathectomy will probably relieve many cases, but ganglionectomy is more certain in its results.

Visceral Pain.—*Bladder.*—The constant wearying pain of chronic cystitis is relieved by resection of the presacral nerve, which may be combined with division of the sympathetic cords. Carcinoma is apt, sooner or later, to escape from the confines of the bladder and cause pain from invasion of the lumbo-sacral plexus and other structures, which is beyond the aid of sympathectomy.

Uterus.—The majority of cases of spasmodic dysmenorrhœa which do not respond to less drastic measures are cured or relieved by presacral neurectomy. No untoward effects on uterine or bladder function have been recorded, but readers must be referred to treatises on these subjects for details of results.

III. Secretory Disturbances

Excessive sweating is sometimes so distressing to the patient that he is willing to undergo surgical measures in order to obtain relief.

Excessive sweating of the face, which is sometimes associated with emotional stress, is abolished by removal of the superior cervical ganglion. Sodden, offensive feet, the skin of which is cracked and painful, may be a genuine disability and is curable by lumbar ganglionectomy.

A parotid fistula, which fails to respond to cautery or

radium, is encouraged to heal by evulsion of the auriculo-temporal nerve, which is exposed in front of the ear in relation to the superficial temporal artery. The secretory fibres are thus ablated, and the fistula therefore closes.

IV. To Relieve Spasm

Megacolon and Colonic Stasis.—Achalasia of the pelvi-rectal sphincter was first described by Hirschsprung in 1886,

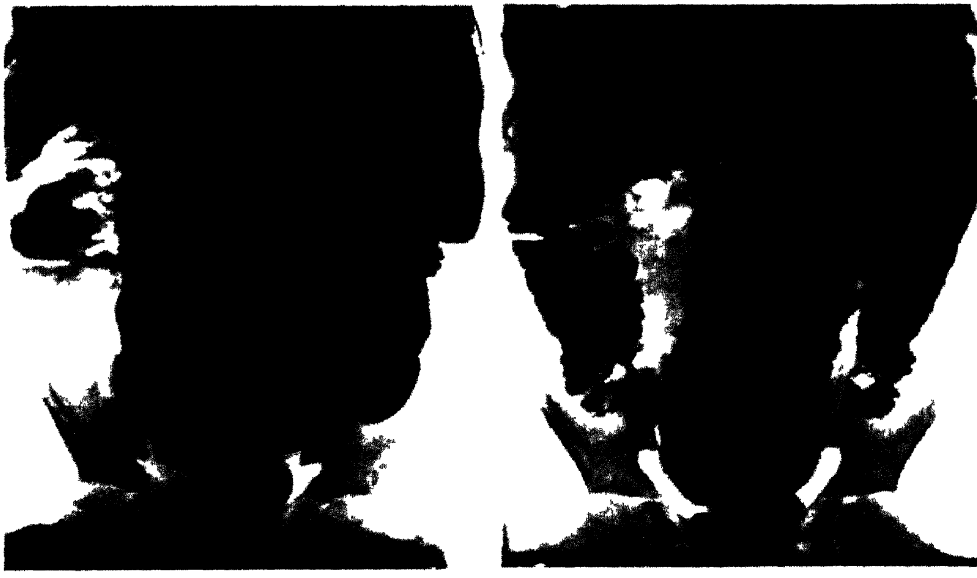

FIG. 582.—The condition of the colon in a case of Hirschsprung's disease as shown by a bismuth enema, before and after ganglionectomy (C. Naunton Morgan).

and the enormous dilatation of the colon which occurs in children is associated with his name. A similar condition, but usually of less severity, is also found in adults. Cases suitable for operation are selected by noting the result of spinal anæsthesia after a barium enema is administered. If adequate peristalsis follows, then removal of the left lumbar sympathetic trunk gives excellent results, although on anatomical and morphological grounds bilateral ganglionectomy would appear to be necessary (fig. 582). As in the case of arterial spasm, good results can only be expected if

operation is performed before the onset of secondary fibrotic changes.

Retention of Urine.—The presacral nerve contains sympathetic fibres which act as motor nerves to the internal sphincter, but the act of micturition is not interfered with to any great extent after presacral neurectomy, although some temporary frequency sometimes results. Apparently the nerve restricts the action of the detrusor urinæ muscle. In certain cases of "cord bladder" where unbalanced action follows such injuries as partial lesions of the cauda equina, resection of the presacral nerve has been of value in restoring muscular balance.

Presacral neurectomy and periarterial sympathectomy of the renal arteries have improved certain cases of hydroureter and hydronephrosis which were apparently due to neuro-muscular inco-ordination.

OPERATIONS

Periarterial Neurectomy.—Leriche, who popularised this operation, performed it in the belief that all the sympathetic fibres pass to a limb in the adventitia of the main artery. It is now known that the arteries to a limb receive sympathetic fibres from the aortic plexus, which accompany the main vessel, and also from mixed nerves which join the vessels at varying levels. Thus periarterial neurectomy does not destroy all the vasomotor fibres passing to the limb.

Nevertheless, periarterial neurectomy occasionally yields satisfactory results, but these are less consistent than ganglionectomy. Therefore the operation is more or less palliative, but it is sometimes of value in patients whose general condition is temporarily or permanently unsuited for the more extensive operation of ganglionectomy.

The operation is readily performed under local anæsthesia. The vessel is exposed for a distance of 2 or 3 inches, and the sheath and adventitious coats are divided and stripped off the vessel, which is conveniently rotated with an aneurism needle. Flooding the wound with saline reveals the sympathetic threads which are adherent to the muscular coat, and the last remnants of nerve fibres are destroyed by mopping the artery with 90 per cent. alcohol. Temporary contraction of the vessel follows neurectomy.

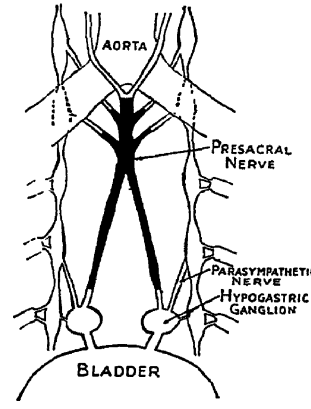

FIG 583.—The presacral nerve and its connections (*The Medical Annual*, 1934.)

Presacral Neurectomy.—The patient is placed in the Trendelenburg position and

the abdomen is opened by a subumbilical paramedian incision. The bifurcation of the aorta is exposed by a vertical incision through the overlying peritoneum, which is easily lifted from the vessel. The presacral nerves are usually represented by a plexus, and in order to ensure complete removal all the nervous, fatty, and areolar tissues lying over the lower inch of the aorta and the sacral promontory are excised (fig. 583).

Ramisectomy.—Theoretically, the division of the grey rami communicantes passing to a limb would interrupt the vasoconstrictor fibres. Practically, ramisectomy is difficult or impossible on account of anatomical variations and difficulties. Clinically, the results of attempted ramisectomy have been disappointing. Therefore this operation has now been abandoned in favour of ganglionectomy.

This operation of necessity includes ramisectomy, and interference with visceral sympathetic supply produces no untoward clinical symptoms.

Ganglionectomy.—Removal of the stellate ganglion and the lumbar ganglionated cord are the two operations most commonly practised.

Cervico-dorsal Ganglionectomy.—The stellate ganglion is formed by fusion of the inferior cervical and first dorsal sympathetic ganglion. As the second dorsal ganglion sometimes gives a branch to the brachial plexus (nerve of Kuntz), its removal is desirable.

Posterior Route.—The first and second ribs are exposed by means of a vertical incision through the muscles. The inner portions of ribs are removed and the pleura separated from the sides of the bodies of the vertebræ. The sympathetic trunk is exposed as it lies on the necks of the ribs in front of the intercostal and dorsal nerves. The trunk is divided below the second dorsal ganglion, and its connections divided until the upper border of the inferior cervical ganglion is exposed and severed. The posterior route necessitates a deep dissection through vascular muscles, but troublesome oozing can be limited by infiltration with novocaine and adrenaline.

Anterior Route.—Although the stellate ganglion is farther from the anterior surface of the neck, yet this route is recommended in preference to the posterior, as anatomical exactitude and careful dissection provide a more adequate exposure. The operation is performed under either general or local anæsthesia. An incision is made half an inch above the inner half of the clavicle, and the clavicular part of the sterno-mastoid, the posterior belly of the omohyoid, and the scalenus anticus muscles are divided, the phrenic nerve being displaced inwards. The subclavian artery is thus exposed, and the thyroid axis artery is divided between ligatures. Occasionally the posterior scapular artery arises directly from the subclavian, in which case it also is ligatured. The subclavian artery is depressed and Sibson's fascia is divided, so that the dome of the pleura can be displaced downwards and outwards. The stellate ganglion is then identified as it lies on the neck of the first rib (fig. 584), the superior intercostal artery being on the outer side. The sympathetic trunk is traced downwards and divided below the second dorsal ganglion, and its connections are severed until the upper border of the inferior cervical ganglion is reached. The intervening portion is then removed.

Successful ablation of the stellate ganglion is followed by Horner's syndrome, i.e. contraction of the pupil, enophthalmos, narrowing of the palpebral fissure, and anidrosis of the face and neck.

Lumbar Ganglionectomy.—Unilateral ganglionectomy is sometimes performed in cases where one limb has already been amputated for gangrene. The approach is extraperitoneal, and is similar to the exposure required for nephro-ureterectomy. The muscles are divided and the peritoneum is stripped inwards so as to expose the inner border of the psoas muscle, the ureter and colon retracted forwards.

The sympathetic trunk lies on the side of the bodies of the lumbar vertebræ, and on the right side is overlapped by the vena cava.

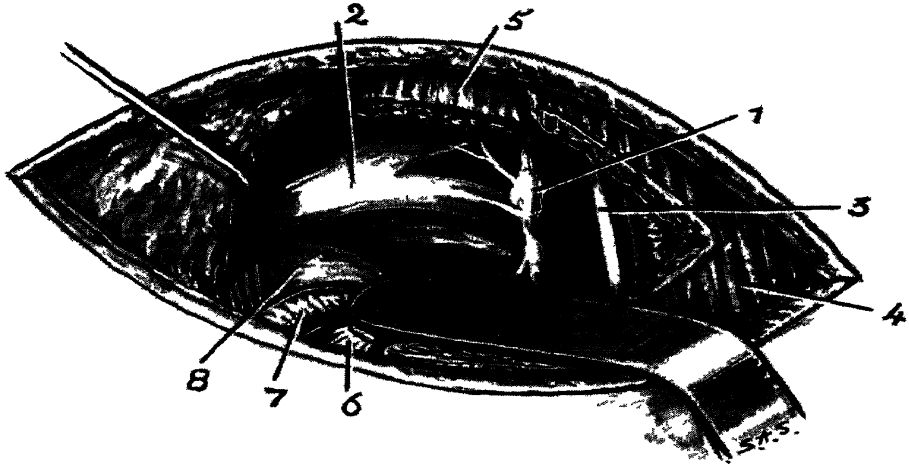

FIG. 584.—Exposure of the right cervico-dorsal sympathetic from the front.

1. Stellate ganglion
2. Inner cord of brachial plexus
3. Phrenic nerve displaced inwards.
4. Partially divided sterno-mastoid muscle.
5. Divided scalenus anticus muscle.
6. Divided posterior belly of the omo-hyoid.
7. Subclavian artery displaced downwards.
8. Dome of the pleura

Lumbar veins are apt to cross the trunk superficially, and must be meticulously ligatured as they pass directly into the adjacent inferior vena cava. The sympathetic trunk is divided on the side of the body of the fourth lumbar vertebra, and the trunk is traced upwards to below the duodenum on either side, where it is divided and resected.

Bilateral ganglionectomy is performed transperitoneally. A left paramedian incision is made extending from above the umbilicus to an inch or two above the pubis. Intestines are packed off, and on the right side the posterior layer of peritoneum is incised vertically over the outer side of the vena cava. The mesenteric attachment is displaced upwards, together with the ileo-colic and right colic arteries. The sympathetic trunk lies under the outer border of the vena cava, and is divided above after displacement upwards of the

duodenum. It is traced downwards until it disappears behind the right common iliac vein, when it is divided and resected.

On the left side exposure is gained by incising the peritoneum on the outer side of the pelvic colon. The bowel is stripped inwards together with the left colic vessels and ureter. The genito-crural nerve is seen emerging from the psoas, and eventually the inner border of the muscle is exposed. The sympathetic trunk is then identified as it lies on the vertebral bodies. It is divided above after displacement upwards of the duodenum, and is dissected downwards until it disappears underneath the left common iliac artery, where it is divided and removed.

CHAPTER XXXI

THE BREAST

THE NIPPLE

CONGENITAL ABNORMALITIES

Absence of the nipple is very rare, and it is associated usually with amazia.

Supernumerary nipples are fairly common, particularly in the male. They usually occur along a line extending from the anterior fold of the axilla to the fold of the groin. This constitutes the milk line of lower mammalia.

Retraction of the nipple is either recent or of long standing.

Long-standing retraction (fig. 585) is due to:

1. Failure of evolution from childhood to womanhood.

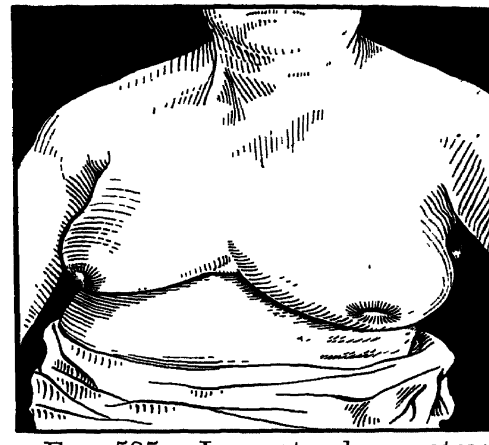

FIG 585.—Long-standing retraction of the nipples. The patient had also interstitial mastitis.

2. Fibrosis following a mammary abscess or mastitis of infancy.

The importance of long-standing retraction is dwarfed by the ominous diagnostic significance of recent retraction. Non-protuberance of the nipple hinders an infant suckling at the breast. It is a common clinical experience that a breast with ancient retraction of its nipple is prone to become the seat of a mammary abscess during lactation, and to chronic interstitial mastitis at all times.

Recent retraction is a frequent accompaniment of scirrhus carcinoma of the breast.

Therefore the all-important question to put to the patient is, "How long has this nipple been retracted ?"

Cracked Nipple.—Want of care in preparation for lactation and neglect of the hygiene of the nipple during lactation are the chief causes of this frequent condition. Its main importance lies in the fact that the crack is the forerunner of acute suppurative mastitis.

Prophylaxis.—During the last two months of pregnancy the nipples should be hardened by gently scrubbing them with a soft nail-brush (Sir Truby King), afterwards dabbing the nipple and areola with methylated spirit, which is allowed to evaporate. After suckling, the nipples should be washed and dried.

Treatment.—The mother should discontinue suckling at that breast until the fissure is healed, boracic dressings being applied. The breast must be emptied artificially at regular intervals.

Papilloma of the nipple presents the features of a cutaneous papilloma. It sometimes grows to a large size, but the pedicle is always narrow. The treatment is excision.

Retention Cyst of a Gland of Montgomery.—These glands, situated in the areola, secrete sebaceous material and, like sebaceous glands elsewhere, are liable to distention from their orifice becoming blocked.

Chancre of the Nipple.—Wet nurses are now seldom employed. In former days, when this calling was followed by a number of lactating women, infection from the mouth of a syphilitic child was fairly common. It should be noted that the mother of such an infant is immune to reinfection from her child. The majority of chancres of the nipple occur by infection from a buccal mucous patch in the mouth of a member of the opposite sex.

Eczema of the nipple is often bilateral, and presents features common to eczema elsewhere.

Paget's Disease of the Nipple must be distinguished from the foregoing. Paget's disease will be considered under the heading of "Carcinoma of the Breast."

Abnormal Discharges from the Nipple

A milky discharge can sometimes be expressed long after lactation has ceased. It can be associated with a galactocele, but this condition is very rare.

A clear serous discharge is associated usually with a retention cyst, consequent upon chronic interstitial mastitis.

A blood-stained discharge is pathognomonic of duct papilloma or duct carcinoma.

A black or green discharge may be due to altered blood from the foregoing, but is much more frequently an accompaniment of retention cysts of chronic interstitial mastitis. We have found that a dirty green discharge is usually due to polycystoma, and when the breast is removed it is found to be riddled with cysts containing the same material.

THE BREAST

CONGENITAL ABNORMALITIES OF THE BREAST

Amazia (fig. 586).—Congenital absence of the breast may occur on one or both sides. It is sometimes associated with an absence of the sternal portion of the pectoralis major. Amazia is more common in males.

FIG. 586.—Congenital absence of the left breast and the sternal portion of the pectoralis major.

Polymazia.—Accessory breasts have been recorded in axilla, groin, buttock, and the thigh. These have been known to function during lactation.

Gynæcomazia. — Hypertrophy of the male breast may be unilateral or bilateral. The breasts enlarge at puberty, and sometimes present the characteristics of a well-developed female organ. The subjects of this deformity are often virile—Chengwayo, chief of the Zulus (fig. 587), a gynæcomast, at the age of 55, had forty wives and over a hundred children. Tribal tales of a father nurturing his motherless infant with milk from his own breast belong to the realms of surgical mythology, but pseudo-lactation has been observed in a few rare instances, and a fluid akin to colostrum has been expressed and analysed by German observers.

FIG. 587.—Chengwayo, from a photograph by Schujelot.

The treatment of gynæcomazia should be excision of the breasts, for their possessor is subjected to ridicule.

Diffuse Hypertrophy of the Breasts

This appears sporadically in otherwise healthy girls at puberty, and, less often, during the first pregnancy. The breasts attain enormous dimensions, and may reach below the knees when the patient is sitting. Except in those cases occurring during pregnancy, where it is possible that the enlargement will subside at the conclusion of lactation, the breasts should be excised one at a time, for their deformity and weight are a real handicap to the patient.

Injuries of the Breast

Injuries of the breast are rare and comparatively unimportant.

Hæmatoma, particularly a resolving hæmatoma, gives rise to a lump which, in the absence of overlying bruising, is difficult, if not impossible, to diagnose correctly until an exploratory incision has been made.

Milk fistula can follow an incised wound of a lactating breast or an operative incision. It usually heals spontaneously.

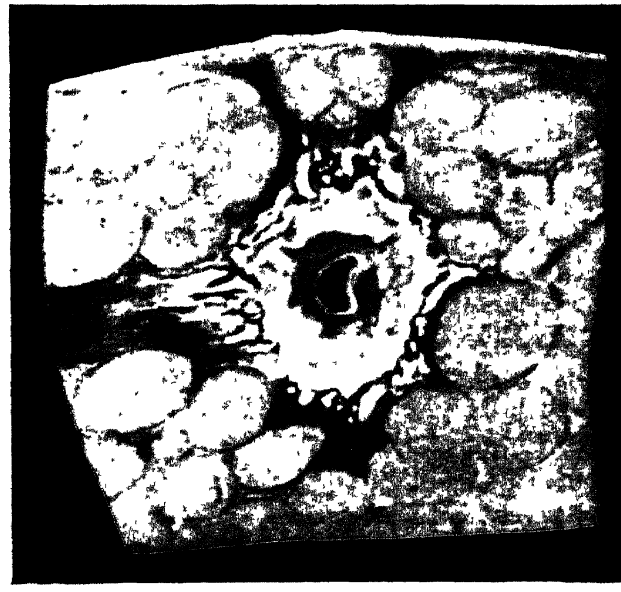

Fig. 588.—Fat necrosis of breast. (G. Hadfield.)

Traumatic fat necrosis is an interesting condition which in recent years has received detailed attention. Following a blow or the administration of subcutaneous saline into the breast, a lump appears. In the absence of a definite lead, the lump is usually diagnosed as a carcinoma. A recent history of injury, especially that inflicted by subcutaneous

saline solution, should put the clinician on his guard. On incising the mass the macroscopic picture is fairly characteristic (fig. 588). The chalky white area of necrotic fat is akin to the areas of fat necrosis seen in acute pancreatitis.

Acute and Subacute Inflammations of the Breast

Mastitis of infants is at least as common in the male as in the female. Its ætiology is closely related to the lactation of infants. On the third or fourth day of life, if a mamma of an infant is pressed lightly, a drop of colourless fluid can be expressed ; a few days later there is often a slight milky secretion, which finally disappears in the third week. This is popularly known as "witch's milk."

The cause of mastitis of infants is not the ignorant maternity nurse "breaking the nipple strings," for it occurs in babies born in hospital. Furthermore, the misguided midwife presumably limits her activities to the female infant's breast ; and all who deal with the new-born appear to be agreed that mastitis of infants is, if anything, commoner in the male. Thus the midwife is exonerated. An ingenious explanation of this phenomenon is that the hormone which stimulates the mother's breast reacts also upon the newly formed mammary tissue of the fœtus. The infant with secreting-breasts is liable to the same danger of a retrograde bacterial infection as its mother.

Mastitis of infants is essentially a physiological activity. It may lead to a true mastitis by retrograde infection. This true mastitis usually resolves ; occasionally it suppurates.

Mastitis of puberty is encountered frequently, usually in males. The boy, aged about 14, complains of pain and swelling in the breast. In 80 per cent. the condition is mainly or entirely unilateral. On examination the breast is enlarged, tender, and slightly indurated. The treatment is expectant. Suppuration never occurs. The symptoms usually disappear in fourteen days or less, but induration often persists for several weeks.

Mastitis from local irritation is now less common in women since high corsets strengthened with whalebone have been out of fashion, but it may be produced from a too tight elastic brassière. Mastitis from local irritation is by no means rare in men, and in this instance can usually be traced to the loss of a trouser button, which is compensated by

hitching the braces buckle to a higher level (fig. 589). The treatment is to remove the cause. The substitution of a belt for braces is sound advice.

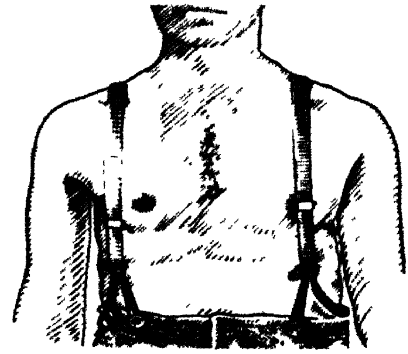

FIG. 589. - A frequent cause of mastitis in the male.

Mastitis from milk engorgement is liable to occur about weaning time, and it is sometimes confined to one portion of a breast. Unless the engorgement is relieved with a breast pump, an ascending bacterial infection may take place, the stagnant milk being a good medium for bacterial growth.

Mastitis of lactation is the commonest of all the acute inflammations of the breast, and in contradistinction to the others, it usually goes on to suppuration. The sufferer is often in the *first* month of her *first* lactation. Infection occurs in one of two ways: (1) Staphylococci enter the lactiferous ducts and cause clotting of the milk. Within the clot these organisms multiply, and the acini, severed by the obstructed duct, become the seat of a lively inflammation. (2) Streptococci enter through a crack or abrasion of the nipple, and inflammation proceeds apace in the interglandular tissues. Unless it is arrested, the infection spreads to the glandular mechanism. Even upon the closest examination it is rare to find any evidence of a cracked nipple. Clinical and bacteriological investigations leave little doubt that the first is by far the commonest cause of mastitis of lactation.

FIG. 590.—A simple form of breast pump.

The affected breast presents the classical signs of acute inflammation.

Treatment.—The patient should be confined to bed. If she is feeding her child, it must be weaned and the breasts emptied by a breast pump. The secretion of milk is minimised by giving saline aperients and atropine. Large magnesium sulphate fomentations are applied locally. The

breast is examined daily. In a very few cases under this treatment resolution will occur. In the majority tenderness and induration become confined to one quarter or, at the most, half the breast. An acute mammary abscess has formed.

Acute Mammary Abscess

Most abscesses of the breast are of the intramammary variety (fig. 591), and it is lactating women who are usually sufferers.

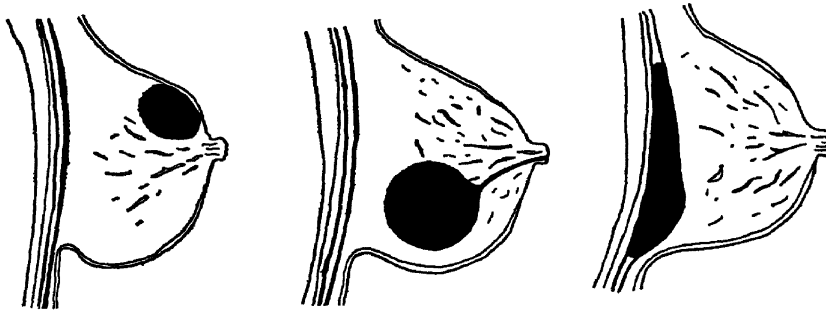

Subcutaneous. Intramammary. Retromammary.

Fig. 591.—Varieties of breast abscess.

Treatment.—An abscess of the breast must be drained. It is seldom wise to consider incision until some localisation of the inflammation has occurred. The classical method of draining a breast abscess is through an incision or incisions radiating from the nipple. The "**closed**" **method** of treatment offers many advantages.

Technique.—Under gas anæsthesia a single incision three-quarters of an inch in length is made at the most dependent portion of the indurated area. The finger is inserted and loculi of the abscess cavity are broken down. Drainage tubes and dressings are then arranged as shown in fig. 593.

After-treatment.—Every four hours the measured quantity of Dakin's solution is injected down the tube. The dressing is not disturbed for twenty-four hours. The overflow is automatically absorbed into the fluffed gauze (fig. 592). At the end of that time the many-tailed bandage is loosened and the fluffed gauze is changed. Providing the temperature chart is satisfactory, and the patient does not complain of discomfort, the inner dressing of vaseline gauze and the tubes are not touched. This labour-saving, pain-sparing regime is followed until the fourth or fifth day, when the dressings and tubes are removed.

From thenceforth the abscess cavity is washed out by means of a rubber catheter once or twice a day, gradually diluting the solution with saline day by day, until the wound granulates.

Chronic Abscess of the Breast.—Chronic abscess of the breast is often a very difficult condition to diagnose. *It*

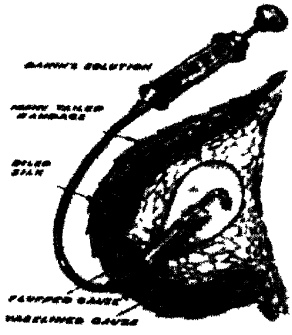

FIG. 592.—Diagram depicting the technique of closed drainage described in the text. The amount of Dakin's solution to fill the abscess cavity has been ascertained at the time of the operation. This quantity is injected down the small tube every four hours. The overflow runs out of the large tube and is absorbed by the gauze. The layer of vaselined gauze protects the skin from the irritating effect of the fluid.



FIG. 593.—Method of applying the overall many-tailed bandage, and of fixing the end of the irrigating tube when not in use. In practice the free end of the tube is wrapped up in a piece of gauze moist with Dakin's solution.

simulates in many respects a carcinoma of the organ. Exploratory incision is often the only means of determining this all-important differential diagnosis.

Retromammary Abscess.—Here the pus is situated in the cellular tissues behind the breast, and in practically all cases it has nothing to do with the breast proper. It arises from a tuberculous rib, or possibly a chronic empyema necessitans, and the treatment is that for those conditions, the breast being retracted as necessary from the field of operation.

Submammary Intertrigo.—On lifting up large, pendulous breasts in fat women it is not uncommon to find patches of intertrigo on the abutting skin edges of the breast and the chest wall.

Tuberculosis of the Breast.—Tuberculosis of the breast is com-

paratively rare. It may be associated with other tuberculous lesions. It usually takes the form of multiple chronic abscesses. The diagnosis rests on bacteriological and microscopical examinations. The treatment is amputation of the breast.

Syphilis of the Breast.—A primary chancre of the nipple has been referred to on p. 673. Secondary lesions of syphilis in the form of mucous patches are sometimes found in the submammary folds. In the secondary stage also both breasts may become swollen and painful, the condition being known as diffuse syphilitic mastitis. Gumma of the breast is very rare, and almost impossible to diagnose unless there is a lead in the shape of other evidences of syphilis.

Cysts of the Breast

Cysts of the breast are usually secondary to blockage of the secretory mechanism, either by fibrosis from without the lumen or obstruction from within. Primary cysts of the breast rarely occur.

Classification of Cystic Swellings of the Breast

1. **Polycystoma.** — The breast is riddled with cysts (fig. 594); one may be large and the others insignificant. The condition is frequently an accompaniment of chronic interstitial mastitis. Less often one sector of the breast is affected alone, when blockage of one main duct near the nipple by a duct papilloma should be suspected.

Fig. 594.—Chronic interstitial mastitis with cysts. The largest cyst contains an intracystic carcinoma. (R.C.S. 1236.1.)

2. **Cystadenoma** (sero-cystic disease of Brodie) (p. 684).
3. **Intracystic Papilliferous Carcinoma** (p. 690).
4. **Colloid Carcinoma** (p. 686).
5. **Chronic Abscess** (p. 679).
6. **Lymph Cyst.**
7. **Hydatid Cyst.**
8. **Hæmatoma** (p. 675).
9. **Galactocele.**—Galactoceles are usually single, and always date from lactation. They contain milk or cream, and in long-standing cases the walls tend to calcify.

Probably 75 per cent. of mammary cysts belong to group 1. Transillumination and aspiration are very helpful in differential diagnosis.

Mastodynia

Slight discomfort in the breasts is not unusual in the premenstrual phase. When such discomfort amounts to pain it is termed mastodynia. On palpation the breasts appear normal, but they are tender. Mastodynia is sometimes associated with neurasthenia. Quite often it is a genuine condition due to overactivity of the corpus luteum. It has been shown that the condition is improved by the exhibition of *ovarian residue*, that is, the residue of fresh ovaries of the hog or cow after removal of the corpus luteum. Five-grain tablets once a day is the usual dose (Max Cutler).

Chronic Interstitial Mastitis

The term "chronic interstitial mastitis" is deep-rooted in British medical nomenclature, but the term is essentially erroneous. The condition is not a chronic inflammation. The modern conception is that it is due to an aberration of those physiological changes which occur in the mammary tissue at puberty and the menopause. Headed by Sir Lenthal Cheatle, who recommends that the condition should be called "mazoplasia," efforts are being made to abandon the old term, but we fear, on the grounds of possible confusion, that the time is not yet ripe for the change.

Clinical Features.—Chronic interstitial mastitis may be seen at any age after puberty, but the majority of patients present themselves about the time of the menopause. It is found more often in breasts which have not performed their intended function, that is, in those of spinsters, childless married women, and fruitful married women who have not suckled their children. The patient usually complains of pain in *one* breast, worse about the time of menstruation, or after using the arm. On examination both breasts are inclined to be what may be described as "lumpy." The breast complained of, when examined between finger and thumb, may contain a definite lump, but this is only felt vaguely with the flat of the hand. The lump is not adherent to the pectoral fascia nor to the skin. There is no retraction of the nipple, but on rare occasions there is a serous or

dark-green discharge therefrom. A cyst, or cysts, may complicate or obscure the clinical picture. The axillary glands are frequently enlarged and often tender.

Pathology.—When sectioned with the knife the affected areas in the breast are white or yellow, but they never present those grey tones of carcinoma. Cysts of varying sizes filled with dark mucoid material are often to be seen in long-standing cases. Microscopically it will be found that the interstitial tissues are swollen, and there is a round-celled infiltration. Fat and elastic tissues have largely disappeared. Later the interstitium is replaced by dense white fibrous trabeculæ. It is this fibrous tissue which strangulates the ducts, thus favouring cyst formation.

Relationship to Carcinoma.—Chronic interstitial mastitis is definitely a precarcinomatous condition, but this does not imply that all, or even many, cases of chronic interstitial mastitis eventually become carcinomatous. We have found Professor Turnbull's tabular representation showing the merging of one condition into the other very helpful in understanding their relationship.

Chronic Interstitial mastitis
(an aberration of evolution or involution of the mammary tissue).
↓
Adenomatous hyperplasia.
↓
Carcinomatous hyperplasia.
↓
Carcinomatous infiltration.

Treatment.—In early cases without cyst formation and where the possibility of carcinoma does not arise, strapping the breast (fig. 595), and giving iodine or iodides by mouth, often relieve symptoms, and in a certain number of cases the nodules disappear. This treatment should be continued for a month or six weeks, the patient being examined at fortnightly intervals. If there is no improvement, operation is recommended. A satisfactory method of removing the mammary gland in these cases is through a submammary

incision. The breast, including its axillary tail, is dissected out, leaving the skin and nipple intact. After the mammary gland has been excised, a purse-string suture on the under-surface of the areola ensures the nipple being everted. This operation, which is known as Gaillard Thomas's, gives a very good cosmetic result, especially in thin women (fig. 596). In the obese, a fat graft may be used to fill the cavity left by the mammary gland.

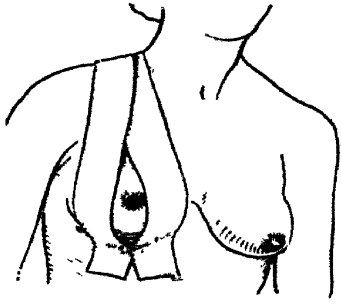

FIG. 595.—A method of supporting the breast by adhesive strapping.

When the Diagnosis of Carcinoma is in Doubt.—There will always be cases where the clinician cannot be sure whether a particular lump in the breast is a patch of chronic interstitial mastitis or an early carcinoma, and this is not surprising, since one condition merges into the other (p. 686). In these cases it is wise to advocate operative treatment without delay. The first step of such an operation is to incise that part of the breast containing the lump, and to look at the cut surface.[1] In many cases a glance will suffice to indicate the nature of the tumour. *If it is chronic mastitis* a local removal of the breast is indicated. *If it is carcinoma*, the incision is closed, gloves and instruments are changed,

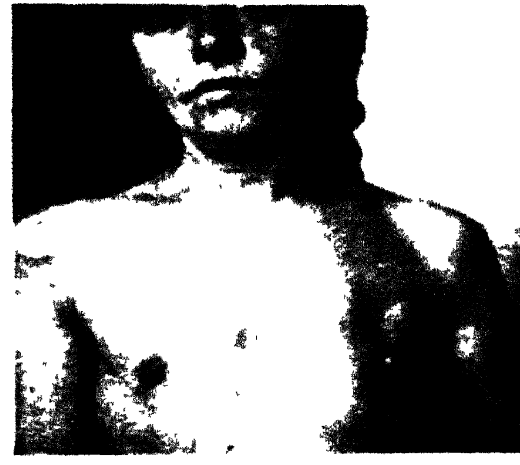

FIG. 596.—Result of submammary excision of both breasts for chronic interstitial mastitis.

[1] Some surgeons advocate local amputation of the breast and then incising the specimen. By following the method detailed in the text we are spared the possible mortification of amputating a breast containing a chronic abscess.

and the operator proceeds to do the complete removal of the breast.

There still remain a small number of instances in which, by looking at the cut surface of the tumour, we are still in doubt as to its nature. A few institutions in the world have facilities for immediate histological diagnosis by frozen section. Where these facilities do not exist, the surgeon should proceed to treat the case as one of carcinoma.

Benign Neoplasms of the Breast

Benign tumours constitute a comparatively small proportion of neoplasms of the breast.

Duct papilloma of the breast presents symptoms identical with duct carcinoma, and it is impossible to differentiate between the two conditions before the breast has been removed.

Fibroadenoma of the breast is divided clinically into two varieties, the hard and the soft.

Hard fibroadenoma is again redivided from the histological standpoint into *pericanalicular* fibroadenoma, which is rare, and *intracanalicular* fibroadenoma, which is common.

Clinical Features.—The patient is usually between the ages of 14 and 30, and she complains of a lump in the breast. Occasionally there is more than one of these neoplasms present. On examination the lump is smooth, hard, and quite freely movable. The treatment is excision. This is very simple and satisfactory, because the fibroadenoma is encapsulated, and can be shelled out.

Soft fibroadenoma again is a definitely localised tumour. It feels to the examining fingers about the consistency of a lipoma. It is much rarer than the foregoing, occurs in women about the age of 35 or 40, and is more difficult to diagnose. These tumours usually lie deeply in the breast, and are best excised through a submammary incision. Again they have a definite capsule. Soft fibroadenomata are inclined to be bilateral.

Cyst Adenoma (*syn.* Sero-cystic Disease of Brodie) (fig. 597).—This very rare affection was first described by Sir Benjamin Brodie in 1844. It constitutes one of the

FIG. 597.—Sero-cystic disease of Brodie. (W. E. Tanner.)

massive tumours of the breast. The cysts are filled with fibro-papillomatous proliferations. The base of the tumour tends to become sarcomatous. Excision of the breast is usually accompanied by an excellent prognosis.

MASSIVE TUMOURS OF THE BREAST

This will be a convenient point at which to tabulate the massive tumours of the breast. They are :

1. Diffuse hypertrophy, which is usually bilateral.
2. Sero-cystic Disease of Brodie.
3. Sarcoma.
4. Colloid carcinoma.

Each of these is considered in its appropriate section.

CARCINOMA OF THE BREAST

The breast is one of the most frequent sites for cancer, and, in its early stages, one of the most favourable to treat. Unfortunately, so often the patient states that whilst washing she noticed a lump in her breast, but "took no notice of it because it was painless." Women should be urged to report to their doctors as soon as a lump in the breast is discovered. There is no known cause of mammary cancer, but it can be stated with assurance that chronic

interstitial mastitis is sometimes its precursor. It is most improbable that injury plays any part in the production of the condition.

Only 1·5 per cent. of all cases of carcinoma of the breast occur in males. Women between 40 and 50 years of age who have suckled children are its most frequent victims, but the disease is not rare in spinsters. Cancer very rarely attacks both breasts simultaneously.

Clinical Classification of the Varieties of Carcinoma of the Breast

(*a*) *From the alveoli*, and histologically a spheroidal-celled carcinoma :

Malignancy ↓		
Colloid carcinoma	approx.	1 per cent.
Atrophic scirrhus	approx.	5 per cent.
Scirrhus	approx.	60 per cent.
Encephaloid	approx.	16 per cent.
Mastitis carcinomatosis	approx.	2 per cent.

(*b*) *From the ducts*, and histologically a columnar-celled carcinoma :

Duct carcinoma	approx.	8 per cent.
Intracystic papilliferous	approx.	2 per cent.

(*c*) *Commencing in the skin of the nipple* and histologically (probably) a basal-celled carcinoma :

Paget's disease of the nipple	approx.	5 per cent.

Colloid carcinoma is the rarest form of carcinoma in group (*a*) It occurs in patients about the same age as in the scirrhus variety. Tumours undergoing this gelatinous degeneration sometimes reach an enormous size, and translucent areas can be seen by transillumination. Contrary to what one might expect, the prognosis after operation, according to statistics issued by the Ministry of Health, is exceptionally favourable, 100 per cent. being alive and well after three years in many of the series.

Atrophic scirrhus carcinoma is distinctly uncommon. It is seen principally in aged, thin women with small breasts. The cellular element of the growth is comparatively small, its main constituent being the fibrous stroma. Although steadily progressive, the disease runs a very chronic course,

perhaps taking ten years to ulcerate through the skin, when it is inclined to grow somewhat more rapidly. It is this type of carcinoma which is usually found in the male breast (fig. 598).

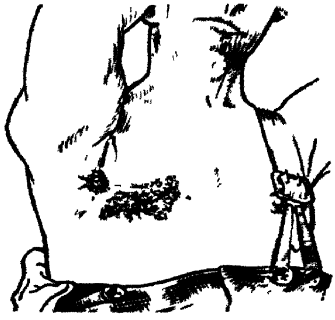

FIG. 598. — Atrophic carcinoma of the male breast of eight and a half years' standing.

Scirrhus carcinoma is the leading type of mammary cancer. While it may commence in any portion of the breast, the upper and outer quadrant is the site of election. Owing to an abundance of fibrous tissue the lump feels very hard, while its contour tends to be irregular. In its early stages it can be moved freely upon the underlying structure, and the skin can be made to move over it. Later it becomes tethered to the skin (fig. 599), or to the pectoralis major, or to both. The importance of recent retraction of the nipple has been alluded to already (p. 672). *Peau d'orange* of the skin overlying the tumour (fig. 600) is another important sign. Both these manifestations are comparatively late. The axillary lymphatic glands are not palpable in the early stages, but they are microscopically invaded long before they can be felt.

Untreated, eventually the growth ulcerates through the skin (fig. 601), and it may invade the thorax, while dissemination via the lymphatic and blood-streams finally determines the fatal issue.

FIG. 599. — Carcinoma of the breast. Note the elevation of the affected breast and the retraction of the nipple.



FIG. 600.—Early peau d'orange is made more obvious by pinching up the skin as shown.

Two to two and a half years from the time the lump was first noticed is the average duration of life.

If a breast containing a scirrhus carcinoma is cut with a knife so as to section the tumour, the following features will be noticed:

MACROSCOPICAL CHARACTERS

1. The growth cuts like a potato, and may creak whilst being cut.

2. Usually *both* cut surfaces are found to be concave.

3. The colour of the cut surface is definitely grey, and its constitution has been aptly likened to the interior of an unripe pear. Here and there will be seen a yellow spot, which is an island of fat undergoing degeneration.

4. On viewing the periphery of the sectioned tumour it will be found that there is not the slightest indication of a capsule. True to its namesake, the crab, its claws have penetrated hither and thither into the breast tissue, and it is impossible to separate the tumour from the breast.

5. Expression of opaque cancer juice

FIG. 601.—Scirrhus carcinoma of the breast invading the skin.

from the cut surface, dear to the old-time demonstrators of morbid anatomy, is no longer regarded as a characteristic feature of carcinoma.

Encephaloid Carcinoma.—This is usually found in women between 25 and 35 years of age with well-developed breasts. While presenting many characteristics of the foregoing variety, the epithelial element of the growth is in excess of its fibrous stroma. As a consequence the tumour does

FIG. 602.—Mastitis carcinomatosis. (Hirst.)

not feel so hard, and in advanced cases it may present semi-solid areas due to degeneration of masses of ill-nourished cells. This variety of carcinoma is not so intensely malignant as one is often led to believe. Statistics from all clinics show that the survival rate after operation is very little worse, or even a little better, than those of scirrhus carcinoma. Perhaps the relatively large size and rapid growth of the tumour impel the patient to seek relief earlier than in the case of scirrhus carcinoma.

Mastitis carcinomatosis (fig. 602) occurs in the lactating breast and, it was stated by the astute clinicians of former days, always in women of a florid aspect. Possibly a carcinoma was present during the latter part of pregnancy, but

it is fired into extreme activity by the increased metabolism of its immediate host—the breast. It will be appreciated that the parasitic cells will take full advantage of the plentiful blood-supply destined for the milk-forming mechanism, and the result is an unbridled proliferation of cancer cells with very little fibrous reaction. This galloping form of mammary cancer often presents all the signs of acute inflammation, and is sometimes mistaken for, and incised as, an abscess. The great distinguishing feature between the two conditions is the massive œdema which accompanies mastitis carcinomatosis. This type of mammary cancer, in spite of every effort to stay the course of the disease, usually ends fatally within a few months.

Duct Carcinoma.—It is difficult, if not impossible, to tell from a clinical examination where a duct papilloma ends and a duct carcinoma begins. The leading symptom in both conditions is a blood-stained discharge from the nipple. A lump may be palpable behind the nipple or areola, and emerging from this there is usually a sector-shaped area of induration, viz. . Patently, the cause of the latter is distention of those alveoli drained by that duct which is blocked by the growth. On bisecting a breast containing a duct carcinoma, we have several times been able to trace the original stalk of the growth arising in one of the larger ducts behind the nipple. From this stalk delicate tendrils like fine seaweed could be traced along smaller ducts, the latter and their corresponding alveoli being dilated into fine spongework by the growth and a blood-stained serous exudate. Histologically the carcinoma is columnar-celled. According to Lockwood, this variety is "not less malignant than the other varieties of carcinoma," but as the lymphatic glands are involved somewhat late in the course of the disease, and as it gives rise to alarming symptoms (bloody discharge from the nipple), which compels the patient to seek advice early, the prognosis after complete removal of the breast is usually good.

Intracystic Papilliferous Carcinoma (*syn.* Disease of Réclus).—It is usually impossible to differentiate this

condition from a simple cyst until its interior has been displayed. Within the cyst there is a cauliflower growth (fig. 603). The prognosis after early operation is distinctly good.

FIG. 603.—Intracystic papilliferous carcinoma.

Paget's Disease of the Nipple.—This condition commences about the menopause. The nipple is slowly eroded and eventually disappears. As the disease progresses the areola is involved (fig. 604), and the erosion continues to spread superficially for about two years, when definite signs of a malignant tumour within the breast become manifest.

Differential Diagnosis

Eczema.	Paget's Disease.
Bilateral.	Always unilateral.
Lactation.	Menopause.
Vesicles.	None.
Always itches.	Sometimes itches.

FIG. 604.—Paget's disease of the nipple.

Theories of Causation.—Ever since Sir James Paget first described the condition in 1874, its exact nature has been the subject of dispute. Many of the older theories have been entirely discarded. At the present time there are three hypotheses of Paget's disease of the nipple.

1. That there is a carcinoma in the breast from the commencement, and the local dermatitis is due to overlying lymphatic œdema. (Sampson Handley.)
2. That Paget's disease of the nipple is a primary carcinoma commencing in the duct outlets of the nipple, possibly induced by irritation of débris plugging those outlets. The underlying carcinoma of the breast which appears ultimately can occur (*a*) by direct spread down the ducts, (*b*) from detached carcinoma cells from the nipple being grafted into the breast, or (*c*) by the agents of irritation which caused carcinoma in the nipple acting also on the epithelial cells of the breast. (Sir Lenthal Cheatle.)
3. That the local condition is a basal-celled carcinoma of the skin of the nipple. (Turnbull, Leitch.)

Treatment should be radical removal, which, if performed before there is a palpable lump in the breast, is accompanied by an excellent prognosis.

PHENOMENA RESULTING FROM LYMPHATIC OBSTRUCTION OF MAMMARY CARCINOMA

Peau d'orange is due to cutaneous lymphatic œdema. Where the infiltrated skin is transfixed by the sweat ducts it cannot swell. The characteristic pitted appearance, so well likened to orange peel by French observers, has become a classical physical sign of carcinoma of the breast. But it should be noted carefully that the same picture is occasionally seen over an abscess, particularly a chronic abscess, of the breast.

Brawny arm (fig. 605) is a distressing complication. It can be due to blocking of the axillary lymphatic vessels, as was the case in the instance illustrated, or it can follow removal of the axillary glands. In post-operative cases damage to the cephalic or axillary vein may be a contributory cause. Halstead maintained that early post-operative brawny arm is usually due to sepsis.

Treatment is highly unsatisfactory. Lymphangioplasty (p. 91) is recommended by Sampson Handley. We have also tried Kondoléon's operation for elephantiasis in two instances, but the results were disheartening.

FIG. 605.—Brawny arm. There is a massive, untreated carcinoma of the breast.

Serous effusion into the peritoneal or pleural cavities is not frequent, and may be classed as one of the terminal events in hopeless cases.

While not entirely a phenomenon of lymphatic obstruction, this is a convenient place to mention a rare complication of carcinoma of the breast which is constantly in the mouth of the student, for no better reason than that it has a fascinating name. We refer to "cancer en cuirasse." Here one side of the thoracic wall is studded with carcinomatous nodules, and the skin is so infiltrated that it has been likened to a coat of armour. The condition appears usually, but not necessarily, in cases with local recurrence after amputation of the breast. It is fortunately rare, and when seen the end is not far distant. It in no way merits that prominent position in the professional mind which it has so long enjoyed.

The Spread of Mammary Carcinoma

(*a*) **Local Spread.**—The tumour increases in size, and invades other portions of the breast. It tends to involve the skin, and to penetrate the pectoral muscle, and even the chest wall.

(*b*) **Lymphatic spread** occurs in two ways: *by emboli*, composed of carcinoma cells being swept along the lymphatic vessels by the lymphatic stream; and *by permeation*, that is, actual growth of columns of cancer cells along the lumen of the lymphatic channels. By these means the axillary lymphatic glands are involved. This occurs early. Later the supraclavicular glands, the mediastinum, and the sheath of the rectus abdominis are all possible stations for carcinoma cells journeying by this route. Finally, they may be found in glands even farther afield.

(*c*) **Spread by the Blood-stream.**—It is by this route that bones become invaded (fig. 606). In most instances it is also by way of the blood-stream that metastases arrive in the liver from the breast. It cannot be denied, however, that secondary deposits may also be carried to the liver via the lymphatics in the rectus sheath and the round ligament.



Fig. 606.—Extensive deposits of secondary carcinoma in the femur. The primary was in the right breast A spontaneous fracture occurred and united.

Complete Amputation of the Breast

So far the best results in carcinoma of the breast have followed wide removal of the mammary gland, together with the structures which are likely to be infiltrated by carcinoma cells. The breast and associated structures are dissected *en bloc*, and the mass excised is composed of:

1. The whole breast.
2. A large portion of skin, the centre of which overlies the tumour, but always includes the nipple.

3. The fat and fascia from the lower border of the clavicle to, and including, the upper quarter of the sheath of the rectus abdominis, and from the manubrium to the free edge of the latissimus dorsi.

4. The pectoralis major and its fascial sheath (its clavicular head is sometimes left).

5. The pectoralis minor and its fascial sheath.

6. The costocoracoid membrane.

7. All the fat, fascia, and lymphatic glands of the axilla.

8. The fascia over, and a few of the more superficial muscle fibres of, the anterior part of the serratus magnus, the subscapularis, the latissimus dorsi (except its posterior surface), and the upper third of the rectus abdominis.

9. Sometimes the supraclavicular fat and fascia have to be removed in addition.

During the operation no effort should be spared to preserve:

1. The axillary vein.
2. The cephalic vein.
3. The nerve of Bell.

(4. The middle or long subscapular nerve should be retained if possible.)

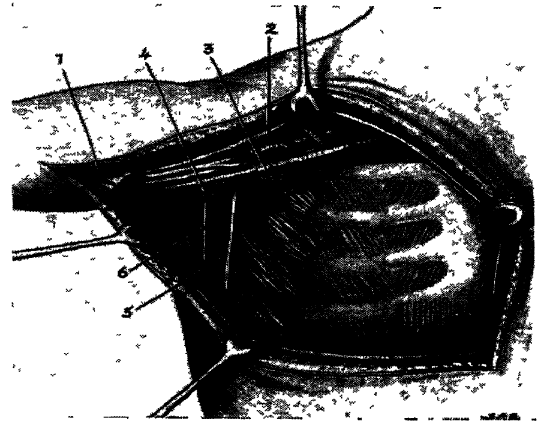

FIG. 607.—The field of operation after radical removal of the breast.

1. Divided sternal portion of pectoralis major muscle.
2. Divided pectoralis minor muscle at its insertion into the coracoid process.
3. Thoracic axis vessels.
4. Subscapular vessels.
5. Nerve of Bell lying on the serratus muscle.
6. Middle or long subscapular nerve.

During the operation the exposed chest wall must be protected by towels wrung out in hot saline. At the completion of the operation the wound is drained in order to prevent blood accumulating. If a wide area of skin has been sacrificed, it may not be possible to approximate completely the skin edges. A deficiency is left, which is later treated by skin grafting. After operation the arm is supported upon a pillow until the wound has healed, and later carried in a

sling until convalescence is complete. The movements of the arm after so extensive a loss of muscle are surprisingly good (fig. 608).

A course of prophylactic X-ray treatment is a valuable aid in prevention of recurrence, and where facilities exist this should be recommended.

FIG. 608.—Showing movements of arm after a radical removal of the breast.

Results.—The results of operation in carcinoma of the breast are good if the operation has been performed thoroughly. Based on a three years' freedom from recurrence, the number of cures after radical removal was over 80 per cent. *in those cases which had no palpable axillary glands* (Harrington, Mayo Clinic). When the axillary glands are palpable, the number of cures falls to half, or less.

From various sources it is computed that the average time between the patient finding the lump and reporting it is eighteen months. If this time factor could be reduced, the total number of cures would be increased proportionately.

THE RÔLE OF RADIUM IN THE TREATMENT OF MAMMARY CARCINOMA

Radium is advocated by all in inoperable and recurrent cases. A few surgeons prefer radium to radical operation, but after a wave of enthusiasm in 1928 their numbers are declining. At the time of writing operation, or operation plus radium, is in vogue throughout the world for the treatment of comparatively early mammary cancer.

Principles of Radium Treatment in Carcinoma of the Breast.—Into the growth itself small needles (·5 mg.) are placed about half an inch apart. Around the periphery of the growth two rows of larger needles are inserted. Larger needles (1·5 mg.) are also inserted into the four upper intercostal spaces along the anterior, middle, and posterior axillary lines, into the roof of the axilla, under and above the clavicle, and over the upper part of the sheath of the rectus. About forty or sixty needles are necessary to construct this barrage, which, it will be noted, follows essentially the same surface outline as that of the complete removal of the breast. The needles are left in from seven to nine days. After inflammation has subsided completely, that is, in about three weeks to a month, a surface application of radium or a course of deep X-ray therapy is advised.

Sarcoma of the Breast

Sarcoma of the breast is usually of the spindle-celled variety. It is difficult to diagnose from encephaloid carcinoma, but its growth is more rapid, and it is even softer than the latter. On incising the growth, its friable, pale consistency at once makes its nature clear. The condition is rare, and it is most often met with in women between the ages of 30 and 40. Metastases occur early, and usually determine a fatal issue in a comparatively short time. Even when the breast has been completely removed at an early stage in the disease, the prognosis is almost hopeless.

CHAPTER XXXII

THE THORAX

INJURY TO THE LUNGS AND PLEURA

NON-PENETRATING

Compression of the chest (*syn.* Traumatic asphyxia) occasionally follows such accidents as mining disasters or panics. The flow of blood in the intrathoracic veins is obstructed, or the direction of the blood-stream may even be reversed. The veins of the head, neck, and arms become acutely engorged and capillaries rupture, so that the parts are dusky or purple in colour, owing to extravasated blood. Subconjunctival and submucous hæmorrhages also occur. Treatment is symptomatic, and blood is absorbed in two or three weeks.

Contusion of the pleura results in dry pleurisy, and consequent pain on deep inspiration. If the lung also is contused, local extravasation occurs, causing a patch of consolidation. Hæmoptysis varies with the severity of the injury. Uneventful recovery is the rule, but the risk of infection must be borne in mind.

Laceration of the lung is usually associated with fracture of one or more ribs; but in some cases, especially in children, serious pulmonary injury is possible without fracture of the bony framework.

The immediate dangers are shock, severe hæmoptysis, or asphyxia following aspiration of blood. Subsequently the following conditions may develop.

Hæmothorax—which is accompanied by dyspnœa. The physical signs resemble those of a pleural effusion, and a rise of temperature is usual, as in any condition in which blood is extravasated. The bleeding tends to diminish as the lung collapses.

Pneumothorax—which yields a high-pitched note on percussion. Pneumothorax is usually associated with hæmothorax, and therefore adds to the dyspnœa, but at the same time assists in arresting hæmorrhage by exerting pressure on the bleeding lung.

Surgical emphysema is likely to occur if both the parietal

and visceral layers of pleura are torn. The condition sometimes spreads widely. Affected tissues yield a crackling sensation on palpation, akin to that experienced when handling tissue-paper. The air is absorbed uneventfully in a few days.

Empyema—infection of a hæmothorax—is always a possible danger, especially if bronchitis is latent or actually present.

Treatment.—Morphia must be given without delay, in order to relieve pain, combat shock, and discourage bleeding. The patient is kept at rest, and an ice-bag applied over the supposed site of injury. Needling should be performed if hæmothorax is suspected. The question then arises, Is hæmorrhage from the lacerated lung continuing ? Periodic estimation of the blood-pressure must be taken, and if a steady fall is occurring thoracotomy is indicated, so that the patient's life may be saved by direct arrest of the hæmorrhage. In most patients who survive the initial dangers, the bleeding ceases spontaneously, and the hæmothorax remains. In order to obviate the risk of infection, and discourage the subsequent formation of adhesions and thickening of the pleura, aspiration of the hæmothorax should be performed about the third or fourth day. The risk of recurrence of bleeding from the lung is obviated by oxygen replacement, so that negative pressure in the pleura is therefore avoided.

Careful attention to oral and dental hygiene will reduce the likelihood of empyema.

Penetrating

Puncture of the lung is likely to follow any penetrating wound of the chest, such as stab or gunshot wounds. A considerable degree of shock follows, and hæmoptysis indicates the pulmonary injury. If a large opening is made through the chest wall the negative pressure in the pleural cavity disappears, and the lung collapses. Inspiratory efforts draw the mediastinum towards the uninjured side, which further embarrasses respiration by compressing the active lung. During expiration the mediastinum is pushed across to the injured side and so to-and-fro movements or "flapping" result.

Dyspnœa, engorgement of veins of the neck, and increasing embarrassment of the heart are the obvious features of an open pneumothorax. Shock, cardiac failure, and hæmorrhage are the early dangers, and if the patient survives, some degree of infection is almost inevitable. The treatment of a penetrating wound depends upon the urgency of symptoms. In the case of an extensive wound the immediate necessity is to arrest any obvious hæmorrhage, and temporarily to pack the aperture with an aseptic pad. Morphia is given as soon as possible. If time and circumstances permit, the parietes should be approximated with a few stitches. Mediastinal flutter is thus controlled, and a short interval is allowed for resuscitative measures. Under intratracheal anæsthesia the superficial wound is excised, and clots and any foreign bodies are removed from the pleural cavity. Lacerated portions of tissue are excised, and the adjacent structures, such as the pericardium and diaphragm, are examined. The wound is closed without drainage, and treatment is conducted as for a subcutaneous injury.

Hernia of the lung (*syn.* pneumocele) occurs either spontaneously, or as a result of severe damage to the chest wall. In the former case Sibson's fascia yields, and a soft swelling appears behind the clavicle, which is readily compressible, but enlarges on coughing. A pad with suitable straps should be applied if the swelling causes discomfort or increases in size.

INFECTIONS OF THE LUNG AND PLEURA

Acute Empyema

Causes.—As with pus in any situation, empyema arises as a result of :

(*a*) Direct infection, as by penetrating wounds.

(*b*) Extension from neighbouring foci of infection, particularly pneumonic and subphrenic.

(*c*) Hæmatogenous infection.

Clinical features are those of a pleural effusion combined with toxæmia. The three cardinal signs of fluid in the chest are diminished movement, a dull percussion note, and displacement of viscera, especially the heart (fig. 609). Breath-sounds are usually inaudible, but are sometimes bronchial, especially in children.

Occasionally empyemata are localised or situated between the lobes, in which case X-ray is a valuable help in diagnosis. If untreated, and the patient survives for a sufficient length of time, the pus may erode a bronchus and be expectorated, or point through the chest wall, usually along one of the perforating branches of the internal mammary vessels (empyema necessitatis).

Needling the chest is always necessary both to confirm diagnosis, and also to allow bacteriological examination of fluid. The skin and deep structures are infiltrated with 1 per cent. novocaine, which not only anæsthetises but also prevents pleural reflex. A fine needle is used, which is pushed into the pleural cavity. If no fluid is withdrawn, a large needle should be substituted, which is less likely to become obstructed by fibrin.

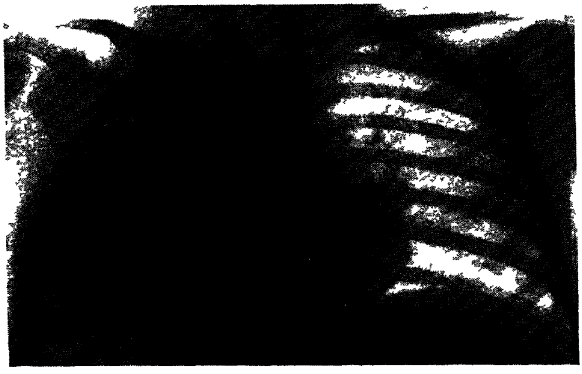

FIG. 609.—Posterior view of a generalised left-sided empyema. The heart is displaced to the right. (Dr. J. E. A. Lynham.)

Treatment.—In bygone days practically all empyemata were treated by rib resection and drainage. During the influenzal epidemic of 1918, it was abundantly clear that immediate drainage of empyemata associated with pneumonia (synpneumonic) carried a mortality of about 60 per cent. This is partly due to the fact that the effusion occurs, and is diagnosed, while the lung is still consolidated, and therefore unable to expand, also adhesions are weak or absent. Therefore rib resection causes an open pneumothorax, with consequent embarrassment of a heart on which great demands are already made, and the musculature of which is enfeebled with toxæmia. On the other hand, a pneumococcal empyema occurs at a later stage when consolidation is nearly or has already abated (postpneumonic),

and therefore the lung is expansile. Also adhesions have formed, and so walled off the abscess from the pleural cavity, and the general condition of the patient is improving.

The treatment of a streptococcal empyema consists of aspiration until the initial brownish turbid fluid has changed to definite pus. For practical purposes the aspirated fluid is allowed to stand in a test tube for twelve hours. If over 75 per cent. of pus is present the adhesions are strong enough for open drainage. Cardiac embarrassment is relieved by aspiration, and adhesions are given time to form. Moreover, the general resistance of the patient will improve in the interval. Aspiration is performed and repeated as often as necessary, with oxygen replacement if such is considered advisable. If repeated aspiration causes infection of the chest wall a catheter should be inserted under local anæsthesia and connected with a water-locked bottle. After a period of two or three weeks the pus becomes thicker in consistency and yellowish in colour. In some cases aspiration alone is sufficient, otherwise rib resection and drainage can now be performed with comparative safety. Treatment on these lines has reduced the mortality of synpneumonic empyema to about 9 per cent.

Operation.—In the case of a generalised empyema the most suitable ribs for excision are the 9th in the scapular line, or the 8th in the mid-axillary line. Drainage at a lower level is likely to be impeded by the diaphragm, and above this the scapula covers a portion of the ribs, and the opening is too high to be dependent. Care must be observed regarding posture. Either the prone position is adopted, or the patient is placed with the affected side projecting beyond the edge of the table, with a sand-bag beneath the loin so as to turn him slightly towards the sound side.

Careful consideration must be given to the choice of anæsthetic. Ether is a pulmonary irritant and chloroform a cardiac poison, therefore gas and oxygen anæsthesia or local infiltration are the methods of choice. If local anæsthesia is used, it is advisable, first, to infiltrate and divide the skin and tissues so as to expose the required rib. The region of the intercostal nerve, which runs along the lower costal border, is then infiltrated with novocaine as far back as possible, and the process repeated so as to anæsthetise the nerve above and below. An angled needle facilitates this step.

The incision is made either transversely along the axis of the rib, or vertically. In the latter case the fibres of the latissimus dorsi are split, and the drainage tube can be inserted precisely opposite

the opening in the pleura. The periosteum is incised along the rib and separated from the superficial surface with a periosteal elevator. By means of a Doyen's raspatory the periosteum and intercostal vessels and nerve are pushed off the deeper surface. From 2 in. to 4 in. of rib are excised with rib shears, the actual length depending on the size of the patient. If an intercostal vessel is injured a further amount of bone is excised so that it can be securely ligatured. Sinus forceps are then thrust through the deep layer of periosteum and parietal pleura, and as pus escapes a finger is inserted into the opening, so that the gush of pus can be controlled, and sudden movements of the mediastinum prevented.

As the flow of pus diminishes the finger is introduced into the lower part of the cavity so as to open any loculi, and flakes of fibrin are removed with gauze and sponge forceps. If open drainage is contemplated, a flanged tube is introduced, which should only just penetrate the pleural cavity, otherwise it may project above the level of the pus, and also irritate the expanding lung or rising diaphragm. In addition to the flange the tube is also stitched to the margin of the wound, as an extra precaution against it being sucked into the pleural cavity.

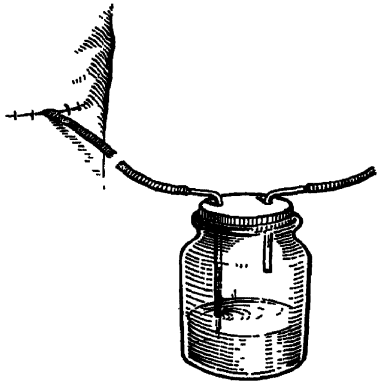

FIG. 610.—Closed method of drainage.

Dressings require frequent renewal during the first day or so. Expansion of the lung is encouraged by blowing water from one Woulff's bottle to another, or in the case of a child a trumpet is useful, provided the noise can be tolerated.

The *closed* method of drainage presents the advantage that during inspiration air is not drawn into the pleural cavity, and consequently the negative pressure which encourages lung expansion is maintained. Also frequent dressings are unnecessary, which are exhausting in a debilitated patient. The muscles and skin are firmly sutured round the drainage tube, which is allowed to project some 3 or 4 in. A glass connection is fitted into the drainage tube, and to the other end a rubber tube is attached sufficiently long to allow the free end to be submerged in a jar containing antiseptic solution, which is placed by the bedside. During inspiration the antiseptic rises in the tube, and on expiration pus is ejected into the antiseptic (fig. 610). After five or six days the drainage tube loosens, but by this time adhesions have formed round the sinus. This method can be elaborated by utilising some form of suction apparatus. The closed method of drainage is very desirable in young children.

In the case of bilateral empyemata the side containing the larger collection of pus is drained, and the opposite side aspirated for a few days until the original wound is securely closed by adhesions.

In cases where the minimal amount of disturbance is desirable, as in the case of young children or debilitated patients, intercostal

drainage can be obtained by means of a special trocar and canula (fig. 611). If necessary rib resection is performed after the immediate crisis has passed, i e. about ten days later.

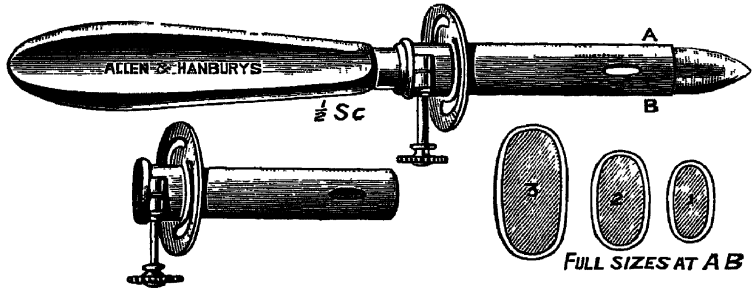

FIG. 611.—An empyema trocar for intercostal drainage.

Interlobar empyemata, and those in apposition with the mediastinum or diaphragm, are unlikely to be diagnosed with certainty without the assistance of X-rays (fig. 612). The radiological appearance resembles that of a pulmonary abscess, but usually the definition is clearer in the case of an empyema. Although spontaneous cure sometimes follows rupture into a bronchus, yet delay is not advisable, owing to the risk of subsequent bronchiectasis. As in the case of pulmonary abscess, exploratory needling as an aid to diagnosis is to be deprecated, owing to the risk of infecting the general pleural cavity.

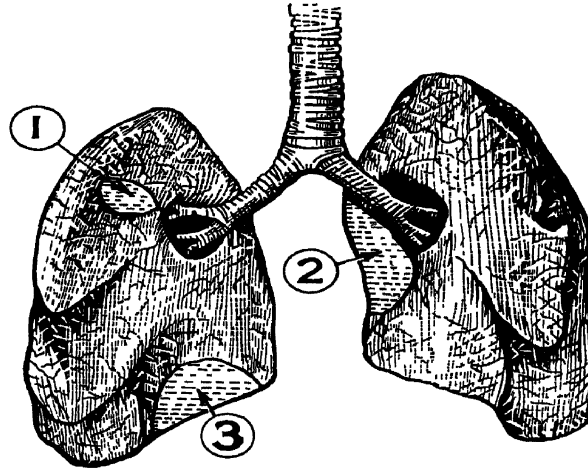

FIG. 612

1. Interlobar empyema.
2. Mediastinal empyema.
3 Diaphragmatic empyema

The affected portion of lung should therefore be exposed by resection of a suitable rib. In the absence of adhesions stitches are introduced so as to approximate the parietal and visceral pleura.

If delay is unwise the pus is located with a needle, and the empyema opened with a diathermy knife or cautery. If the delay of a few days can be tolerated by the patient, it is wiser to pack gauze into the wound and allow adhesions to form before drainage of the pus.

Chronic Empyema

The term " chronic " is an arbitrary one regarding duration of time, but clinically it is applied to those cases which require further surgical treatment.

Causes.—The majority of empyemata become chronic as a result of delay in the treatment of acute cases, or by reason of faulty or inadequate drainage.

The actual causes can be summarised as occurring in connection with the chest wall, the pleural cavity, or the lung, although in many cases more than one factor is responsible for chronicity.

(i) *Chest Wall.*—Drainage is inadequate. Either it is not dependent, or it is too small to allow free escape of pus. In other cases loculi are present, and continually reinfect the main cavity.

Fibrosis of intercostal muscles and thickening of the parietal pleural result in inelasticity of the parietes, and consequent delay in healing.

(ii) *Pleural Cavity.*—Foreign bodies are occasionally responsible for non-closure, and include drainage tubes, aspirated teeth, and separated sequestra. If tuberculosis or actinomycosis is present prolonged chronicity is inevitable.

(iii) *Lung.*—Expansion of the lung is hindered or rendered impossible by interstitial fibrosis or thickening of the visceral pleura. The thickened pleura also harbours organisms, and so is a source of reinfection. Bronchial fistulæ are not uncommon, and occasionally a chronic empyema is associated with a neoplasm.

Treatment.—Obviously it is essential to endeavour to discover the cause of the chronicity. A routine clinical examination of the chest may suggest the presence of fluid or a neoplasm. A probe in some cases shows that the drainage is obviously inadequate, or detects the presence of a foreign body.

A radiograph will demonstrate loculi containing fluid. Information regarding the extent and direction of the cavity or sinuses can be obtained by means of an X-ray after injection of lipiodol (fig. 617). The suspected presence of most foreign bodies, including tubes of red rubber (which contain sulphur, and are therefore opaque) is confirmed.

Bacteriological examination of the discharge is likely to show a variety of organisms, owing to mixed infection. The

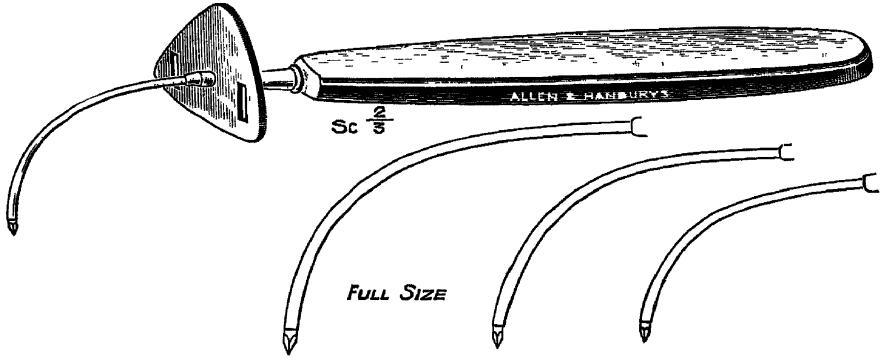

FIG. 613.—Trocar and canula for injection of lipiodol through the cricothyroid membrane.

presence of tubercle bacilli or the ray fungus is of gloomy significance.

TREATMENT in the first instance consists in removal of a foreign body if such is present, and securing adequate drainage. If necessary, portions of one or two ribs are removed, and loculi are opened so that they drain freely into the main cavity. Irrigation by Carrel-Dakin's method promotes healing, both by its antiseptic property, and also by softening the fibrous coating over the lung, and so encouraging expansion. Irrigation cannot be used if bronchial fistulæ are present, as fluid trickles into the lung and causes violent coughing. When healing is proceeding in a satisfactory manner the use of an appliance which exercises pressure on the chest wall will expedite closure of the cavity (fig. 614). Compensatory scoliosis, flattening of the chest, emphysema of the lung, and displacement of the mediastinum all contribute towards obliteration of the cavity.

If, after a reasonable trial of the above measures, progress is disappointing, more extensive measures must be adopted, so that the chest wall and lung are approximated. Either the chest wall is mobilised, or the visceral pleura dealt with so that the lung can re-expand.

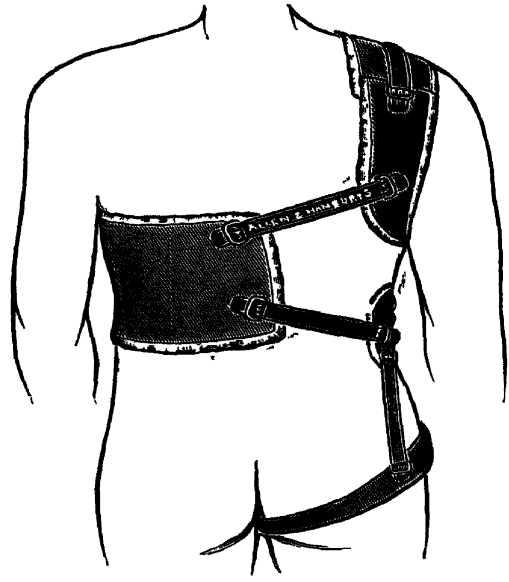

FIG. 614 —Thoracoplasty splint for applying pressure to aid collapse after resection of ribs.

OPERATIONS ON THE CHEST WALL

Estlander's operation, which consisted of subperiosteal removal of portions of overlying ribs, yields poor results, as the chest wall is also rendered immobile by indurated and fibrotic muscles, and thickened parietal pleura. Schédé therefore elaborated Estlander's operation and removed these structures, as well as the ribs and periosteum, with gratifying results. A basal anæsthetic such as nembutal is advisable, reinforced with gas and oxygen or local anæsthesia. A flap of skin and subcutaneous muscles is turned up, and shock and post-operative pain are diminished if the intercostal nerves corresponding to the ribs to be resected, together with the nerve above and below, are injected posteriorly with 90 per cent. alcohol. Schédé's operation is now reserved for small empyemata situated laterally, otherwise an extensive thoracoplasty in two or three stages is necessary. Regeneration of periosteum is discouraged by mopping the beds of the ribs with 10 per cent. formalin.

OPERATIONS ON THE LUNG

Decortication (Delorme) and discission (Ransohoff) are the measures advocated with the object of allowing the lung to expand.

Discission consists in making a series of incisions through the thickened visceral pleura so that it is divided into ¼-in. squares. Although this procedure is simpler than decortication, yet the latter operation yields better results. Decortication entails dissecting the thickened pleura from the lung, which is a difficult and tedious process. These operations are unlikely to benefit as interstitial fibrosis will prevent adequate lung expansion. Operations devised to allow expansion of the lung are contraindicated in tuberculous cases.

Amyloid disease is likely to supervene in long-standing cases, such as those due to tuberculous or actinomycotic infection.

Pulmonary Tuberculosis

In a volume of this nature a summary of the surgical procedures for the treatment of pulmonary tuberculosis is all that can be attempted. For detailed information the reader must consult special books.

Artificial Pneumothorax.—This is a simple procedure, and practically free from danger. It consists of injecting air into the pleural cavity through a needle, a manometer being used so that pressure can be regulated. When the puncture is made a negative pressure and respiratory variations indicate that the needle-point is in the pleural cavity. The initial dose of 250 c.cm. is injected and increased at sub-

Fig. 615.—Posterior view of collapsed left lung, after artificial pneumothorax. The arrows indicate a cavity in the upper lobe. (Dr. J. E. A.

sequent injections until the lung is completely collapsed, as shown by radiography (fig. 615). Pneumothorax is indicated in all cases in which one lung is comparatively healthy, provided that no advanced cardio-vascular disease is present, and that the patient's mental state is satisfactory.

Artificial pneumothorax is especially beneficial in chronic cases associated with fibrosis, and is also a valuable means of controlling hæmoptysis. The main cause of failure is the presence of adhesions, which prevent collapse of the lung. Fine adhesions can sometimes be ruptured by increasing the intrapleural pressure up to 15 mm. of mercury. A pressure higher than this is likely to cause tearing of the surface of the lung, with consequent hæmorrhage and infection. Attempts are sometimes made to stretch adhesions by maintaining an intrapleural pressure of 10 mm. of mercury for some weeks. If one or two stout adhesions prevent collapse they may be divided with a thermo-cautery. Two canulæ are introduced between suitable ribs. A thoracoscope is inserted through one canula, and a cautery through the other, so that the adhesion is divided under direct vision.

Phrenic Evulsion.—This operation should be performed under local anæsthesia, provided the patient is old enough to be self-controlled.

The nerve is exposed through a horizontal incision situated one inch above the clavicle. The omohyroid muscle is drawn upwards, and the outer border of the scalenus anticus identified. On retraction inwards of the sterno-mastoid, the phrenic nerve is exposed by blunt dissection, and is seen passing downwards and inwards on the scalenus anticus. The nerve is divided, and the lower end seized with artery forceps, and by traction and twisting the nerve is evulsed. Usually about 4 in. of nerve are removed. The accessory phrenic nerve arises from the nerve to the subclavius or directly from the 5th cervical nerve, and passes into the thorax in front of the subclavian vein. It joins the main nerve in the thorax, and is therefore removed by a successful evulsion.

The result of phrenic evulsion is to diminish the capacity of the corresponding pleural sac by about one-third. As the diaphragm loses its tone this amount increases. The diaphragm is sometimes partially supplied by the lower intercostal nerves, in which case paralysis is incomplete.

Diaphragmatic adhesions and thickening of the pleura will also hamper elevation of the diaphragm.

Phrenic evulsion is particularly indicated as an accessory to artificial pneumothorax, especially if the lung is adherent to the diaphragm, or if pneumothorax has failed to collapse a thin-walled cavity. Also when the lung is allowed to re-expand the required degree of expansion is limited. Phrenic evulsion is always performed as a preliminary to total thoracoplasty, as a less extensive operation is then adequate.

Thoracoplasty should be considered in cases of unilateral long-standing cases of tuberculosis, especially if cavities

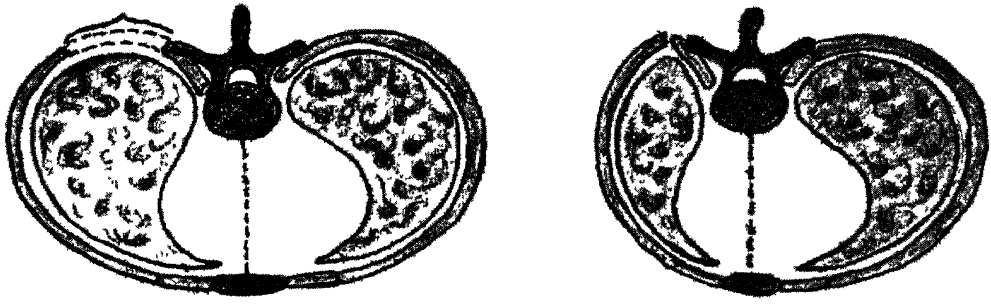

FIG. 616.—Showing collapse obtained after thoracoplasty. For maximum collapse the rib must be excised as far as the transverse process (after Brunner).

or bronchiectasis are present. In these cases artificial pneumothorax would be necessary for an indefinite period, but thoracoplasty attains the same result, i.e. permanent collapse, with more certainty, also further local treatment is unnecessary.

In bilateral cases thoracoplasty is contraindicated unless severe hæmorrhage occurs from one lung, in which case rib resection on that side is sometimes performed in order to arrest the periodic bleeding.

As a preliminary to the operation efforts must be made to improve the patient's general health, and phrenic evulsion should be performed.

Needless to say, as the operation is severe, the patient should be in a reasonably good state of health, and not past his or her physiological "middle-age."

Operation.—Sauerbruch's method is usually adopted. This consists of excision of the posterior ends of the upper eleven ribs as close to the costo-transverse joint as possible (fig. 616). The amount of each rib to be removed is approximately as follows: first rib, 2 cm.; second rib, 4 cm.; and from 6 cm. to 12 cm. for subsequent ribs up to the eighth, below which the length decreases. To avoid excessive shock the operation is usually done in stages, but owing to scar tissue fixing the ends of the ribs already divided, the amount of collapse is lessened. The interval between stages should not exceed three weeks, otherwise this fixation very seriously interferes with falling in of the chest wall.

The operation is performed under gas and oxygen or local anæsthesia according to the patient's mentality and the extent of the intended operation. A moderate dose of some basal anæsthetic is useful, especially in nervous patients. A periscapular incision is made and the superficial muscles are divided. The arm is drawn forwards so as to displace the scapula and expose the subjacent ribs. The first six ribs are excised from below upwards, and special care is exercised in resecting the first rib, as the 1st dorsal nerve and superior intercostal artery pass across the neck. If the condition of the patient is satisfactory and a one-stage operation is intended, the incision is prolonged downwards so as to expose the lower ribs. These are excised from below upwards. A firm bandage is applied in order to steady the mediastinum, and the patient is encouraged to cough freely so as to expel secretion.

Wilm's operation combines resection of the upper five or even seven costal cartilages on the same side as the thoracoplasty. These costal cartilages are resected as soon as the patient has sufficiently recovered from removal of the posterior parts of the ribs. The operation is useful when dense fibrosis or bronchiectasis calls for the maximum amount of collapse obtainable.

If the disease is localised, the excision of a limited number of ribs may suffice.

Pneumolysis.—This procedure consists of separating the parietal pleura from the chest wall, so that the portion of lung beneath is encouraged to collapse. The resulting cavity is filled with paraffin wax, which is simpler and more adaptable than fat or muscle. This operation has its chief application in cases in which a cavity is present in one or both apices (apicolysis).

Abscess of the Lung

Causes.—The commonest cause of lung abscess is aspiration during an operation of foreign material, such as blood-clot, a tooth, part of a tonsil, or regurgitated food. The majority of abscesses follow operations under general anæsthesia. Other causes include unresolved pneumonia, pulmonary in-

farcts, and penetrating wounds. An empyema is occasionally the result of a lung abscess, but rarely, if ever, the cause.

Clinical Features.—General signs and symptoms are usually evident, and in acute cases include a swinging temperature, sweating, anorexia, and wasting. The breath is fœtid, and pain indicates involvement of the pleura. Physical examination of the chest usually reveals a local area of dullness, with diminished breath-sounds, and possibly signs of a cavity. In stout patients a small abscess is naturally difficult to locate with assurance. The commonest site for an abscess is the lower lobe of the right lung.

An abscess is likely to rupture into a bronchus, in which case a copious amount of offensive, purulent sputum is expectorated. Shreds of lung tissue or elastic fibres can frequently be recognised. If the sputum is allowed to stand, three layers become evident ; the upper of frothy mucus, the central turbid, and the lowest containing debris and pus cells. The sputum is frequently blood-stained, but definite hæmoptysis is less common than with bronchiectasis. Clubbing of the fingers occurs in long-standing cases.

Radiography is of the utmost value, and films should be taken from the front, side, and back. Appearances vary according to the acuteness or chronicity of the abscess, and whether an existing cavity contains pus or is partly air-filled. In acute cases respiratory movements are limited, and the portion involved appears as an area of irregular density, surrounded by a zone of slightly increased opacity, due to consolidation. In chronic cases the area of density is more circumscribed, and should air be present the upper portion of the cavity is translucent.

Lipiodol is of little use, as even if the cavity is partially empty granulation tissue prevents entry of the oil. It is even stated that lipiodol may disseminate infection to other parts of the lung. Exploratory needling is not justified, owing to the risk of infecting the pleural cavity and consequent formation of an empyema.

Treatment.—Symptomatic treatment is necessary in acute cases. Stimulants, expectorants, sedatives and posture, so

that free expectoration is encouraged, all receive consideration. This treatment is continued so long as the abscess drains freely, and shows signs of resolution, but it is inadvisable to delay operative interference for longer than six weeks, as otherwise fibrosis and bronchiectasis are liable to develop.

Operations.—*Bronchoscopy* with aspiration is the simplest form of treatment, but is unlikely to be curative as the opening into the abscess is usually small and difficult of access; also it is apt to be obscured by granulation tissue. Aspiration is continued as long as improvement is maintained, and granulations can be discouraged by painting with 10 per cent. silver nitrate solution.

Phrenic evulsion is a useful adjunct to treatment if the abscess is basal in position and recent in origin.

Thoracotomy, in the absence of widespread fibrosis or bronchiectasis, is comparatively safe, and gives good results in selected cases. Unless urgent, the operation is performed in two stages.

Careful localisation is essential, and under gas and oxygen or local anæsthesia exposure is obtained by resection of portions of two suitable ribs and intercostal structures. The parietal and visceral pleuræ are encouraged to adhere by the insertion of gauze moistened with iodine. The wound is closed. A week later the wound is reopened, the gauze is removed, and the lung is explored with a needle. On discovery of the abscess, the needle is left in the cavity, and the intervening lung incised with a scalpel or diathermy knife. Pus is evacuated and loculi opened freely. The cavity is packed with gauze moistened with mild antiseptic, and the wound closed with the exception of an aperture for the packing. The gauze is removed on the third day, and the wound repacked daily until healed. Drainage tubes should not be used, on account of the likelihood of erosion of the lung and consequent hæmorrhage.

Thoracoplasty, preceded by phrenic evulsion, is sometimes advisable if infection is widespread.

Lobectomy, when the abscess is confined to one lobe, holds out the best prospect of cure, especially when the abscess is complicated by surrounding fibrosis or bronchiectasis.

Bronchiectasis

Causes.—The commonest cause of bronchiectasis is unresolved broncho- or lobar-pneumonia. Pressure on a bronchus by enlarged glands, tumours, or aneurisms occasion-

ally results in bronchiectasis. A chronic lung abscess or long-standing tuberculosis is usually associated with some degree of bronchiectasis.

Clinical Features.—The usual symptoms are persistent cough and free expectoration, which varies in quantity according to the position of the patient. The sputum is usually frothy and fœtid. Loss of weight, or in the case of a child diminution in stature, is sometimes observed. Hæmoptysis occurs in 25 per cent. of cases, and clubbing of the fingers in 50 per cent.

On examination of the chest the percussion note is dull over the affected area. Amphoric breathing and moist sounds may be heard, but vary according to the emptiness of the dilated tubes. Surrounding fibrosis is likely to displace the heart, and in long-standing cases scoliosis develops.

Lipiodol injection, with the patient in such a position that the oil gravitates to the affected area, is of great assistance. The bronchial tree is outlined, and the site and extent of the disease can be estimated (fig. 617).

FIG. 617.—Radiograph of bronchiectasis, following lipiodol injection.

Treatment.—Permanent improvement is unlikely, apart from operative procedures. Inhalations, expectorants, and postural coughing are palliative measures, and may render a patient comparatively comfortable, and the diminution of halitosis will be appreciated by his neighbours. If a foreign body is present it should be removed by bronchoscopy, and aspiration of secretion via a bronchoscope at intervals will relieve the symptoms. Cerebral abscess is a dreaded complication, as with other causes of chronic pulmonary infection.

Artificial Pneumothorax.—As in the case of a lung abscess, this procedure is unlikely to be successful on account of adhesions and surrounding fibrosis.

Phrenic evulsion is useful in recent or localised cases, and in any case is a preliminary step to thoracoplasty.

Thoracoplasty.—Sufficient ribs should be removed to cause generous diminution in the size of the thoracic cavity. The operation should be performed in stages, in order to avoid too sudden a collapse and flooding of the lung with secretion. A wide amount of rib should be excised over the affected area, so that the greatest collapse will occur where most needed.

Lobectomy must always be considered if the patient's condition warrants this somewhat severe procedure and if the disease is confined to one lobe. Many brilliant cures have resulted from this operation.

Intrathoracic Neoplasms

Benign

Mediastinum :
- Subserous lipoma. Fibroma. Teratoma.
- Dermoid, usually in the anterior mediastinum.
- Retrosternal goitre, often calcified.
- Ganglio-neuroma.

Lung and Pleura : Endothelioma.

Malignant

Primary

Mediastinum :
- Lymphosarcoma. Fibrosarcoma.

Lung :
- Hilum, i.e. bronchial carcinoma.
- Parenchymatous, i.e. squamous-celled carcinoma commencing in a lobe.

Secondary

Mediastinum :
- Direct invasion, as from the breast.
- Lymphatic involvement, as from thyroid or breast.

Lung :
- Blood-borne metastasis, usually sarcoma.

Benign neoplasms give rise to signs and symptoms according to their size, position, and rate of growth. A benign tumour which grows slowly may attain insidiously the size of a fœtal head, as structures are gradually displaced and accommodate themselves in a surprising manner. Gradually increasing pressure, especially in children, is likely to cause deformity of the chest wall, owing to bulging of the ribs or even sternum.

A tumour in the upper narrow portion of the thorax is more likely to cause trouble from pressure on the œsophagus

or trachea while it is still of comparatively small size. A typical example is the plunging retrosternal goitre with recurrent attacks of dyspnœa.

The symptoms and signs of a benign thoracic tumour naturally vary widely. In the case of a large growth, inspection reveals diminished movement and possibly



FIG. 618.—A fibroma in the anterior mediastinum. (Dr. J. E. A. Lynham.)

deformity. Percussion over the tumour yields a dull note, and on auscultation breath-sounds are absent.

Radiography is of the utmost value. A simple X-ray reveals the tumour (fig. 618). Alteration in position of the tumour, after an artificial pneumothorax, suggests that the tumour is attached to the lung or pleura. Lipiodol injection may reveal pressure collapse of part of the lung adjacent to the tumour.

Treatment.—Removal of a benign new growth should

always be contemplated, otherwise vital structures will become eventually compressed, with fatal results.

Approach to the *anterior mediastinum* can be obtained by splitting the sternum along its whole length, a special chisel being used for the purpose (fig. 619). Traction on either side gives a wide

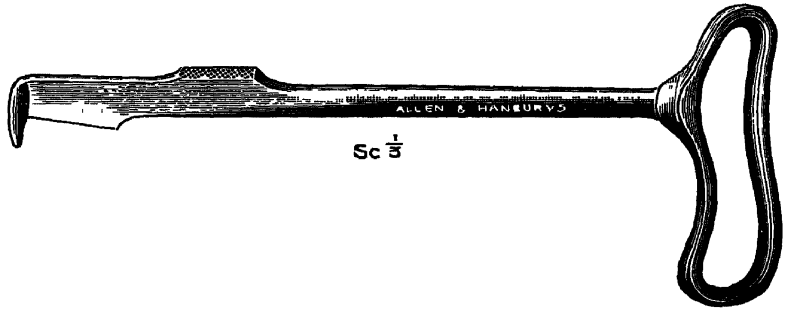

FIG. 619.—Chisel for splitting the sternum.

exposure. If a less-extensive operation is adequate the sternum is split to the third space, and then laterally, either on one or both sides, as may be necessary. Incisions are carried through the intercostal spaces, the internal mammary vessels are ligated, and the two halves of the sternum are pulled apart.

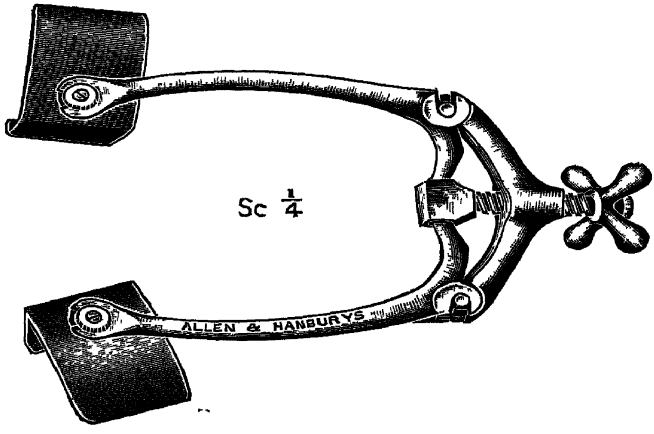

FIG. 620.—A mechanical rib retractor

A tumour situated in the *region of the hilum* is exposed by lateral thoracotomy. An incision is made along the 5th intercostal space from the angles of the ribs behind, to the costal cartilages in front. If the maximum amount of room is desirable, the 5th rib is excised subperiosteally. Mechanical rib spreaders are introduced (fig. 620), and an excellent view of the corresponding side of the thorax is thus obtained. Intratracheal anæsthesia is necessary for thoracic operations, in order to prevent pulmonary collapse.

Malignant.—Primary malignant tumours of the lungs arise either in a bronchus or more rarely in the lung tissue itself.

Bronchial carcinoma soon causes symptoms, the most

prominent of which is an irritable cough. In the early stages sputum is small in amount, but often tinged with blood, so that tuberculosis is frequently suspected. In the later stages brisk hæmoptysis is likely to occur, and a purulent sputum indicates secondary infection. Loss of weight and deterioration in health soon follow. Secondary changes in the lung include bronchiectasis, and resorption collapse of a lobe owing to bronchial obstruction. A pleural effusion, usually blood-stained, is commonly present, and is liable to infection.

Involvement of nerves, including the phrenic, left recurrent laryngeal, or sympathetic, in which case Horner's syndrome is manifest (myosis, ptosis, anidrosis, and enophthalmos). Pressure on veins is a late manifestation. Axillary and cervical glands are sometimes involved, and secondary deposits in bones are relatively common, and may lead to the discovery of the primary growth. Clubbing of the fingers and osteo-arthropathy sometimes occur, especially if the growth projects into the mediastinum.

Examination of the chest reveals diminished movement, dullness on percussion, altered or absent breath-sounds, and possibly evidence of effusion. Dilated veins are commonly seen, and evidence of nerve involvement or venous obstruction is sometimes present.

A radiograph is usually diagnostic, and the tumour is seen radiating from the hilum. Also one or more lobes are sometimes seen to be collapsed (fig. 621).

FIG. 621 —Carcinoma of the right bronchus extending into the lung.

By means of a bronchoscope the edge of the tumour is usually visible.

The treatment of bronchial carcinoma is symptomatic, although some temporary improvement may follow deep X-ray therapy. Aspiration of fluid with or without air replacement sometimes diminishes discomfort. The insertion of radon seeds through a bronchoscope is liable to cause mediastinitis, but intubation with a radon tube is useful to maintain an airway and so prevent collapse. Hypodermic injections of cocaine produce a humane euphoria. The average duration of life is from six to nine months from the onset of symptoms.

Parenchymatous carcinoma is much less common than the bronchial type. The tumour consists of a squamous-celled carcinoma, and is usually situated in the upper lobe. Symptoms are slow in appearance, and may be delayed until involvement of the pleura causes pain. Cough and expectoration are not in evidence until a bronchus is eroded, or compression results in bronchiectasis. A radiograph shows a shadow of somewhat unequal density, which closely resembles a lung abscess.

A few of these tumours have been successfully removed by lobectomy, and provided the patient's condition is satisfactory and the tumour circumscribed, this procedure should be considered. The affected lobe is exposed by thoracotomy, and the vagus nerve injected with novocaine. The vessels which supply the affected lobe are secured, and the bronchus crushed, ligatured, and divided. The lobe is removed, and the wound closed with drainage, as infection from the bronchial stump is likely to occur.

Secondary deposits in the thorax or lung are important from the standpoint of prognosis. They are usually readily demonstrable by X-rays (figs. 622 and 623). Deep X-ray may cause some recession or arrest of growth.

Pulmonary Embolism

This dreaded complication is the cause of death in ·1 per cent. of all major operations. In addition to these fatal cases, emboli not infrequently delay convalescence and cause alarm and anxiety to both surgeon and patient.

Much time and labour have been expended in endeavouring to elucidate the causes of pulmonary embolism. As far as our present knowledge carries us, the following predisposing causes favour embolus production.

Pre-operative.—*Age of Patient.*—Embolism is rare under the age of 20. The most common decades are the fifth and sixth.

Site of Operation.—Pelvic operations, particularly hysterectomy and prostatectomy, are most commonly

FIG. 622.—Secondary deposits following carcinoma of the breast. (Dr. J. E. A. Lynham)

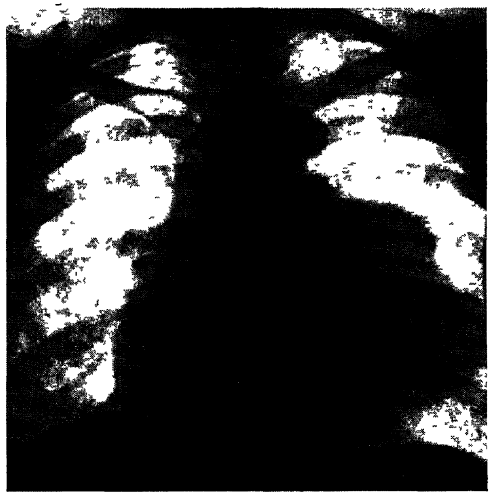

FIG. 623.—Intrathoracic sarcoma. (Dr. J. E. A. Lynham.)

associated with embolism. Operations on the upper part of the body are very rarely complicated by pulmonary embolism.

Operative.—*Operative Trauma.*—Tearing or bruising of tissues, as by prolonged pressure of mechanical retractors, is liable to cause absorption of an excessive amount of coagulant substances.

Post-operative.—*Stasis.*—Post-operative shock and prolonged immobility of the patient favour venous stasis, and so encourage intravenous clotting. In operations on the upper abdomen subsequent diminution of the

diaphragmatic excursion favours stasis in the abdominal veins.

Infection.—It was formerly considered that infection of the operation field was almost a *sine qua non* in the production of pulmonary embolism. There is little evidence to support this, and Sir Bernard Spilsbury in 120 necropsies, in which death was caused by pulmonary embolism, found infection present in only 25 per cent.

In addition to these causes, *desiccation*, as by pre-operative limitation of fluids, hæmorrhage during the operation, and post-operative vomiting, all lead to diminution of body fluids, and consequently predispose to thrombosis.

Clinically, pulmonary emboli occur in three more or less distinct degrees of severity (Lockhart Mummery).

(i) The patient experiences a sudden sharp pain which is aggravated by respiratory movements. Hæmoptysis follows, and on examination a small patch of dullness and crepitations are usually discoverable. Recurrences are not infrequent, but the prognosis is favourable.

(ii) Sudden acute precordial pain occurs, with dyspnœa and cyanosis. After a period of acute distress, usually lasting for a few minutes, the patient succumbs.

(iii) The patient gasps, perhaps urgently requests a bed-pan, and dies almost immediately.

The commonest time for emboli to occur is towards the end of the second week. As a rule there is nothing to indicate that the catastrophe is imminent, and often previous convalescence has been uneventful. In a few cases patients have complained of cramp-like pains in the lower abdomen or legs.

Treatment.—*Pre-operative.*—The avoidance of purgation and of limitation of fluids.

Operative.—Trauma must be reduced to a minimum. Self-retaining retractors should not overstretch the tissues for long periods. Unnecessary tearing and bruising of tissues is to be deprecated. Loss of blood must be prevented as far as possible.

Post-operative.—The patient should be encouraged to

drink freely. If vomiting is troublesome, rectal or subcutaneous saline should be administered. Thrombosis is most likely to occur during the forty-eight hours following the operation, and exercises are especially desirable during this period, in order to discourage venous stagnation.

Recent experiments suggest that the agglutinability of the blood platelets is less with a diet of carbohydrates than with meat. Therefore meat extracts should be prohibited during the first few days following operation.

Within a few hours of the operation active flexion of the hip and knee joints should be performed every two hours. In addition, on the day following the operation, the patient is encouraged to raise the buttocks by pressing the hands into the bed. A few slow and deliberate deep breaths should be taken at stated intervals so that the piston-like action of the diaphragm squeezes blood out of the abdominal veins. These exercises, with elaborations, if necessary, are continued until the patient leaves bed, and in addition to lessening the risk of embolism, they interest the patient, improve muscular tone, and shorten the period necessary for convalescence.

Tight abdominal binders and many-tailed bandages hamper respiratory movements, therefore in the case of susceptible patients dressings should be fixed with strips of elastoplast or adhesive strapping.

TRENDELENBURG'S OPERATION

Several cases are now on record in which an embolus or emboli have been successfully removed from the pulmonary artery. As with "new" operations enthusiasm is apt to over-rule discretion, and the criticism has been levelled that attempts have been made to perform the operation in unnecessary cases. The type of case suitable for this procedure is one in which the patient is unconscious and the heart beat absent. An anæsthetic is only necessary when the wound is being closed. A vertical incision is made along the left border of the sternum, and a second horizontal incision is carried outwards along the 2nd costal interspace. The 2nd and 3rd costal cartilages and anterior portions of ribs are rapidly removed, and the pleura pushed aside. The pericardium is opened and the pulseless pulmonary artery thus exposed. A rubber tube is insinuated along the transverse sinus, so that traction delivers the aorta and pulmonary artery into the wound and simultaneously acts as a tourniquet. The pulmonary artery is incised, and forceps are passed into either branch in an effort to extract an embolus A clamp is applied to the wound in the pulmonary artery so that adequate circulation can continue while the artery is sutured. Adrenalin is injected into the left ventricle, the wound in the pericardium is closed, and the muscles and skin rapidly stitched together. Professor A. W. Meyer of Berlin has reported a series of seven successful cases of embolectomy. It would appear that this operation should be performed more often, in an attempt to "resurrect the patient from the dead."

THE HEART AND PERICARDIUM

Suppurative Pericarditis

The causes of pyopericardium are as follows :

Direct infection, as by penetrating wounds.

Local extension, as from an adjacent empyema.

Blood-borne infection, which is the commonest cause, and is particularly prone to occur as a complication of acute osteomyelitis.

Pus in the pericardium, as is the case with any fluid, produces cardiac distress owing to heart tamponade. This condition is due to the presence of fluid in the inelastic pericardial sac, which prevents adequate cardiac diastole. If a pyopericardium is suspected, the sac must be aspirated. The needle is inserted obliquely upwards through the 5th space, a full inch from the left border of the sternum, so as to avoid injury to the internal mammary vessels. If pus is withdrawn pericardostomy should be performed, as although the mortality is over 90 per cent., the condition otherwise is probably hopeless.

Pericardostomy

Drainage is obtained either by the anterior or the inferior route. The former is the simpler method, but drainage is less dependent.

(*a*) *Anterior.*—The 5th costal cartilage is excised through a transverse incision. The internal mammary vessels are divided between ligatures, and fibres of the triangularis sterni muscle brushed aside. The pleura is displaced by the distended pericardium and is not encountered. Should the chest wall be thin the bulging pericardium is sutured to the skin so as to diminish the risk of mediastinitis. The pericardium is aspirated, opened, and drained by means of a soft rubber tube.

An alternative method of exposing the anterior surface of the pericardium consists in trephining the sternum just above the xiphoid cartilage. The trephine hole is enlarged towards the left with nibbling forceps. The exposed pericardium is picked up by means of a suture and opened. The internal mammary vessels are not encountered, and the operation can be performed under local anæsthesia. We have found this method to be very satisfactory.

(*b*) *Inferior.*—A vertical incision is made over the left costo-xiphoid angle. The rectus muscle is split and the peritoneal reflection pushed downwards. If the costo-xiphoid angle is narrow, part of the 7th costal cartilage should be excised. The superior

drink freely. If vomiting is troublesome, rectal or subcutaneous saline should be administered. Thrombosis is most likely to occur during the forty-eight hours following the operation, and exercises are especially desirable during this period, in order to discourage venous stagnation.

Recent experiments suggest that the agglutinability of the blood platelets is less with a diet of carbohydrates than with meat. Therefore meat extracts should be prohibited during the first few days following operation.

Within a few hours of the operation active flexion of the hip and knee joints should be performed every two hours. In addition, on the day following the operation, the patient is encouraged to raise the buttocks by pressing the hands into the bed. A few slow and deliberate deep breaths should be taken at stated intervals so that the piston-like action of the diaphragm squeezes blood out of the abdominal veins. These exercises, with elaborations, if necessary, are continued until the patient leaves bed, and in addition to lessening the risk of embolism, they interest the patient, improve muscular tone, and shorten the period necessary for convalescence.

Tight abdominal binders and many-tailed bandages hamper respiratory movements, therefore in the case of susceptible patients dressings should be fixed with strips of elastoplast or adhesive strapping.

TRENDELENBURG'S OPERATION

Several cases are now on record in which an embolus or emboli have been successfully removed from the pulmonary artery. As with "new" operations enthusiasm is apt to over-rule discretion, and the criticism has been levelled that attempts have been made to perform the operation in unnecessary cases. The type of case suitable for this procedure is one in which the patient is unconscious and the heart beat absent. An anæsthetic is only necessary when the wound is being closed. A vertical incision is made along the left border of the sternum, and a second horizontal incision is carried outwards along the 2nd costal interspace. The 2nd and 3rd costal cartilages and anterior portions of ribs are rapidly removed, and the pleura pushed aside. The pericardium is opened and the pulseless pulmonary artery thus exposed. A rubber tube is insinuated along the transverse sinus, so that traction delivers the aorta and pulmonary artery into the wound and simultaneously acts as a tourniquet. The pulmonary artery is incised, and forceps are passed into either branch in an effort to extract an embolus A clamp is applied to the wound in the pulmonary artery so that adequate circulation can continue while the artery is sutured. Adrenalin is injected into the left ventricle, the wound in the pericardium is closed, and the muscles and skin rapidly stitched together. Professor A. W. Meyer of Berlin has reported a series of seven successful cases of embolectomy. It would appear that this operation should be performed more often, in an attempt to "resurrect the patient from the dead."

CHAPTER XXXIII

INJURIES TO BONES

Contusion of a bone results in traumatic periostitis and an extravasation of blood under the periosteum. Resolution and absorption of exudates usually follows, but in more severe cases a permanent periosteal node may persist, e g. the irregular shins of professional footballers. As in the case of extravasated blood in any situation, if the resistance of the patient is low or infective foci exist, suppuration may ensue. A subperiosteal abscess results, and unless opened without delay it may cause necrosis of the underlying bone.

Treatment of a contused bone consists of rest and cold applications, which exert a vaso-constricting effect, and thus limit oozing. If infection threatens, then fomentations are applied, and if œdema or fluctuation is detected, an incision is made down to the bone in order to reduce tension and, if suppuration has occurred, to allow the exit of pus.

FRACTURES

A fracture is caused by direct violence, indirect violence, or muscular action. The predisposing causes are divided into those which are due to general or constitutional disturbances, and those due to local conditions.

1. **General.**—(*a*) *Age.*—Fractures, especially greenstick, are common during the "toddling" period, when co-ordination and balance are being acquired. During the subsequent growing years separated epiphyses are common, and the prime of life predisposes to dislocations. Towards the end of life senile atrophy predisposes to fracture, e g. intracapsular fracture of the neck of the femur.

(*b*) General disease of bone, e.g. osteomalacia, generalised fibrocystic disease, and osteogenesis imperfecta.

Generalised fibrocystic disease is associated with parathyroid tumour and an increase of blood calcium. Cases are reported in which removal of the tumour has caused an immediate fall in the calcium content of the blood, and re-formation of bone (p. 813).

Osteogenesis imperfecta, or fragilitas ossium, is characterised by marked predisposition to fractures, which may be evident at birth, or manifests itself during childhood. Thus the fœtus may be still-

born, which is not remarkable, as the skull may be merely a membranous bag with perhaps a few islands of bone, or many fractures may be present at birth and the child drags out a precarious existence for a few months. In less-marked cases multiple fractures occur during childhood, often at the least provocation, but this tendency lessens as maturity is reached. The disease is familial, and is associated with blue sclerotics which are not thinned, as in buphthalmos, but are abnormally translucent. This translucency is due to some peculiarity of the fibrous tissue, and it is a significant fact that sprains are more common than usual in these cases.

The cause of this condition is some inherited defect in the evolution of connective tissue cells. Normally some of these cells become specialised into healthy fibrous tissue, and others into osteoblasts, but in osteogenesis imperfecta the fibrous tissue is poor in quality (e.g. blue sclerotics, sprains), and instead of the development of osteoblasts evolution stops short at cartilage cells.

Treatment consists in attention to the general health and protection from injury.

(*c*) Neuropathic conditions, e.g. tabes and general paralysis of the insane. Attendants in asylums are sometimes unfairly accused of roughness when fractures occur in patients under their charge.

2. **Local.**—(*a*) Inflammatory conditions, e.g. acute osteomyelitis.

(*b*) New-growth, e.g. local cysts, malignant growths, either primary or secondary.

(*c*) Local atrophy, e.g. tuberculous arthritis, infantile paralysis.

(*d*) Erosion of bone, e.g. aneurism.

Fractures which are predisposed to by local causes are particularly likely to occur in bones which are unsupported, e.g. femur, humerus, or clavicle.

Varieties of Fracture

1. *Simple.*—The bone is broken in one place, and no other important structures are injured.

2. *Compound.*—The fragment communicates with the external air, either through the skin, lung, or mucous membrane.

3. *Complicated.*—Other important structures are injured, such as vessels, nerves, joint, or viscera.

4. *Comminuted.*—The bone is broken into more than two pieces.

5. *Impacted.*—One fragment is driven into the other, so that abnormal mobility may not be evident.

6. *Greenstick.*—The fracture is incomplete, the bone bending, so that it is partially fractured transversely and is further damaged by a longitudinal split. This type occurs in children.

7. *Spontaneous.*—The bone fractures as a result of violence insufficient to fracture a normal bone. This type occurs as a result of pathological conditions.

Clinical Features.—A history of injury is usually obtainable from the patient, or from a witness of the accident, and in some cases a distinct " crack " is audible. On examination some or all of the following clinical features may be recognised :

(i) *Pain.*—If the patient is conscious, and not under great emotional stress, pain is referred to the site of the fracture.

(ii) *Loss of function*, which varies with the individual bone.

(iii) *Deformity*, which is either longitudinal, lateral, or rotatory. The initial deformity is due to the direction of violence, contraction of muscles, and the influence of gravity, and the deformity is maintained by spasm of muscles, gravity and extravasation of exudates.

(iv) *Other Signs of Injury.*—These may be absent or extensive. In the case of a simple fracture, extravasated blood usually reaches the surface in two or three days.

(v) *Abnormal Mobility.*—Is present unless the fracture is of the greenstick or impacted variety.

(vi) *Crepitus.*—This sign can be detected if the fragments are adjacent and not impacted. It must obviously be sought for with gentleness and discretion, owing to consequent pain, and the possibility of causing further injury.

It cannot be too strongly emphasised that even in cases in which there is but the merest possibility that a bone may be fractured, an X-ray should be taken. Otherwise the " reasonable skill and care " of the practitioner may be questioned, and no other branch of surgery is more damaging to a practitioner's reputation. It has been said that " bones are not filled with red marrow, but with black ingratitude."

UNION OF FRACTURES

The changes which occur around the ends of a fractured bone resemble those which result from any wound, but the ultimate result is the formation of bone.

As a consequence of the injury to blood-vessels at the time of the fracture, an extravasation of blood occurs around the fragments. After a few days absorption commences, and pigment from the disintegrated corpuscles stains the surrounding tissues. Connective tissue cells proliferate, new blood-vessels are formed, and granulation tissue is found around the fragments. Osteoblasts, derived from the deep layer of the periosteum and from the bone itself, invade the granulation tissue, and callus, which gradually increases in density, is formed. If the fragments are adjacent, or a bridge of periosteum unites them, "ensheathing" callus is formed around the bone, and if the medullary cavities are adjacent, they are gradually connected by a bar of "internal callus." If the medullary cavities are separated from each other they become sealed off by a layer of compact bone.

Owing to its comparative avascularity, the compact bone is the last to unite. If the bone unites in an anatomically correct position, the ensheathing and internal callus may practically disappear, so that, even when a dry bone is examined, it may be difficult to ascertain that a fracture has ever occurred. Although callus formation is proceeding normally, some weeks elapse before sufficient calcium is deposited for the callus to be clearly seen in an X-ray.

Treatment of Fractures

First-aid treatment consists of fixation of the bone by improvised means, and transportation to a suitable place for subsequent treatment. Fractures of the spine, pelvis, and lower extremity must receive necessary attention at the site of the accident, prior to transport to hospital or elsewhere for deliberate treatment.

Treatment of a simple fracture falls under three headings, i.e. reduction, fixation, and restoration of function.

(*a*) **Reduction.**—This is necessary in all cases in which displacement is present to such an extent that the subsequent utility of the limb would be jeopardised should union occur in the faulty position. If reduction is necessary it is effected with or without an anæsthetic, depending on the power of adjacent muscles and the associated degree of pain. It is important to place a limb in such a position that muscular relaxation is obtained; thus, in the case of fractures below the knee, flexion of that joint relaxes the calf muscles, and facilitates manipulation of the foot. Clinical

examination and possibly X-rays have previously indicated the direction of the deformity, and traction and rotation are used in directions necessary to restore alignment. Reduction should be attempted as soon as possible after the fracture is sustained, as infiltration by exudates and their subsequent organisation render successful manipulation increasingly difficult. Unless reduction is obviously satisfactory, confirmation should be obtained by radiology, but in any case a tape measure will exclude longitudinal deformity.

Local anæsthesia is increasing in popularity as an aid in the reduction of fractures.

Method of Injection.—A 2 per cent. solution of novocaine in saline is used, and is injected into the hæmatoma which surrounds the fragments. A previous X-ray is advisable so as to locate the exact site of the fracture. The skin is sterilised, and a small subcuticular wheal is raised by injecting novocaine with a hypodermic needle. A ·8-mm. needle is inserted so that the point is adjacent to the fracture, and a 20-c.c. syringe is attached to the needle. The piston is withdrawn, and the appearance of blood-stained fluid in the barrel indicates that the hæmatoma is reached. If no fluid is withdrawn the needle must be reinserted. When the hæmatoma is tapped an adequate amount of novocaine is injected. If necessary injections are made from different angles. Thus in the case of a Colles's fracture novocaine is injected from the flexor and extensor aspects of the wrist, and in the region of the avulsed styloid process of the ulna. The amount of novocaine required naturally varies with the site and extent of the fracture, but average quantities are 20 c.c. for fractures near the wrist, 40 c.c. for a Pott's fracture, and perhaps as much as 100 c.c. for a fracture of the femoral shaft. After injection gentle pressure is maintained for five to ten minutes, by which time muscular spasm disappears and the parts can be manipulated painlessly. If necessary a Steinmann's pin or a Kirschner wire can be inserted after suitable injections of novocaine.

The use of local anæsthesia in simple fractures, as compared with a general anæsthetic, has the following advantages :

(i) The fracture can be reduced single-handed.

(ii) Local anæsthesia can be used in patients unsuited for a general anæsthetic, which in the case of fractures is often of necessity deep and prolonged.

(iii) In cases associated with shock, pain is relieved and the fracture can be reduced without undue delay.

(iv) The patient can co-operate with the surgeon. Thus in the case of fracture of the humerus the patient can sit up, and even assist in the application of the splint.

(v) Reduction can be confirmed immediately by X-rays, and if necessary further manipulation can be performed before sensation returns.

(vi) Unless confinement to bed is necessary, the patient can depart as soon as satisfactory reduction is confirmed.

(vii) The patient may refuse a general anæsthetic. Local anæsthesia, as in any circumstance, is unsuitable for young children. Also, unless an X-ray is obtainable before reduction is attempted, a general anæsthetic is advisable, unless the exact site of the fracture can be determined with reasonable exactitude.

Spinal, regional, or local anæsthesia yields excellent results in reduction of fractures. Spinal anæsthesia, especially in the case of compound or complicated fractures, is ideal for fractures of the lower extremity, although local anæsthesia is adequate in simple cases. Similarly, compound fractures of the upper extremity can be dealt with after injection of novocaine into the brachial plexus.

In the case of fractures of the shaft of long bones, manipulation sometimes fails, and prolonged extension is then necessary. This can be obtained by means of adhesive strapping, or in the case of the lower limb, Beasley's ice-tong callipers may be used to grasp the femoral condyles. Preferably Steinmann's pin or Kirschner's wire is used to transfix the condyles, in the case of a fractured femur, or the os calcis if the tibia is fractured. Care must be taken that traction on a wire does not cause it to cut through cancellous bone, such as the os calcis. Sufficient weight is applied to stretch contracted muscles, and counter-extension may be obtained by raising the foot of the bed. X-rays, preferably portable, are used to gauge the results of extension.

(*b*) **Fixation.**—If reduction is satisfactory, the fragments are fixed until union has occurred, the length of time required depending on the individual bone and age of the patient. Thus the thick weight-bearing bones of the leg require a longer period of fixation than the arm or forearm bones, also fractures unite more quickly in children than in adults. The patient's weight and occupation also influence the time during which fixation is necessary.

Adequate fixation can also be obtained by a plaster casing, or by a variety of splints, but any apparatus applied must adequately control the fragments without risk of injury to the soft parts, such as pressure sores, or interference with the circulation.

Among other materials which are sometimes used for support may be mentioned Gooch splinting, and poro-

plastic material, which is softened by immersion in warm water, and which can then be moulded as desired. These supports are used according to the ingenuity of the surgeon and the local needs of the fracture.

The limb must be inspected frequently after manipulation and the application of splints or bandages, as further extravasation may occur, with consequent tightening of the bandages. This is particularly liable to occur in the case of fractures in the region of the elbow joint, which are put up in a flexed position. Blueness of the fingers, sluggish return of subonychial circulation following pressure on a nail, or diminution of the pulse, are indications of undue pressure. Immediate relaxation of bandages is essential, otherwise myositis fibrosa or even gangrene is liable to follow.

If there is no necessity for the patient to remain in bed, split plaster of Paris casing is very satisfactory, but this should not be applied until swelling has subsided, otherwise imperfect fitting will ensue.

In many cases, provided that fixation can be maintained, the patient is encouraged to use a fractured limb. This "functional activity during treatment" is strongly recommended by Lorenz Böhler of Vienna, and use of a limb during union of a fracture prevents atrophy of bone and muscles, and discourages troublesome stiffness and adhesions. Furthermore the patient is often enabled to continue his occupation, and the length of time necessary for recovery is shortened (fig. 624).

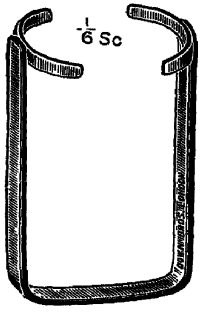

FIG. 624.—Bohler's malleable walking iron, for incorporation in a plaster cast.

(*c*) **Restoration of Function.**—Unless the patient is able to use the limb, massage should be commenced on the day following reduction of the deformity, provided that this entails no risk of displacing the fragments. Massage relieves pain, diminishes muscular spasm, and by improving the circulation encourages the absorption of exudates and maintains muscular tone, and must be applied by a properly trained person. If applied

too vigorously it may cause further oozing from torn muscles, etc., and tends to induce or maintain muscular spasm rather than relieve it. A good working rule is that massage should soothe and relieve pain, and if pain is caused or aggravated by the procedure, then massage should be modified or suspended.

Passive and, later, active movements are allowed as soon as possible, the actual time varying with individual fractures. Thus in the case of a fracture of the lower end of the radius, stiffness from adhesions in tendon sheaths is more to be feared than imperfect anatomical apposition of the fragments, whereas, in the case of a weight-bearing bone, correct alignment, maintained until it is secured, is highly desirable. Further details are mentioned in connection with individual fractures.

Complications of a Fracture

1. General

(i) **Shock.**—The degree of shock associated with a fracture depends on the size of the bone or bones affected, the temperament of the patient, and the associated circumstances. As with any injury, a severe lesion may pass almost unnoticed during a period of great excitement. Fracture of both femora is often fatal.

(ii) **Fat Embolism.**—A rare complication, which sometimes follows the shattering of a large bone, e.g. by a bullet or fragment of shell (page 83).

(iii) **Aseptic Traumatic Fever.**—This is due to absorption of fibrin ferment from extravasated blood, and resembles the fever which occurs in the case of any simple wound.

(iv) **Delirium Tremens.**—This condition, fortunately much rarer than formerly, may be divided into three stages.

(*a*) *Prodromal Stage.*—The first indications are usually noticeable about the third day, and consist of sleeplessness, semi-conscious muttering, anorexia, marked constipation, and tremors of the hands and tongue, which is heavily coated. The patient is restless, and the pulse usually shows considerable variations.

(*b*) *Stage of Violence.*—This stage either gradually follows the prodromal stage, or develops abruptly. In the latter case, calamities are likely unless the condition has been anticipated. The patient suffers from hallucinations, sometimes of persecution, or perhaps

with a reptilian background, and may inflict serious injuries on himself or others. Insensitiveness to pain is a marked feature, and the patient may drag himself along with a fractured leg trailing behind him. The patient's struggles and attempts to overcome restraint, combined with sleeplessness, result in exhaustion.

(*c*) *Stage of Exhaustion.*—This is characterised by extreme feebleness, and may terminate in coma and death. The pulse is raised, while the temperature varies, periodically becoming subnormal. The prognosis is improved if sleep can be induced without the aid of excessive drugging.

Treatment.—Delirium tremens sometimes occur in the most unlikely patients, but in cases where an alcoholic tendency is suspected, careful watch should be observed for the prodromal symptoms, as early recognition and appropriate treatment may prevent the onset of actual delirium and exhaustive struggles. Sedatives and aperients are indicated, and a moderate amount of alcohol is given, in the hope that it will prevent the onset of delirium. Precautions are taken to obviate further damage to the fracture, and if circumstances permit, a plaster of Paris casing should be applied. The patient must be under continuous supervision, with adequate assistance immediately at hand, and in the case of delirium supervening, control by means of a strait-jacket may be necessary.

(v) **Hypostatic Pneumonia.**—This condition is liable to occur in elderly patients who are confined to bed for more than a few days, particularly if they are "fat and wheezy."

(vi) **Crutch Palsy.**—All crutches should be supplied with a suitable hand-grip, so that weight is transmitted chiefly along the arms, and not by pressure on the axillæ. A drop-wrist, due to musculo-spiral involvement, has followed only four hours' use of crutches unsupplied with hand-grips.

2. Local

(i) **Bone.**—(*a*) *Mal-union.*—Although union in the correct alignment is always desirable, particularly in the case of weight-bearing bones, yet in some cases mal-union does not appreciably affect the function of a limb, e.g. most fractures of the clavicle unite in a faulty position, but the utility of the arm is unimpaired. If mal-union is likely to interfere with the function of a limb, manipulation may be attempted during the first month, while the callus is still soft. In later cases reconstruction of the fracture is sometimes necessary, or osteotomy may be performed.

(*b*) *Dis-union.*—This is a rare condition in which union is occurring in a satisfactory manner, but some grave constitutional disturbance, e.g. enteric fever, undermines the reparative powers of the patient, so that callus is absorbed.

(*c*) *Non-union.*—This term is applied to those fractures which, in the opinion of the surgeon, will not unite by the natural processes of repair. The condition includes absolute non-union, fibrous union, and pseudoarthrosis, in which a false joint is formed, the synovial membrane being represented by an adventitious bursa, which forms between the fragments (fig. 625).

Non-union is predisposed to by local and general causes. General causes include old age, debility from any cause, conditions which exercise a devitalising effect on the bone marrow, e.g. malaria,

FIG. 625.—A false joint following an ununited fracture of the shaft of the humerus. (R.C.S. 401.1.)

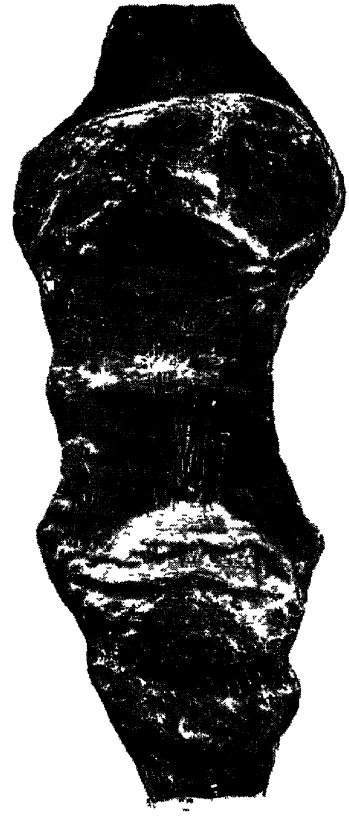

FIG. 626.—Old fracture of the patella. The fragments are united by a band of fibrous tissue. (R.C.S. 3519.1.)

syphilis, and some disorders of the central nervous system, such as tabes dorsalis.

Local causes are numerous, and infection is probably the commonest, associated as it may be with necrosis and sclerosis of the bone. Other causes include inefficient blood

supply, e.g. the neck of the femur (particularly if the retinacular fibres are torn), failure of apposition (such as commonly occurs in transverse fractures of the patella, fig. 626), interposition of soft parts, and inefficient fixation, which must be marked, as some fractures, notably of the ribs, unite firmly in spite of want of fixation. Tumours of bone predispose to fracture ; in the case of secondary carcinoma, union may occur, but a fracture caused by sarcoma will not unite.

TREATMENT.—This is first directed to any cause which is amenable to treatment, and if necessary the general health of the patient receives due attention. Locally, delayed union is combated by efficient reduction and immobilisation for a further period in plaster of Paris, or an accurately fitting splint. Various substances have been injected between the fragments in order to stimulate reaction, and in some cases a few c.c. of the patient's own blood appear to exert a beneficial effect. Bier's passive congestion may also be a useful stimulus to union.

If union does not occur, then operative measures are indicated, the simplest being exposure and fixation of the ends of the bone, which are "freshened" if necessary. Metal plates and screws exert a deleterious effect upon the vitality of the bone, and bone screws, plates, or pegs are preferable. The best method, if circumstances permit, is by means of an autogenous bone graft, which not only acts as an internal splint, but also brings healthy bone cells, which reinforce those in the devitalised bone. Thus an inlay graft from another bone is the most suitable line of treatment, as a sliding graft from the same bone will share to some extent the atrophy consequent on prolonged fixation of the fracture.

(*d*) *New-growth.*—Some surgeons consider that sarcoma occasionally results from a fracture, but the possibility of coincidence is always a difficult factor to eliminate.

(ii) **Muscle.**—If fracture occurs in a bone clothed with muscle, some matting of the muscular fibres is liable to occur as a result of organisation of extravasated blood and exudates, and the consequent liability to stiffness is com-

bated by massage and movements as soon as these procedures can be adopted without risk of displacement of the fragments.

Two additional complications in connection with muscles need special mention :

(*a*) *Myositis Fibrosa*.—Sometimes occurs in the calf muscles, following prolonged recumbency, but it is most commonly seen in connection with the flexor muscles of the forearm (*syn.* Volkmann's ischæmic contracture). The deformity is encouraged by excessive flexion, but may also follow pressure of extravasated blood in the flexor sheaths, and consequent interference with the normal supply of blood to the muscle fibres. Prophylactic measures include avoidance of circulatory disturbance, especially excessive flexion of the elbow joint. If swelling and induration of the forearm muscles is profuse, timely incisions into the sheaths of the muscles relieves tension and so permits restoration of venous drainage. If contracture has occurred, sliding the muscles from the internal condyle improves the condition.

(*b*) *Myositis Ossificans*.—Deposition of bone in a muscle consequent on a fracture most commonly occurs in the brachialis anticus (fig. 627), but other muscles occasionally affected are the quadriceps and adductors of the thigh. The condition is due to extensive laceration of periosteum and muscle. Displaced bone cells find an agreeable nidus in the blood extravasated in the muscle, and proceed to carry on their normal function of laying down new bone among the muscle fibres. After a period of four to six weeks an indurated mass is palpable in the muscle, and sufficient calcification will have occurred to be seen in an X-ray.

Massage and movements merely stimulate the osteoblasts to increased efforts, hence the limb should be kept at rest for at least six months. Localisation of the mass will then occur, and if sufficient disability then exists to warrant such a procedure, the misplaced bone can be removed without serious damage to the enveloping muscle.

(iii) **Joint.**—Either true or false ankylosis are liable to occur as a result of a fracture of the neighbouring bones.

TRUE ankylosis is usually of the fibrous variety, and is particularly liable to occur if the joint is implicated by the fracture, owing to organisation of blood. Limitation of movement may follow excess of callus formation, e.g.

FIG. 627.—Myositis ossificans of the brachialis anticus muscle, following a fracture of the shaft of the humerus.

fracture of the head or neck of the radius. Complete bony ankylosis can only occur when both or all the bones forming the joint are severely damaged.

FALSE ankylosis sometimes follows adhesions between muscle fibres, or fascial planes between the muscles. Myositis fibrosa has been referred to elsewhere. Limitation of movement as a result of adhesions of tendons in their sheaths is a complication particularly to be dreaded in the case of fractures in the region of the wrist or ankle, in which situations the tendons lie in close apposition with the bones. Thus, particularly in the case of a Colles' or Pott's fracture, early movements are imperative.

Osteoarthritis must be mentioned as a sequela of malunion of a fracture, particularly in the case of weight-bearing bones. Owing to alteration in the direction of the lines of stress, an undue strain is thrown on the joint, and

the penalty exacted for this abuse is early degeneration of the joint above the fracture. Thus mal-union of a fractured femur in youth or early manhood is liable to be followed by osteoarthritis of the hip joint in middle age.

(iv) **Nerves.**—Nerves, particularly those which lie adjacent to bones, are liable to be involved as a result of immediate injury by the jagged fragments, or some few weeks later by callus formation. The former is much the commoner, and appropriate tests should always be carried out when the patient is first seen in order to test the function of any nerve which may have been injured.

Nerves which are frequently injured at the time of the fracture are the ulnar, in the case of supracondylar fracture or separation of the lower epiphysis of the humerus, and the musculo-spiral (10 per cent. of cases), as it lies in its groove on the humerus. The median nerve is occasionally injured, as it lies in front of the elbow and wrist, in connection with fractures of the lower end of the humerus or radius, especially if associated with much deformity. The commonest nerve to be involved in callus is the musculo-spiral, partly on account of its close relationship to the humerus, and partly because perfect alignment in the case of the humerus is not always considered necessary, and consequently a considerable amount of callus is formed.

(v) **Blood-vessels.**—Arteries or veins are sometimes ruptured immediately at the time of the fracture. Extravasation of blood occurs, which, in the case of an artery, is liable to result in the formation of a false aneurism. If the arterial wall is only incompletely damaged the weakened wall may subsequently yield, with the formation of a true saccular aneurism.

Vessels are occasionally occluded by the pressure of displaced fragments, the classical example of this occurrence being pressure on the popliteal artery by the diaphysis of the femur in the case of separation of the lower epiphysis, which is displaced forwards.

(vi) **Skin.**—Pressure sores, as a result of the application of splints and plasters, should be avoided by reasonable care

and foresight, e.g. pressure over the tuber ischium resulting from the ring of a Thomas's splint is anticipated by accurate fitting and adequate padding. Leather rings and supports may be softened by the application of soap, and parts likely to exert pressure should be covered with chamois leather.

Extensive pressure sores are likely to occur under a plaster of Paris casing if bony prominences are ill-protected, or if pressure is allowed to indent the casing before the plaster has sufficiently set. Persistent localised pain, following the application of a plaster, should be investigated by removal of the plaster, or by cutting a window. If this step is not taken the gradual diminution of the pain should not lull the surgeon into a sense of false security, as it may in reality indicate the onset of gangrene. If infection occurs beneath a plaster it can be recognised by a local patch of warmth over the affected area. In neglected cases the presence of pus, or the odour emanating from beneath the plaster, leaves no doubt as to the presence of infection, even to the most casual observer !

(vii) **Infection.**—If the fracture is compound, and efforts to prevent infection are unsuccessful, then the general and local complications of infection supervene. Locally, necrosis of bone and delayed union are probable, and the surrounding soft tissues may be involved, e.g. secondary hæmorrhage, gas gangrene.

As a rule the general clinical manifestations of infection are not severe, as the open wound associated with a compound fracture provides an exit for inflammatory exudates.

More detailed accounts of the effects of local and general infection are to be found in the chapters dealing with the structures involved.

Indications for Operation

The indications for operative interference in connection with a fracture can be classified as immediate, intermediate, or remote. The first group includes those cases in which an emergency operation is necessary, the second comprises fractures which require operative interference after the

lapse of a few days, while remote indications include surgical measures devised to combat late complications. These indications only refer to fractures of bones of the limbs ; such conditions as fractures of the skull, spine, or pelvis are considered separately.

(i) **Immediate.**—(*a*) Complicated fractures, such as rupture of, or pressure on, the main vessels of a limb, may require operative interference in order to control hæmorrhage, or to diminish or obviate the risk of gangrene.

(*b*) Compound fractures, provided the condition of the patient is satisfactory, must be operated upon immediately in order to diminish the risk of infection. Each hour's delay allows infection to become more securely established, and if much blood has been lost or a tourniquet has been applied, then the devitalised tissues are particularly susceptible to bacterial invasion.

An anæsthetic is given, and, if necessary, the clothes are cut along the seams in order to expose the injury. The wound is temporarily covered with a gauze pad soaked in suitable antiseptic, such as 1 : 80 carbolic acid or 1 : 1000 flavine, and the surrounding skin cleansed with ether soap and spirit, a nail brush being used if necessary. The edges of the wound are then excised, and it is explored in order to secure hæmostasis, and any foreign bodies or fragments of bone detached from the periosteum are removed. Severely lacerated or grossly contaminated fascia or muscle is excised, and the wound cleansed with a suitable antiseptic, carbolic acid 1 : 20 being very efficient. Some surgeons prefer to smear the wound surface with B.I.P.P., but care must be taken not to leave more than a minimum of this preparation in the wound, as some patients display an idiosyncrasy towards iodoform, and vomiting, delirium and, later, pigmentation of the gums may result. The wound, having been sterilised as adequately as possible, is closed partially or completely according to circumstances. Thus, in the case of a severely contused and contaminated wound, particularly if circumstances have necessitated a few hours' delay, only a few stitches are inserted so that, if inflam-

matory exudates occur, they have a ready exit, and two or three days later secondary suture can be performed if conditions are favourable. In the case of more recent wounds with little contamination, adequate suturing may be performed with bright prospects of healing by first intention, and thus the compound fracture is converted into a simple one. It is often possible, during an operation on a compound fracture, to reduce the fracture openly by manipulation of the fragments, but no extensive separation of soft tissues is permissible in the presence of potential infection. Needless to say, no foreign bodies, such as plates or screws, should be used to maintain apposition, as infection is thereby rendered almost inevitable, resulting in devitalisation or even necrosis of the bone, and a sinus which discharges until the offending metal is removed. After operation the limb is suitably immobilised, with traction if necessary.

(*c*) If a compound fracture is associated with extensive damage to the soft parts, particularly the main vessels or nerves, then immediate amputation may be the most desirable line of treatment. This is especially the case in the lower limb, which possesses less vitality than the arm.

(ii) **Intermediate.**—(*a*) Complicated fractures, particularly those in which a large joint or an important nerve is involved, usually require operative interference. In the case of joint involvement, the advantages of operation are twofold. Firstly, blood-clot can then be evacuated, so that its organisation into troublesome fibrous adhesions is prevented, and secondly, mechanical fixation of the fragments is usually possible, so that early movements can be safely instituted without the risk of displacement recurring. For example, a fracture of the outer tuberosity of the tibia is exposed by a lateral incision, the blood in the knee joint evacuated, and lavage performed with saline solution if necessary. A bone peg or screw is readily inserted, so that the tuberosity is firmly held in its normal position, and the tibial plateau thus restored. Passive movements of the knee joint are commenced the following day, and a full range of movement can confidently be expected. Injury to a nerve at the time

of fracture may be incomplete or complete. In the former case, recovery usually follows, but in complete injuries it is impossible to be certain whether the lesion is physiological, (due to compression or concussion), or anatomical, in which case the nerve is completely divided. Physiological lesions are much the commoner, an intraneural hæmorrhage being the usual condition, due to partial rupture of the nerve sheath, and consequent extravasation of blood. However, if the functions of the nerve are completely absent at the end of two weeks, it must be assumed that it is anatomically divided, and exposure, with a view to suture, is advisable. It is, of course, of paramount importance to test the functions of all nerves possibly implicated before immobilising the limb, so that involvement is not overlooked. Paralysed or paretic muscles must be supported during the period which elapses while evidence of recovery is awaited.

(*b*) In some cases, in spite of adequate attempts at reduction, mal-position persists. This is a common occurrence in connection with separation of an epiphysis, owing to the jagged diaphysial fragment piercing and becoming buttonholed by the periosteum. It is becoming increasingly recognised that a good anatomical result is necessary for perfect physiological function, and this is particularly so in the case of weight-bearing bones.

In some situations manipulation is unlikely to overcome the existing deformity, e.g. fracture of the shafts of the radius and ulna at the same level. Unless adequate reduction is obtained, cross-union is likely to occur with consequent limitation of pronation and supination.

Operations designed to secure adequate reduction are usually performed a few days after the accident. This interval allows the lymphatic circulation to become re-established so that any organisms which accidentally gain admission to the wound during operation can be dealt with efficiently. If operation is delayed beyond this period, organisation of extravasated blood and exudate, and, at a later date, the formation of callus, add considerably to the difficulty of apposing the fragments. Moreover, bony

spicules are absorbed, and the ends of the fragments become rounded, which mitigates against interlocking of the fragments. When operation is performed at the expiration of a few days, the fragments usually dovetail in a sufficiently firm manner to render mechanical fixation unnecessary, otherwise wires, screws, or plates may be utilised in order to fix the fragments, especially in such situations where early movements are desirable. Bone plates and screws (fig. 628) are much to be preferred to those composed of metal, which frequently cause absorption of adjacent bone and consequent loosening of the screws. In some cases actual infection occurs, either as a result of some flaw in the operative technique, or at a later date as a



FIG. 628.—Ox bone plates and screw.

result of blood-borne infection, e.g. following boils or tonsillitis. Removal of the foreign bodies is then necessary.

(*c*) Small bones and bony processes are best treated by operation, provided sufficient separation exists to render impairment of function probable. Thus a transverse fracture of the patella, fracture of the olecranon process, or avulsion of the great tuberosity of the humerus are treated by wiring or pegging, provided that the general condition of the patient is satisfactory.

(iii) **Remote.**—(*a*) In some cases of severe multiple injuries, a fracture must, of necessity, be merely supported until the condition of the patient permits of attention being directed towards its treatment. If extravasated blood and inflammatory exudates have begun to organise, attempts

at manipulation are unlikely to be successful, and exposure and fixation of the fragments will be necessary if good alignment is to be obtained.

(*b*) Late complications sometimes arise in connection with the soft structures. In connection with muscles, myositis fibrosa and ossificans have already been mentioned. Involvement of a nerve in callus is uncommon, and if a mixed nerve is implicated, paræsthesia, followed by pain, and finally muscular paresis result. The affected nerve is exposed, freed from callus, and buried in adjacent muscle. Rarely an aneurism, arterial or arterio-venous, demands surgical interference.

(*c*) Non-union or mal-union may occur. The causes and treatment of the former condition, in connection with long bones, have already been discussed. In addition, troublesome non-union commonly occurs in the scaphoid bone of the wrist. This non-union usually results from failure to recognise the existence of the fracture, the condition being treated as a "sprained wrist." If pain and weakness persist in spite of prolonged and adequate fixation, then the fragments should be pinned together with a small bone peg.

Mal-union may require surgical attention, e.g. in the case of a Pott's fracture-dislocation, reconstruction of the fracture with adequate reposition is sometimes necessary, or an osteotomy of the tibia is sometimes performed in order to correct eversion.

Special Fractures

Face and Jaw

The **Superior Maxilla** is fractured either as a result of a direct localised blow, or a portion of the alveolar border is broken off in efforts to extract a tooth. In the former case comminution is probable, and the fracture is frequently compound, on account of involvement of the maxillary antrum. If the fracture extends to the alveolar border, crepitus is usually obtainable. Treatment consists in the application of lead lotion in order to discourage hæmorrhage, mouth-washes, and nasal irrigation, while if the alveolar border is involved a dental splint may be advisable.

Complications which sometimes follow are extensive extravasation of blood, surgical emphysema, infection, necrosis of bone, and aspiration pneumonia.

The **Zygomatic Arch** may be fractured and depressed by a direct blow. Unsightly deformity results, and anæsthesia of the cheek may occur owing to pressure on the infraorbital nerve. If the arch cannot be elevated by digital pressure from within the mouth, a small incision is made over the depressed bone, through which a blunt hook is introduced. The hook is manipulated around the arch, which is then drawn forwards into position. If this procedure fails the lip is everted, and a small incision made through the reflection of mucous membrane at the junction of the cheek and gum, through which a blunt instrument is passed, e.g. curved scissors. The instrument is manipulated so that it passes between the arch and the superior maxilla, and leverage is then applied so as to elevate the bone. Some extravasation of blood results, but is uneventfully absorbed. Reposition of the depressed arch should always be performed, otherwise the cheek remains permanently flattened.

The **Nasal** bones are commonly fractured as a result of direct violence. The fracture usually occurs near their lower margin, but in more severe injuries the root of the nose may be driven in towards the base of the skull. In these cases the septum is commonly fractured and displaced. Epistaxis, considerable swelling, and surgical emphysema may result. Consolidation speedily occurs, hence replacement must be

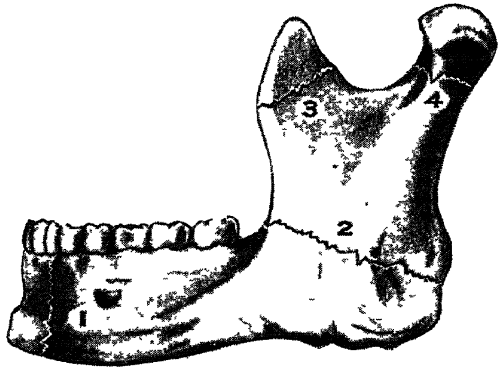

FIG. 629.—Lower Jaw.

1. Commonest site, anterior to the mental foramen, through the canine fossa.
2. Through the angle or ascending ramus.
3. Coronoid process.
4. Neck of condyle.

undertaken without undue delay. Under anæsthesia a pair of rubber-covered sinus forceps are introduced, one blade into either nostril, and the fragments levered into position. The nasal cavities are packed with gauze soaked in carbolised paraffin, or other suitable antiseptic. The packing is

changed daily, the nasal cavities being irrigated at the same time, and consolidation occurs in about ten days.

The **Inferior Maxilla** is usually fractured in one of four situations (fig. 629).

(i) The coronoid process is sometimes fractured, diagnosis only being possible by means of a radiograph.

Only slight displacement occurs, as the temporal muscle is inserted over the inner surface of the process and so retains the fractured portion in position. Treatment consists in supporting the jaw by means of a four-tailed bandage for three weeks.

(ii) The neck of the condyle is occasionally fractured, in which case it is displaced forwards and inwards by the pull of the attached external pterygoid muscles. Localised pain occurs on movements of the jaw, and crepitus is detected by the patient or surgeon. Removal of the condyle shortens the period of disability, and obviates the likelihood of limitation of movement.

(iii) The ascending ramus may be fractured, usually in the region of the angle of the jaw. Little displacement occurs, as the masseter on the outside and internal pterygoid muscle on the inner aspect sandwich the fragments between them. The injury is suspected on account of persistent localised pain, and is confirmed by an X-ray. Treatment consists in supporting the jaw for three weeks.

(iv) The body of the jaw is the part most commonly fractured, usually as the result of a blow with a fist. The fracture frequently occurs in the region of the canine fossa, the bone being weakened by the depth of the socket for the canine tooth. As the mental foramen is situated posteriorly, the inferior dental nerve and vessels are not implicated. Occasionally the fracture is bilateral, in which case the central portion of the jaw is displaced downwards by the anterior belly of the digastric muscle and the muscles attached to the genial tubercles. Owing to the firm attachment of the muco-periosteum to the bone, the fracture is almost always compound.

Diagnosis is usually obvious, as speech and swallowing are

impaired. Blood-stained saliva trickles from the mouth, and irregularity of the line of the teeth is apparent. Crepitus can be elicited if considered necessary.

Treatment consists, in the first instance, in supporting the fracture by means of a four-tailed bandage. This consists of about 3 ft. of 4-in. bandage, which is divided at either end so as to leave 6 in. intact in the centre. A small aperture is cut to accommodate the symphysis menti. The centre of the bandage is applied to the jaw, and the two lower tails are then carried upwards and tied across the summit of the head, while the two upper tails are carried backwards and tied beneath the occiput. The four tails are then tied together in order to prevent the bandage slipping.

As the fracture is compound, infection from the mouth is likely, particularly if pyorrhœa or infected teeth are present. Warm antiseptic mouth-washes are therefore used almost continuously. The diet obviously must be confined to fluids, which are taken through a rubber tube until sufficient consolidation occurs.

Fixation of the fragments should be undertaken by the dental surgeon, the most satisfactory appliance being an interdental splint which fits over the teeth adjacent to the fracture. A corresponding splint is fitted to the upper jaw, so that fixation of the two splints secures immobilisation. Any obviously septic teeth, or an interposed tooth, are removed when the splint is being fitted.



FIG. 630.—Clavicle.

1. Commonest site, at junction of outer flattened and inner pyramidal portions.
2. Between the conoid and trapezoid ligaments
3. Acromial tip.
4. Inner extremity, between the rhomboid ligament and sterno-clavicular joint.

Wiring of the teeth together, or the fitting of wire splints, is much less satisfactory than the intermaxillary splint.

Complications of fracture of the lower jaw are mainly due to infection. Thus necrosis of bone and delayed union are not uncommon, while submaxillary cellulitis may require operative interference. Aspiration pneumonia is a grave danger, particularly in old or alcoholic patients with pronounced dental sepsis.

Upper Extremity

The **Clavicle** is the commonest bone to fracture, indirect violence being the usual cause. Fractures most frequently occur in one of the following four situations (fig. 630) :

(i) *Acromial Tip.*—This fracture is due to direct violence, such as a sharp blow on the shoulder. Separation occurs owing to contraction of those fibres of the deltoid muscle which are attached to the fragment. If strapping is unsuccessful in retaining the fragment in position and relieving pain, then an operation should be undertaken, and the tip screwed or pegged in position.

(ii) *Acromial End.*—This fracture is also due to direct violence, but displacement is slight, as the fracture occurs between the trapezoid and conoid ligaments, and thus the two fragments are held in position. Localised pain and tenderness suggest the presence of the fracture, which often requires a radiograph for confirmation. The application of strapping and a sling for three weeks is usually sufficient.

(iii) *Sternal End.*—This is the least common situation for fracture, and as a rule little deformity occurs, since the small inner fragment is steadied by the sterno-clavicular ligament, and the outer fragment is anchored to the junction of the first rib and costal cartilage by the rhomboid ligament. The application of a sling for two or three weeks is usually all the treatment that is necessary.

(iv) *Greater Convexity.*—This is an exceedingly common fracture, and is usually due to indirect violence, such as falls on the hand or shoulder. It is frequently met with in the hunting field and on the football ground.

A greenstick variety occasionally occurs in children and

is liable to be overlooked, but the definite localised tenderness and reluctance to move the arm should arouse suspicion. The frequency of fracture at this site is accounted for by the fact that it is the junction of two curves, also the bone on the outer side is flat and the inner side pyramidal, hence the internal architecture undergoes adjustment at this site. Subsidiary reasons are that the bone is weakened in this situation by the groove for the subclavius muscle, and also by the foramen for the nutrient artery.

Diagnosis is usually obvious, even at a distance, as the patient is seen supporting the elbow on the injured side with the opposite hand, and flexing his head to the affected side in order to relax the sterno-mastoid muscle. The outer fragment is displaced in three directions—downwards by gravity, forwards by the pull of the pectoral muscles, and inwards by contraction of the muscles inserted into the bicipital groove, notably the latissimus dorsi. The inner fragment is tilted upwards to a slight extent by the sterno-mastoid muscle, but the obvious projection of its outer end is chiefly due to displacement downwards of the outer fragment.

If displacement is slight, all that is necessary is to place a pad in the axilla, steady the fragments by passing strapping over the site of fracture, and apply a sling for three weeks. If deformity is pronounced, then various methods have been utilised, among which may be mentioned the following :

If even slight deformity is undesirable, the patient should be confined to bed for three weeks, with a small sandbag between the scapulæ, and the arm bandaged to the side. Strapping is applied over the fragments for additional support, and a pad should be retained in the axilla.

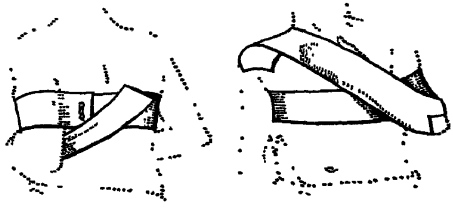

FIG. 631.—Sayre's method of strapping applied for fracture of the left clavicle.

If the patient prefers ambulatory treatment at the cost of some deformity, then Sayre's method is very suitable (fig. 631). A pad of

cotton-wool, sprinkled with boric powder, is placed in the axilla. This acts as a fulcrum, and levers the external fragment outwards, thus correcting inward displacement. A 3-in. strip of adhesive strapping is applied so as to encircle the middle of the arm, the loop being fixed by safety-pins, and the remainder of the strapping is carried around the back to the opposite side of the spinal furrow. The loop acts as a fulcrum, so that, when the elbow is brought forwards, the outer fragment is carried backwards, thus reducing the anterior deformity. At the same time the elbow is pushed upwards, so as to correct the downward displacement due to gravity. The arm is fixed in this position, i.e. with the elbow carried forwards and pushed upwards, the forearm resting on the opposite side of the chest by means of a second strip of strapping, which passes from the opposite clavicle down the back of the hand and forearm, under the elbow, and upwards along the back of the arm. An aperture is cut to accommodate the olecranon process, care being taken that the edge does not press upon the ulnar nerve. A broad bandage is then applied to the arm and chest. After two weeks the strapping is removed, and replaced by a sling, movements being gradually regained.

Some degree of mal-union is the usual result, but no disability results. In the case of gross mal-union, excessive drooping of the shoulder girdle may cause traction on the inner cord of the brachial plexus, which becomes stretched over the normal first rib. Thus similar features are produced to those caused by a cervical rib. Reconstruction of the fracture or excision of part of the first rib may be necessary in order to relieve nervous symptoms. If fracture of the clavicle is caused by direct violence, the subjacent structures are sometimes injured, e.g. the subclavian vessels, brachial plexus, or pleura. In cases where fracture is due to indirect violence, these structures are protected by the subclavius muscle, and prolongation of deep cervical fascia into the axilla, which in this situation consists of a dense felted membrane.

Fractures of the **Scapula** occur in connection with the coracoid process, acromion process, neck, or body (fig. 632).

(i) The *coracoid process*, on account of its protected situation and sturdy structure, is rarely fractured. The kick from a badly held gun, or other severe localised blow, occasionally results in fracture. Owing to extensive

ligamentous attachments, only slight displacement of the fragment is possible, and elevation and fixation of the arm for two or three weeks is sufficient.

(ii) The *acromion process* may be detached by localised direct violence. Crepitus is obtainable if a sufficiently large fragment is detached. Owing to the attachment of the trapezius and deltoid muscles, separation is usually slight, but if troublesome the detached fragment should be fixed in position by a screw or peg.

(iii) The *neck* of the scapula may be fractured through the articular surface, a small fragment, usually including the origin of the long head of the triceps, being separated downwards. Fracture also occurs through the anatomical neck, i.e. running downwards from between the base of the

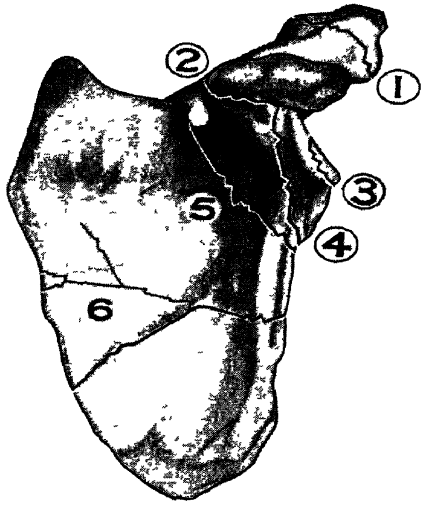

FIG. 632.—Scapula.

1. Acromion process.
2. Coracoid process.
3. Portion of glenoid fossa.
4. Anatomical neck.
5. Surgical neck.
6. Stellate fracture of the body.

coracoid process and the glenoid fossa, or through the surgical neck, in which case the fracture commences above in the suprascapular notch. In either case the articular surface is displaced downwards by the weight of the arm. On inspection some flattening of the shoulder is apparent, which superficially simulates dislocation of the joint; however, reposition is easy, but the deformity recurs when support is withdrawn. In some instances dislocation of the shoulder and other injuries are associated.

Treatment consists in elevating the shoulder by means of a large axillary pad or other suitable support, the arm being then bandaged to the side for three or four weeks.

(iv) Fractures of the *body* of the scapula are caused by severe and direct injury. Any degree of damage is liable to result, from a simple crack to a star-shaped comminution. In any case, little separation occurs owing to widespread muscular attachments, although extensive bruising or a large hæmatoma commonly co-exists. Treatment consists in the application of cooling lotion and support by strapping

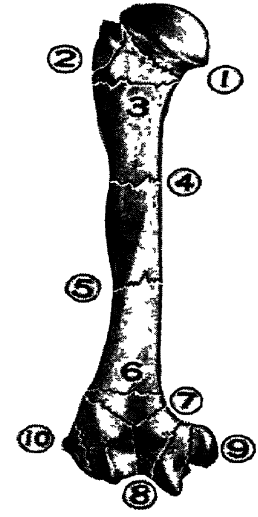

FIG. 633.—Humerus.

1. Anatomical neck.
2. Greater tuberosity (the smaller tuberosity is omitted).
3. Surgical neck.
4. Shaft above the insertion of the deltoid.
5. Shaft below the deltoid.
6. Supracondylar.
7. Y-shaped into the elbow joint.
8. Internal condyle.
9. Internal epicondyle.
10. External condyle.

and a sling. Evacuation of a hæmatoma is sometimes desirable.

Fractures of the **Humerus** (fig. 633).

(i) *Upper End.*—The *anatomical neck* is rarely fractured as a result of direct violence. Extensive effusion occurs, and although crepitus can usually be detected, the exact diagnosis is uncertain without a radiograph.

If complete detachment has occurred, reposition is difficult owing to the impossibility of controlling the loose head of the bone. Should reduction be unsatisfactory, and a full range of movement is desirable, then the head of the bone should be removed. Pegging it back into position results

in callus formation, especially if early movements are instituted in order to prevent stiffness of muscles.

The *surgical neck* is commonly fractured as a result of falls on the shoulder, and this fracture may complicate a dislocation of the shoulder. The upper fragment is abducted by the supraspinatus muscle, while the shaft of the bone is drawn inwards by the muscles inserted into the bicipital groove, and upwards by the deltoid, triceps, and biceps. Extensive extravasation occurs, which confuses the diagnosis, but the round contour of the shoulder remains (fig. 679), and the head of the bone can still be felt under the acromion process. The elbow is held away from the chest, and the line of the shaft, when prolonged upwards, passes internal to the glenoid fossa. Crepitus is obtained unless impaction is present, in which case the diagnosis is suggested by local tenderness and shortening of the arm, as measured from the acromion process to the external condyle.

Treatment consists in reduction under anæsthesia and fixation of the arm in the abducted position with an axillary support. If reposition is unsatisfactory, the patient should be confined to bed, with the arm fixed in a Thomas's splint and weight-extension applied, the strapping being carried up the arm to just below the site of fracture. Should the position still be unsatisfactory, and if the age and occupation of the patient demand the minimum of disability, then operation should be performed. The fracture is exposed by an incision which passes between the deltoid and pectoralis major, the cephalic vein being displaced inwards. The fragments are cleared of soft parts, and firm interlocking often renders the use of mechanical fixation unnecessary. In the case of a fracture complicating a dislocation, the head of the bone can be controlled readily by means of a screw-driver, which is thrust into, and so impales, the fragment. Leverage can be exerted readily and the dislocation reduced, after which attention is directed to reposition of the fracture.

Injury to nerves, particularly the circumflex and musculo-spiral, is an occasional complication.

Either *tuberosity* may be avulsed, the greater particularly in association with dislocation of the shoulder joint. If considered necessary, the avulsed fragment is exposed and pegged back into its original position.

Separation of the epiphysis occurs between the ages of 6 and 20. It is uncommon, owing to the conical shape of the diaphysis, which fits into the correspondingly cup-shaped epiphysis. Displacement is sometimes partial, and can occur in any direction. The signs resemble those of fracture, but the age of the patient and soft character of the crepitus are of assistance in distinguishing the conditions. Accurate reposition is essential, otherwise limitation of movement is probable, and also interference with growth, particularly in young children. Manipulation often fails if separation is complete, as sometimes the cup-shaped epiphysis lies in such a position that it is impossible to appose the conical diaphysis ; while in some incomplete cases the diaphysis protrudes through the periosteum and so becomes button-holed. In either case, the bone should be exposed by operation and manipulation under direct vision, or, in incomplete separation, division of periosteum will permit of easy reduction.

(ii) *Shaft.*—Fractures of the shaft of the humerus are usually easily recognisable, and deformity varies with the site of the fracture. If above the deltoid muscle, the upper fragment is drawn inwards by the muscles inserted into the bicipital groove, while the lower fragment is drawn outwards by the deltoid and upwards by the biceps and triceps. If fracture occurs below the deltoid, then the upper fragment is displaced outwards by the deltoid, and the lower inwards and upwards.

Immediate injury to the musculo-spiral nerve occurs in about 10 per cent. of cases, but involvement in subsequent callus formation is a rare event. Myositis ossificans developing in the brachialis anticus, and non-union, are other not uncommon complications.

Treatment consists in manipulation in order to restore alignment, and if this is satisfactory, all that is necessary

is to encircle the arm with Gooch splinting and bandage the arm to the side. As an alternative, a light plaster of Paris casing is utilised, particularly if frequent adjustments are inconvenient.

If abduction is desirable, an aeroplane splint may be used, which consists of three segments in three planes, one of which is applied to the chest wall, a second supports the arm in right-angled abduction, and the third supports the fore-

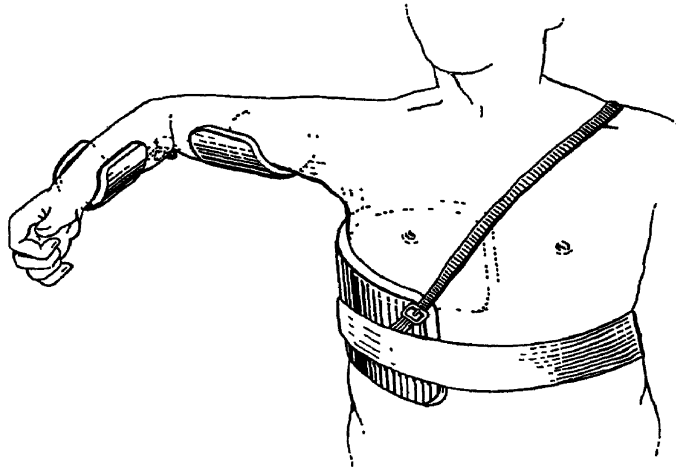

FIG. 634.—A type of aeroplane splint for fractures of the upper end of the humerus.

arm at right angles to the arm (fig. 634). The advantage of this splint is that complete abduction is maintained, and adduction is readily regained. The disadvantages are that it is cumbersome, and internal rotation of the lower fragment is liable to occur.

If manipulation fails to restore alignment in a satisfactory manner, then extension must be applied. This is best obtained by means of a small Thomas's splint. The patient is confined to bed, and the splint applied with adequate extension, counter-pressure being obtained by apposition of the ring with the axilla. The limb is supported by pieces of rubber or flannel clipped to the bars of the splint, and supination of the forearm prevents internal rotation of the lower humeral fragment. The carrying angle is preserved

by approximating the lower fragment to the inner bar of the splint.

Extension can also be obtained by means of Sir Robert Jones's flexed arm splint, which is a modification of Thomas's splint (fig. 635). The ring is set at right angles to the lateral irons, which are flexed to a right angle. A prolongation of the irons in the region of the elbow joint allows for fixation of strapping and consequent extension. The strapping is applied to the arm, and is fixed to the prolongation by means of rubber bands or metal springs. The forearm is maintained in a position of supination, and thus internal rotation of the lower fragment is obviated.

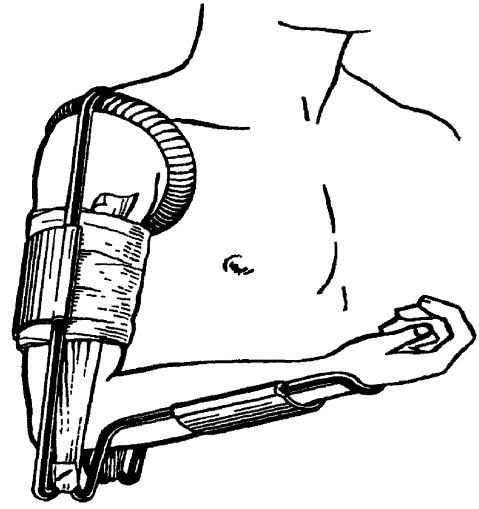

FIG. 635.—Sir Robert Jones's splint for fractures of the humeral shaft.

Middeldorpf's triangle, formerly much in vogue, should never be used, on account of the likelihood of œdema of the hand, and internal rotation of the lower fragment.

In cases where manipulation and extension fail to secure efficient reduction, operation must be considered, if adequate function, in accordance with the patient's age and occupation, is desirable.

(iii) *Lower End.*—Fractures of the lower end of the humerus are either supracondylar, fissured into the elbow joint, involve either condyle, or result in separation of the epiphysis.

Supracondylar fractures are usually due to falls on the hand. The lower fragment is displaced backwards, and is pulled upwards by the triceps. If lateral displacement occurs as well, it is usually in an outward direction. The condition has been mistaken for a posterior dislocation

of the elbow joint, but the following points of distinction should prevent error :

(*a*) In the case of fracture the normal relationship of bony points around the elbow is unaltered.

(*b*) Measurement from the acromion process to the external condyle is shortened in a fracture, as compared with the opposite arm.

(*c*) The anterior projection of the lower end of the upper fragment forms an obvious swelling or is palpable in the case of a fracture, while if a dislocation has occurred, the olecranon process is unduly prominent.

(*d*) A fracture can usually be readily reduced, provided the patient tolerates this procedure, but the deformity recurs.

(*e*) Crepitus is obtainable if a fracture is present.

In cases seen after a few hours' delay, extensive extravasation masks many of the above signs, and a radiograph is necessary for accurate diagnosis without discomfort to the patient.

Treatment consists in reduction under anæsthesia. Steady traction is exerted on the elbow, which is then flexed. The limb is then bandaged in flexion, which may be increased in two or three days as swelling diminishes. Reposition is confirmed by an X-ray, preferably stereoscopic, as the lower end of the humerus is obscured by the radius and ulna. If reduction is inefficient a further attempt should be made. If this fails, then weight-extension or open operation should be considered.

Continuous care must be exercised in observing the circulation of the limb. The extravasation already present in the antecubital fossa, possibly reinforced by that caused by additional trauma during manipulation, is liable to interfere with the circulation of the forearm. Hence the radial pulse and subungual circulation are carefully noted, and impairment of either is the signal to reduce the angle of flexion, otherwise a grave risk is incurred of the development of ischæmic contracture of the flexors of the forearm. In the flexed position the stretched triceps then acts as a posterior

splint, and extension is an easier movement to regain than the power of flexion.

T- *or* Y-*shaped fractures* are usually the result of a fall on to the elbow. If complete separation has occurred, crepitus is usually obtained, and in any case involvement of the articular surface results in the elbow joint becoming distended with blood.

If no local nor general contra-indication exists, operation should be performed so that blood can be removed from the joint and the fragments fixed in position.

Separation of the lower epiphysis frequently occurs, and it is the commonest epiphysis in the body to separate. The line of separation, however, more commonly occurs on the diaphyseal side rather than actually through the epiphyseal cartilage. This accident can occur at any age up to 16 or 18. At the age of 5 or 6 years the centre for the internal epicondyle appears, this centre remaining separate from the main epiphyseal mass, until about two years before union with the shaft. Hence from about 6 years until 16 separation does not include the epiphysis for the internal epicondyle.

The signs and symptoms closely resemble those of a supracondylar fracture, with the exception that crepitus is softer. Treatment is conducted on similar lines, accurate reposition being essential, as any initial deformity may be magnified as growth continues. Particular care should be taken to maintain the "carrying-angle." Should cubitus varus subsequently develop, the groove for the ulnar nerve on the internal condyle of the humerus acts as a pulley, and constant friction is then likely to cause a localised patch of fibrosis in the ulnar nerve, and increasing paresis of the corresponding muscles.

Reduction by manipulation commonly fails, owing to the jagged diaphysis buttonholing the periosteum. A posterior incision exposes the site of injury, and after enlarging the buttonhole reduction is simple. Firm interlocking can usually be obtained, and if mechanical fixation is necessary, the epiphyseal cartilage must not be damaged, and a plate

or other apparatus must be removed when union has occurred, otherwise growth will be impaired.

Fractures of the *condyles* are due to direct injury, and the elbow joint is implicated in both cases. Fracture of the internal *epicondyle*, or separation of the epiphysis occasionally occurs, and does not involve the joint. If the joint is affected, operation should be performed so that blood may be removed, and the fragment of bone is fixed in position. Fractures of the internal condyle are sometimes associated with injury to the ulnar nerve.

Fractures of the **Radius** are common (fig. 636).

(i) Fractures of the *head or neck* occasionally occur, the former frequently being associated with injury to other

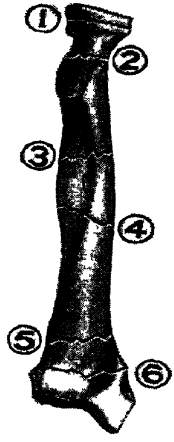

FIG. 636 —Radius.

1. Transverse fracture of head.
2. Transverse fracture of neck.
3. Shaft, above pronator radii teres
4. Shaft, below pronator radii teres.
5. Chauffeur's fracture.
6. Colles's fracture.

bones forming the elbow joint. The type of fracture and position of the fragments in the case of fracture of the head depend on the direction and force of the violence, but unless a fragment is completely detached displacement is slight, as the orbicular ligament prevents marked separation. If the patient is young and healthy, the best treatment to adopt is excision of the head of the bone through an incision situated posteriorly in order to avoid the posterior interosseous nerve. Unless removal is undertaken, subsequent callus formation is likely to limit pronation and supination.

Fracture of the neck of the bone is less common, and as the lesion occurs below the attachment of the orbicular ligament

deformity occurs, the lower fragment being drawn forwards and upwards by the biceps muscle. If the forearm is gently rotated, it is found that the head of the radius remains stationary. Treatment consists in fixing the arm in flexion and supination in order to relax the biceps muscle.

(ii) The *shaft* of the radius is fractured either above or below the pronator radii teres muscle. If above the insertion of this muscle, the upper fragment is supinated by the biceps, while the lower portion is pronated by the pronator radii teres and the pronator quadratus. If an unimpacted fracture occurs below the middle of the shaft, then the upper fragment is in a position of mid-supination, as the position is influenced by both the biceps and pronator radii teres, while the lower fragment is pronated by the quadrate muscle. These positions are merely of anatomical interest, as in all cases treatment consists in fixation in complete supination, which is best obtained by means of a posterior gutter splint, attention being directed towards the prevention of pronation, which is constantly liable to occur. In the case of simple fractures, a light plaster of Paris case may be applied from above the elbow to include the palm of the hand and ball of the thumb. This is applied for three weeks, movement of the fingers and thumb being carried out daily. A special variety of fracture of the radial shaft is that known as chauffeur's fracture, which is due to sudden hyperextension of the wrist as a result of a "backfire." Some cases are possibly due to a revolution of the starting-handle, which violently strikes the back of the wrist, this type therefore being due to direct violence.

The fracture occurs in the lower 3 in. of the radius, and may implicate the joint. Impaction does not occur, otherwise treatment is similar to that described in connection with Colles's fracture.

(iii) Fractures of the *lower end* are common, the most important being Colles's fracture. This fracture commonly occurs in old ladies who trip and fall on the outstretched hand. The lesion occurs from ½ to 1 in. above the wrist joint, and either the styloid process of the ulna is avulsed,

or the internal lateral ligament of the wrist joint is ruptured. The lower fragment of the radius is displaced backwards and outwards, and also rotated, so that the articular surface looks backwards and outwards, i.e. it is both displaced and rotated in the direction of the violence. In addition, impaction usually occurs, so that the lower fragment is also displaced upwards. On inspection, the hand is displaced towards the radial side, and a "dinner fork" deformity is produced by contraction of the flexors of the fingers, which are more powerful than the extensors. On palpation the radial styloid process, instead of being ½ in. below that of the ulna, is on a level with it, or if marked displacement has occurred, even higher. In some cases a projection may be felt on the back of the wrist caused by the lower end of the upper fragment of the radius (figs. 637, 638).



FIG. 637.—Chauffeur's fracture, non-impacted, in an adolescent subject.

FIG. 638.—Colles's fracture, the ulnar styloid process is avulsed and on the same level as that of the radius.

Smith's fracture is due to falling with the hand behind the body, and the deformity is the reverse of that which occurs in Colles's fracture.

Treatment consists in early reduction with disimpaction. Gas anæsthesia is sufficient, and either the surgeon grasps

the patient's hand as for a hand-shake, or preferably applies direct pressure to the lower end of the radius with the ball of his thumb, the other hand firmly grasping the forearm. The lower fragment is manipulated in a forward and inward direction, traction being exerted simultaneously. In some cases firm impaction resists mere traction, in which case a sudden jerk in the direction of the deformity snaps some of the interlocking bony spicules and reduction can then be accomplished. It must be emphasised that subsequent disability is more likely to result from adhesions between the tendons and their sheaths than from imperfect correction of the deformity. Early active movements are therefore essential, and these can best be obtained by the use of a plaster cast. A plaster slab is applied directly to the skin along the back of the hand and forearm. It is moulded to the limb, and extends distally to just short of the heads of the metacarpals. When the slab has set it is fixed to the limb with a flannel bandage. A confirmatory radiograph is taken twenty-four hours later, and if the position is satisfactory the slab is fixed in position with a plaster bandage (fig. 639). The delay obviates the possibility of swelling within the plaster cast. The patient is encouraged to use the limb, and three weeks later the cast is removed. Full return of function is usually obtained after a further three or four weeks.

FIG. 639.—A plaster cast applied for Colles's fracture.

If after reduction it is found that the fragments are apt to slip, fixation of the hand in a partially flexed position is advisable, so that the extensor tendons can act as splints and so assist in maintaining correction. The drawback to this position is that movements of the fingers are hampered.

Satisfactory results are often obtained after the use of a Carr's splint, but the plaster cast is preferable in that the

necessity for readjustments is excluded, and full movements of the metacarpal-phalangeal joints are obtainable.

In the case of feeble old women, disimpaction is unnecessary, all that is needed being a temporary support to the wrist and encouragement regarding movements of the fingers. In fact, medical advice is not always sought, the condition being regarded as a sprain, and the result in these cases is usually very satisfactory.

Separation of the lower epiphysis of the radius can occur between the ages of two and twenty, most commonly in the early years of the second decade. The epiphysis is displaced backwards, and the deformity and treatment are

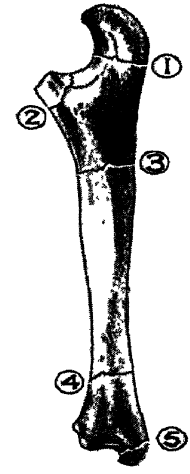

Fig. 640.—Ulna.

1. Olecranon process.
2. Coronoid process, which may complicate dislocation of the elbow joint.
3. Upper third of shaft, which may be associated with dislocation of the head of the radius.
4. Lower part of shaft, as from direct violence.
5. Styloid process.

similar to those already described in the case of Colles's fractures. If reduction is unsatisfactory operation must be performed, so that the periosteum through which the diaphysis protrudes can be divided.

Fractures of the lower end of the radius and separation of the epiphysis, if associated with marked deformity, are liable to be accompanied by stretching, or hæmorrhage into the sheath of the median nerve. Evidence of nerve injury should be sought before reduction and immobilisation.

Fractures of the **Ulna** (fig. 640).

(i) The *olecranon process* is commonly fractured as a result of falls on the elbow, e.g. slipping on a banana skin.

Separation usually occurs through the constricted base of the process, and may be almost negligible if the triceps expansion remains untorn. If wide separation is present, diagnosis is usually easy, in that the gap between the process and the shaft can be palpated, and the power of extension is lost.

If separation is sufficient to require operation, the fragment is easily fixed in position, kangaroo tendon or even stout catgut being sufficient for the purpose. If screws are deemed necessary, one composed of bone is preferable to metal. If separation is slight or operation not advisable, as on account of age or constitutional disability, then fixation in extension should be maintained for at least three weeks.

The *coronoid process* is occasionally fractured, usually in conjunction with a posterior dislocation of the elbow joint. The condition should be suspected when the dislocation recurs after apparently successful reduction. Treatment consists of maintaining complete flexion for three weeks, in order to relax the brachialis anticus muscle. If flexion of the elbow joint is subsequently limited, removal of the process may be necessary, as accurate fixation is difficult and results in callus formation.

(ii) Fractures of the *shaft* of the ulna are due to direct or indirect violence. In the latter case they are sometimes associated with dislocation of the head of the radius. Diagnosis is readily made, as the bone is subcutaneous, and displacement or definite localised tenderness is readily palpable.

The upper fragment is usually pulled slightly forwards by the brachialis anticus, and the lower fragment inwards by the pronator quadratus. Treatment consists of fixation of the forearm either by splints or a plaster casing, in a position of partial flexion and mid-supination.

(iii) The *styloid process* of the ulna is commonly avulsed in association with a Colles's fracture (fig. 638). The maintenance of the hand in a position of adduction, which is an integral part of the treatment of Colles's fracture, approximates the position of the ulnar styloid process.

Fractures of the **Radius** and **Ulna** are due to direct or indirect violence. In the former case the bones are fractured at approximately the same level, which depends upon the site of injury. If the fractures are due to indirect violence, the radius usually fractures in its lower third, and the ulna about its centre. The position of the fragments depends on the direction of violence and the site of fracture ; some approximation of the fractured ends is common, with consequent risk of cross-union. If manipulation succeeds in restoring alignment, then the forearm is fixed in supination by means of a posterior gutter splint. Should manipulation fail, as is usually the case if the bones are fractured at approximately the same level, then open operation must be performed and the bones plated if necessary. In some cases operation on one bone only will be sufficient, usually the radius, which suffers more displacement than the ulna. Exposure is obtained by an incision along the outer side of the forearm, between the supinator longus and the extensor tendons and muscles.

Carpal bones are fractured by either direct or indirect violence. In the former case any bones may be involved, and comminution is common. The commonest bone to be fractured by indirect violence is the *scaphoid*. Thus a " sprained wrist " after such an incident as falling on the hand, delivering a blow with the fist, or receiving a jerk from the starting-handle of a car, should arouse suspicion. If a fracture is present, inspection of the backs of the hands, with fingers and thumb fully extended, will reveal some fullness of the anatomical " snuff-box," and on palpation of that area definite local tenderness is experienced by the patient. X-rays will confirm the diagnosis (fig. 641). Unless treated efficiently the condition will cause permanent weakness of the wrist. As soon as the condition is diagnosed, the hand must be fixed in hyperextension and abduction. A light plaster of Paris casing should be applied along the back of the forearm and extend to the heads of the metacarpal bones, with the hand dorsi-flexed and abducted. The wrist is immobilised for at least six weeks, otherwise " shearing "

movements occur between the fractured surfaces and prevent bony union. The patient is encouraged to use his fingers and hand while awaiting union. A leather support may be worn with advantage for the ensuing three months. Cases which do not present themselves, or which are unfortunately undiagnosed until after the expiration of some weeks from the time of injury, will require immobilisation for three months. Removal of the distal fragment always results in permanent weakness, although pain is sometimes relieved, thus the few cases which remain ununited after prolonged immobilisation are best treated by the insertion of a bone peg in order to fix the fragments.

Metacarpal bones are commonly fractured. If due to direct violence, any of the bones may be involved, and the fracture is usually transverse. The shaft of the second metacarpal is sometimes fractured by indirect violence

FIG. 641.—Fracture through the waist of the scaphoid.

during boxing; this injury is termed a "punch" fracture.

Fractures of the inner four metacarpals are usually treated by requesting the patient to grasp a roller bandage which is placed in the palm, and firmly bandaging the fingers over this support. Immobilisation and some degree of extension are thus obtained, but if the position of the fragments is unsatisfactory, then extension may be required of the appropriate digits.

Fracture of the first metacarpal requires special mention, as a fracture of the base, due to indirect violence, may be overlooked. Unless efficient treatment is instituted, permanent weakness is likely to result. The base of the metacarpal remains in apposition with the trapezium, while the shaft is drawn backwards and upwards by the extensors of the phalanges, the broken bone somewhat resembling the "stave" of musical manuscript.

The deformity is easily reduced by traction, but immediately recurs when released. Traction is maintained by utilising a piece of Gooch splinting, cut so as to cover the thenar eminence and front of the thumb. This is applied to the palmar surface, and the distal end of the splint is strapped to the terminal portion of the thumb, i.e. immediately over and above the nail. The splint is then pushed distally so as to exert traction, and the upper portion firmly fixed in position by strapping. After three weeks the splint is removed, and massage and movements are substituted.

Phalanges are commonly fractured by direct violence, e.g. by a blow with a hammer, or crushed by a door of a car or slipping window sash. The condition known as "mallet finger" is frequently due to avulsion of the base of the terminal phalanx.

Fractures of the **Ribs** and **Sternum.**

Fractures of the **Ribs** occur as a result of direct, indirect, or muscular violence. In certain nervous diseases, e.g. tabes dorsalis, very slight trauma may cause a fracture, and consequently asylum attendants are sometimes unfairly accused of undue roughness in dealing with inmates under their supervision.

(i) Fractures due to *indirect violence*, e.g. while struggling in a crowd, in which dilemma the arms should be kept at the sides in order to protect the ribs. The fifth to the eighth ribs, which are compressed beyond their limit of elasticity, are those usually fractured.

The fracture occurs a short distance in front of the angle of the rib (fig. 642). Usually viscera are uninjured.

The condition is suggested by the history, and localised

pain on deep inspiration. Pain is referred to the site of fracture if simultaneous pressure is exerted upon the sternum and spine.

(ii) Fractures due to *direct violence* affect the ribs most exposed to injury. Thus the first and second ribs are uncommonly fractured, as they are protected by the clavicle, and trauma sufficiently severe to smash the clavicle and upper ribs is likely to inflict fatal injuries on adjacent structures (hence the introduction of metal epaulettes on army uniforms of bygone days). Similarly, the lower two ribs are protected by muscles, and enjoy a degree of mobility which mitigates the risk of fracture.

FIG. 642.—Rib of Robert the Bruce, King of Scotland, fractured by indirect violence while jousting in England many years before his death. (R.C.S.130.)

Fractures due to direct injury are more serious than those due to indirect causes, as bone fragments may be driven inwards and damage, among other structures, the lungs, pleuræ, diaphragm, liver, kidneys, spleen, pericardium, or heart. Surgical emphysema is likely to follow if the lung is lacerated.

(iii) Fractures due to *muscular violence* occasionally occur, e.g. a violent sneeze, especially if partially suppressed. These fractures resemble those due to indirect violence.

The treatment of fracture of the ribs depends on whether risk exists in driving fragments into subjacent soft tissues. Thus fractures due to indirect violence, muscular action, or direct violence with no depression of fragments are treated by the application of strapping. Strips of adhesive strap-

ping, from 2 to 3 in. wide, depending upon the size of the patient, are applied horizontally around the chest, reaching from the opposite side of the spinal furrow behind to the opposite nipple line in front (fig. 643). These strips are applied at the end of expiration, e.g. the patient is requested to emit a long-drawn whistle, and the strapping applied as this becomes tremulous. The fractured ribs are thus partially immobilised by the strapping, and receive additional support by the application of a flannel bandage.



FIG. 643.—Leukoplast strapping for fractured ribs.

In cases where depression exists, further pressure is obviously dangerous. The patient is therefore propped up in bed, or, if he will tolerate the position, is kept recumbent with a sand-bag in the spinal furrow. A close watch is kept for evidence of visceral injury, and operative interference may be necessary.

Ribs, in spite of lack of immobility, unite readily, and support for three weeks is usually sufficient.

The **Sternum** is occasionally fractured as a result of direct violence, e.g. by the steering-wheel of a car as the result of a collision. If displacement is marked, death is likely, owing to injury to or pressure on the heart and great vessels. In less severe cases the patient is confined to bed with a pillow or sand-bag between the shoulders, and strapping applied to steady the fragments.

Fracture due to indirect violence is sometimes associated with a fracture-dislocation of the spine, and is due to excessive flexion of the trunk. Treatment is symptomatic, as the more serious injury to the spine takes precedence.

Lower Extremity

Fractures of the **Pelvis** involve the false or true pelvis, or portions of either.

(i) Fractures of the **False Pelvis** sometimes involve the ilium, but displacement is slight, as the iliacus on the inner side, and gluteal muscles on the outer side, support the bone. Portions of the iliac crest may be fractured and displaced by muscles attached thereto, or the anterior superior spine may be knocked off by direct violence. Both the anterior superior and inferior spines have been detached by muscular violence, the former by contraction of the sartorius, and the latter by the straight head of the rectus femoris.

If no displacement occurs a firm flannel bandage is applied to the pelvis, and the patient confined to bed until adequate union has occurred. Small detached fragments should be pegged back into position.

(ii) Fractures of the **True Pelvis** usually occur in the oblique diameter, i.e. the obturator foramen on one side is involved, and the ala of the sacrum on the opposite side, although in some cases the pelvic ring is fractured in two places on the same side. The cause is some severe crush, such as a horse rolling over its rider, or a car passing over a pedestrian. Severe shock is usually present, but if the patient is sufficiently composed, and is unfortunately assisted to his feet by sympathetic but ignorant bystanders, he feels as though the pelvis was "coming to bits." Rapid extravasation of blood occurs, and crepitus may be detected when the patient's position is changed, or when he is lifted.

The most important aspect of a fractured pelvis is the liability to injury of viscera—the urethra commonly, bladder occasionally, and rectum rarely. Therefore the patient should be instructed not to attempt to pass urine, and as soon as possible a detailed examination is made.

Blood escaping from the external urinary meatus immediately suggests rupture of the urethra, and unless a soft rubber catheter can be passed into the bladder, steps must be immediately taken to suture the urethra (*vide* Rupture of the Urethra). Should no blood be escaping, a catheter is passed, and a small quantity of blood-stained urine will suggest rupture of the bladder, which is usually extraperitoneal (*vide* Rupture of the Bladder). A rectal examination is

made, and in rare cases a fragment of jagged bone may be encountered. In such cases the anal canal should be divided from the anus below to the rent above in order to provide drainage for the inevitable infection. The wound is lightly packed with gauze soaked in mild antiseptic, and an iliac colostomy performed in order to divert the passage of fæces. Wounds of the vagina are rare, and can usually be sutured.

Having methodically excluded or dealt with visceral lesions, attention is directed towards the fracture. In some instances fragments may be more or less adequately replaced, thus a finger in the rectum or vagina may exercise pressure on, and improve the position of a displaced piece of sacrum or pubic bone. In the majority of cases all that can be done is to steady the pelvis by means of a fracture-cloth held in position on either side by a heavy sand-bag, the legs being bandaged together at the knees. A divided mattress is of great assistance for nursing purposes. Union readily occurs, and after six to eight weeks the patient is allowed to get up, with a pelvic support and crutches.

(iii) **Incomplete** fractures include fractures of the acetabulum, ischial tuberosity, the sacrum, and coccyx.

Fractures of the acetabulum occur either in connection with dislocation of the hip joint, or as a result of a heavy fall on the great trochanter. In the former case the upper or posterior part of the rim is carried away with the head of the femur, and the condition is suspected if the dislocation tends to recur after reduction. Extension is required for six weeks, applied to the leg in an abducted position.

In the case of falls upon the trochanter, any degree of injury may occur from a fissured acetabulum to central dislocation of the head of the femur, in which case it is driven through the acetabulum into the pelvis, where it can be felt on rectal or vaginal examination. If deformity exists, reduction must be attempted under anæsthesia, and weight extension applied for six to eight weeks, followed by the use of a walking calliper until consolidation is satisfactory.

The ischial tuberosity may be cracked as a result of a fall

on the buttocks, as by withdrawal of a chair when a person is about to sit down. The diagnosis is suggested by persistent pain and unwillingness to sit on the centre of a chair. A radiograph may clinch the diagnosis, but displacement is slight. Treatment is symptomatic.

The *sacrum* is fractured by either direct or indirect violence. The latter is usually associated with fracture of the pelvis. Fracture from direct violence, e.g. a fall or kick, may result in displacement and consequent injury to sacral nerves or pressure on the rectum. The displacement can



FIG. 644.—Femur.

1. Intracapsular fracture.
2. So-called extracapsular fracture, often comminuted.
3. Per-trochanteric fracture.
4. Spiral fracture of upper third of shaft, due to indirect violence.
5. Transverse fracture of the middle of shaft, due to direct violence.
6. Supra-condylar.
7. T-shaped into joint.

sometimes be detected and partially corrected on rectal examination. Treatment otherwise is conducted along the lines suggested for fractures of the true pelvis.

The *coccyx* may be fractured as a result of kicks, blows, or even parturition. Pain, which is often severe, occurs on walking, sitting, or actions which cause contraction of the levator ani, such as defæcation or coughing.

Rectal examination reveals local tenderness and probably deformity. It should be remembered that the sacrococcygeal joint allows some degree of movement in the majority of cases.

In some cases these symptoms are produced when no fracture is evident, the condition being known as coccydynia, which is probably due to traumatic periostitis, with possible involvement of the lowest sacral and coccygeal nerve.

If adequate rest and symptomatic treatment are of no avail, excision of the coccyx should be performed.

Fractures of the **Femur** are of the greatest surgical importance, both on account of difficulties in treatment and disability which results if such is inefficient.

(i) Fractures of the **Upper End.** These occur near the head of the bone, near the trochanters, or through the trochanters (fig. 644). In addition, separation of the epiphysis sometimes occurs, or either the great or small trochanter may be separated from the femur.

(*a*) Fracture near the head, or so-called intracapsular fracture, is a common accident in elderly people, especially females, owing to atrophic changes which occur in the bone, particularly atrophy of the strong lamina which runs in the neck of the femur from the small trochanter to the head—the calcar femorale of Merkel. The accident occurs as a result of indirect violence, often of a trivial nature, e.g. stumbling over a stair.

The head of the bone may not be completely separated from the neck owing to some of the retinacular fibres remaining intact. These fibres are reflected from the under surface of the capsule at its attachment to the neck of the femur, inwards along the neck of the bone. Impaction only occurs if the patient falls on the injured limb at the time of the fracture.

The diagnosis is usually made without difficulty, in that an elderly person suffers some slight accident, followed by inability to use the limb. On inspection the limb is everted and shortened, the eversion being due to the weight of the limb. The ilio-tibial band is felt to be relaxed, but movements should not be attempted, not only on account of pain, but intact retinacular fibres may thereby be torn. Nélaton's line, which is drawn from the anterior-superior iliac spine to the tuber ischii, indicates elevation of the great trochanter.

Bryant's triangle, formed by drawing a line horizontally backwards from the anterior superior iliac spine, a second line from the spine to the top of the great trochanter, and a third from the top of the great trochanter vertically upwards to meet the horizontal line, also indicates elevation of the great trochanter, in that the base, i.e. the third line, is shorter than the corresponding measurement on the sound side of the limb.

Diagnosis must be made from such conditions as severe bruising, in which case shortening and eversion are absent. Osteo-arthritis associated with trauma may present difficulty, in that shortening and grating are present, but eversion, complete loss of power, and relaxation of the ilio-tibial band are not present. In cases of dislocation the head of the bone is felt in an abnormal position.

Treatment depends upon the age and general condition of the patient, the ultimate result of the fracture being of secondary importance. In the majority of cases prolonged confinement to bed is liable to encourage pulmonary complications, and therefore the fractured leg is merely steadied between sand-bags. After recovery from associated shock, e.g. about two or three days, a plaster of Paris spica may be applied with the leg in abduction and inversion (Whitman's method). If this is cumbersome and undesirable, a Thomas hip splint is fitted, a patten being provided for the other leg, and the patient allowed up on crutches. If impaction is present, no attempt is made to disimpact the fragments, as bony union is desirable even in a faulty position.

In about 40 per cent. of cases Whitman's plaster results in only fibrous union, and in addition to the risk of hypostatic pneumonia prolonged immobilisation of the knee in elderly subjects results in painful stiffness. Open operation and fixation of the femoral head with a bone peg or Smith-Petersen's nail is therefore gaining in popularity, and the results in selected cases are excellent. Smith-Petersen's nail is of stainless steel, and is sufficiently long to prevent angular displacement. The three flanges prevent rotation of the head of the bone.

In order to introduce the nail spinal anæsthesia is sufficient, and a vertical incision is made over the great trochanter. A finger is thrust along the anterior aspect of the joint, so that the fragments can be palpated. The limb is abducted and inverted by an assistant, and manipulated until the fragments are felt to be in apposition. A guide is driven through the compact bone of the trochanter in order to obviate blunting the cutting edge of the pin. The pin is then hammered home into the head of the femur (fig. 645). The wound is closed, and no other immobilisation is necessary, and the patient is encouraged to move the knee and hip from the day after the operation. Walking with the aid of sticks is allowed in about a month. Bony union occurs in four to six months, with painless, free movements of the knee and hip, and negligible wasting of muscles.

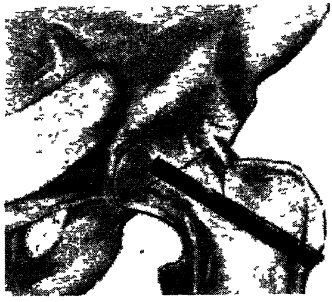

FIG. 645.—A tracing of a radiograph showing Smith-Petersen's nail in position.

An elaboration of the above method is advisable if portable X-rays are available. Before the pin is introduced 3 Kirschner wires are inserted into the head of the bone in slightly different directions. An X-ray is taken and rapidly developed, and the wire which is seen to occupy the best position is left *in situ*. A pin with a hollow centre is then driven along the wire. X-ray control ensures good apposition, and the wire steadies the head of the bone so that the impact of the nail causes no displacement.

(*b*) Fracture near the trochanters, or so-called extracapsular fracture, most commonly occurs in young men as a result of a fall on the great trochanter. The fracture is only extracapsular posteriorly, where the attachment of the capsule to the neck of the bone is a full ½ in. from the intertrochanteric line.

The deformity resembles the intracapsular type of fracture, in that shortening and eversion are usually present, but in this case shortening is due to impaction rather than to muscular contraction, and eversion is due to more extensive comminution and impaction posteriorly than anteriorly, as the posterior aspect of the neck of the femur is the more brittle. In addition, marked bruising over the region of the great trochanter is present. Shortening is more obvious than with the intracapsular variety, and may be as much as 2 inches. Nélaton's line and Bryant's triangle confirm the elevation of the great trochanter.

In some cases, owing to the direction of violence, inversion may occur instead of eversion.

As the fracture is impacted, loss of power is not complete, and cases have occurred in which the patient has succeeded in walking after the injury, or even sought medical advice only for the condition to be overlooked by the doctor.

Treatment consists in the administration of an anæsthetic and forcible disimpaction. The patient is presumably young and healthy, and consequently disimpaction is the first step towards correction of deformity, and pulmonary complications are unlikely to follow prolonged confinement to bed. After disimpaction, which is indicated by crepitus and ability to overcome shortening by traction, either a Whitman's plaster (fig. 646) or weight extension is applied. In the latter case the limb is fixed either in a double abduction or on Thomas's splint. Care must be taken to prevent rotation of the pelvis and consequent loss of abduction. X-rays confirm the corrected position, and after six to eight weeks the patient is allowed up in a walking calliper, which should be worn for at least three months, and then gradually discarded. As an alternative a Whitman's plaster, applied with the limb in abduction and inversion, gives good results. In some cases, if comminution is not extensive, the insertion of a bone peg or nail will secure fixation in a good position.



FIG 646.—Plaster applied by Whitman's method.

Bony union usually occurs, but some limitation of movement may result from callus formation, and the older the patient the greater is the risk of subsequent osteoarthritis developing in the joint.

(*c*) Fracture through the trochanters, or Kocher's pertrochanteric fracture, also occurs as a result of direct violence.

The upper end of the lower fragment may be felt separately from the great trochanter, also the latter does not move on gentle rotation of the limb. Owing to considerable bruising and tenderness, the exact diagnosis is seldom possible apart from radiography.

(*d*) Separation of the ephiphysis of the head of the femur is of rare occurrence. The centre appears during the first year, and unites at the age of 20. The clinical features resemble those of an intracapsular fracture, and treatment is conducted on similar lines, but if reduction is unsatisfactory, open operation should be performed, as irregular growth may subsequently lead to coxa vara.

(*e*) Fracture of the great trochanter occasionally results from direct violence, and pegging will be necessary if displacement is other than slight. Before the age of 18 years this injury is of the nature of separation of the epiphysis.

(*f*) Avulsion of the small trochanter is sometimes caused by sudden contraction of the ilio-psoas. The commonest age for this accident is about puberty, in which case the epiphysis is separated. The condition is unlikely to be diagnosed without the assistance of X-rays. Treatment consists in immobilising the limb for five or six weeks in a position of flexion and eversion.

(ii) Fractures of the **Shaft** of the femur occur at any site ; those in the upper part are usually due to indirect violence, and those nearer the knee joint are more commonly caused by direct injury.

Displacement depends on the direction of violence, muscular contraction, and gravity. In the upper third the upper fragment is flexed by the ilio-psoas, and abducted and everted by the external rotators. Shortening occurs from contraction of the hamstrings, and eversion is due to gravity and pull of the adductor muscles.

In the middle third fractures result from either direct or indirect violence. In the former case comminution may occur, and the line of fracture is transverse, while in the latter it is oblique. Displacement in fractures due to direct violence depends to some extent on the direction in which

the violence was applied, but tends to resemble the position assumed in cases due to indirect violence. Thus the upper fragment is flexed, abducted, and slightly everted, while the lower fragment is displaced backwards, upwards, and rotated outwards.

Fractures of the lower third, being due to direct violence, are usually transverse. The lower fragment is drawn downwards and backwards by the gastrocnemius, and may cause injury to structures in the popliteal space. Eversion is present owing to the leg rolling outwards.

The treatment of fractures of the femoral shaft may be conducted on manipulative or operative lines. It is becoming more generally recognised that restoration of alignment is essential if an ultimate satisfactory result is to be obtained, particularly in the case of the femur, which is a single, weight-bearing bone. Also alteration of direction of the lines of stress associated with malalignment throws an abnormal strain upon the hip or knee joint, and osteoarthritis is prone to develop in later life.

If manipulative treatment is considered advisable, then weight extension in some form is necessary. This may be applied by means of strapping, the limb first being washed and shaved. Two broad pieces of adhesive plaster, 2 or 3 in. in width, according to the size of the limb, are applied on either side of the leg to well above the level of the fracture. The sides of the knee and ankle are protected by pads of lint, and the smaller pieces of strapping are then applied obliquely to encircle the limb from below upwards, each overlapping the preceding strip. The ends of the long pieces of strapping are then fixed to a wooden stirrup, which is about 4 in. broad, and perforated in the centre. Through this perforation a strong cord is attached which passes over a pulley. An adequate weight is suspended from the free end of the cord.

A more precise method of applying weight extension is by some form of skeletal traction. This can be obtained by transfixing the femur with a Steinmann's pin or Kirschner's wire, which is passed through the bone just above the

adductor tubercle. The wire is introduced by means of a drill, and after the wire is rendered taut it is attached to a stirrup, and thence to the extending weight (fig. 647). With skeletal traction movements of the knee joint can be obtained at an early date, and wounds of the soft tissues are exposed for dressing. Needless to say, strict aseptic precautions must be exercised in inserting the transfixion pin or wire.

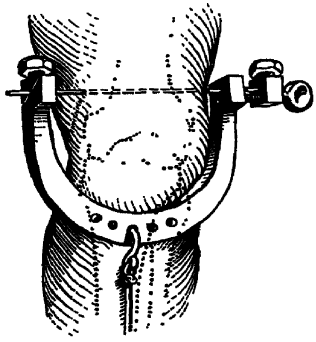

FIG. 647.—The lower end of the femur transfixed by a Kirschner's wire, which is attached to a stirrup.

Many varieties and modifications of splints have been devised for the treatment of fractures of the femur; those most commonly used are the following:

Thomas's Knee Splint.—This consists of a ring padded with leather, which may be softened if necessary by the application of soap, or further padded with chamois leather. Extending from the ring on either side is an iron bar, which reaches about 4 in. below the foot, the two lateral bars being joined by a cross-bar. The limb is passed through the ring, which eventually comes to rest against the ischial tuberosity. The extension apparatus is fixed on the leg, the splint is fitted, and traction exerted by a weight attached to a cord which runs over a pulley.

The limb is supported by a trough composed of pieces of flannel or broad rubber strips cut from a discarded inner tube, which are fixed to the splint by means of safety-pins or large paper-clips. Sagging of a fragment can be remedied by tightening the appropriate support, and lateral displacement corrected by passing a loop around the limb and fixing it to one of the lateral bars of the splint. The bottom of the bed is raised on blocks in order that the weight of the patient may provide counter-extension. A movable leg piece may be attached to the splint in order that the movements of the knee joint can be obtained and stiffness thereby prevented.

Hodgen's splint, now but rarely used, consists of two lateral irons which are joined above by an oblique cross-piece which, when the splint is fitted, lies over Poupart's ligament. The lateral irons are bent opposite the knee joint, and project beyond the foot, where they are again united by a cross-piece.

The traction apparatus is applied, and the limb supported in the splint by a trough of bandage or rubber, as described in connection with Thomas's splint. The cord passing through the stirrup is tied to the cross-piece at the foot of the splint, which is suspended by four cords attached to a pair of hooks on either lateral iron. These cords are connected to a further cord, which passes over a pulley fixed to a vertical support at the foot of the bed. An appropriate weight is then fixed to this cord, so that extension is obtained. The degree of extension depends on the actual weight applied and the obliquity of the cord, which can be modified by adjusting the height of the pulley. Counter-extension is obtained by raising the foot of the bed by means of wooden blocks.

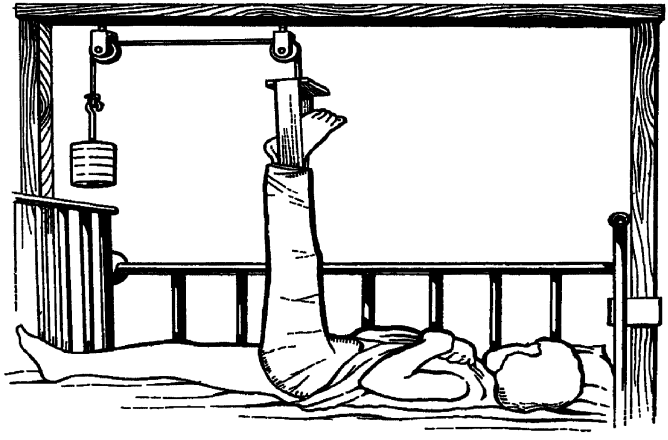

FIG. 648.—Gallows splint.

A *gallow's splint* is useful in children during the first decade. Extension is applied, and the legs are slung up to the cross-piece, so that the pelvis is just lifted from the mattress. The child's weight acts as counter-extension, and the position of the child is convenient for nursing purposes (fig. 648).

MacIntyre's splint is an interrupted posterior gutter splint with a screw at the level of the knee, so that the position of

the joint can be altered as desired. A sliding foot-piece can be approximated to the foot, which may be fastened to the foot-piece by covering the foot with a sock. A tape may be sewn along the back of the sock, and then carried between the foot and foot-piece, so that it passes over the top of the latter, and is then fixed to a small stud on the plantar surface. The foot is thus elevated, and pressure on the heel prevented.

MacIntyre's splint is useful for fractures in the neighbourhood of the knee joint, as in these cases flexion of the joint is usually desirable.

Various forms of apparatus are available from which splints can be suspended. The Balkan beam, or some modification, is a satisfactory apparatus, and consists of an overhead beam, which is fixed to two uprights, one of which is fixed at either end of the bed. The uprights may be fixed in suitable position for suspension of either limb, or obliquely, if necessary. Pulleys are arranged in such positions that suspension and extension are conveniently obtained. In some cases an upright support at the bottom of the bed will be sufficient to support the splint or a pulley for the purposes of extension.

If fractures of the upper third of the femur are to be treated conservatively, the position of the upper fragment must be borne in mind, as it is small, deeply situated, and therefore cannot be controlled. Therefore the lower fragment must be flexed, abducted, and slightly everted, a Hodgen's or Thomas's splint being best suited for the purpose. Sufficient weight must be applied to overcome muscular contraction, so that measurement of the two legs in the same position reveals no inequality. If possible X-rays should always be used in order to confirm reduction and maintenance of the correct position.

Reduction of the fracture in the middle third of the thigh may be difficult, because the lower end of the upper fragment is buried in the quadriceps muscle, with consequent interposition of soft parts. Hence operative interference is sometimes necessary. If satisfactory reduction can be

obtained and maintained, then a Thomas's or Hodgen's splint combined with skeletal traction yields good results.

In fractures of the lower third of the femur flexion of the knee joint is usually desirable, in order to relax the gastrocnemius, MacIntyre's splint, or a flexed Thomas's splint is usually adequate.

As a general rule the limb should be immobilised for two months, after which, if union appears to be satisfactory, a walking calliper is worn for a further four months, and then gradually discarded. The actual time required for treatment depends upon the age and weight of the patient, his occupation and the liability of the fragments to separate after reduction and fixation.

(iii) Fractures of the **Lower End**. T- or Y-shaped fractures occur as a result of direct violence. A variable degree of separation of the condyles occurs, and the joint is speedily distended with blood. According to general principles, as the joint is involved, open operation should be advised, provided that the general condition of the patient is satisfactory. The fragments are fixed by means of a screw or peg, and the joint emptied of blood-clot. Massage and passive movements are commenced after the third day in order to prevent muscular atrophy, and to diminish the risk of adhesions.

One or other condyle can be separated, either by direct violence or as a result of a fall on the knee. Treatment is conducted as for fractures implicating joints.

Separation of the lower epiphysis was more common in the days of light horse-drawn vehicles, when children enjoyed the excitement of riding on the rear axle. Entanglement of the foot in the spokes caused violent hyperextension of the leg and forward separation of the epiphysis. The lower end of the diaphysis projects backwards, and gangrene sometimes followed pressure on the popliteal vessels. The deformity is reduced by traction on the flexed knee with the patient lying on his back on the floor, the pelvis being fixed by assistants. After reduction the limb is bandaged in flexion, the pulsations of the posterior tibial artery being a guide to the

circulation of the limb. After three or four weeks, passive movements may be commenced, and a walking calliper is subsequently worn until six months after the accident. If manipulation fails to reduce the displacement, then open operation must be performed, otherwise stunted growth or deformity will result.

Fractures of the **Patella** are due to direct or indirect violence.

If due to *direct violence* a comminuted or star-shaped fracture usually results. Separation of the fragments is not marked, and may be absent, owing to the intact aponeurosis and periosteum, which hold them in position. Considerable bruising and effusion into the joint are to be expected. Aspiration of the joint is often desirable, otherwise lead lotion and a back splint are applied for a week, after which passive movements may be commenced, but active flexion should be prohibited for at least a month. In the rare event of separation of the fragments, a purse-string of strong catgut or silver wire may be inserted in order to secure approximation.

Fractures due to *indirect violence* occur when the knee is semi-flexed. In this position the patella is balanced on the front of the condyles, and sudden contraction of the quadriceps, as in an effort to regain balance, snaps the bone in the same manner as a stick is broken across the knee. The fracture usually occurs in the lower third of bone, the smaller fragment being tilted forwards by contraction of the patellar ligament. The fracture may be heard by the patient, who falls to the ground. Local pain and loss of power to extend the leg are prominent symptoms. The joint rapidly fills with blood, and the gap between the fragments can sometimes be seen, and in any case is readily palpable, this feature distinguishing the condition from rupture of the quadriceps tendon. Owing to separation of the fragments, and the interposition of torn aponeurosis, fibrous union will occur unless operation is undertaken. Moreover, in cases treated conservatively, the initial band of fibrous tissue which unites the fragments tends to stretch, so that eventually

the fragments may be separated by a distance of 3 or more inches (fig. 626).

Treatment, therefore, in the majority of cases, consists in five or six days' confinement to bed, followed by open operation. A U-shaped flap is turned downwards, so that the scar is not subjected to pressure, and aponeurosis and blood-clot, which cover the raw surfaces of the fragments, are carefully removed, the aponeurosis being snipped away with scissors, and blood-clot scraped away with a sharp spoon. The procedure of drilling the bone and insertion of silver wire is losing popularity, as rarefaction of the bone and loosening of the wire is a not uncommon sequela, necessitating removal of the wire some years later. Soft tissues are much more tolerant to metal than the bone, and if silver wire is used it should be introduced as a purse-string around the fragments, the patellar ligament, aponeurosis, and extension tendon being pierced in turn by a hollow guide through which the wire is passed. An alternative method is to use kangaroo tendon, or No. 4 chromic catgut, which is passed through the drilled bone. After the fragments are approximated the torn periosteum and aponeurosis are carefully sutured, and the wound closed. Massage of the quadriceps should be commenced on the following day, passive movements at the end of one week, and limited active flexion at the end of two weeks. Normal function is regained after the expiration of two months.

Cases due to muscular contraction occasionally occur, in which the bone is fractured, but the aponeurosis remains intact. Localised pain and tenderness result, and a radiograph shows a transverse crack in the bone. Diagnosis is important, as otherwise injudicious movements are liable to tear supporting soft tissues, and separation of fragments. Treatment consists in the application of a back splint for three weeks, and restricted movements until two months have elapsed from the time of injury.

In cases in which fibrous union has been allowed to occur (fig. 626), and which subsequently require operation on account of disability, a two-stage operation is often necessary. At the first operation the upper fragment is separated from the intercondylar notch to

which it is usually adherent, and, with the leg held vertically, the two fragments are approximated as nearly as possible. During the ensuing two or three weeks the leg is gradually brought to the horizontal position, thus stretching the quadriceps muscle. At a second operation the two fragments can usually be brought together.

Fracture of one patella is not infrequently followed by fracture of the other at a later date, possibly owing to some congenital abnormality in the shape of the bones.

Fractures of the **Tibia** may occur at either end, or involve the shaft (fig. 649).

(i) Fractures of the *upper end* are usually due to direct violence, one or other tuberosity being separated, but occasionally a Y- or T-shaped fracture is produced by a fall



FIG. 649.—Tibia.

1. Y-shaped fracture involving the knee joint.
2. Inner tuberosity.
3. Transverse fracture due to direct violence.
4. Oblique fracture due to indirect violence.
5. Internal malleolus.

on to the feet. In either case the knee joint is involved, and rapidly fills with blood. If the patient is otherwise fit, operation should be performed, the tuberosities being screwed or pegged into position and the joint cleared of blood. The tibial plateau is thus restored and risk of subsequent osteoarthritis diminished. Fixation of the outer tuberosity is even more important than the inner as a greater proportion of the weight of the body is transmitted through the outer tuberosity, particularly in females, and persons with a tendency to genu valgum.

Separation of the upper epiphysis of the tibia is a rare accident, but may occur up to the age of 22 years. The

epiphysis includes the articular facet for the head of the fibula, and the tongue-shaped prolongation in front for the tubercle of the tibia. Adequate reduction must be effected, and a MacIntyre's splint is a convenient and comfortable means of fixation for the first two or three weeks, after which a light plaster case or a walking calliper is applied.

(ii) Fractures of the *shaft* of the tibia, without implication of the fibula, are usually due to direct violence, in which case the fracture is transverse and often comminuted. Diagnosis is readily made as the bone is subcutaneous and even if deformity is not obvious, any irregularity or localised tenderness is readily palpable.

Treatment consists in reduction of deformity and fixation of the fragments by means of a back splint, further support being obtained by Cline's lateral splints if necessary.

It should be remembered that in all fractures below the knee joint correct alignment is only regained when the inner border of the patella, the internal malleolus, and the ball of the big toe are in line with one another.

The leg may then be suspended on a Bloxam's cradle, which allows the injured limb some degree of mobility, and greatly adds to the comfort of the patient while in bed. When swelling has diminished a plaster cast is applied so that the patient is enabled to get about on crutches.

If reduction is difficult to maintain, extension may be necessary, the leg being supported in some suitable splint, such as Thomas's splint, which is flexed at the knee joint. Traction is best applied by a transfixion pin through the os calcis (fig. 650). Such methods as Sinclair's glue or strapping, or a spat or the upper of a boot to which lateral straps are sewn, have now been replaced by skeletal traction.

In some cases it is possible to reduce displacement and apply an unpadded plaster cast so that the patient can commence ambulatory treatment at the beginning of his disability. The cast extends from the toes to the middle of the thigh, and reduction can be confirmed by a radiograph taken through the plaster. A second plaster is sometimes necessary should the first become slack owing to diminution

of swelling. Weight-bearing is allowed in about four weeks, and after eight weeks a plaster is fitted which extends to below the knee, so as to allow movements of the joint. The plaster is discarded after ten to twelve weeks.

(iii) Fractures of the *lower end*. The only common fracture in this situation consists in fracture of the internal malleolus. This may occur as a result of direct injury, or the malleolus may be avulsed as a result of a stumble or

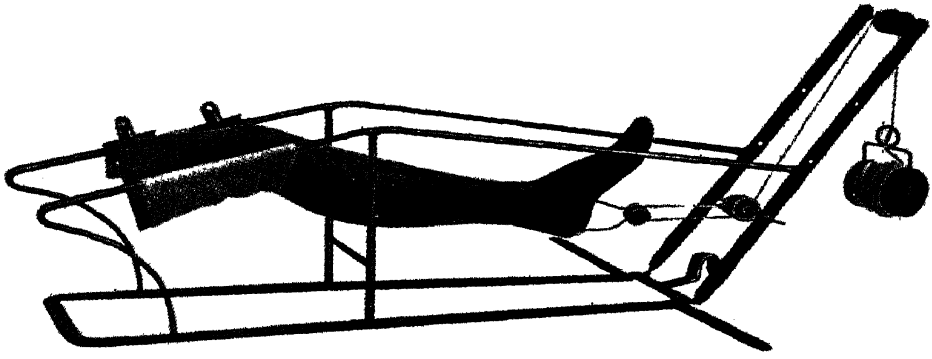

FIG. 650.—A cradle splint for traction fractures of the femur or tibia. Traction is applied by the transfixion pin, and the weight can be multiplied two-, three- or four-fold by the double pulley blocks (from *A Surgical Adventure*, by E. W. Hey Groves).

slip, causing the weight of the body to fall on the everted foot. Localised tenderness and ecchymosis suggest the nature of the injury. Treatment consists in fixation of the foot in marked inversion for a month, and the inner side of the boot should be raised when walking is resumed.

Fractures of the **Fibula** alone are usually due to direct violence, the lower end being most commonly affected. The procedure of "springing" the fibula assists in the diagnosis, and consists in compressing the fibula against the tibia, local pain being referred to the site of a fracture. A radiograph confirms the diagnosis, and treatment consists of the temporary application of a split plaster of Paris case, massage and movements being carried out after a few days.

Fractures of the **Tibia** and **Fibula** commonly occur either as a result of direct or indirect violence. In the former

case the bones are fractured at the same level, but if due to indirect violence the tibia is broken at the junction of its lower and middle thirds, and the fibula at about its centre. The upper fragment tends to be displaced forwards by the pull of the quadriceps muscle, and may pierce the skin, while the lower fragment is usually displaced backwards and upwards by the calf muscles, and is rotated outwards by the weight of the foot.

Treatment is conducted as in the case of a fractured tibia.

If reduction is unsatisfactory, operation should be considered, as malalignment predisposes to osteoarthritis of the knee joint, and fixation of the fragments permits early movements of the adjacent joints. Troublesome "fracture blisters" occasionally occur, and prevent or delay operation. They are probably due to interference with the subcutaneous lymphatic circulation by pressure of extravasated blood and exudate.

Fractures involving the **Ankle Joint**.

Pott's Fracture.—Dislocation and modifications of this fracture constitute an important group of injuries, as inefficient treatment leads to severe disability and even permanent crippling. Shuffling towards every large massage clinic may be seen men with stiff ankles and flat, everted feet, progressing laboriously with the aid of a stick.

This group of injuries is due to such accidents as slipping off a stair or kerb, or the foot "turning over" while walking or hurrying over rough ground. In such a case the strain falls on the inner side of the foot, and either the internal malleolus is fractured or the internal lateral ligament is ruptured. The astragalus is then forced against the external malleolus, and the fibula snaps 2 or 3 in. above its lower end. The foot is therefore everted and displaced backwards and outwards. In some cases the internal malleolus projects through the skin. The ankle joint is of necessity involved, and effusion occurs in the tender sheaths surrounding the ankle joint.

Modifications of Pott's fracture-dislocation :

(i) The internal malleolus only is fractured, there being no displacement of the foot.

(ii) Continuance of outward displacement ruptures the

interosseous tibio-fibular ligament, or the flake of tibia to which it is attached may be avulsed. The astragalus is forced upwards between the two bones, resulting in marked broadening of the ankle (Dupuytren's fracture).

(iii) Inversion of the foot occurs instead of eversion, due to the patient slipping in such a manner that the fibula fractures, and the astragalus is forced against the internal malleolus.

(iv) The tibia is fractured transversely immediately above the internal malleolus, or in children the lower tibial epiphysis is separated.

Treatment consists in the administration of a general, spinal, or local anæsthetic. The leg is then flexed in order to relax the calf muscles, and the foot is manipulated forwards and inwards. A slight amount of inversion, i.e. over-correction, is desirable, and counteracts the subsequent tendency to flat-foot. An external splint with a foot-piece is then applied: the foot-piece prevents recurrence of the backward displacement, and a pad below the external malleolus maintains eversion. The patient remains in bed with the knee flexed; this position relaxes the calf muscles, and enables the leg to rest on its outer side. Massage and passive movements are commenced as soon as possible, the length of time which elapses before movements are permitted depending on the risk of recurrence of the deformity. When the swelling has subsided, an unpadded plaster cast is applied and the patient allowed up. Crutches are necessary at first, but the patient soon accustoms himself to walking on the plaster with the aid of a stick. The incorporation of a metal stirrup in the plaster is an additional aid in ambulatory treatment (fig. 651) A plaster cast is necessary for at least two months, the actual time depending on the degree of deformity and the weight of the patient. When walking is resumed the inner side of

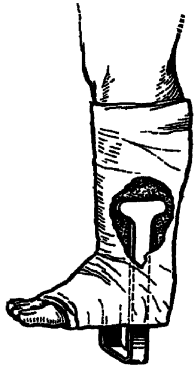

FIG. 651 — A metal stirrup incorporated in plaster in order to allow weight-bearing.

the heel should be raised a ¼ in., or if the patient is heavy an outside iron with an inside T-strap should be fitted for a few months in order to prevent the development of valgus deformity.

If no backward deformity is present, Dupuytren's splint may be used, which consists of a short, straight splint reaching from the knee to below the foot, the lower end being deeply notched in order to facilitate the fixation of the bandage. The splint is well padded from the knee to just above the internal malleolus, so that when it is applied to the inner side of the limb the abrupt lower end of the pad acts as a fulcrum, and maintains inversion of the foot. Syme's horseshoe splint is now obsolete.

If little displacement or swelling is present the plaster cast is applied at the commencement of treatment, adequate alignment being confirmed the following day by means of a radiograph taken through the plaster.

Old-standing cases of mal-union and consequent disability occasionally require osteotomy of the tibia and fibula, or even reconstruction of the fracture with more adequate reduction and possibly fixation by means of a screw.

It cannot be over-emphasised that careful reduction and constant supervision are essential in cases of Pott's fracture-dislocation and allied injuries, if osteoarthritis of the ankle joint, flat-foot, and adhesions in the joint and surrounding tendons are to be avoided.

Fractures of the **Tarsal** and **Metatarsal Bones.**

The **Os Calcis** may be fractured by falls from a height, a comminuted compressing fracture occurring. In other cases the sustentaculum tali, to which the "spring" ligament is attached, may be broken, or a fracture may occur through the body of the bone. In the latter case displacement is usually slight on account of ligamentous attachment, but if complete separation occurs, the posterior part of the bone is drawn backwards by the calf muscles.

Rarely the epiphysis into which the tendo Achilles is inserted is avulsed (10 to 14 years), or the portion of bone to which the tendon is inserted is separated.

Treatment depends on the degree of deformity. If this is slight, a plaster of Paris cast is applied for a few weeks and the patient is allowed to walk at once. If a portion of bone is avulsed, pegging may be necessary. Compression of the bone can be remedied by a few pats with a wooden mallet, the foot being protected by a folded towel and supported by a sand-bag. In some clinics a special *redresseur*, which acts on the principle of a vice and exerts lateral pressure, is available for reduction of compression fractures (fig. 652).

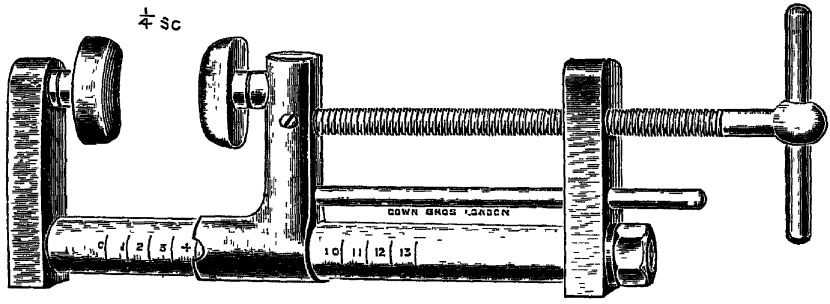

FIG. 652.—Bohler's redresseur for reduction of fractures of the os calcis and fractures in the region of the knee joint.

If flat-foot is likely to develop, e.g. as a result of fracture of the sustentaculum tali, prolonged convalescence is essential.

The **Astragalus** is sometimes fractured as a result of a fall from a height. If the foot is flexed and supported, as by the strut in an airplane, the neck of the bone may be shorn through by the sharp anterior articular surface of the tibia, comminution is common, and injuries to neighbouring bones are often associated. As in the case of the os calcis, considerable swelling rapidly develops and obscures the diagnosis, which is often only conclusive after radiography.

Treatment consists in the application of a plaster cast as soon as swelling has sufficiently diminished, and prolonged abstinence from weight-bearing so as to avoid flat-foot.

Fractures of the **Metatarsals** commonly occur, either as a result of falls or crushes, or by a wheel passing over the dorsum of the foot. Adequate rest is necessary, depend-

ing on the number of bones fractured, and the weight and occupation of the patient. If any of the inner four bones are fractured, it is advisable to provide an instep support until firm union has occurred.

March fractures (*syn.* **pied forcé**) occasionally occur in the necks of the second or third metatarsals. As the name implies, they are liable to affect those who do considerable walking, especially soldiers. The fracture occurs spontaneously, and is predisposed to by inter-osseous compression and consequent interference with the blood-supply to the bones.

CHAPTER XXXIV

DISEASES OF BONES

ACUTE INFLAMMATION

Acute periostitis may be traumatic or infective in origin.

Traumatic periostitis is a common condition, e.g. a kick on the shin. A tender swelling follows, due to bruising of the periosteum and subperiosteal extravasation of blood. Cold applications relieve pain and limit further extravasation, and the blood is usually absorbed. Repeated or severe trauma may result in the formation of a periosteal node of bone, e.g. the irregular shins of professional footballers. If the resistance of the patient is low, or if infective foci are present elsewhere, the subperiosteal hæmatoma, in common with hæmatomata in any part of the body, may become infected, as blood-clot is an excellent nidus for organisms circulating in the blood-stream. If infection occurs, a subperiosteal abscess will result, and unless the pus is evacuated without delay necrosis of superficial bone is likely to occur.

Acute Infective Osteomyelitis

Predisposing causes of this condition are as follows :

(i) *Trauma.*—Before ossification has occurred, the weakest part of a long bone is at the diaphyseal side of the epiphyseal line. At this level loops of blood-vessels penetrate the epiphyseal cartilage, and constitute a row of perforations across the diaphysis. Any excessive strain imposed on the bone first affects the weakest portion, and rupture of one or more capillary loops is liable to occur, with the formation of a hæmatoma.

Juxta-epiphyseal hæmatomata have been demonstrated during necropsy in children who have died from multiple injuries. Also osteomyelitis of the lower end of the femur usually commences towards the posterior part of the epiphyseal line. The explanation is that strains in connection with the knee joint occur when the joint is extended, in which position the brunt of the force is borne by the posterior ligament, and transmitted to the posterior part of the epiphysis, with consequent formation of a hæmatoma at that site.

(ii) *An Infective Focus.*—Such conditions as infected scratches, impetigo, pediculi, etc., allow organisms to enter

the blood-stream. A hæmatoma in any situation then forms an excellent culture medium, in which organisms rapidly multiply and possibly increase in virulence.

(iii) *Lowered General Resistance.*—The disease is common in industrial areas, where overcrowding occurs and children are ill-fed. In such places as naval schools, where minor injuries from games, etc., are common, and infected abrasions frequent, acute osteomyelitis is very uncommon, as the general health of the boys is excellent.

Pathology.—The causative organism in the majority of cases is the staphylococcus aureus, other organisms which are less frequently responsible being the staphylococcus albus, pneumococcus, and streptococcus.

The local effects depend upon the actual site of infection, which travels along the lines of least resistance. If infection commences near the surface of the bone a subperiosteal abscess is likely to form. Provided such an abscess is opened early necrosis of bone is minimal. If infection occurs nearer the centre of the epiphyseal line extension occurs along the medullary cavity. The changes associated with inflammation of bone are peculiar, in that the vessels in the unyielding bony canals become compressed by exudate, and thrombosis with arrest of circulation follows, with inevitable necrosis of adjacent bone. This extending inflammation may affect the whole of the diaphysis, and sooner or later reaches the periosteum, which is stripped up as the collection of pus extends beneath it. Owing to the firm attachment of the periosteum to the epiphyseal cartilage, subperiosteal pus is unlikely to invade the neighbouring joint, unless the epiphyseal line is intra-articular, as in the case of the head of the femur and olecranon process. Pus finally bursts through the periosteum, and tracks under muscles or finds its way to the surface. If the patient survives, the necrosed bone forms a sequestrum, the surrounding periosteum becoming extensively thickened to form an involucrum, which is perforated by cloacæ through which pus and spicules of dead bone escape from the cavity surrounding the sequestrum, and so reach the surface.

Clinical Features.—The symptoms usually commence abruptly, the child complaining of severe pain near the end of a bone, the pain being aggravated by movement. Shivering or an actual rigor may occur, and the general symptoms of infection are present.

The severity of the general signs of infection depends on the virulence of the organism and the resistance of the patient. In severe cases the child may be comatose as a result of profound toxæmia ; more usually elevation of the temperature by 2° or 3°, and associated increase in pulse-rate indicates a more moderate degree of infection.

The local signs depend to some extent on the depth of the affected bone. Thus, if the bone is well clothed by muscle, as in the case of the lower end of the femur, a localised area of tenderness is the most definite sign to be discovered in the early stages. In the case of a subcutaneous bone, such as the tibia, redness and œdema of the skin, in addition to local exquisite tenderness, will be present in the early stages. In both cases movements of the limb are painful, and may be strongly resented. At a later date thickening of the periosteum is palpable, and sympathetic effusion occurs into the neighbouring joint. Unless efficient treatment is adopted or a fatal issue results, the local signs of pus become increasingly obvious, a painful brawny area appears which gradually softens, and finally an abscess bursts through the skin, the resulting sinus leading down to the bone by a more or less direct route.

Differential Diagnosis.—*Acute Arthritis.*—This is an intra-articular condition, and therefore the slightest movement of the joint is painful. In cases of osteomyelitis associated with "sympathetic" effusion, a few degrees of painless movement can usually be obtained, and the maximum pain is near the end of the bone rather than over the joint. If any doubt exists, some of the fluid should be aspirated for examination.

Acute rheumatic arthritis is often polyarticular, and associated with characteristic acid sweats. As in any variety of acute arthritis, the slightest movement of the

joint causes intense pain. Awaiting the results of salicylates is to be condemned.

Cellulitis and Erysipelas.—If the affected bone is subcutaneous, redness and œdema rapidly involve the overlying skin. Constitutional symptoms are usually more marked in the case of acute osteomyelitis, and the changes in the skin remain more localised. A small wound or abrasion can usually be discovered in the case of cutaneous infection.

Acute Exanthemata and Typhoid Fever.—These conditions may be suspected on account of the profoundly toxic and even comatose condition of the patient. Careful palpation of the iliac bones and the ends of the long bones is necessary, and if pressure over a localised area induces resentful movements or moaning, then the possibility of osteomyelitis should be considered.

Acute Abdominal Conditions.—Acute osteomyelitis may occur in a vertebra or in connection with an iliac epiphysis. In the former case pain may be referred to either or both sides of the abdomen, while involvement of the right iliac bone may somewhat resemble acute appendicitis. If a history is obtainable, and a careful examination is made, mistakes should be avoided.

Complications

General.—(i) *Toxæmia.*—Some degree of toxæmia is inevitable, but in fulminating cases toxæmia may be so profound as to be fatal. In the case of long-continued suppuration, e.g. in connection with the upper end of the femur or the ilium, chronic toxæmia may eventually proceed to amyloid disease.

(ii) *Septicæmia.*—Should be suspected if shivering, rigors, or an intermittent temperature are present. Infection of any serous membrane is likely to occur, particularly of the pericardium.

(iii) *Pyæmia.*—In the acute stages this condition is fatal, for infected emboli are carried to the lungs. Plum-coloured, wedge-shaped infarcts occur, with a small quantity of blood-stained fibrinous fluid in the pleural cavity. Increased respiration, cyanosis, and patches of bronchial breathing are indicative of this complication. Acute pyæmia is particularly liable to occur if the bone involved consists largely of cancellous tissue, e.g. ilium or scapula.

In addition to these acute manifestations, chronic septicæmia and pyæmia may occur and give rise to abscesses in

any part of the body, particularly in other bones. These abscesses may reveal themselves at any time from the first few days of the disease, or not until after the lapse of many years. In the latter case intermittent pain is complained of near the end of a long bone, with perhaps transitory effusion into the adjacent joint during an exacerbation. The condition is often considered to be "rheumatic," but examination reveals thickening of the bone, and a radiograph shows sclerosis around a central cavity.

These chronic staphylococcal abscesses were first described by Sir Benjamin Brodie in connection with the head of the tibia. Free exposure and curretting are necessary, and the cavity is found to contain jelly-like granulation tissue rather than actual pus.

FIG. 653.—Acute osteomyelitis of the lower end of the femur, complicated by a spontaneous fracture and acute infective arthritis of the knee joint, the cartilage of which is partially destroyed.

Local Complications.—(i) *Bone.*—Spontaneous fracture may occur, especially if a single bone, e.g. the femur, is extensively destroyed (fig. 653).

Deformity sometimes follows from interference with the epiphyseal line. Tissue adjacent to the focus of infection is destroyed, but around this area a zone of hyperæmia exists, which encourages increased growth. Thus, if the destructive area is sufficiently extensive to affect the epiphyseal line, growth is arrested, but if infection is more

localised the hyperæmic zone will stimulate epiphyseal activity and cause growth to be more rapid. The whole or part of the epiphysis may be affected, and thus regular or irregular growth, or an increase or diminution of growth, results.

Deformity also results from extensive necrosis of bone. If the shaft of a single bone is destroyed, contraction of soft tissues is likely to occur and lead to gross deformity. If two bones are present the normal growth of one bone will eventually cause deformity if the growth of its partner is arrested, e.g. continuance of growth of the fibula tends to push the foot inwards, so that a varus deformity results.

(ii) *Joint.*—Acute infective arthritis occurs in a variety of ways :

(*a*) A subperiosteal abscess bursts into the periarticular tissues, and pus invades the joint through a weak part of the capsule, e.g. where it is pierced by a blood-vessel.

(*b*) Pus may track along a tendon which passes into the joint, e.g. biceps, popliteus.

(*c*) Very occasionally the infection destroys the epiphyseal line and so directly invades the joint. This complication may occur in young children attacked by a virulent organism.

(*d*) The epiphyseal line may be wholly or partly intra-articular, as in the case of the head of the femur, olecranon process, and inner side of the head of the humerus.

(*e*) Any joint may be affected by blood-borne infection, including the joint adjacent to the initial lesion.

(iii) *Muscles and Tendons.*—Extensive œdema occurs in the neighbouring muscles, and effusion in the tendon sheaths. This predisposition to stiffness is encouraged by the desirability of fixation of the limb during the acute stage of inflammation. As soon as possible movements must be instituted in order to prevent serious stiffness, particularly in the case of the wrist and ankle, which are surrounded by tendons.

(iv) *Nerves.*—Are rarely involved by fibrosis.

(v) *Blood-vessels.*—Secondary hæmorrhage occasionally occurs, particularly if a large artery is adjacent to the affected bone. Thrombosis of the popliteal vein may give rise to troublesome œdema.

(vi) *Special sites.*—e.g. osteomyelitis of the pubic bone

sometimes causes hæmaturia, or involvement of the skull is likely to give rise to sinus thrombosis via the emissary veins, or meningitis by direct extension.

Treatment.—All stages of severity of infection are encountered. On the one hand constitutional symptoms are slight, and moderate delay may be justifiable in the hope that the condition may abort, whereas in other cases toxæmia is so profound that even a primary amputation promises but a slender chance of survival.

However, in the common type of case between these two extremes, emergency operation is indicated, the bone being exposed by the most convenient route, such as :

Upper End of Femur.—Between the tensor fasciæ femoris and gluteal muscles on the outer side, and sartorius and rectus femoris medially.

Lower End of Femur.—Between the biceps and vastus externus, or alternatively between the latter muscle and the rectus femoris.

Upper End of Humerus.—Between the deltoid and pectoralis major muscles, the cephalic vein being displaced inwards.

Lower End of Radius.—From the outer side, between the supinator longus and the extensor muscles and tendons.

The *tibia* and *ulna* are exposed on their subcutaneous surfaces.

The bone having been exposed, the periosteum is incised. In early or mild cases the only abnormality found is that the periosteum is easily separable from the bone, which shows increased vascularity. If general evidence of infection is slight, the wound is lightly packed with gauze soaked in some mild antiseptic, and a splint or other support is applied. If after twenty-four hours signs of infection show no remission, the wound is reopened, and the medullary cavity explored by drill or trephine. If a bone drill is used it must be of large size, as small holes are liable to become blocked by granulation tissue before infection has subsided. In the more common cases of longer duration or more severe infection pus is found under the periosteum, which is partially stripped from the bone. The medullary cavity is then opened by means of a bone-drill, trephine, or gouge, so that any pus present in the bone may have a ready exit. The older procedure of guttering the bone and scraping away the marrow until free bleeding occurred is now aban-

doned in favour of these more conservative measures, as extensive removal includes bone which would otherwise recover when intra-medullary tension is relieved, and prolonged convalescence is necessary before bone is re-formed. When the medullary cavity has been sufficiently explored the wound is lightly packed as before, with such antiseptics as eusol, flavine, or carbolised paraffin. Splints are then applied so as to immobilise the limb. On the following day the packing is removed, and continuous eusol irrigation expedites healing. Occasional syringing with hydrogen peroxide assists in the separation of sloughs and the removal of debris. If subsequent necrosis occurs, the resulting sequestrum will need removal. Sequestra may be felt with a probe, and are distinguishable from normal bone by their rough surface. Removal should be performed when they are felt to be loose, a fact which may be verified by radiography. If delay is permitted after the sequestrum has separated, increasing difficulty will be encountered as the involucrum becomes more dense.

In severely toxic cases, which occur in large bones, such as the femur, immediate amputation affords the only chance of recovery. Owing to lymphangitis, infection of the stump is certain to occur, and therefore in order to obviate further toxæmia a "guillotine" amputation is indicated. This consists of dividing skin, muscles, and bone at the same level, so that no flaps are sewn over the infected stump. As a modification, skin flaps may be fashioned and stitched back over the stump, and if infection subsides they are sutured over the raw surface a few days later, but the principle must not be violated that any discharge is free and unhindered.

Special reference must be made to the *fibula*, as resection of the shaft of the bone yields excellent results and reduces convalescence to a minimum. When osteomyelitis occurs the shaft of the bone is exposed by a free incision and separated subperiosteally by means of a Doyen's raspatory, and the diaphysis resected with due regard for the external popliteal nerve. The wound is either closed or lightly stitched according to the extent of infection, and healing occurs in a few weeks. The bone is gradually re-formed from the remaining sheath of periosteum (fig. 654).

A recent method of treatment of osteomyelitis (Winnett Orr) consists of obtaining wide exposure and efficient drainage of the bone. The wound is swabbed with some antiseptic, such as iodine in spirit, and packed with vaselined

gauze, with no attempt at closure. Frazer recommends packing with gauze soaked in flavine, liquid paraffin, and potassium citrate. The last prevents coagulation of blood and exudate and so promotes drainage. The limb is then encased in plaster of Paris and left undisturbed for several weeks. Immuno-transfusion is useful if toxic symtoms persist and cause anxiety. Although the wound is bathed in decomposing pus healing progresses in a satisfactory manner. Apparently the only objection to this line of treatment is the accompanying odour of stale pus. On the other hand, the discomfort and labour of frequent dressings are avoided, and convalescence is shortened.



FIG. 654. — Showing regeneration of the fibula after diaphysectomy; skiagraph taken eight months after operation.

This method is also advocated for chronic cases, such as compound fractures with necrosis of bone.

It is the experience of most surgeons that acute osteomyelitis is much less virulent than formerly. This is probably due to improvement in the health and nutrition of children, and consequently treatment tends to be more conservative. In most cases the best results are obtained by a limited operation on the bone combined with Winnett Orr's method of treatment.

INDICATIONS FOR AMPUTATION

(i) *Fulminating cases* with profound toxæmia.

(ii) *Acute Infective Arthritis.*—In this case two severe foci of infection are present, either of which threaten life. Also, should the limb be saved at the risk of the patient's life, its ultimate function will be gravely impaired as a result of infection of bone, stiffness of muscles, and disorganisation of the joint.

(iii) *Secondary hæmorrhage* after the usual procedures for its arrest have been adopted unsuccessfully.

(iv) *Spontaneous Fracture.*—Usually occurs in cases of virulent infection and extensive destruction, and even if the limb is eventually saved, its function will be seriously impaired.

(v) *Deterioration of the Patient's Condition.*—In spite of efficient treatment, the general condition of the patient may gradually deteriorate as a result of prolonged toxæmia. In more severe cases the presence of septicæmia or pyæmia may demand amputation.

Finally, although the patient is not seriously ill, the onset of *amyloid disease* due to prolonged suppuration may be the deciding factor in favour of amputation.

Mention must be made of a subacute form of osteomyelitis due to *B. typhosus.* This condition occurs at any period of the disease or during the ensuing two years. The bones most commonly affected are the skull, tibia, or ribs, and the inflammation commences in the periosteum. Secondary infection sometimes follows, and incision and scraping are usually necessary.

Acute Traumatic Osteomyelitis

arises as a result of infected wounds, e.g. compound fractures, operations on bones, following amputations, etc. The constitutional disturbances are less severe than in cases of infective osteomyelitis, as the causative wound provides some measure of drainage. More extensive opening of the wound, removal of bone, or even amputation may be necessary.

Syphilitic Diseases of Bone

Syphilis may affect the osseous system during either its congenital or acquired manifestations.

Congenital.—(i) Osteochondritis of the nasal septum is the first manifestation. Necrosis of cartilage follows, and the resulting discharge causes "snuffles." Characteristic depression of the bridge of the nose follows destruction of its support.

(ii) Craniotabes of the vault of the skull occurs during the first six months, as a result of absorption of bone. This condition is merely a constitutional effect, and is likely to occur in any debilitating disease, e.g. rickets, diarrhœa.

(iii) Parrot's nodes may appear on the skull during the early years. They consist of patches of periostitis, and if the parietal bones alone are affected, a "natiform" head results; if the frontal bones are involved, so that there are four bosses, the term "hot-cross bun" is sometimes applied. Similar patches of periostitis may affect the long bones.

(iv) *Epiphysitis.*—Occurs towards the end of the first year, the epiphyseal line being broader than usual and yellowish in colour. Separation may occur, and occasionally

infection follows, resulting in so-called "pseudo-paralysis." Periostitis usually extends from the epiphysis along the shaft of the bone, forming a fusiform swelling, unlike the abrupt expansion of the epiphysis associated with rickets.

(v) *Dactylitis.*—Is a rare manifestation which occasionally occurs in severe cases. The osteitis commences centrally, and a marked periosteal reaction occurs.

(vi) *Overgrowth and Curvature of the Tibia.*—Usually appears towards puberty. The curve is only in an antero-posterior plane, and affects the whole bone. The anterior border of the tibia is rounded, and no buttress

FIG. 655.—Hutchinson's teeth, characteristic of congenital syphilis. (Mr. J. H McCurrich.)

in the concavity is necessary, as the tibia is sclerotic and therefore stronger than a normal bone. These features distinguish the curved tibia of syphilis from that of rickets. The condition is probably due to excessive and irregular deposition of bone. Formerly, the curvature of the tibia was considered to be due to fixation at either end of the elongating bone by the fibula, but in other cases, in which increase of length of the tibia occurs, it is found that the fibula is avulsed from the tibia at its upper articulation.

(vii) *Teeth.*—Hutchinson's notched and peg-shaped teeth affect the permanent incisors (fig. 655), and Moon's turret-teeth, so called from the absence of the central cusp, occasionally occur in the permanent molars.

Acquired.—In the *secondary* stage osteocopic pains may occur, due to localised patches of periostitis. If the case is unduly severe or inefficient treatment is adopted, permanent periosteal nodes may remain.

As a result of *tertiary* syphilis a variety of osseous changes occur; the following are those usually described :

(*a*) *Periosteal Gumma.*—Single gumma arising in the periosteum characteristically occur in the tibia and manubrium sterni, although other bones may be affected. A firm, slightly tender swelling appears, which is obviously connected with the underlying bone. As the swelling

FIG. 656.—Perforations of the hard palate, resulting from tertiary syphilis. (R C.S. 3951 1.)

enlarges the superficial structures are progressively involved, until eventually the skin shows a reddened area which covers indurated tissues. Eventually the skin softens, and the gumma discharges, a punched-out or serpiginous ulcer resulting, the floor being temporarily covered by a wash-leather slough. Secondary infection is probable, and necrosis of bone then follows.

The nasal septum and hard palate are not uncommonly affected. In these situations extensive necrosis of bone occurs, commonly resulting in perforation of the septum or palate (fig. 656).

Multiple periosteal gummata occur characteristically on the skull. Although common in the East, owing to more efficient treatment this condition is now rare in civilised

countries, but the "worm-eaten" skulls of previous sufferers are common museum exhibits. The local signs are similar to those described above, but early secondary infection occurs owing to the depth of the hair follicles in the scalp. Necrosis of bone follows, but sequestra may require years before separation is complete, owing to relative avascularity of the compact bone, and associated endarteritis.

Treatment consists, in addition to the usual antisyphilitic remedies, in local application of mercurial lotion. Attempts to remove a sequestrum before separation is complete may result in spread of infection to the meninges, or via emissary veins to the intracranial venous sinuses.

(*b*) *Endosteal Gumma.*—Syphilitic osteomyelitis occurring in the tertiary period affects the shafts of long bones. It is an increasingly uncommon condition, but when it does occur errors of diagnosis are likely, and many a limb has been sacrificed unnecessarily under the impression that the bony enlargement was malignant, e.g. periosteal sarcoma. Perhaps in no other situation does syphilis more justly deserve its title of "the great imitator."

The symptoms of syphilitic osteomyelitis consist of aching pain in the bone, boring in character, particularly when the limb is dependent, or at night when covered by warm bedclothes. On examination some local swelling or venous dilatation is often seen, and palpation reveals thickening of the bone, due to associated periostitis. General examination of the patient frequently reveals other signs of the disease, and the Wassermann reaction may be suggestive. X-ray shows marked sclerosis and periostitis, the superficial bone being deposited in the long axis of the shaft, in distinction from right-angled spiculation sometimes to be seen in cases of periosteal sarcoma. Exploration should be undertaken in doubtful cases.

Even vigorous antisyphilitic treatment may fail to relieve the constant pain associated with an endosteal gumma, owing to the protection afforded by the surrounding zone of thickened bone, which prevents remedial substances in the blood from reaching the affected area. Hence trephining or

"guttering" the bone is sometimes necessary so as to open up the medulla and allow the re-establishment of an adequate blood-supply to the interior of the bone (fig. 657).

(c) *Diffuse Sclerosis.*—This consists of thickening of all or any of the periosteal, cancellous, or medullary elements of a bone. The skull and shafts of the long bones are those most commonly affected, and in long-standing cases such a degree of density occurs that the medullary cavity is obliterated.

FIG. 657.—An endosteal gumma, which has been trephined in order to relieve pain.

Tuberculous Disease

Tuberculous disease of bone is secondary to some other tuberculous focus, the organisms from which reach the bone either via the blood-stream, as from deep-seated glands, or by direct invasion from an adjacent lesion, e.g. tuberculous arthritis. The disease commences either in the interior of the bone, or in the periosteum. (For tuberculous disease of the spine, see page 616.)

(a) **Endosteal tuberculosis,** other than that due to direct invasion, occurs in either an epiphysis, or commences in the cancellous tissue of the affected bone. In the case of a long bone, infection usually commences near one end, where the nutrient vessel breaks up into capillaries in which the bacilli lodge.

Tarsal and carpal bones are commonly affected, and children appear to be particularly susceptible to infection of the phalanges (tuberculous dactylitis).

Tuberculous osteitis is insidious in onset, and for some weeks or months the patient may be conscious only of slight weakness or aching, particularly after use. On examination some puffiness may be noticed, and palpation reveals slight thickening of the periosteum, due to œdema. At a later stage the skin becomes shiny, the bone is definitely thickened and tender, and muscular wasting is evident.

Finally, a subperiosteal abscess forms, which destroys the periosteum and finds its way to the surface, the last stage being represented by sinuses which lead down to the bone, and allow the entry of secondary infection.

Necrosis of bone occasionally occurs in cases of tuberculous osteitis, but sequestra are usually small and spiculated. With the advent of secondary infection bony destruction is greatly hastened.

Careful clinical examination often reveals other active or latent tuberculous foci, and X-ray examination shows rarefaction of bone, i.e. the density is diminished owing to absorption of calcium, and the pattern is blurred on account of destruction of trabeculæ.

(*b*) **Periosteal tuberculosis** most commonly affects the flat bones, e.g. the ribs, sternum, or skull. Infection commences in the deeper layers of the periosteum, which becomes œdematous, and is soon separated from the underlying bone by granulation tissue. Caseation and abscess formation follow, the superficial structures becoming progressively adherent and invaded, while the bone itself is eroded. In the case of a rib the abscess extends along the bone in a characteristic manner. Finally, the skin is involved and the abscess discharges on the surface, which allows access to secondary infection. X-rays show erosion of the bone if the condition has advanced sufficiently.

Treatment.—As with tuberculous disease in any part of the body, this depends upon the functional value of the part affected, and the risk entailed should conservative treatment fail to arrest extension of the disease.

Thus tuberculous disease of a rib is treated by excision of the affected portion of bone. If pus is present it is mopped away and the cavity smeared with B.I.P.P. before closure. The loss of part of a rib is of little moment to the patient, and speedy convalescence should be assured. In the case of osteitis of a tarsal bone, with the exception of the os calcis, removal should be advised, partly to shorten convalescence, but chiefly to obviate the risk of extension of infection to the tendon sheaths and synovial membranes.

This latter consideration especially applies to the bones on the inner side of the foot which are in apposition with the common synovial sac, and through the medium of which infection readily spreads to other tarsal bones.

In cases in which early operative treatment would entail grave disability, conservative measures must be adopted. Immobilisation is essential, and counter-irritation or Bier's passive congestion may be applied. General treatment, including heliotherapy, receives due consideration. The success of conservative measures is indicated by an improvement in the general condition of the patient and diminution of local tenderness and swelling ; also in the case of endosteal infection radiography reveals a ring of sclerosis around the affected area. If conservative measures fail, then the bone should be thoroughly scraped, the resulting cavity swabbed with B.I.P.P. or iodoform emulsion, and the wound carefully closed. If abscesses appear, aspiration is performed, and if sinuses form and persist in spite of surgical measures, excision of the bone, or even amputation, is sometimes necessary.

Rickets

Although rickets is not fundamentally a disease of bone, yet the characteristic bony changes may be considered with advantage in this chapter.

It is now known that rickets is a deficiency disease, the essential cause being lack of antirachitic vitamin D, which is a component of natural fats and oils. In addition, lack of sunshine, and insufficient ingestion of calcium and phosphorus, are contributory factors.

The pathological changes which occur mainly affect the epiphyses, the cartilages of which are enlarged both longitudinally and laterally. In addition, the epiphyseal line, as seen on section, is strikingly irregular. The zone of provisional calcification is either absent or represented by irregular patches, and therefore no definite line of demarcation exists between the proliferating cartilage and the medullary spaces. Instead of being composed of bone, the walls of the medullary spaces are formed of osteoid tissue,

which contains no calcium salts, and is not laminated, while the medullary spaces are filled with vascular fibro-cellular tissue instead of normal bone marrow. The deformities associated with rickets are due to lack of rigidity of this osteoid tissue. As the disease is overcome, calcium salts are deposited, and the deformed bones become normal in texture, or in some cases even denser than normal.

Deformities are due to inability to bear the body weight, to the influence of posture, or the constant pull of muscles bending the softened bones to which they are attached.

Clinical Features.—The child is usually flabby, and sweating of the head is common. It is particularly susceptible to respiratory and gastro-intestinal disturbances, and the abdomen becomes protuberant owing to enlargement of the liver and spleen, and flatulence. Umbilical hernia is common as a result of prolonged distension.

Fig. 658.—Rickets in an adolescent girl, showing bow legs, curved tibiæ, and enlarged epiphyses.

Bony developments cause restlessness and peevishness, and the child, on account of epiphyseal tenderness, resents being handled. As the disease progresses deformities appear, among which the following are typical:

Epiphyseal Enlargement.—The increased width of the epiphyses can usually be felt. As the child uses the limbs, compression of the softened epiphyseal line may cause visible swelling, and as the child crawls before it walks the enlargement is first obvious at the wrists, and later at the ankles (fig. 658). These swellings disappear as the disease fades, and the formation of periosteal bone causes increased width of the shaft.

Long Bones.—Bending of the long bones is more marked in the legs on account of standing and walking. Natural curves are exaggerated, and thus the femur shows increase of the normal anterior curve. The linea aspera may be thickened to form a buttress. Bending of the neck produces a corresponding degree of coxa vara.

The tibia is characteristically bent in two places. An abrupt kink occurs in the lower

third of the bone, the portion below this being bent backwards and inwards. A well-marked buttress formation occurs in the concavity, and the anterior border of the bone is sharp, owing to lateral compression of the shaft.

Bending of the bones of the arms indicates a severe degree of rickets. The radius and ulna are bent backwards, and the humerus outwards at the site of the insertion of the deltoid.

Ribs.—The "rickety rosary," due to beading of the costo-chondral junctions, is of the same nature as epiphyseal enlargements. The swelling is more pronounced on the posterior surface. Harrison's sulcus has been attributed to diaphragmatic pull, but the groove fails to correspond with the attachment of this muscle. It is probably due to abdominal distension "spreading" the lower ribs.

The Skull.—Craniotabes occurs as a result of any severe constitutional disturbance, and if associated with rickets is most obvious in the region of the lambdoid suture. Closure of the fontanelles and dentition are always delayed. As the skull develops it becomes broader and flatter than normal, and the increased width between the eyes indicates broadening of the base.

The Spine.—The child is tardy in its efforts to sit up. Kyphosis constitutes the first spinal deformity, which may be followed by scoliosis due to posture or to inequality of the legs.

The Pelvis.—Two types of deformity may result. In the flattened type the conjugate diameter is diminished, while if the lateral walls are approximated a tri-radiate deformity results.

Stature.—Diminution in stature is due to various reasons. The actual growth of bone is retarded, especially that of the tibia and femur, which are alleged to be one-quarter shorter than those of a normal child of equal size and age. Also the weight of the body compresses the softened epiphyses. This is well marked in the case of genu valgum, as the growth of the weight-bearing external condyle is repressed. Diminution of stature is also emphasised by bending of the bones of the legs, and by spinal deformities.

Treatment.—Early recognition and appropriate treatment are rewarded by ready response. Fresh milk, cod-liver oil, and meat extracts are administered as freely as the child will digest them, and judicious exposure to natural or artificial sunlight or ultra-violet rays is beneficial. The child's activities are curbed by means of light splints, but some degree of movement is desirable, otherwise efficient circulation is discouraged.

Early bony deformities respond to appropriate splinting. In the case of the tibia osteoclasis may be necessary, and should be performed during the third or fourth year. Before this age splinting should be given a trial, and when the child is older osteotomy is preferable.

Osteoclasis is performed by resting the leg on a rubber-covered wedge, the leg lying on its outer side. Pressure is applied so that the fibula and then the tibia snap opposite the site of maximum deformity. Care must be taken to grasp the lower end of the bone as close to the deformity as possible, as cases have occurred where the lower epiphysis has been separated. The deformity is corrected, and a plaster of Paris casing applied for three weeks; the subperiosteal fracture readily unites during that period.

In older children or adults osteotomies, either linear or cuneiform, are sometimes necessary.

SCURVY RICKETS

Scurvy rickets is occasionally seen in children whose mother, for social or other reasons, weans them at an early age. Most prepared foods are deficient in vitamins, and the antiscorbutic vitamin appears to be particularly susceptible to heat.

The disease commonly appears between the sixth and tenth months, and in addition to rickety changes of a variable degree, evidence of scurvy is superadded. This latter condition is evinced by subcutaneous or submucous hæmorrhage, subperiosteal extravasations which are markedly tender (they have been mistaken for acute osteomyelitis), and in more advanced cases by sponginess of the gums and even hæmaturia.

If neglected, the disease may progress to a fatal issue, preceded by separation of epiphyses, melæna, and emaciation.

Treatment consists in the administration of such antiscorbutic remedies as fresh juice, cabbage water, mashed potato and cream.

Due attention is paid to the associated rickety element.

LATE RICKETS

Late rickets is a rare disease which occurs during puberty or adolescence. In some cases careful enquiry and examination suggest that it is due to a recrudescence or relapse of the ordinary type of this disease. In a typical case of late rickets the head is not affected, and bending of the bones occurs close to the epiphyses. Treatment is conducted on the lines already suggested for infantile rickets.

A similar condition may occur in communities subjected to great privations, as was the case in Vienna during the Great War. This disease occurred in the middle-aged and old people, and was ill-advisedly termed "hunger osteomalacia." Severe pain occurs in the bones, which are tender on palpation. Bony deformity occurs in advanced cases. As with infantile rickets, ingestion of substances containing fat-soluble A vitamin results in rapid improvement.

Osteitis Deformans

This condition, first described by Sir James Paget in 1876, occurs more commonly in men, and usually commences between the third and fourth decades, although obvious signs are not noticeable for many years.

The changes which occur in the bones cause enlargement and softening. Atrophy of the compact tissue and

absorption of the calcium salts weaken the bone, and at the same time spongy subperiosteal bone is deposited.

The skull is usually enlarged, although this is not invariable.

Three stages are described, the first being the vascular stage, in which the skull is brick-red in colour and soft in texture. Advancing sclerosis then follows, the skull being markedly thickened and deeply grooved for meningeal vessels. Finally, complete diffuse sclerosis ensues, the diploic zone being almost obliterated (fig. 659). The cranial cavity is but slightly diminished in volume, as the increase in thickness of the skull is almost entirely eccentric.

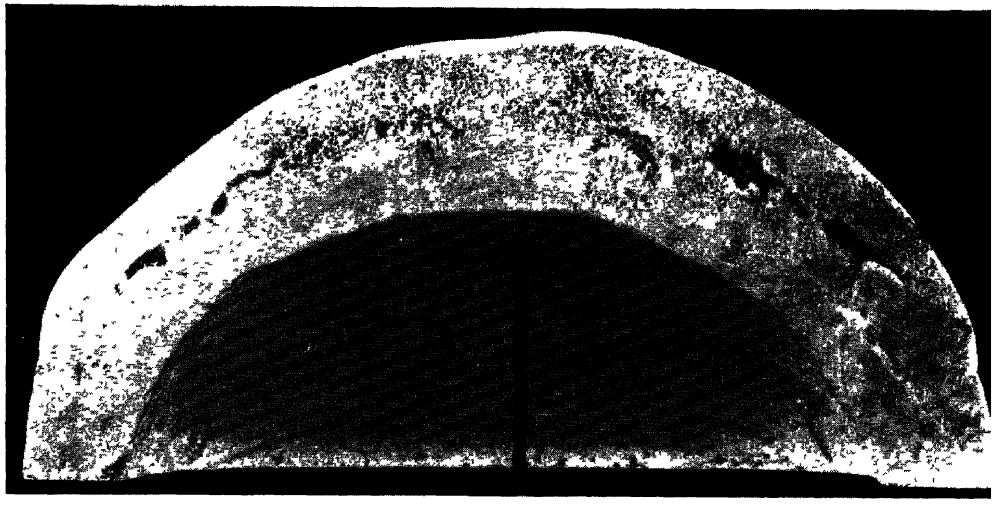

FIG. 659.—Paget's disease of the skull. (R.C.S. 705.1.)

The most striking change in the spine is the development of kyphosis, due to softening and yielding of the vertebral bodies. Cases of paraplegia have occurred owing to diminution in calibre of the spinal canal, and improvement has been effected by laminectomy (fig. 660).

The long bones are affected by two processes—absorption of original, and especially the compact bone, and deposition of vascular porous bone. An eccentric enlargement and elongation follows, and bending occurs readily, as although the bone is more bulky rigidity is diminished (fig. 661). After a period of many years the porous bone gradually becomes dense, so that eventually the deformed bones are hard

and heavy, i.e a permanent state of complete sclerosis. Some degree of coxa vara usually affects the femoral necks.

The pelvic bones and clavicles are commonly affected in the early stages. The facial bones, base of the skull, jaw, and ribs are only involved in the minority of cases.

Clinical Features.—(i) *Pain.*—Is the most constant symptom, and is usually complained of for years



FIG. 660 —A lumbar vertebra from a long-standing case of Paget's disease, with narrowing of the spinal canal. (R.C.S. 3826.2.)

FIG. 661.—A tibia from a case of Paget's disease. (R.C.S. 3823.1.)

before the cause is realised. The tibia is one of the first bones to be affected, and the disease may remain localised in a single bone for years. The pain is intermittent, and in the case of a subcutaneous bone redness of the overlying skin occurs during exacerbations.

(ii) Diminution of stature, even up to 13 in., due to kyphosis and bending of the long bones of the legs.

(iii) Increased diameter of the head, an early indication of which may be the necessity for larger hats.

(iv) Spontaneous fracture is not uncommon, and may first bring the patient under supervision. Radiographs occasionally reveal partial fracture, and probably a spontaneous fracture occurs in stages.

Complications.—Myelomatosis occurs in about 5 per cent. of cases. These endosteal tumours do not disseminate, and resemble myelomata, except that reaction of the adjacent bone is absent.

Calcification of the arteries may be very obvious, and is probably due to the same cause as the disease itself.

Necrosis of small areas of bone may occur in late stages as a result of excessive sclerosis interfering with the circulation.

Osteoarthritis occurs in joints adjacent to deformed bones, owing to alteration in the mechanics of the joint. Spontaneous fractures and paraplegia have already been mentioned.

Treatment.—As in the case of other obscure conditions, chronic toxæmia is considered to be either the actual or a contributory cause. Therefore any obvious foci of infection should be eradicated, in the slender hope that the progress will be delayed. Ultra-violet rays appear to relieve pain, otherwise analgesics are given, and supporting apparatus may be necessary to hinder deformity. Potassium iodide ("the morphia of bones") often relieves pain in this condition, as with most chronic inflammations of bones.

Possibly Paget's disease is due to unbalanced action between the parathyroids and the suprarenal glands, resulting in increased activity of the former, and deficient function of the latter. Cases are reported which have improved with suprarenal cortex extract combined with a high calcium diet.

Osteitis Fibrosa

(i) The generalised form, which is also known as Recklinghausen's disease of bone. This type usually commences in the second decade, and diffuse cystic changes are widely scattered throughout the skeleton, particularly the long bones and skull. Fractures, pain, bending of bones, and grotesque deformities occur, so that the patient becomes bedridden.

It has been recently demonstrated that cases of generalised osteitis fibrosa have an unduly high calcium content in the blood, often as high as 16–18 mgm. per 100 c.c. instead of the normal 10 mgm. Also a tumour of one of the parathyroid bodies is present in these cases. Although the tumour is not obvious on clinical examination, yet a careful exploration is rewarded by its discovery, either embedded in the thyroid gland, or lying at a lower level in the mediastinum. Removal is followed by an immediate drop in the calcium content of the blood, rapid amelioration of symptoms, and later by reconstruction of the affected bones.

(ii) *Local Cyst.*—This is the common form of the disease, and this type usually appears at the end of the first

FIG. 662.—Local cyst of bone in the lower end of the ulna, showing a clear, expanded cavity (child, aged 4 years).

decade. The condition most frequently occurs at the end of a long bone or in the skull. Coxa vara sometimes follows a cyst in the femoral neck. Cysts in other bones attract the patient's attention either because of spontaneous fracture or swelling, depending on whether the affected bone is clothed with muscle or subcutaneous. Radiography shows a clear cavity in the bone, which is expanded (fig. 662). Trabeculation, so characteristic of a myeloma, is absent.

The disease is presumed to be toxic in origin, although some authorities consider that the cysts represent attenuated myelomata. Treatment consists in exposure of the bone and curettage of the cyst, which contains straw-coloured fluid, and is lined with a fibrous wall in which giant cells have been

demonstrated. There is no abnormality of the calcium content of the blood, nor any parathyroid derangement in connection with local cysts of bone.

OSTEOMALACIA

Osteomalacia is rare in this country, although in some localities, e.g. certain regions in the Himalayas, it is by no means uncommon. Nine-tenths of cases occur in females, mostly during the child-bearing age. Pregnancy sometimes appears to be the cause of the disease, and undoubtedly causes the disease, if already present, to run a more rapid course.

The changes in the bone consist of decalcification of the osseous framework and metaplasia of the resulting matrix and medulla to

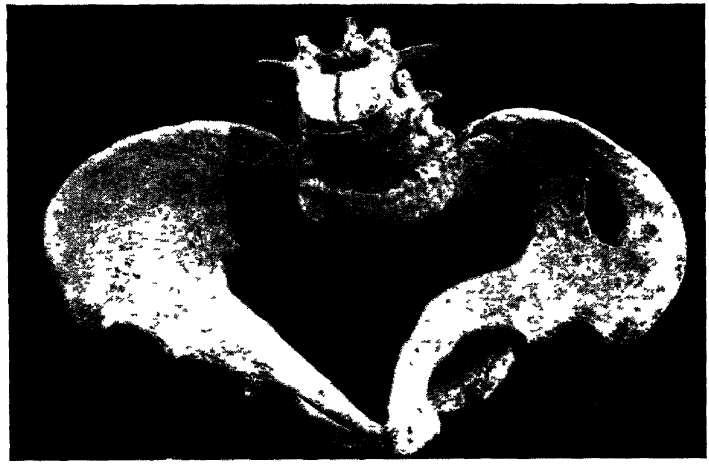

FIG. 663.—Pelvic deformity due to osteomalacia. (R.C.S. 560.)

fibro-cellular tissue. The compact bone may become as thin as paper, and the marrow represented by fatty fibro-cellular tissue of a vascular nature, which has been likened to liver or splenic pulp. An excessive amount of calcium phosphate is excreted in the urine, and calculi sometimes occur in the kidneys.

The main symptom is pain in the bones, which is deep-seated, and aggravated by movements or pressure. Lassitude and asthenia follow, and gross deformities (fig. 663) and fractures become increasingly in evidence. The disease usually lasts from three to six years, the bed-ridden patient eventually succumbing to asthenia or intercurrent disease.

Treatment is symptomatic, although cases have improved after removal of the ovaries (provided the menopause has not been reached), or hysterectomy and double ovariotomy, if the patient is pregnant. Foci of infection are sought for and eradicated.

Evidence exists which suggests the possibility that osteitis deformans, osteitis fibrosa, and osteomalacia are different manifestations

of the same disease. Thus, portions of bone from a case of osteitis deformans when examined microscopically appeared to be identical with the changes to be found in osteitis fibrosa. Also, tissue typical of osteitis fibrosa has been found in a humerus removed from women who died as a result of osteomalacia.

Possibly these three conditions are caused by a similar toxin, the reaction on the part of the bone depending on its powers of resistance under different circumstances. Thus if bone resistance is good, the noxious effects of toxins are delayed until middle age, and porous bony reaction occurs, resulting in osteitis deformans. If the affection commences in childhood, a less vigorous reaction occurs, and deposition of fibrous tissue very inadequately compensates for the bony absorption, and osteitis fibrosa follows. In the most severe cases, where the patient's vitality is seriously undermined, and especially if subjected to the strain of pregnancy, reaction is feeble, and a cellular response only is possible, with resulting osteomalacia.

LEONTIASIS OSSEA

This condition consists of a creeping periostitis of the bones of the face and skull. The probable cause is some infection spreading from the nose, accessory sinuses, or possibly teeth. The periostitis is arrested for variable periods at the suture lines, thus the squamous portion of the temporal bone may be greatly thickened and raised above the surface of the skull, while the parietal and frontal bones remain unaffected for years. Eventually the suture line is crossed, and the periostitis creeps on over another bone. The lower jaw becomes implicated, infection presumably reaching it by way of the buccinator muscle and pterygo-mandibular ligament, as the periostitis commences at the attachment of these structures.

The early symptoms may be those of lachrymal duct or nasal obstruction. The facial bones then become enlarged, and adjacent bones are successively attacked. Eventually hideous deformity results (fig. 664), and the patient's sufferings are increased by pressure on the eye, brain, and cranial nerves as they emerge from the skull.

Leontiasis ossea has been mistaken for sarcoma of the maxillary antrum, osteitis fibrosa, and "frog face," due to displacement forwards of the maxillæ by nasopharyngeal tumours. Treatment consists of dealing with any discoverable infection, otherwise it is symptomatic.



FIG. 664.—The skull and lower jaw from an advanced case of leontiasis ossea. (R C.S. 1359.1.)

OSTEOGENESIS IMPERFECTA

This rare familial condition is due to some congenital defect in the evolution of the connective tissue cells. Normally, some of these develop into fibrous tissue, and those in connection with the osseous system become bone-forming cells. The blue sclerotics so characteristic of this disease are not due to diminution in thickness, and no abnormality can be detected on microscopic examination. The translucency is therefore due to some peculiarity of the fibrous tissue, which suggestion is supported by the fact that another associated abnormality is an increased tendency to sprains.

In the case of bone, the evolution of osteoblasts is interfered with, and development stops short at the formation of cartilage cells.

Clinically the condition is characterised by an abnormal tendency for bones to fracture. Thus the fœtus may be still-born, the skull being represented by a membranous bag with a few small bony plates, and evidence of antenatal fractures is common. In the infantile type the child is born alive, but the fragile limbs break with distressing ease. In less severe cases fractures begin to occur in childhood or adolescence, and Wormian bones persist in the skull. The fractures are less painful than those occurring in normal bones, and although union occurs readily, deformity is common owing to the frequency and comparative painlessness of the fractures.

Treatment consists of dealing with fractures as they arise, and of protecting the patient from the risk of injury.

TUMOURS OF BONES

Innocent : Chondroma. Osteoma.

Intermediate : Myeloma.

Malignant : (*a*) Primary—Sarcoma. (*b*) Secondary—Sarcoma, Carcinoma.

Chondroma

These tumours arise in connection with the epiphyseal cartilage. Rickets has been blamed as a contributory factor, owing to the irregularity of the epiphyseal line in that condition. However, chondromata are no commoner in rickety than in normal children. The tumours consist of hyaline cartilage, the cells of which are irregular in shape and arrangement.

Chondromata may be conveniently classified according to the type of bone from which they arise :

(*a*) **Small Bones of the Hands and Feet.**—As these tumours arise within the bone they are termed enchondromata. They most commonly appear during childhood. The affected bone becomes gradually and painlessly expanded, and the local condition may suggest dactylitis. However,

the more advanced age of the patient and the absence of evidence of local inflammation or of any general manifestation of disease should prevent an error of diagnosis. A radiograph shows a clear expansion of the bone, similar to that seen in connection with a bone cyst (fig. 665). If allowed to grow, destruction of the bone is inevitable. In long-standing cases small areas of calcification appear in the tumour, and finally myxomatous degeneration may occur.

Treatment consists of scraping out the tumour through a postero-lateral incision, which passes between the extensor tendon and the digital vessels and nerve. Prognosis should be guarded, as enchondromata are sometimes multiple.

An X-ray sometimes reveals small enchondromata in other digits, which have not expanded the bone sufficiently to call attention to their presence.

FIG. 665.—Enchondroma of the distal phalanx of the thumb, with the opposite normal bone for comparison.

(*b*) **Long Bones.**—Chondromata commence under the periosteum in the region of the epiphyseal line, but as growth proceeds and the bone lengthens they remain stranded in the shaft. Thus, if the tumour originates in a small child near the growing end of a long bone, by the time adult life is reached it may be some inches from the end of the bone. As the tumour projects from the surface of the bone, to which it is attached by a pedicle, the term "*ecchondroma*" is applied.

An ecchondroma forms a hard, fixed, and painless swelling near the end of a bone. Occasionally some lobulation may be discernible. If the tumour is not interfered with it ossifies when the epiphyseal line from which it arises joins the shaft, and a cancellous osteoma results.

As ecchondromata never undergo malignant change, and cease to grow when the bone ossifies, removal is only indicated if symptoms necessitate that procedure, such as:

(i) Displacement of adjacent muscles or tendons, causing a sensation of weakness owing to interference with their efficient action. Occasionally a tendon becomes hitched around the tumour in certain positions of the limb, a condition known as a " snapping " tendon.

(ii) Interference with joints, or, more rarely, vessels or nerves.

(iii) Inflammation of an overlying adventitious bursa, e.g. on the inner side of the knee in a cavalryman.

(iv) Fracture, due to direct violence or muscular action.

(v) Cosmetic reasons, e.g. upper end of the humerus in women who desire to wear low evening dress.

If removal is indicated care must be taken to chisel through the base of the tumour close to the parent bone, so that none of the cartilaginous " cap " of the tumour is left, otherwise recurrence is possible.

(*c*) **Flat Bones.**—These tumours grow from such bones as the ribs, scapula, and pelvis, and form characteristically hard and painless swellings. However, they may remain unnoticed until myxomatous degeneration causes a sudden increase in size, in which case errors of diagnosis are common. Thus a chondroma of the rib may be mistaken for a sarcoma, or a pelvic enchondroma which has undergone myxomatous degeneration may be mistaken for a broad-ligament cyst, as in both cases a fixed cystic swelling is detected on pelvic examination.

Osteoma

Osteomata are of two varieties, ivory or cancellous. **Ivory** osteomata are uncommon but are occasionally found on the skull, particularly in connection with bones which bound the orbit or air sinuses (fig. 666).

Treatment is only indicated when pressure symptoms result, e.g. deafness from auditory obstruction, displacement of the eye, or involvement of nerves. Owing to the density of these tumours, removal should be effected through adjacent normal bone, as chiselling through the dense base is liable to cause concussion.

Cancellous osteomata are comparatively common tumours,

and are formed as a result of ossification occurring in an ecchondroma. Thus they occur near the ends of long bones; the physical signs are identical with those of an ecchondroma, and treatment should be conducted on the same lines.

A *subungual exostosis* is an irregular bony outgrowth under the nail of the big toe, which is lifted off the underlying phalanx. Although included in this section this condition must not be confused with a neoplasm, as it is due to pressure of an ill-fitting boot and consequent

FIG. 666.—An ivory osteoma growing in the region of the frontal air sinus. (R.C S. 1390.1.)

periosteal irritation. The nail should be removed or displaced, and the bony excrescence excised by means of a chisel or bone-cutting forceps.

Myeloma (*syn.* Osteoclastoma)

A myeloma occurs most commonly in the end of a long bone, particularly in the vicinity of the knee joint. Myelomata also occur in the skull and lower jaw, and in the latter situation they constitute one variety of epulus. Similar tumours are occasionally found at the site of tendinous insertions, and are then probably derived from misplaced endosteal cells.

Myelomata usually occur during the third or fourth decades of life, and are presumed to arise from osteoclasts, which are giant cells normally engaged in absorption of

bone. Clinical features depend upon whether the affected bone is subcutaneous or surrounded by muscle. In the former case a swelling is first noticed, which is somewhat abrupt and painless.

Expansion of the bone follows, which process consists of destruction of the bone from within, while at the same time new periosteal bone is formed (fig. 667). This new



FIG. 667.—A myeloma of the upper end of the fibula, showing abrupt expansion of bone, and trabeculation.

formation of bone occurs more slowly than the destructive process, so that the bone becomes larger but progressively thinner, and eventually "egg-shell crackling" may be detected. Finally, the growth erodes the compact bone, and a soft, pulsating swelling results. Owing to refinements of diagnosis the final stages are rarely seen in civilised countries.

In the case of deep-seated bones enlargement and consequent destruction of the bone may be unnoticed, and the first evidence of the presence of the tumour may be a spon-

taneous fracture. This is especially liable to occur in the femur or humerus, which are unsupported bones.

Owing to the slow rate of growth of these tumours, pain is not a marked feature. When a large myeloma is adjacent to a joint, e.g. the lower end of the femur, a sympathetic effusion may occur as a result of local hyperæmia. A radiograph confirms the abrupt expansion of the bone, and presents a stippled or mottled appearance, due to bony trabeculæ which traverse the cavity.

Macroscopically a myeloma appears as a soft, maroon-coloured tumour, with localised extravasations of blood. A definite bony septum usually separates it from the medullary cavity, and bony trabeculæ intersect the softer portions. On section characteristic myeloplaxes are strikingly evident; these large cells, about 120 μ in diameter, are irregular in shape, and contain from twelve to fifteen deeply staining nuclei. The remainder of the tumour consists of spindle cells, extravasated blood, and numerous blood-vessels. "White" myelomata occasionally occur, usually at the lower end of the radius.

Treatment.—Until recently it was believed that myelomata were only locally malignant, but a more careful "follow-up" shows that in about 8–10 per cent. of cases metastases occur, usually in the lungs. These deposits contain no giant cells, and are possibly due to an osteogenetic sarcoma developing in the myeloma. This indicates that curetting, which was the standard treatment of former years, should only be countenanced in situations unsuitable for more radical treatment, such as the lower jaw or upper end of the femur. A course of deep X-ray therapy must always follow curetting. If it is considered advisable to curette the tumour, the bone is opened with a gouge or chisel, and the growth scraped away with a sharp spoon, care being taken not to penetrate the adjacent articular cartilage. The cavity is swabbed with pure carbolic acid, any excess being removed with spirit. If necessary the cavity is reduced in size by compression of its walls, or a muscle graft may be inserted. If the cavity is small it is sufficient to allow it

to fill with blood-clot. Precautions must be taken to obviate excessive hæmorrhage, and therefore a tourniquet is applied, or a vessel tied in continuity, e.g. ligature of the external carotid above its superior thyroid branch, as a preliminary to scraping a myeloma of the lower jaw.

In most cases one of the three following procedures will be preferable to curettage :

(*a*) If removal of the bone will cause little disability then excision is performed, e g. rib, metacarpal, or fibula.

In the case of the fibula the external popliteal nerve must be isolated above the swelling, as it lies under the tendon of the biceps, and its anatomical relations in the region of the tumour will be distorted. The nerve is traced downwards and held aside, and the fibula is divided and cleared of muscles from below upwards. If possible the head of the fibula is spared, otherwise the external lateral ligament and tendon of the biceps must be sutured to the periosteum of the outer tuberosity of the tibia.

(*b*) In certain situations, if the affected bone is indispensable for adequate function, excision and insertion of a bone graft should be considered.

Thus the upper end of the humerus is excised and a graft inserted into the medullary cavity below, and wedged into a slot cut in the glenoid cavity above. Similarly, after excision of the lower end of the radius a graft may be fixed into a hole drilled in the scaphoid below, and impacted into the radius above.

(*c*) In the case of extensive destruction of the lower end of the femur or head of the tibia, amputation is usually performed. Although bone-grafting has been successfully accomplished, the convalescence is tedious, and as the knee joint must of necessity be bridged by the graft, the end result is a rigid leg.

In neglected cases amputation may be necessary in any situation on account of invasion of the soft tissues, or in the event of recurrence after less drastic measures.

Myelomatosis is a rare condition in which multiple endosteal tumours occur. Locally the condition causes destruction of bone with less reaction than a single myeloma, i.e. no septum forms between the tumour and medullary cavity, and trabeculation is less evident, so that the X-ray appearance suggests secondary carcinoma (fig. 668). Microscopically large giant cells are present with thirty to forty nuclei. A proteose appears in the urine, first described by Bence-Jones, which precipitates on the addition of nitric acid, and disappears on warming.

FIG. 668.—Extensive destruction of one half of the sacrum, due to myelomatosis. (Dr. J. W. Linnell's case.)

This condition may also occur as a complication of osteitis deformans. Death results from cerebral compression in the case of skull involvement, or some intercurrent disease in a bedridden sufferer.

SARCOMA

Primary sarcoma of bone may originate as a parosteal, endosteal, or periosteal tumour.

Parosteal sarcomata are spindle-celled tumours which arise at the site of insertion of tendons or muscles, and should therefore be regarded as tumours of these structures rather than of the bone itself. Local and free excision, including the periosteum in the neighbourhood, occasionally results in cure, but incomplete removal is likely to be followed by recurrence of the tumour with increased malignancy.

Endosteal sarcomata, either round- or spindle-celled, are uncommon tumours, and have been confused with myelomata and periosteal sarcomata which have eroded the compact bone and invaded the medullary cavity. A true endosteal sarcoma usually commences in the medulla of a large bone, e.g. the head of the tibia. As growth is rapid, pain is a prominent feature, and the bone is eroded and destroyed rather than expanded. Eventually a spontaneous fracture occurs, or the appearance of a soft pulsating swelling indicates that the bone is extensively destroyed. The

presence of enlarged superficial veins, and possibly an effusion into the neighbouring joint, indicate the vascular nature of the tumour. Dissemination occurs, at first by the blood-stream, but when soft tissues are invaded the lymphatic system is also involved.

A confident diagnosis is always difficult in the early stages; in addition to a myeloma and periosteal sarcoma already mentioned, such possibilities as an endosteal gumma or secondary deposit must be considered. The X-ray appearance of an endosteal sarcoma shows destruction of the compact bone from within, with little reaction of the bone, such as expansion, sclerosis, or periostitis. In doubtful cases exploration is essential, and even if early amputation is performed, dissemination by the blood-stream has probably occurred already. Should the bone be eroded with consequent invasion of the soft parts, then prognosis is almost as gloomy as that of a periosteal sarcoma.

A rare but characteristic form of endosteal sarcoma, known as Ewing's tumour, occurs usually in the small bones of the hands or feet, or the skull. These endosteal tumours grow rapidly, and are extremely vascular, so that the painful enlargement of the bone associated with hyperæmia may suggest an inflammatory rather than a neoplastic condition. A radiograph shows endosteal destruction of the bone. The prognosis is poor, even after amputation, and secondary deposits frequently occur in other parts of the skeleton, especially the skull. Deep X-ray therapy causes striking retrogression of these tumours, and even secondary deposits may disappear.

Periosteal sarcomata are fortunately not common, as they constitute a tumour which is perhaps only second in malignancy to melanoma malignum.

This variety of sarcoma most commonly occurs during puberty or adolescence, and is practically unknown after the age of 50. The favourite sites are the ends of the shafts of long bones, and the lower extremity is affected five times as often as the upper.

Owing to the rapid growth of the tumour, pain is an early symptom, and on examination of the affected part distended veins are often seen, which indicate the vascular nature of the growth. On palpation a spindle-shaped swelling of the bone is detected, at first elastic in consistency, but

pulsatile in the later stages. Eventually soft tissues are invaded, and finally the tumour involves and fungates through the skin. Dissemination occurs in the early stages, the lungs being commonly affected via the systemic veins, and if the patient survives long enough these deposits occasionally ossify. A blood-stained pleural effusion is sometimes the first evidence of pulmonary involvement.



FIG. 669.—Fusiform swelling and spiculation in the case of a periosteal sarcoma of the tibia.

Secondary deposits also occur via the lymphatic system, and other bones are frequently affected.

The radiographic appearances of periosteal sarcoma vary according to the degree of malignancy of the tumour. If rapidly destructive erosion of the bone is the principal feature, but if the tumour is of moderate malignancy, then characteristic spiculation is evident ("ladder pattern") (figs. 669 and 670). This phenomenon is due to separation of the periosteum from the bone, and formation of bone by osteoblasts on the walls of the blood-vessels which pass from the bone to the uplifted periosteum. In cases which

FIG. 670.—Macerated specimen of a periosteal sarcoma of the upper end of the humerus, showing characteristic spiculation.

are of slow growth, fusion of the bony spicules results in the formation of an irregular osseous mass surrounding the normal bone from which the tumour originates, and erosion of the compact bone is masked by the ossifying tumour (fig. 671).

The treatment of a periosteal sarcoma can be summarised as follows :

(*a*) *Amputation.*—Is the usual procedure, providing the diagnosis is accepted, and should be performed well above the tumour, i.e. if possible with one intervening joint between the site of amputation and the tumour. In the case of the femur or humerus,

FIG. 671.—Ossifying sarcoma of the malar bone. (Mr. W. B. Gabriel's case.)

disarticulation should be performed through the hip or shoulder joint (fig. 672). However, even after amputation, the prognosis is gloomy, but pain is relieved and the distress associated with fungation is obviated.

(*b*) In certain situations local excision of the affected bone and the insertion of a bone graft have been adopted. In support of this method it has been urged that earlier permission is given for this method, as compared with amputation. Also in the early stages local recurrence is unlikely, and if secondary deposits have occurred, even amputation cannot retard their progress. Hence in situations where bone grafting yields poor results, particularly in the upper limb, the arm may be saved, and cases are on record where this line of treatment has been adopted, and the unmaimed patient has survived for many years.

(*c*) *Conservative Measures.*—Coley's fluid, which consists of a sterilised culture of *B. prodigiosus* and the streptococcus of erysipelas, appears to be useless, at any rate in this country, although Coley himself claims a small percentage of cures. The initial dose is half a minim, gradually increased until a definite reaction is produced, with elevation of temperature by 3° or 4°, and perhaps a rigor. Injection of the fluid into the growth enhances the reaction. A suitable dose is given every other day, and at the end of two weeks response is indicated by diminution in the size and vascularity of the tumour. If no effect has been obtained, the treatment should be abandoned, as further injections are unlikely to have any other effect than still further undermining the health of the patient.

FIG. 672.—The appearance after a fore-quarter amputation.

Radium and radon check the growth of sarcomata, but sarcoma cells are less sensitive to radium than those of carcinoma. X-ray therapy is usually more convenient, in that large masses

of tissue or deep deposits, e.g. intrathoracic, can be irradiated.

Prognosis.—Out of 650 cases collected by the American Registry of Bone Sarcoma, only seventeen *appear* to have been cured—sixteen after amputation, and one following treatment by radium.

Recurrence within a year is likely to occur in viscera or other bones if the primary growth is situated near the trunk. In more distant tumours recurrence commonly occurs within three years, although we have known a case in which a secondary deposit appeared in the spine thirteen years after amputation through the thigh for periosteal sarcoma of the tibia. Thus the time limit for a "cure" is almost unlimited.

An X-ray of the chest may reveal secondary deposits in the lungs, and is of value in estimating the expectation of life.

Secondary Tumours

Carcinoma.—Carcinoma of bone occurs either by direct extension, as in the case of the chest wall following carcinoma of the breast, or by metastasis.

Secondary deposits are liable to occur particularly as a result of a primary growth in the following situations :

(i) *Breast.*—Is the commonest cause of secondary carcinoma of bone, the favourite situations being the spine, upper end of the humerus, and the neck of the femur.

(ii) *Kidney.*—Any bone is liable to be affected, perhaps most commonly the pelvis. A bony swelling or a spontaneous fracture is sometimes the first evidence of a carcinoma of the kidney.

(iii) *Bronchus.*—Carcinoma of a bronchus appears to be increasing in frequency, and secondary deposits in bones are not uncommon.

(iv) *Prostate.*—The clavicle, for no obvious reason, is commonly affected. Occasionally the shaft of a long bone is infiltrated with growth, causing bending (osteomalacia carcinomatosa). More commonly diffuse sclerosis occurs in the pelvic bones, and it is probable that this invasion occurs via the lymphatics, which stimulates bone reaction and

causes sclerosis, whereas blood-borne metastases result in absorption of bone.

(v) *Thyroid.*—The flat bones, especially the vertex of the skull, are likely to be affected. These tumours in particular are very vascular, and apparently are capable of function, as after complete thyroidectomy for carcinoma the post-operative myxœdema has disappeared on the appearance of secondary deposits.

Secondary deposits usually cause considerable pain, and if occurring in the vertebræ pain is liable to be referred along spinal nerves. In most cases a swelling eventually becomes palpable ; the presence of superficial veins and possibly pulsation indicate the vascular nature of the tumour. Spontaneous fracture is common, and if immobilised, union sometimes occurs, in distinction from spontaneous fractures caused by sarcoma, which never reunite.

A radiograph shows irregular destruction of bone with little or no surrounding reaction unless fracture has occurred, in which case evidence of callus formation may be seen.

If a tumour in connection with bone is suspicious of a secondary carcinoma, then the common primary sites must be carefully examined. Carcinoma of the breast, prostate, or bronchus can usually be detected with ease. The presence of a slowly growing carcinoma of the kidney is often difficult to ascertain in the absence of hæmorrhage, but a pyelogram will usually show some distortion.

Primary carcinoma of the thyroid gland is sometimes so unobtrusive as to be impalpable, or a tumour which clinically appears to be a simple adenoma may disseminate.

Osteochondritis Juvenilis

Various lesions, the pathology of which is doubtful, are grouped under this term. Certain epiphyses are commonly involved, and also some bones which develop from a single ossific centre may be affected. The essential changes consist of partial arrest and irregularity of growth, followed by sclerosis. Trauma appears to be a causative factor, especially the cumulative effect of repeated minor strains. For

instance, Schlatter's disease has been known to follow training for cross-country running, and Osgood's disease has occurred after dancing lessons. A speculative theory is that small aseptic emboli cause obstruction to arteries supplying the affected bone, and the consequent interference with nutrition is reflected in the irregular growth.

In all cases symptoms are relatively mild, and comprise aching of the affected limb and local tenderness. If the affected portion is palpable, e.g. the tibial tubercle, enlargement can be detected.

Symptoms are relieved by adequate rest and relief of strain, and little disability results if the condition is recognised before gross bony changes have occurred.

The more important of these conditions are :

Perthes' disease (*syn.* coxa plana, pseudo-coxalgia). This condition appears between the ages of 5 and 10, slightly more common in boys than girls, and 15 per cent. of cases are bilateral. Until this condition was recognised and adequately described, it was confused with tuberculous arthritis. Slight pain, especially after vigorous use, and limp, are the early symptoms. On examination, wasting is slight, and movements are restricted according to the extent of bony change. Thus as the head of the bone becomes flatter so inversion and eversion are progressively restricted, and if coxa vara supervenes, then abduction also is limited. Flexion and extension, however, are free and painless, and this feature, combined with negligible wasting of muscles, and the robust health of the patient, should prevent an erroneous diagnosis of tuberculous disease. As with other chronic conditions, e.g. coxa vara, traumatic arthritis may be superimposed and cause painful limitation of all movements. In these cases a week in bed will result in the disappearance of the recent traumatic element and its associated muscular spasm, after which the characteristic features of the underlying condition can be recognised.

A radiograph shows, in the early stages, slight flattening of the head of the bone, which is appropriately termed

"mushroomed," and the epiphysis is seen to be represented by two or more nuclei. At a later stage the neck becomes thickened, and the epiphyseal fragments fuse to form an expanded flattened head of the femur.

The rational treatment would appear to consist in the restriction of movements and limitation of weight-bearing, as by the application of a walking calliper. However, many cases seem to make an equally good recovery in the absence of any local treatment other than limitation of activity.

Schlatter's disease is much commoner in boys than girls, and appears between the ages of 10 and 16. It is frequently preceded by some unusual strain. The tibial tubercle becomes unduly prominent and somewhat tender on pressure. A radiograph shows partial separation of this tongue-shaped portion of the epiphysis from the shaft. If the affected part is supported by strapping, local tenderness disappears in from three to six months, but enlargement persists for a much longer period.

Osgood's disease, or apophysitis of the os calcis, affects the epiphysis of the heel, which is present between the tenth and sixteenth years. This condition forms one variety of painful heel. A radiograph shows fragmentation and irregularity of the epiphysis. Symptoms abate with appropriate rest.

Köhler's disease affects the scaphoid tarsal bone, and occurs about puberty. The bone is at first enlarged and tender, but later is compressed and sclerotic.

Keinboch's disease of the semilunar bone of the wrist occurs between the ages of 18 and 40. In most cases a history of injury is obtainable, which is followed by pain and tenderness over the bone. Finsterer's sign is sometimes present, and consists of sharply tapping the head of the third metacarpal when the fist is closed. If the sign is positive, pain is felt in the region of the bone. Treatment consists in immobilisation for six months in order to encourage regeneration. If sclerosis occurs the head of the third metacarpal becomes less prominent. In some cases, on account of persistent pain and disability, the bone has been removed through an incision passing between the tendons of

the extensor longus pollicis and the extensor communis digitorum.

Madelung's deformity (*syn.* manus valga) may be included in this group of diseases, and occurs in girls at the period of adolescence. Deficient growth of the lower radial epiphysis results in relative elongation of the ulna, so that the hand is displaced outwards and forwards. It is stated that the condition is liable to occur in typists.

Calvé's epiphysitis is another member of this group of diseases, and affects the epiphysis of a vertebra. It is commoner in boys than girls, and appears about puberty.

RENAL DWARFISM

Is a rare condition, due to renal insufficiency during childhood, as a result of a condition similar to chronic interstitial nephritis, or, more rarely, polycystic kidneys. Thirst and polyuria, followed by headache and vomiting, are the symptoms which should suggest renal disease, but cardio-vascular changes are absent. The blood urea content is markedly increased, and may be as high as 300 or more mgm. per cent.

Bony deformities appear at any age, and in the early years

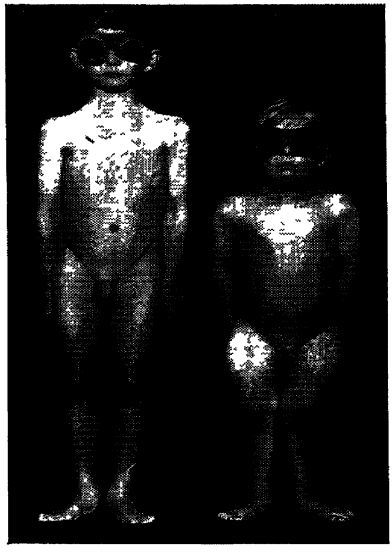

FIG. 673.—A renal dwarf, with a normal child of the same age for comparison. (Dr. Schlesinger's case.)

FIG 674.—An X-ray of the left leg of the dwarf in fig. 673, showing osteoporosis of the comparatively straight epiphyseal lines. Displacement of the epiphyses has not yet occurred.

separation of epiphyses may occur. After the first decade the changes somewhat resemble adolescent rickets, and deformity follows (fig. 673). Deformity occurs chiefly at the epiphyseal line, and is due to displacement of the epiphysis rather than to bending of the shaft of the bone, a point which distinguishes this condition from true rickets (fig. 674).

Death from uræmia is seldom delayed beyond puberty, and is hastened by any operative interference, e.g. osteotomy.

FIG. 675.—An achondroplasic infant. (R.C.S. 93.1.)

ACHONDROPLASIA

This familial condition is due to maldevelopment of bones arising from cartilage. Thus the stature is markedly diminished and the limbs in particular are stunted. The legs are obviously short, and the finger-tips reach only to the great trochanters, the arms thus resembling flippers (fig. 675). The fingers themselves diverge, so that they resemble the spokes of a wheel. The base of the skull, being developed from cartilage, is small in proportion to the vertex, so that the prominent forehead causes the bridge of the nose to appear to be depressed. Mental development is normal, and no cause has yet been discovered.

ANOSTEOPLASIA (*syn.* CRANIO-CLEIDO DYSTROPHY)

The counterpart of achondroplasia, in that it is due to failure of development of bones arising in membrane. Thus the vertex of the

skull and clavicles are ill-formed, so that the head appears flattened, and as the buttress action of the clavicles is lost the heads of the humeri are approximated to and may articulate with the sternum. This condition is appropriately termed cranio-cleido dystrophy, and is a rarer abnormality than achondroplasia.

DIAPHYSEAL ACLASIS (*syn.* MULTIPLE CONGENITAL OSTEO-CHRONDROMATA)

This rare disease is hereditary, and is characterised by cartilaginous and osseous outgrowths from the neighbourhood of the epiphyseal line. These multiple swellings first appear about puberty, and are associated with diminution of stature and deformities, such as coxa vara and genu valgum. Bones which develop from membrane are unaffected. Sarcomatous changes have been reported in a few cases.

ACROMEGALY

This condition is due to excessive secretion of the anterior lobe of the pituitary gland occurring in adult life. The early signs are enlargement of the hands and feet, at first confined to the soft tissues, but later bony thickening also occurs. The jaws enlarge, especially the lower, which becomes prognathic, and separation of the teeth indicates that the enlargement is partly interstitial. Overgrowth of facial bones also occurs, especially of natural ridges and at the sites of muscular attachment. The lips, nose, and ears show a variable amount of thickening. When the disease is well established, the spine becomes kyphotic in the dorsal region.

As the disease is associated with new-growth and enlargement of the pituitary gland, symptoms of increased intracranial pressure supervene. Vision is affected, partly owing to this general increased pressure, and also as a result of local pressure of the enlarged gland on the optic chiasma giving rise to bilateral temporal hemianopia. More rarely an optic nerve is displaced, so that it is compressed by the circle of Willis, with consequent blindness of the corresponding eye. Involvement of the trigeminal nerve, and proptosis from pressure on the cavernous sinus, to which the ophthalmic veins pass, sometimes occur.

A radiograph will demonstrate any existing enlargement of the sella turcica (fig. 553).

Operation should be undertaken only for intolerable headache or threatened blindness.

The trans-sphenoidal route is useful if the sella turcica is seen in

FIG. 676.—A large pituitary tumour, with expansion of the sella turcica. (R.C.S. 48.1.)

the radiograph to be expanded downwards. The nasal septum is removed, and the sphenoidal air cells nibbled away until the tumour is exposed, when it is either partially removed or allowed to extrude. In other cases the sella turcica is approached by the transfrontal route, an osteoplastic flap being displaced outwards in order to give access to the pituitary fossa.

FIG. 677.—Radiograph of ankle in a girl of 12, with line of arrested growth due to pneumonia one year previously. (H. A. Harris.)

Harris's Lines.—Radiographic examination of long bones in children and adolescents sometimes reveals transverse lines of compact bone near the epiphyses (fig. 677). These are due to arrest of growth which accompanies some severe constitutional disturbance.

CHAPTER XXXV

INJURIES TO JOINTS

Sprains are due to overstretching of ligaments, with consequent partial or complete rupture. The ligaments commonly affected are the external lateral of the ankle and the internal lateral of the knee. Localised pain, which may be sickening in severe cases, and tenderness over the site of the torn ligament, are immediate features. Extravasation of blood occurs in the neighbourhood of the torn ligament, and if the synovial membrane is also torn, a hæmorrhagic effusion occurs into the joint.

Treatment consists in the immediate application of a bandage soaked in a cooling lotion; cold water or methylated spirit are useful first-aid remedies. The bandage must be applied firmly so as to limit further extravasation or articular effusion. After two or three days massage and graduated movements are instituted, and subsequently care is taken to relax the damaged ligament, e.g. the boot raised on its inner side in order to relieve strain on a torn internal lateral ligament of the knee joint.

Dislocations

Dislocations are either complete or partial, the latter being referred to as a subluxation. The causes of dislocations are: congenital malformations, pathological processes, and injury.

Congenital dislocation most commonly occurs in the hip joint, and is considered in the chapter on Deformities.

Pathological dislocations are due to:

(*a*) *Destruction*, e.g. "travelling" acetabulum in advanced tuberculous arthritis of the hip joint, or subluxation of the knee joint in cases of triple deformity (*vide* p. 877).

(*b*) *Distension*, which, if excessive, may cause ligaments to stretch to such an extent that the articular ends of the bones slip apart, e.g. Charcot's joint. In cases of typhoid arthritis, softening of the ligaments predisposes to stretching, and pathological dislocation is liable to occur, even in the hip joint.

(*c*) *Paralysis* of muscles which support a joint, as in the

case of infantile paralysis of the shoulder girdle, or of the muscles around the hip joint.

Traumatic dislocations occur most commonly in adult life, as in children separation of an epiphysis is more likely. Older people are less subject to trauma, and atrophy of bone predisposes to fracture.

The liability of any individual joint to suffer dislocation depends upon its exposure to injury, the shape of the articular surfaces, and the support given by muscles and ligaments. The shoulder joint is commonly dislocated, as the glenoid cavity is shallow, and the support given to the head of the bone by muscles and ligaments is somewhat lax. Conversely, in the case of the hip, the acetabulum is deep, and muscles closely support the joint, therefore dislocation is rare.

Clinical Features.—(*a*) Pain—due to local trauma, or pressure on nerves, e.g. the displaced head of the humerus may press on the brachial plexus.

(*b*) Loss of function—fixity replaces mobility.

(*c*) Deformity. The limb is shortened or lengthened, or malalignment is present.

(*d*) The end of the bone can be detected in an abnormal position. This is the absolute sign of a dislocation. Unless the dislocation is accompanied by a fracture, movement of the shaft of the bone causes corresponding movement of the articular end.

Treatment.—Reduction should be attempted as soon as any attendant shock, or shock associated with other injuries, has passed off. In the case of large joints surrounded by powerful muscles, general anæsthesia is desirable in order to overcome muscular spasm. The path taken by the displaced bone should be visualised, and movements are carried out so that this path is retraced, and thus additional damage to soft tissues is minimised. Movements which do not stretch weakened parts of the capsule are commenced on the following day, so that the formation of articular and periarticular adhesions is discouraged. Operative measures are sometimes necessary ; thus the glenoid ligament must

occasionally be divided before the head of the first metacarpal can be reduced, and in the case of larger joints, open reduction may be required should manipulation fail.

Unreduced Dislocation

If the dislocation is not reduced within a few days, the surrounding soft structures become matted together by inflammatory exudates and extravasated blood. After two or three weeks organisation occurs, and soft tissues become secondarily contracted. As time passes the articular cartilage is replaced by fibrous tissue, and a false joint may form around the end of the displaced bone. Thus reduction becomes progressively more difficult.

The treatment of an unreduced dislocation often presents a difficult surgical problem. It is generally conceded that reduction should be attempted up to within three weeks from the date of the injury. In healthy adults who need a full range of movement this period is extended for a further three weeks. After the elapse of six weeks surrounding fibrosis and secondary contraction render success unlikely, and the risk of injury to blood-vessels or nerves, or fracture of the bone, is increased considerably. If manipulative attempts fail, open reduction is sometimes indicated. If secondary contraction has occurred excision of the articular end of the bone is preferable.

If attempts at reduction fail or are contra-indicated, then massage, exercises, and movements are adopted, and the function of the limb is frequently adequate for the needs of the patient. In a few cases such sequelæ as osteoarthritis or pressure on nerves, e.g. the head of the displaced humerus on the brachial plexus, necessitates excision of the articular portion of bone.

DISLOCATIONS OF SPECIAL JOINTS

Lower Jaw

The mandible is most commonly dislocated as a result of a blow on the chin, especially if the mouth is partly open. Dental operations, particularly those performed under general anæsthesia, and excessive yawning, are other causes.

If the dislocation is unilateral the jaw is displaced towards the opposite side, and saliva dribbles from the partially open mouth. A hollow is palpable immediately in front of the tragus, and the condyle is felt in a slightly anterior situation. In bilateral cases the mouth is fixed in a partly open position, and both condyles are palpable in front of their normal situations.

Reduction is usually performed with ease by pressing the padded thumb on the lower molar teeth, at the same time rotating the body of the jaw upwards with the fingers. A general anæsthetic is occasionally necessary. After reduction the jaw is supported by means of a four-tailed bandage for three weeks.

Sterno-clavicular Joint

Violence affecting this joint is transmitted along the clavicle, and in the majority of cases fracture of the clavicle occurs before force sufficient to cause dislocation reaches the sterno-clavicular joint. Moreover, the sturdy rhomboid ligament anchors the inner end of the clavicle to the first costal cartilage. When dislocation occurs the inner end of the clavicle is displaced forwards, backwards, or upwards, the former being the most common. Backward dislocation may cause severe dyspnœa from pressure on the trachea, or congestion of the head or arm owing to obstruction to the great veins at the root of the neck. Owing to the subcutaneous position of the inner end of the clavicle, the dislocation is readily recognised.

Reduction is effected by standing behind the seated patient and placing the knee on the upper dorsal spine. The shoulders are then drawn backwards until reduction is accomplished. If necessary, further leverage in an outward direction can be obtained by means of a pad placed in the axilla. A piece of folded lint is firmly strapped over the joint in order to prevent redislocation, and the arm is supported in the same manner as for a fractured clavicle.

The Acromio-clavicular Joint

Dislocation of this joint is not uncommon, owing to the obliquity of the articular surfaces, which are separated by an

inverted triangular intra-articular cartilage. The prominence caused by the displaced bone is readily palpable. The dislocation is easily reduced by elevation of the shoulder, but withdrawal of the support allows immediate redislocation. Treatment consists in flexing the forearm, and fixing two or three strips of broad strapping so that they exert pressure on a pad situated over the joint, and then pass under the elbow, thus encircling the arm and shoulder (fig. 678); the arm is then supported by a sling. If recurrence ensues, the bones should be approximated by means of a wire loop, which is so placed that the joint surfaces are avoided. We have found the results of this operation excellent.



FIG. 678.—Pad and strapping for dislocation of the acromio-clavicular joint.

SHOULDER JOINT

Owing to the wide range of movement, the shallowness of the glenoid cavity, and the lack of support by ligaments and muscles, particularly on the inferior aspect, dislocations of this joint are of common occurrence. In the majority of cases a subglenoid dislocation occurs, as excessive abduction of the arm brings the neck of the humerus against the coraco-acromial arch, and the head of the bone is forced downwards against the weak inferior part of the capsule. Dislocation sometimes follows a trifling injury, e.g. throwing a ball, and in these cases the condition may be overlooked.

On inspection of the shoulders an alteration of contour is obvious, unless the patient is very obese. The rounded appearance of the shoulder is lost owing to displacement inwards of the head of the humerus, and consequently the "point" of the shoulder is angular (fig. 679). The axis of the arm passes upwards and inwards, and a fullness is noticed below the outer part of the clavicle.

On palpation loss of resistance is felt beneath the acromion process, and the head of the bone is palpable on following

FIG. 679.—The contour of the shoulder:
1. Normal. 2. Dislocation. 3. Fracture-dislocation. 4. Wasting of the deltoid muscle, e.g. circumflex palsy or caries sicca.

upwards the shaft of the humerus. Pain and limitation of movement are complained of by the patient.

SPECIAL TESTS

The following tests are rarely necessary, provided that a careful examination is made, and they are only mentioned as of academic interest.

Hamilton's Ruler Test.—The acromion process and the external condyle can be connected by a straight line.

Callaway's Test.—The axillary folds are lowered, and therefore the vertical measurement around the axilla is increased on the injured side.

Dugas' Test.—Owing to the abduction of the lower end of the humerus it is impossible to place the hand of the patient on the opposite shoulder while the elbow is in contact with the chest wall.

Varieties.—With the exception of the supracoracoid dislocation, which is of necessity accompanied by fracture of the overhanging coraco-acromial arch, dislocations are primarily subglenoid. The head of the humerus thus rests in a precarious manner on a narrow ridge of bone, and usually slips forward into the subcoracoid position. Should the exciting force continue to act, the head of the bone moves further inwards, and comes to rest in the subclavicular position. Occasionally the head of the bone is displaced backwards under the acromion process (subacromial). In this position it is balanced on the posterior rim of the glenoid cavity, so that it frequently slips further inwards to the subspinous position.

Treatment.—A general anæsthetic is usually advisable, particularly in a muscular subject, or when delay has allowed muscular spasm to supervene. Care should be taken in the administration of the anæsthetic, as the patient is often ill-prepared, and sudden changes of posture should be avoided.

KOCHER'S METHOD.—The patient may be either sitting or lying down, and the scapula is steadied by a towel, which passes round the chest. The following manipulations are then performed :

(i) The elbow is flexed and adducted.

(ii) The arm is rotated outwards, so as to stretch the subscapularis muscle, which has contracted owing to the inward displacement of the upper end of the humerus. This manipulation must be performed gradually and to its fullest extent.

(iii) When full external rotation is obtained, the elbow is lifted upwards and forwards, so as to bring the head of the bone downwards into the axilla.

(iv) The arm is then rotated inwards, so that the elbow is carried across the chest, and the fingers sweep downwards across the opposite shoulder.

This method is successful in the majority of cases, and frequently reduction occurs during or at the completion of external rotation.

TRACTION.—If Kocher's method fails, traction can be applied by placing the unbooted foot in the axilla of the patient, who is lying supine. A steady pull is maintained on the forearm in an outward and downward direction.

A more scientific method of applying traction is to place the patient on a table, with a towel round the chest in order to provide a means of counter-extension. A four-inch flannel bandage is then looped round the affected arm just below the axilla. Traction is applied in an outward direction by means of the flannel bandage, and downwards by pulling on the arm itself.

Operation.—In rare cases manipulative measures fail, and then open reduction should be considered.

After-treatment consists of supporting the arm in a partially abducted position. If the arm is kept in an

adducted position, e.g. bandaged to the chest wall, the loose inferior portion of the capsule is thrown into folds which become adherent to each other, and thus return of full abduction is hindered. Massage and movements are commenced on the following day, but abduction to more than a right angle should be prohibited for one month.

Recurrent Dislocation

In cases in which after-treatment has been inefficient or in persons who are subjected to frequent injury, e.g. epileptics, weakness of the capsule persists, and it may even happen that the patient is able to dislocate a joint voluntarily. If disability results, an operation which usually gives satisfactory results is excision of a portion of the anterior part of the capsule, and firmly suturing the resulting gap. Most surgeons prefer to separate the posterior portion of the deltoid, the nerve supply being carefully preserved. The slip is passed through the quadrilateral space and sutured to the anterior aspect of the capsule, or preferably passed underneath and sutured to the subscapularis tendon. When the arm is abducted, the slip of muscle contracts, and consequently supports the under surface of the joint. It is a curious fact, which we have personally observed, that in some epileptics the number of fits diminish after an operation for recurrent dislocation.

If the patient is unsuitable for operation, e.g. owing to the frequency of fits, then an appliance is fitted which supports the joint and prevents more than limited abduction.

Fracture-dislocation

This serious accident is due to continuation of force after the shoulder has been dislocated, the fracture occurring through the surgical neck of the humerus. The condition is recognised by the fact that the head of the bone is absent from the glenoid cavity, and is palpable under the coracoid process, but rotation of the arm causes no corresponding movement of the humeral head. Crepitus may also be obtained on manipulation, and more pain and extravasation are present than in cases of dislocation only. In fat patients radiography is often necessary before a confident diagnosis is possible.

Reduction by manipulation is unlikely to be successful, owing to the small size and consequent difficulty in controlling the upper fragment. Open reduction is therefore usually necessary, the bone being exposed by an incision which separates the deltoid and pectoralis major muscles. The

upper fragment is conveniently manipulated by means of a screw-driver, which is thrust upwards through the fractured neck, and thus impales the head of the bone. Unless the fragments firmly interlock, some mechanical means of fixation should be adopted.

Complications

Fracture.—As already mentioned, dislocation of the shoulder may be complicated by fracture of the humerus, or in rare cases of the coraco-acromial arch.

Recurrent-dislocation.—*Vide supra.*

Nerves.—Any part of the brachial plexus, or the circumflex nerve, may be involved.

Vessels.—Damage to vessels is rare, but has occurred during attempted reduction of a long-standing dislocation.

Osteoarthritis of the shoulder joint is liable to follow dislocation in elderly subjects.

Elbow Joint

In cases of dislocation displacement is either forwards, lateral, or backwards, the latter being the most common. Forward dislocation is usually accompanied by fracture of the olecranon, while lateral dislocation is seldom complete. Backward dislocation usually occurs in young adults or children, and may be associated with fracture of the coronoid process, unless the patient is under the age of 14, as prior to this the coronoid process is ill-developed. The condition is distinguished from separation of the lower humeral epiphysis by the fact that the normal position of bony points around the elbow are distorted (fig. 680). Also on inspection the forearm is apparently shortened, and the measurement between the external epicondyle and radial styloid process confirms this shortening.

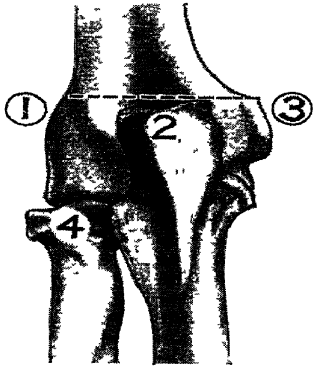

Fig. 680.

1. External condyle.
2. Tip of olecranon process.
3. Internal condyle.
4. Head of radius.

Reduction is effected by flexing the arm across the surgeon's knee, which is placed in the bend of the elbow. Massage and movements are commenced on the following day.

Dislocation of the upper end of the **radius** occasionally occurs as a congenital abnormality. In cases due to trauma the head of the bone usually passes forwards and hinders flexion of the joint. Fracture of the shaft of the ulna is commonly associated, and can be readily recognised by palpation of its subcutaneous border. Traction of the forearm, combined with pressure on the radial head, usually results in reduction, but as the orbicular ligament is torn the dislocation tends to recur. In most cases the head of the bone can be retained in position by means of a pad, the joint then being placed in the fully flexed position. If disability persists, the head of the bone should be removed.

Wrist Joint

This joint is rarely dislocated, as a severe injury is more likely to separate the radial epiphysis in children, or to cause a Colles's fracture in adults. The injury is recognised by the fact that the styloid processes retain their normal relationships, i.e. the radial process is half an inch lower than that of the ulnar. Reduction is effected by traction, and a "cock-up" splint is applied for two weeks. Massage should be commenced on the day following reduction.

Fig. 681.—Anterior dislocation of the semilunar bone.

Carpal Bones

Dislocation of the *os magnum* very occasionally occurs, the bone being displaced backwards, and forming an obvious swelling under the extensor

tendons. The bone can sometimes be reduced by applying pressure with the wrist joint flexed. If this is unsuccessful, or the dislocation recurs, then excision is indicated.

The *semilunar* bone is sometimes dislocated forwards and then interferes with movements of the wrist (fig. 681). If attempts at reduction fail the bone should be excised through an anterior incision, the flexor tendons being separated and the median nerve carefully avoided.

Metacarpo-phalangeal and **interphalangeal** dislocations can be reduced readily by traction and flexion, with the exception of the metacarpo - phalangeal joint of the thumb. Traction should be applied, and a bandage, placed as a clove-hitch round the thumb, may assist in securing a firm grip. Manipulation frequently fails, owing to interposition of the glenoid (anterior) ligament between the two bones. This tough ligament, firmly attached to the base of the phalanx, is carried backwards, and lies like a curtain between the phalanx and the head of the metacarpal (fig. 682). If manipulation is unsuccessful the ligament should be split vertically by means of a tenotomy knife, which is inserted from the posterior aspect, and passes underneath the base of the displaced phalanx. The two halves of the ligament then separate and allow the head of the metacarpal to pass between them. We have found this a most successful procedure, and in only one case have we found open reduction of the dislocation necessary.

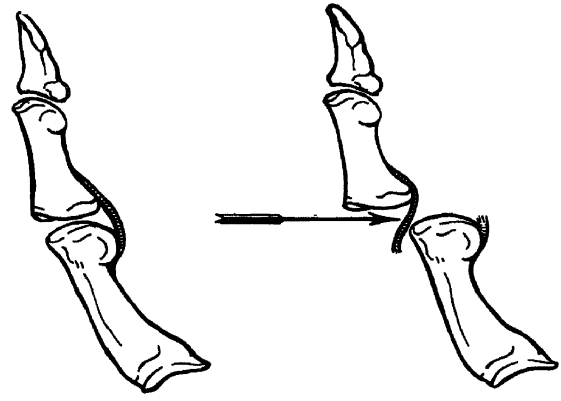

FIG. 682.—Dislocation of the metacarpo-phalangeal joint of the thumb. The arrow indicates the path of the tenotomy knife when division of the glenoid ligament is necessary.

Hip

Owing to the depth of the acetabular cavity, and the strong support afforded by ligaments and muscles, dislocation of this joint is uncommon.

The term "irregular" dislocation is applied to cases where the Y-shaped ligament of Bigelow is ruptured, or the rim of the acetabulum is fractured. If the head of the bone is driven through the acetabulum a "central" dislocation results (fig. 683).

Regular dislocation usually occurs when the thigh is abducted, as in this position the head of the bone is in contact with the relatively weak under surface of the capsule. The usual causes are such accidents as stepping sideways on to an unstable object, e.g. a boat, or a weight falling on the back of a person in a stooping position. Machinery accidents, or a horse rolling on its rider, are other occasional causes.

Anterior dislocation is either thyroid or pubic, and in both cases the limb is in a position of flexion, abduction, and eversion. In thyroid dislocations the head of the femur rests upon the obturator externus muscle, and pain may be referred along the obturator nerve, which is compressed as it passes through the upper part of the foramen. The limb is apparently lengthened. If the head of the bone slips upwards, it comes to rest upon the pectineus muscle, where it covers the ascending ramus of the pubis, and a pubic dislocation results. The limb is shortened, and pain is sometimes referred along the anterior crural nerve.

Posterior dislocations are more common than the anterior variety. The head of the bone escapes into the sciatic notch (sciatic variety), and if the tendon of the obturator internus is ruptured the femoral head then passes up into the dorsum of the ilium (dorsal variety). In both cases the leg is flexed, adducted, and inverted, so that the sole rests upon the opposite instep. Pain is sometimes referred along the sciatic nerve, and the limb is shortened.

Reduction is usually accomplished without difficulty, provided that the anæsthetist obtains adequate relaxation of the muscles. The patient is placed on a mattress on the

floor, and the iliac crests are steadied by an assistant. The surgeon stands over the limb and flexes the knee and thigh, bringing the head of the bone beneath the acetabulum.

FIG. 683.—Central dislocation of the head of the femur.

In the case of a posterior dislocation the flexed thigh is adducted and inverted. It is then externally circumducted, and rapidly straightened alongside the opposite leg. These movements were summarised by Bigelow in the phrase, "lift up, bend out, roll out."

If an anterior dislocation is present, the leg and thigh are flexed as before, and the limb placed in an adducted and everted position. It is then internally circumducted and straightened.

Should these manœuvres fail, then upward traction is employed. The patient is held down by assistants, or a towel or binder is fixed firmly across the trunk by means of staples driven into the floor. The surgeon then places the patient's flexed leg against his perineum, and folding his

arms beneath the upper part of the leg, exerts vigorous upward traction, thus lifting the head of the bone upwards into the acetabulum.

After apparent reduction the movements of the limb must be tested, as cases have occurred in which manipulation merely converted an anterior dislocation into a posterior one or *vice versa*, owing to the head of the bone rotating underneath the acetabulum. Attempts at reduction in neglected cases have resulted in fracture of the neck of the femur. After reduction the legs are bandaged together for seven days, but massage should commence on the following day. Passive movements are commenced after a week, and recurrence is most unlikely.

Knee

Complete dislocation of this joint is rare, but subluxation occasionally occurs, following rupture of one or other crucial ligament, or both. The diagnosis is usually obvious, although rapid effusion into the knee joint tends to render immediate recognition difficult. The most common direction of dislocation is forward, and the popliteal vessels are occasionally compressed by the lower end of the femur.

Reduction is effected by flexion and traction, and aspiration of the distended knee joint is often advisable. Massage is commenced in a few days, and the patient is allowed to use the limb after six weeks, the joint being supported by a knee brace. Instability sometimes persists owing to rupture of the crucial ligaments (*vide* internal derangement).

Patella

This sesamoid bone may be dislocated inwards or outwards, or become twisted, so that its anterior surface is in contact with the condyles. By far the most common direction is outwards, often in association with some degree of genu valgum. The diagnosis is readily made on palpation, and lateral dislocation causes the joint to appear broadened. Reduction is effected by laying the patient on his back with the leg and thigh extended. The quadriceps muscle is thus relaxed, and the bone can be manipulated into position.

Recurrence is common if genu valgum coexists. The obvious treatment is to correct the alignment of the leg by means of a suitable osteotomy. If no such correction is necessary, then an ellipse of capsule on the inner side of the patella should be excised, so that closure of the aperture draws the patella inwards. If this procedure fails, then the rectus femoris muscle can be shortened, but in all probability a permanent knee brace will be required.

Ankle

Owing to the deep mortise formed by the tibia and fibula, dislocation of the ankle joint, without fracture, is extremely rare. Dislocations of the astragalus are more common than formerly, as aeroplane crashes contribute a number of cases. The displacement is anterior, and the bone pushes forward the extensor tendons, or may even protrude through the skin. As reduction is usually impossible, astragalectomy is the common method of treatment.

Subastragaloid dislocation occasionally occurs as a result of severe twists or wrenches, e.g. the patient being dragged by a horse with a foot in the stirrup. If manipulation fails, open reduction must be performed.

Internal Derangement of the Knee Joint

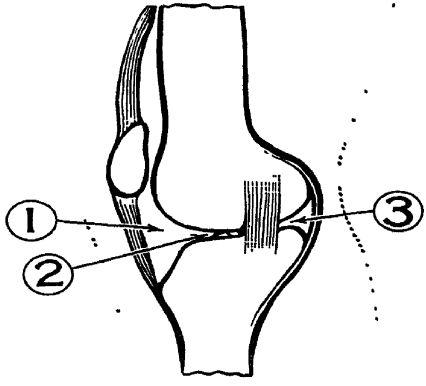

Fig. 684.—The site of pain in various forms of internal derangement: (1) synovial fringes, (2) semilunar cartilage, (3) loose body in the joint.

This term is used to include intra-articular lesions due to trauma occurring in a previously healthy knee joint. The injuries are classified in accordance with the anatomical structure involved.

Synovial Membrane.—Injury to the knee joint may result in traumatic synovitis, the synovial membrane becoming hyperæmic and œdematous. If movements are permitted before the swelling has disappeared, the thickened synovial

fringes become nipped between the articular surfaces, and thus a vicious circle is established, i.e. frequent nipping causes increased thickening, and consequently a greater liability for nipping to occur. Pain is experienced behind and on either side of the patella (fig. 684).

Hence, cases of synovitis should be carefully treated and flexion of the joint prevented until any swelling has completely disappeared. Recurrent attacks are treated by prolonged immobilisation, and counter-irritation as by Scott's dressing. If this is unsuccessful, arthrotomy must be performed and the thickened fringes excised.

Ligaments.—Partial tear or rupture of the lateral ligaments sometimes occurs, especially of the band-like internal lateral ligament, owing to the slight normal degree of genu varum. Localised pain and tenderness follows, with some hæmorrhagic effusion into the joint. Treatment consists in applying cooling lotions in the early stages, and later the strain is relieved by raising the boot about one-third of an inch on the corresponding side. In severe cases suture of the torn ligament is sometimes advisable.

The crucial ligaments are very occasionally ruptured as a result of severe trauma, such as lateral dislocation. The anterior crucial ligament alone may be ruptured in hyperextension. Undue mobility and subluxation of the joint indicate the nature of the injury; if the anterior ligament is torn the tibia can be subluxated forwards on the femur. Actual suture of the torn ligament is impracticable, as the injury is in reality avulsion of the ligament at the tibial attachment. Efforts have been made to reconstruct the ligaments by drilling the bones obliquely, and threading a strip of iliotibial band as a substitute for the anterior ligament, and the tendon of semitendinosus for the posterior ligament. Ultimate results are, however, disappointing, as these substituted struc-

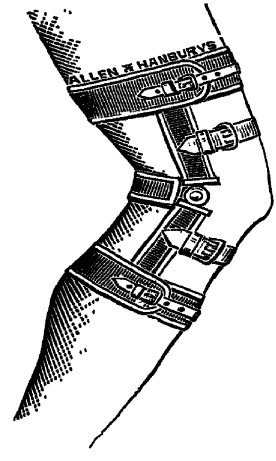

FIG. 685.—Marsh's knee splint.

tures tend to stretch. The most satisfactory treatment, should immobilisation for three months in plaster have failed, is to furnish the patient with some apparatus which steadies the knee joint, as by Howard Marsh's knee brace (fig. 685).

Cartilage.—Portions of articular or interarticular cartilage may become detached, and the resulting loose body constitutes one variety of internal derangement. More commonly a semilunar cartilage becomes torn or loosened. The internal cartilage is affected twenty times more commonly than the external, because it is attached to the internal lateral ligament, and is therefore unable to accommodate itself to rotatory movements of the corresponding condyle (fig. 686). The torn portion of cartilage becomes

FIG. 686.—Indicating the mechanism by which outward rotation of the femur is transmitted to the external cartilage, and, via the transverse ligament, to the internal cartilage, with consequent avulsion of its free border.

nipped between the articular surfaces, giving rise to sickening pain and inability to extend the joint. A rapid effusion follows, and localised tenderness is present over the interarticular groove on the inner side of the knee.

Treatment of this condition is of the utmost importance if subsequent convalescence is to be shortened and disability prevented. Reduction of the cartilage is essential, and should be performed without delay. The cartilage may be reduced by flexing the knee and hip, and placing the leg in a position of eversion and abduction to its fullest extent. Sudden inversion of the tibia and extension of the leg, e.g. by instructing the patient to kick suddenly, usually results in

reduction. Should this procedure fail, an anæsthetic must be administered, preferably general or spinal, in order to obtain muscular relaxation, and more deliberate manipulation applied in order to ensure satisfactory reduction, which is shown by the fact that full extension is obtainable. Cooling lotions and a firm bandage are then applied in order to discourage further effusion, and a back splint is applied to prevent flexion of the joint. Massage of the quadriceps is important, as these muscles waste rapidly. After three weeks it is hoped that the torn cartilage has united, but in such cases it is more likely that the torn portion has become fixed in such a position that subsequent movements will not again bring it between the articular surfaces. Gradual flexion is then permitted, and subsequent events awaited. In the majority of cases recurrence follows, in which case operation should be advised, as a repetition of conservative measures is unlikely to be successful, and repeated locking will lead to osteoarthritic changes.

A few days are usually allowed in order that effusion may be absorbed, and the skin is then carefully prepared prior to operation. A tourniquet (preferably an Esmarch's rubber bandage) is applied, and an incision is made on the inner side of the joint. The torn cartilage is steadied by a blunt hook, the transverse ligament is divided anteriorly, and an incision through the coronary ligament separates the cartilage from the tibial tuberosity. The cartilage is then grasped by tissue forceps and divided as far back as possible, but no traction is permissible, otherwise the posterior portion may be loosened and give rise to subsequent trouble. Usually about two-thirds of the cartilage is removed. The synovial membrane, capsule, and skin are sutured with interrupted stitches, and a firm bandage applied before the tourniquet is removed, so as to limit bleeding into the joint. The limb is steadied between sand-bags, and massage of the quadriceps is commenced on the third day. The inner side of the boot is raised one-third of an inch, so that when the patient commences to walk strain on the inner side of the capsule is relieved.

Investigation of a series of cases by one of us indicated that operation in 84 per cent. of cases gave perfect results, provided that the patient was under 35 years of age and had not suffered from more than three attacks.

A *cyst* of a semilunar cartilage occasionally occurs, and is alleged to be due to myxomatous degeneration following trauma. The external cartilage is affected more commonly than the internal,

and a tense swelling appears over the interarticular groove. The cyst appears suddenly, due to some movement forcing it out from between the bones, and then steadily increases in size (fig. 687). The portion of cartilage from which the cyst originates should be removed.

FIG. 687.—A cyst of the internal semilunar cartilage.

Bone.—Small portions of bone are sometimes separated by injury, or avulsion of a tibial spine may be associated with a torn anterior crucial ligament. The features and treatment have already been indicated.

Loose Bodies.—These are considered in Chapter XXXVI.

CHAPTER XXXVI

DISEASES OF JOINTS

Synovitis

Inflammation of the synovial membrane occurring other than as part of a generalised arthritis is commonly due to injury. Traumatic synovitis may follow such accidents as aseptic penetrating wounds, direct blows, sprains, or nipping of a loose body or cartilage. An effusion follows, either serous or blood-stained, according to the severity of the lesion. The joint assumes a position of ease, i.e. its greatest capacity, and palpation or movements are painful.

Treatment consists, in the early stages, in rest, combined with cold lotions and firm bandaging, in order to minimise further effusion. If effusion is excessive, aspiration is sometimes advisable, as symptoms are thereby relieved, and the time necessary for absorption is shortened. When the early symptoms have abated, massage and graduated movements are employed in order to prevent adhesions and to maintain muscular tone, but these measures must not be too vigorous otherwise a recrudescence is liable to follow.

As movements are increased, the joint should be supported by strapping or a soft bandage, and a stimulating liniment hastens final recovery.

Acute Infective Arthritis

Acute infection of a joint occurs as a result of :

(i) Direct infection, as by a penetrating wound.

(ii) Local extension, from some neighbouring focus, such as acute arthritis of the hip joint from osteomyelitis of the femoral neck.

(iii) Blood-borne infection, the commonest organisms being streptococcus, staphylococcus, pneumococcus, and gonococcus.

The knee joint, owing to its large size and exposed position,

is the commonest joint to be involved by penetrating wounds, while blood-borne infections, due to pyæmic conditions, not infrequently attack small joints, particularly the sterno-clavicular or temporo-maxillary.

Clinical Features.—*General*, as of any infection, depending on the size of the joint and virulence of the infection.

Local.—Pain, especially on attempted movement. The joint is held in position of greatest capacity, and swelling is usually evident. Palpation reveals increased cutaneous heat and tenderness. Movements are limited by muscular spasm, and attempts at either active or passive movement cause severe pain.

Joint.	Position of ease.	Site of maximum swelling.	Position for ankylosis.
Shoulder	Adducted . .	Under the deltoid, along the tendon of the biceps, and in the axilla	40° to 50° of abduction, and just anterior to the coronal plane.
Elbow	Flexed at a right angle and pronated	On either side of triceps tendon	130° of extension semi-pronated. If both sides, the second elbow at 75° of extension. These positions may be modified according to occupation.
Wrist	Slight flexion	Under extensor and flexor tendons	Dorsi-flexed to allow a firm grasp.
Hip	Flexed, abducted, and everted	Upper part of Scarpa's triangle	20° to 30° of flexion to allow sitting, and sufficient abduction to compensate for the resultant shortening.
Knee	Flexed	Subcrureal pouch, and either side of patellar tendon	5° to 10° of flexion to allow foot to clear ground in walking.
Ankle	Slightly extended and inverted	Anteriorly and on either side of the Achilles tendon	At right angles, with slight inversion to discourage flat-foot.

It will be seen that in most cases the position of ease differs widely from the position which is most useful should ankylosis occur. As any case of arthritis may be followed by ankylosis, the first duty of the surgeon is to anticipate this possibility by immobilising the joint in the position indicated in the preceding table.

Treatment.—The limb is supported and fixed by a suitable splint or appliance in the correct position, an anæsthetic being administered if necessary. If infection is already established weight-extension is advisable, as by this means muscular spasm is relieved and interarticular pressure prevented. The following lines of treatment are then to be considered.

(i) *Aspiration*, which is useful for both diagnostic and therapeutic reasons. Thus the nature of the fluid can be ascertained, and smears of cultures assist in identifying the causative organism. Aspiration reduces the tension within the joint, thereby relieving pain, and obviating the stretching of ligaments and capsule.

(ii) *Aspiration and Irrigation.*—After fluid has been aspirated some mild antiseptic may be injected into the joint and reaspirated, this procedure being repeated until the fluid returned is almost unaltered. Such mild antiseptics as flavine, mercurochrome or eusol are suitable; stronger fluids irritate the joint and cause further damage to the endothelial lining. In early cases, or when the infection is of low virulence, aspiration and irrigation, repeated if necessary, cause the inflammation to subside.

(iii) *Arthrotomy and Closure.*—If aspiration withdraws fluid which is semi-purulent, or if the general and local conditions suggest a virulent infection, then the joint is opened and washed out thoroughly with a suitable antiseptic (fig. 688). Flavine is especially useful in gonococcal joints. The synovial membrane is closed with plain interrupted catgut stitches, and the capsule, muscles, and skin are sutured either completely, partially, or not at all, according to whether the arthritis is expected to subside or progress.

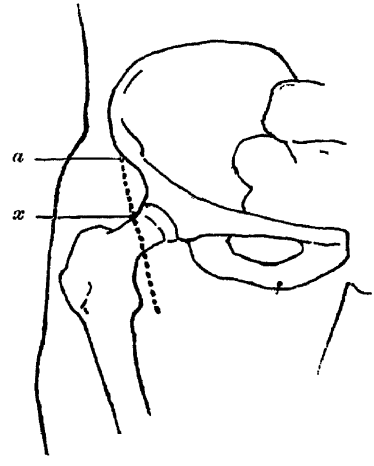

FIG. 688.

a = incision for arthrotomy in suppurative arthritis.
x = site for puncture.

(iv) *Arthrotomy and Drainage.*—In more advanced cases, or when the above measures have failed, the joint is opened, washed out, and drainage tubes inserted down to the synovial membrane. On no account should tubes project into the articular cavity. If advisable, two or more openings are made, and drainage can be supplemented by continuous irrigation, as by Carrel-Dakin's method.

Extra-articular abscesses also require to be opened and drained. In the case of the knee joint, pus is particularly liable to track upwards beneath the quadriceps, where its presence may be overlooked.

(v) *Excision.*—If in spite of drainage the condition of the patient deteriorates, or if suppuration is prolonged, then excision of the joint must be considered, although infection of bone and delay in healing are to be expected. However, provided that the condition of the patient does not demand amputation, excision should be tried in the case of the wrist, elbow, or shoulder, as an artificial arm is a poor substitute. Excision of the ankle or knee is rarely performed, as amputation and provision of an artificial leg are likely to be followed by rapid convalescence and a satisfactory functional result, and cut short any further lowering of vitality or risk from absorption. In the case of the hip joint, excision is sometimes performed in an attempt to avoid such a mutilating procedure as amputation through that joint, but the functional result, even after a successful excision, is usually poor. In all cases the patient's life must not be jeopardised in an endeavour to spare a limb, particularly as the affected joint will eventually be more or less disorganised.

(vi) *Amputation* is indicated if at any stage the patient's life is threatened, or prolonged suppuration leads to amyloid disease (which is particularly liable to occur in connection with arthritis of the hip joint). Also, in some cases a painful and disorganised joint causes such disability that an artificial limb is preferable.

Penetrating Wounds of Joints

Owing to its size and exposed position the knee joint is most commonly affected by penetrating wounds. For the

purposes of treatment wounds are classified according to the risk of subsequent infection.

(i) *Infection is unlikely*, e.g. recent puncture by a small and comparatively clean article, as by a needle. In these cases the needle is removed and the puncture wound sterilised with iodine. The limb is placed in the most useful position, should ankylosis subsequently occur (a back splint suffices), and developments are awaited. Usually a mild, transitory effusion occurs, which subsides in two or three days. Should general and local symptoms or signs suggest that infection is occurring, then the joint is aspirated, and treatment continued along the lines already indicated for acute arthritis.

(ii) *Infection is probable*, such as penetration by a rusty nail, particularly if delay has already permitted infection. In these cases emergency operation must be performed, and the wound excised layer by layer until the joint is opened. Irrigation is advisable if obvious contamination has occurred, as by fragments of rust. The wound is partially or completely closed according to the risk of infection, and the limb is fixed in the most suitable position should ankylosis follow.

(iii) *Infection is certain*, e.g. extensive laceration of the capsule, or less extensive wounds which have been neglected. In these cases an anæsthetic is given, the edges of the wound are excised, and seriously devitalised tissue removed. The wound is rendered as surgically clean as possible, and infection is anticipated by the provision of adequate drainage. The wound is covered by gauze moistened in suitable antiseptic, and the limb immobilised in the correct position.

Gonococcal Arthritis

Owing to more efficient treatment of gonococcal urethritis and conjunctivitis, articular complications are much less common than formerly.

Joint lesions occur at any stage after infection, but are most common when the initial infection is subsiding, or during an exacerbation, e.g. after urethral manipulations.

The following types of gonococcal arthritis occur:

(i) "**Rheumatism.**"—Is characterised by attacks of pain in one or more joints. The duration is variable, and pain frequently attacks different joints in succession. On examination of the joints no physical signs are detectable, and the condition gradually abates.

(ii) **Acute Arthritis.**—Usually a single large joint is affected, especially the ankle, elbow, or wrist, the last particularly in females. All the symptoms and signs of acute infective arthritis are present, and destruction is sometimes sufficiently extensive to cause bony ankylosis. On aspiration the fluid may be found to contain other organisms in addition to gonococci; in less acute or later cases it is sometimes sterile. Treatment is conducted as already indicated, and frequently arthrotomy and lavage of the joint in the early stages are followed by resolution.

(iii) **Subacute Polyarticular Arthritis.**—Is a link between the acute and the chronic plastic types. Several joints are affected, and moderate effusion, associated with periarticular œdema, are the main features. Some degree of ankylosis, either false or fibrous, is likely to result.

(iv) **Chronic Plastic Arthritis.**—Is a polyarticular infection, in which there is but slight effusion in the joints. Considerable œdema of the synovial membrane and periarticular structures occurs. Troublesome adhesions and stiffness are to be expected.

(v) **Periarticular Arthritis.**—Chiefly affects tendon sheaths and ligaments, and occasionally occurs in the hands or feet. In the latter situation stretching of ligaments leads to flat-foot unless preventive measures are adopted.

(vi) **Pyæmia.**—The small joints are most likely to be affected, e.g. the temporo-maxillary or sterno-clavicular. In common with other types of pyæmic abscesses, the condition is relatively painless, and swelling is sometimes the first indication of the condition.

Treatment.—Limitation of movement arising from fibrosis of extra-articular structures, or fibrous and sometimes even bony ankylosis, are characteristic features of gonococcal affections. Therefore, as soon as the acute phase of inflammation has abated, judicious massage and movements must be instituted. Diathermy is a useful adjunct to local treatment, as gonococci are susceptible to a degree of heat which is readily tolerated by the tissues.

Vaccine therapy sometimes yields surprisingly good results. Needless to say, the primary focus of infection should receive appropriate treatment.

Syphilitic Diseases of Joints

Inherited.—(*a*) *Painless Effusion.*—This has been aptly described as "symmetrical, serous, syphilitic synovitis," and is associated with the name of Clutton. It is character-

ised by a painless effusion into a large joint, most commonly the knee. This condition is frequently bilateral, although the swelling of the two joints may not actually synchronise. The effusion causes a sensation of weakness and insecurity, and on examination the joint is seen to be distended, and palpation reveals the painless effusion. Movements are only limited if the amount of fluid mechanically prevents the full range.

The condition occurs between the ages of 10 and 18, and other stigmata of inherited syphilis are usually present. This condition is one of the four characteristic signs of inherited syphilis, which appear about puberty, and give rise to "the halt, the deaf, the blind, and the impotent," i.e. halt because of Clutton's joints, deaf because of otitis interna, blind because of interstitial keratitis, and impotent because of gummatous orchitis.

If no confirmatory clinical evidence of syphilis is discovered, then the family history is usually suggestive, and finally the W.R. of the patient and parents, or even of the fluid aspirated from the joint, should be tested.

Acquired.—During the *secondary* stage a transient or variable effusion sometimes occurs in any of the larger joints. The condition is painless, and sometimes, like most secondary lesions, symmetrical.

Lesions of the *tertiary* stage are classified as follows :

(*a*) *Local Synovial Gumma.*—This uncommon condition commences in the synovial membrane of a large joint, e.g. on the inner side of the knee. At first firm and nodular, like all gummata it tends to infiltrate superficial tissues, and if neglected it eventually softens and discharges through the skin, giving rise to a gummatous ulcer which communicates with the joint cavity.

(*b*) *Gummatous Synovitis.*—In some respects this simulates tuberculous disease, but the synovial thickening is more irregular. Moreover, the condition is painless, therefore muscular spasm and wasting are not pronounced.

(*c*) *Chondroarthritis.*—Chiefly affects the bone and cartilage, which are eroded. It is distinguished from osteo-

arthritis in that pain is slight, and erosion does not necessarily occur at sites of intra-articular pressure. Moreover, lipping is absent, and the synovial membrane is sometimes palpably thickened.

Treatment of tertiary manifestations involves anti-syphilitic remedies combined with counter-irritation. Improvement follows rapidly, and is often complete if no destruction of bone or cartilage has occurred. The main importance of syphilitic joints is that the true nature of the condition is sometimes overlooked, and therefore any "tuberculous" or "osteoarthritic" joint which presents abnormal features should be considered in the light of being possibly syphilitic.

Neuropathic Joints

The most important pathological conditions of joints secondary to affections of the nervous system occur in connection with:

(I) Parasyphilis.
(II) Syringomyelia.
(III) Hysteria.
(IV) Other Lesions of the Nervous System.

I. Parasyphilis

Owing to the more energetic and efficient treatment of syphilis Charcot's joints occur with diminishing frequency. The "hypertrophic" type usually occurs in hinge joints, e.g. the knee, while the "atrophic" variety occurs more frequently in ball-and-socket joints. In either case, an effusion, which varies in amount from time to time, is present, and complete absence of pain is a striking feature. Examination of a typical case following the routine which should be adopted for all joints, comprises:

(i) *Inspection.*—The joint is distended, and if the effusion is generous, it assumes the position of greatest capacity. In advanced cases the joint is obviously disorganised.

(ii) *Palpation.*—The presence of fluid is confirmed, and in hypertrophic cases irregular masses of bone are readily palpable. Bursæ which communicate with the joint, such as the psoas bursa, are sometimes distended, and herniation

of synovial membrane is liable to occur through weak parts of the distended capsule, e.g. into the popliteal fossa.

(iii) *Movements.*—A curious soft crepitus is usually noticed resembling the "crunching" under the foot when walking over snow. Movements vary with the amount of restriction imposed by new bone formation, but in the absence of interlocking they are usually surprisingly free and painless.

FIG. 689.—Disorganisation of a knee joint, following Charcot's disease.

(iv) *Measurement.*—Shortening of the limb sometimes occurs owing to absorption of bone, and some degree of muscular wasting may result from disuse.

(v) *Radiograph.*—Irregular masses of bone are seen in the hypertrophic variety (fig. 689). The atrophic type will show irregular and eventually almost complete absorption of the articular ends of the affected bones.

(vi) *General Examination.*—It is rare for a Charcot's joint to appear as the first evidence of tabes. Lightning pains, ataxic or other symptoms are usually present, while examination commonly reveals Argyll-Robertson pupils and loss of tendon reflexes, particularly the knee and ankle jerks.

Treatment consists in supporting the joint by a suitable appliance, e.g. a Howard Marsh knee splint, or a walking calliper. Excision of the knee joint has been practised, but is only justifiable if ataxia has not developed, otherwise the slight benefit secured by stabilisation of an ataxic joint is

more than offset by the risk of infection or non-union of the atrophic tissues.

II. Syringomyelia

Is due to gliomatous degeneration round the central canal of the spinal cord, and usually occurs in the lower cervical region. Joint complications occur in about 30 per cent. of cases of syringomyelia, and closely resemble the Charcot's joints described above, except that in this condition the arm is affected much more commonly than the leg (fig. 690). The shoulder is most frequently attacked, and being a ball-and-socket joint, the atrophic type of the disease is the more usual.

Fig. 690.—The bones of a Charcot's wrist joint, from a case of syringomyelia. (R.C.S. 4572.2.)

Further examination of the patient reveals other evidence of syringomyelia, such as :

(*a*) *Dissociation of Sensation in the Hands.*—The sensibility to pain and variations of temperature are lost, but tactile sensation and muscular sense remain. Owing to the loss of sensation, small injuries, notably cigarette burns, occur unnoticed.

(*b*) *Trophic Changes.*—Wasting occurs of all the muscles of the hand, and later the forearms. Also the tissues are more prone to injury, and healing is delayed. Eventually the soft tissues and finally the phalanges become absorbed.

(*c*) *Scoliosis,* due to asymmetrical irritation of the pyramidal tracts, so that the erector spinæ on one side is more spastic than its fellow, and acts on the spinal column in the manner of a bow-string.

(*d*) *Unequal pupils,* due to unequal irritation of the oculo-pupillary fibres, which pass down the cervical cord, and leave it in company with the first dorsal nerve, passing thence via the rami communicantes to the inferior cervical sympathetic ganglion, and along the carotid sheath and ophthalmic artery to the ciliary ganglion.

(*e*) *Spasticity of the legs,* due to irritation of the pyramidal tracts.

Treatment of the joint condition consists of support, pressure being

carefully guarded against, as owing to insensitiveness to pain pressure sores are particularly liable to occur.

III. Hysteria

Disability in connection with a joint sometimes occurs in patients of hysterical tendencies, and is most commonly seen in adolescent or young adult females. The history in some cases is suggestive, in that the onset follows some emotional crisis, or mimicry of some joint condition seen in another patient. The larger joints are usually affected, the commonest being the hip or knee.

The more important clinical features are as follows :

(*a*) *Inspection.*—The limb is often in a position which is unusual for any early pathological condition, e.g. in the case of the hip joint the thigh may be markedly flexed, adducted, and inverted. Wasting of muscles, if any, is slight, and is due to disuse.

(*b*) *Palpation.*—Gentle palpation may appear to cause intolerable pain, but if the attention is distracted, considerable pressure will pass unnoticed. Otherwise no abnormal features are discovered.

(*c*) *Movements.*—All movements are restricted, and if the patient is requested to move a joint, both the group of muscles which carry out the movement, and the antagonistic muscles, are contracted, so that the limb is rigidly fixed. This phenomenon can easily be appreciated by palpation of the muscles, while the patient attempts to carry out the desired movement.

(*d*) *Measurement.*—If the condition has persisted for a sufficient length of time, wasting will be detected owing to disuse atrophy.

(*e*) *Radiograph.*—In long-standing cases disuse atrophy of bone occurs, as is shown by thinning of the compact layer, and loss of density of the cancellous tissue owing to absorption of calcium salts.

(*f*) *General Examination.*—Other hysterical manifestations will probably be found, such as globus hystericus, glove or stocking anæsthesia, etc.

Treatment.—Psycho-analysis should be employed in order to correct the warped mental outlook. Symptomatic treatment directed to the joint includes encouragement regarding movements, or an anæsthetic can be given, and the position of the joint altered. In the case of the lower limb spinal anæsthesia is particularly useful, as the patient herself can then observe the range of movements through which the joint can be put.

IV. Other Lesions of the Nervous System

Long-standing impairment of the trophic innervation of a limb is followed by changes in the small joints of the hands and feet. Such causes include cerebral injury, spina bifida, and peripheral nerve lesions, e.g. injury, neuritis, or leprosy. The articular surfaces of the bones are absorbed, and ligamentous structures become contracted. Treatment consists in prevention of deformity and stimulation of the affected joints.

Tuberculous Disease

Tuberculous arthritis originates either in the synovial membrane or in the bone. The factors which influence the site of origin are the age of the patient, and the individual joint which is affected. In children the osseous type is commoner than the synovial, as the epiphysis is frequently affected, whereas the reverse is true for adults. In the knee and elbow, the disease usually first attacks the synovial membrane, whereas in other joints, notably the hip and wrist, the initial focus of infection is generally in the adjacent bone.

Four types of tuberculous arthritis are recognised :

(i) *Synovial.*—Characterised by œdema and infiltration of the synovial membrane and periarticular tissues, giving rise to the typical "white swelling." The synovial membrane becomes thickened and succulent, and subserous tubercles appear. Gradually the structure is lost, and the membrane becomes converted into granulation tissue. These granulations creep across the articular cartilage, which is eroded and destroyed, thus exposing the underlying bone to invasion.

(ii) *Osseous.*—The infection commences in the bone adjacent to the joint, or in the case of a child in the epiphysis, and extends into the joint by the continuous invasion of the intervening tissue. This type is more insidious than the synovial type, and symptoms are usually present before clinical signs are obvious.

(iii) *Caries sicca.*—Is seen most commonly in the shoulder joint. Gradual destruction of the bones occurs with very little synovial œdema.

(iv) *Hydrops.*—Excess of fluid is a rare occurrence in tuberculous arthritis, but occasionally the knee joint becomes distended with fluid containing fibrin, which is later converted into flat, oval bodies, so-called melon-seed bodies.

Clinical Features.—*Symptoms.*—Tuberculous arthritis presents an insidious onset, aching after use and stiffness following rest being early symptoms. Pain is not severe, but sudden strains and twists are deliberately or sub-

consciously avoided. When erosion of cartilage has occurred, "starting pains" are characteristic, and occur just when the patient is dropping off to sleep. They are due to relaxation of the muscles which guard the joint, so that slight movement between the articular surfaces causes friction between the exposed and sensitive bones. Swelling of the joint is sometimes noticed by the patient, and in most cases is due to œdema of the synovial membrane and periarticular structures.

Some deterioration of the general health is to be expected, and the temperament of a small child may completely alter, so that happiness and contentment give way to peevishness and fretfulness.

Signs.—Following the routine which always should be adopted for the examination of joints, we find:

(*a*) *Inspection.*—The limbs are exposed, and the position of the affected one is observed. The opposite limb is then placed in a corresponding position. Deformity in the early stages is due to the position of ease which the joint automatically assumes; later deformity results from disorganisation. Swelling of and around the joint is due to œdema; only in the rare cases of hydrops is it caused by distension of the joint by free fluid. The swelling therefore, in most cases, fades away above and below the joint, and is characteristically spindle-shaped. The whiteness of the overlying skin is due to pressure of the œdema emptying the cutaneous capillaries, which are not in a condition of reflex hyperæmia, such as occurs in acute infection.

Muscular wasting is a constant feature, and is due to both disuse atrophy and trophic disturbances.

In the later stages abscesses and sinus formation sometimes occur in addition to the above visible signs.

(*b*) *Palpation.*—Sensitive hands may detect a slight rise of cutaneous temperature over the affected joint. A somewhat boggy or doughy thickening of the synovial membrane will be detected if this structure is sufficiently superficial. Owing to muscular atrophy, and flabbiness of the remaining muscle resulting from loss of tone, the articular ends of bones are much more easily palpable than those of the opposite

limb, and this leads the unwary into the erroneous belief that the bone ends are enlarged, instead of merely being thrown into relief.

(*c*) *Movements.*—The patient is requested to move the joint as far as possible in all directions, and it will be noted that active movements are limited.

The surgeon then puts the sound limb through its full range of movements, in order to gain the confidence of the patient, and also to ascertain the degree of mobility present in that individual patient. The movements of the affected limb are then tested, if possible while the patient's attention is diverted. In cases of tuberculous arthritis, all movements are found to be limited, owing to protective spasm of muscles. In late cases complete ankylosis may occur.

(*d*) *Measurement.*—The presence of muscular wasting is confirmed, and the amount of shortening, due to lack of growth or disorganisation of the joint, is estimated.

(*e*) *Radiograph.*—If the bone is actively affected, rarefaction is present, as shown by loss of pattern due to destruction of the bony trabeculæ, and also by diminution in density, owing to absorption of calcium salts (fig. 691).

Should the disease be limited to the synovial membrane, then the bone undergoes some degree of atrophy, in common with the soft tissues. The X-ray then shows thinning of the compact bone and loss of density of the cancellous bone, the pattern of which remains unaltered, as trabeculæ are not destroyed. Invariably, it is necessary to compare the radiograph with one of the normal side in order to appreciate early atrophy of bone.

(*f*) *General Examination.*—Other evidence of tuberculous trouble, either active, latent, or healed, may be discovered.

Prognosis.—Prolonged treatment is necessary if adequate restoration of function is to be obtained ; thus, in the case of a large joint treated conservatively, three years is a reasonable period, provided no complications ensue.

The prognosis depends upon the following factors :

(1) *Age of Patient.*—Patients at the two extremes of life have less resistance to tuberculous disease than those of adolescence or middle adult life.

(ii) *Family History.*—Lack of resistance appears to be a hereditary characteristic, and when the disease occurs in a member of a tuberculous family, the prognosis is less bright.

(iii) *Social Status.*—Under the best possible surroundings the chances of recovery are greatly improved. Results obtained at



FIG. 691.—Tuberculous disease of the left big toe joint (with the corresponding joint for comparison).

some of the Swiss resorts, such as Leysin, amid invigorating and sunny surroundings, are encouraging.

(iv) *The Stage of the Disease.*—As would be expected, cases which are diagnosed in the early stages and which receive appropriate treatment are more likely to make a good recovery than those which have been neglected.

(v) *The Presence of other Tuberculous Foci.*—If the patient is otherwise healthy the chances of a good result are materially increased.

Results.—(i) *Resolution.*—This fortunate result occurs occasionally in early and otherwise favourable cases which are subjected to treatment under ideal conditions.

(ii) *Fibrous ankylosis* is a common result The presence of adhesions in the joint may still allow some degree of movement, so that the function is not necessarily much impaired. If dense adhesions form, then movement is probably entirely absent, but is distinguished from bony ankylosis by

the fact that vigorous attempts to move the joint cause pain if ankylosis is of the fibrous variety.

(iii) *Bony ankylosis* nearly always occurs as a result of secondary infection, which gains entry to the joint along sinuses formed by abscesses bursting through the skin.

(iv) *General Dissemination.*—Acute miliary tuberculosis occasionally occurs as a result of blood-borne infection, particularly if the general resistance of the patient is undermined by some debilitating condition. This complication has also followed manipulation of tuberculous joints by bone-setters and unskilled persons.

(v) *Toxæmia.*—If sinuses occur and prolonged suppuration follows, subacute or chronic toxæmia is likely, and if of sufficiently long duration, amyloid disease may develop. Amyloid disease is prone to occur in hip disease, for such a mutilating procedure as amputation through that joint is naturally dreaded and postponed by the patient.

Treatment.—*General treatment* is instituted without delay, and maintained until the condition is pronounced to be cured. Fresh air, natural or artificial sunlight, suitable food, and cheerful surroundings are all of great importance. Vaccines are worthy of trial if recovery is retarded.

Local treatment is considered under the following headings: conservative, operative, and the treatment of complications.

(*a*) *Conservative.*—The principle of conservative treatment is to immobilise the limb in the most useful position should ankylosis occur, until six months after the last sign or symptom has disappeared. The actual length of time for which treatment should be continued, after the disease is apparently cured, depends on the general condition of the patient, local response to treatment, and the actual joint affected. The hip joint in particular requires prolonged fixation, and one year's further treatment is usually considered necessary after the disease is apparently cured.

If the limb is in an unsuitable position when first seen, e.g. considerable flexion of the knee joint, then the deformity

is usually overcome by weight extension. This is arranged so that traction is exerted in the line of the bone below the affected joint. Cases with slight deformity often respond to a period of rest in bed, which results in disappearance of some of the muscular spasm, and permits the joint to be placed in the correct position. Should weight extension be necessary, e.g. in the case of the knee joint, strapping is applied along either side of the leg as far as the tuberosities of the tibia. These two lateral strips are attached to a wooden stirrup below the foot, from which a cord passes over a pulley. Sufficient weight is then applied to overcome muscular spasm; 1 lb. for each stone of the patient's weight is usually adequate. Interosseous pressure and starting pains are thereby relieved. After a few days the muscles relax, and the pull of the weight then stretches ligaments and causes a renewed aching, in which case the weight is reduced. As spasm is overcome, so the leg is gradually straightened until the desired position is reached.

Immobilisation is then obtained by means of some suitable appliance or apparatus. Plaster of Paris is commonly used, and although it is cumbersome and cannot be removed frequently for inspection or to permit the limb to enjoy heliotherapy, yet it is efficient, and interference by the patient is prevented. If local inspection is desirable, a window may be cut in the plaster casing. When the condition appears to be responding to treatment, a lighter and removable splint is substituted for the plaster of Paris. Such materials as poroplastic, gutta-percha, or celluloid are used for this purpose, or a light split plaster is sometimes found to be adequate and convenient. In the case of the lower limb a walking calliper forms a very suitable appliance for convalescent cases.

The last signs or symptoms to disappear include local or referred pain, abscess formation, or spasm of muscles. After a further variable period (*vide supra*) the patient is allowed to regain the use of his limb gradually.

(*b*) *Operative.*—Operative interference is required under the following circumstances:

(i) *Failure of conservative treatment*, either from continued local extension of the disease, or owing to gradual deterioration of the patient's health.—In the former case abscesses enlarge and extend in spite of aspiration, or repeated radiographic examinations sometimes reveal increasing disorganisation of the joint or destruction of the adjacent bones. In more advanced cases sinuses extend or persist, and show no tendency to heal.

The general condition of the patient may be undermined by an active tuberculous focus. In other cases a second focus of infection appears, or if already present, it sometimes becomes more active. Excision of the shoulder joint in a case of caries sicca is sometimes desirable if pulmonary tuberculosis is also present, as removal of one focus will assist the general resistance of the patient to overcome the second lesion. In more advanced cases chronic toxæmia or the advent of amyloid disease is the deciding factor in favour of operation.

(ii) *To shorten the time necessary for treatment.*—In some instances experience teaches that the result obtainable by operation is equally good or even better than that resulting from conservative measures, e.g. tuberculous arthritis of the wrist or knee in patients past the meridian of life, treated on conservative lines will end in fibrous ankylosis. Prolonged treatment will be necessary, and many patients will fail to respond, in which case radical measures will be imperative at a later date. Therefore, as an equally good result is obtainable by surgical measures, operation is recommended at the outset in order to shorten the time required for treatment, and to rid the patient of an active tuberculous focus which may otherwise impair health or even endanger life.

In other cases it becomes increasingly obvious during conservative treatment that, although the disease is being overcome gradually, yet destruction of the joint is inevitable. For example, in the case of the knee joint, fixity of the patella to the intercondylar notch suggests that, *a fortiori*, the condyles are becoming fixed to the tibial

plateau. Excision of the knee is then indicated, as bony ankylosis is obtainable in a comparatively short time, and is preferable to a dense and possibly painful fibrous ankylosis.

(iii) *To improve position.*—A tuberculous joint which has been allowed to ankylose in a faulty position is usually an indication that the elementary principles of conservative treatment have been ignored. However, in the case of a neglected child, deformity sometimes occurs, or the life of the patient has possibly been threatened by some intercurrent condition so that treatment of the joint was necessarily suspended.

The most useful positions for ankylosis have been indicated already (*vide* p. 857), and operation is sometimes desirable to improve the position and consequent function of the limb.

(iv) *To regain mobility.*—Ankylosis in a good position results in adequate function as far as the majority of joints are concerned. However, in certain situations, notably the elbow and temporo-maxillary joints, excision with a view to regaining mobility is desirable. In the rare event of bilateral ankylosis of the hip joints, a successful arthroplasty of the joint will facilitate such activities as ascending or descending stairs.

Operations.—(i) *Arthrotomy.*—In cases of doubtful diagnosis it is sometimes justifiable to open a joint for inspection, and to allow removal of a portion of synovial membrane for microscopical examination. If any disintegrated tissue is present this is removed, and the joint is irrigated with some suitable mild antiseptic.

(ii) *Arthrectomy.*—Consists in opening the joint freely, and dissecting away as much diseased synovial membrane as possible. Eroded or loose cartilage is removed, and any local areas of diseased bone are gouged away. If a slice of articular cartilage is removed, the procedure is then termed erasion, and is preferable to excision in the case of children, as the epiphyseal cartilage is not encroached upon thereby.

(iii) *Excision.*—Is the most common operation to be performed. It consists of free removal of all intra-articular soft tissues, together with the articular ends of the bones, and diseased foci in the shaft. Classical excisions are rarely performed in practice, and in the case of children, epiphyseal cartilage should be spared if possible. In certain joints, e.g. the knee, the end result should be firm bony ankylosis, while in other joints, notably the elbow, some degree of movement is desirable.

(iv) *Amputation.*—In cases where conservative measures have failed, either for local or general reasons, amputation will be necessary in order to remove a useless encumbrance, or to cut short the debilitating effects of prolonged toxæmia.

Special Joints

Sacro-iliac.—This joint is not commonly affected, and owing to vagueness of the early symptoms and late appearances of definite signs, the correct diagnosis is often delayed. A local ache, pain referred along the great sciatic nerve, which lies in front of the joint, and a sensation of weakness of the pelvic ring are among the first symptoms. After a few weeks a boggy swelling appears over the back of the joint, which gradually enlarges to form an abscess. Rectal or vaginal examination may reveal a similar condition in the pelvis. When the disease is established, pressure on the iliac crests causes articular pain. A radiograph confirms the diagnosis.

Treatment necessitates operation as soon as the condition is recognised, as obliteration of the joint causes no disability, and removal of diseased tissue and fixation of the joint favours a cure in the shortest possible time. Also, failure of the conservative treatment will result in secondary infection and persistent sinuses. Access is gained by removal of the posterior superior spine and adjacent iliac crest. Tuberculous granulation tissue and diseased bone are removed with a sharp spoon and gouge, and a bone graft or peg is driven through the bones so as to immobilise the joint.

Hip.—The disease usually commences in the bones, either in the under surface of neck of the femur or in the acetabulum. It is uncommon after the age of 20.

Early symptoms include a limp, and pain commonly referred to the knee joint. This referred pain is stated to pass via the geniculate branch of the obturator nerve, but the anterior crural and great sciatic nerves also send articular branches to both joints.

During the first stage of this condition the joint is held in the position of ease, i.e. flexed, abducted, and everted. The abduction causes the pelvis to tilt downwards, and gives rise to apparent lengthening of the limb. As the joint becomes more painful, a larger proportion of time is spent in the recumbent position, during which the patient lies on the sound and painless hip. Thus the affected joint gradually becomes adducted and inverted, and flexion becomes more marked. Owing to adduction, the limb is apparently shortened. The third stage corresponds with articular disorganisation, with absorption of the femoral head and acetabular cavity. The position of adduction and inversion encourages the head of the femur to slip out of the eroded acetabulum, and consequently the femoral head is displaced upwards on to the dorsum ilii. Further absorption of bone, combined with continuous pull of spastic muscles, results in a "travelling acetabulum." In a small percentage of cases complete erosion of the acetabulum is associated with the formation of a tuberculous abscess in the pelvic cavity. During the third stage a tuberculous hip is in a position of flexion, inversion, and adduction, and disorganisation of the joint leads to true shortening of the limb, in addition to the apparent shortening due to adduction.

In considering the differential diagnosis, such conditions as spasm of the psoas (which causes flexion of the joint) and tuberculosis of the gluteal bursa (which leads to abduction and eversion) must be considered. Coxa vara, with superadded traumatic arthritis, may cause confusion, but a week in bed results in disappearance of the arthritis, after which the typical signs of unmasked coxa vara become evident.

Prior to its recognition most cases of Perthes' disease were considered to be tuberculous; the distinguishing features have already been discussed (*vide* p. 831).

Treatment is conducted along the lines already prescribed. Deformity is corrected by weight extension, the limb being supported in a Thomas's knee splint, and suspended either from an upright fixed to the end of the bed, or a Balkan beam. Care must be taken that tilting of the pelvis does not mask the true position of the leg. When the disease is apparently subsiding, the patient is fitted with a Thomas hip splint, a patten on the boot of the sound foot, and crutches, and so allowed to get about. Owing to the tendency for relapse to occur, and the serious disability which results should conservative measures fail, treatment is persisted in until twelve months after the apparent cure.

If operative measures are necessary, arthrectomy is performed through an anterior incision. Excision of the head of the bone is carried out from the posterior aspect, and as sinuses are probably present, this route allows the best possible drainage. Amputation is seldom required nowadays, but if necessary the preliminary step should be ligature of the common iliac artery by the extraperitoneal route, which effectively controls hæmorrhage.

Knee.—The knee joint is commonly affected by tuberculous disease, and diagnosis is as a rule not difficult. In neglected cases the position of triple deformity will occur, which consists of flexion, external rotation, and backward subluxation of the tibia, the latter occurring when the crucial ligaments have become softened and destroyed. Excision of the knee joint yields good results, provided bony ankylosis is obtained. Flexion of the joint is unnecessary, as the limb is already shortened by removal of bone.

Ankle.—Tuberculous disease of this joint usually commences in the synovial membrane. Puffiness first appears under the extensor tendons, and later at the sides of the Achilles tendon.

If conservative treatment fails, such measures as arthrectomy, astragalectomy, or excision are usually disappointing owing to the complicated nature of the joint, and the comparatively poor blood-supply of the foot. Amputation will probably be required, and should be performed at the modern site of election, i.e. about 7 inches below the upper end of the tibia.

Shoulder.—Tuberculous disease of this joint usually occurs in the form of caries sicca. The ends of the bones are destroyed, but very little œdema or thickening of the soft structures is evident. On examination, wasting of the deltoid muscle is obvious (fig. 679), and the arm is held against the chest wall. Movements are all limited, and pain is produced when they are attempted. Treatment consists in fixation of the joint in abduction, and a few weeks in bed with lateral traction on the arm is usually required in order to obtain the desired position. Care must be taken to observe that true abduction is obtained, and not apparent abduction due to rotation of the scapula.

If response to conservative measures is unsatisfactory, no hesitation need be felt in performing excision of the joint, as the results are very satisfactory.

Elbow.—In this joint the disease usually commences in the synovial membrane. The arm becomes weak and aches after use, and a doughy swelling appears on either side of the triceps tendon. Fixation is obtained by a plaster of Paris casing, or, if frequent inspection is desirable, a poroplastic splint can be applied. Abscesses usually appear posteriorly. Arthrectomy is sometimes necessary, but excision, unless imperative, should be reserved until after the age of 16, otherwise stunting of the limb will result.

Wrist.—This joint is not uncommonly affected in elderly patients, in whom the prognosis is somewhat gloomy. Carpal bones are readily destroyed, and abscesses appear under the extensor tendons on the back of the wrist.

If response to conservative measures is disappointing, excision should be performed before extensive destruction occurs. In elderly patients, and in those cases which have

been allowed to progress to sinus formation, amputation is usually necessary.

Osteoarthritis

Various types of joint affections may be included under this heading, the predisposing factors being trauma, infection, exposure, and declining years. For practical purposes the different members of this disease may be classified as acute polyarticular, chronic polyarticular, and chronic monarticular, the latter being surgically the most important.

(i) **Acute Polyarticular.**—This variety, sometimes referred to as rheumatoid arthritis, is seen most commonly in young females, and commences in the small joints of the hands and feet. It gradually spreads to the larger joints, thus causing progressive crippling, until the patient may become almost helpless. It is apparently a toxic condition, and sometimes definitely follows such infective conditions as acute sinusitis or tonsillitis. During the earlier stages of the condition bouts of pyrexia occur periodically, associated with sweating, tachycardia, and exacerbations of pain and swelling in the affected joints. Fibrosis and contraction of ligaments gradually occur, and eventually the fingers become flexed and the hand fixed in a position of ulnar adduction. This disease is apt to run a painful course to more or less complete crippledom.

Still's disease is a similar condition occurring in children usually as they approach the second decade. In addition to joint changes, splenic and lymphatic enlargement, and a lymphocytosis are also associated.

The treatment of acute polyarticular osteoarthritis comprises an exhaustive search for any possible causative focus of infection, including the Fallopian tubes, teeth, tonsils, air sinuses, gall-bladder, and bowels. In a few fortunate cases eradication of some focus is rewarded by arrest of the disease. Locally, deformities are prevented, and massage, warmth, electrical therapy, etc., are utilised in order to delay degenerative changes.

Recent investigation suggests that polyarthritis is associated with hypercalcæmia, and that apyrexial and non-toxic cases are improved by removal of one or more parathyroids.

(ii) **Chronic Polyarticular** (*syn.* arthritis deformans) occurs chiefly in middle-aged or elderly females. Again the smaller joints are usually the first to be affected, the changes which occur being degenerative—and atrophy of the ends of the bones and fibrosis of ligaments cause disorganisation and stiffness of the joints. Localised patches of periostitis (Heberden's nodules) may appear on the phalanges. Treatment consists of the prevention of deformity and stimulation of the affected joints.

Spondylitis deformans is a similar condition, more commonly seen in men, which occurs in the spine, and is associated with osteoarthritis of the articulations, and fibrosis or ossification of ligaments (*vide* Spine).

(iii) **Chronic Monarticular.**—Trauma is the causative factor, although the recuperative powers of the affected joint may be undermined by some low-grade toxic condition. As injury is the essential predisposing cause, the disease is therefore more common in men. The injury is either of a single severe nature, e.g. following dislocation of the shoulder, or results from minor repeated traumata, such as nipping of a loose body or semilunar cartilage in the knee joint. Other factors which predispose to this condition, and which can be included as traumatic, are excessive use, frequent exposure to cold or damp, or alteration in the mechanics of a joint, malalignment following fracture of the corresponding femur.

Pathological Changes.—The process first affects the soft structures, and later spreads to the cartilage and bone. Thickening of the synovial membrane occurs, and as this progresses villiform processes develop, which on movement may be nipped between the bones, and when unduly enlarged are termed "lipomata arborescens." The matrix of the cartilage undergoes a fibrous metaplasia, and the cells multiply and become arranged at right angles to the articular surface. The superficial cells burst into the joint, sometimes in sufficient numbers to render the fluid turbid, and con-

sequently the surface of the cartilage becomes roughened. The thickened synovial membrane overlaps the edge of the articular cartilage, and under this fringe cartilage cells collect. Thus lipping or osteophytic growth occurs, as the cartilage cells subsequently ossify. Owing to the degeneration of the matrix and increase of cells, the cartilage softens, and is worn away on pressure-bearing surfaces, with resulting erosion. The underlying bone when exposed reacts to pressure, and becomes dense and smooth, this process being termed eburnation (fig. 692).

FIG. 692.—Osteoarthritis of the knee joint, showing thickened synovial fringes, lipping of the cartilaginous margins, and eburnation of bone on surfaces exposed to friction. (R.C S 4558 1.)

Not infrequently exacerbations occur with synovial effusion, so that distension of the joint follows. Bursæ communicating with the joint are apt to become distended, e.g. psoas bursa, or Baker's cysts appear. The latter are protrusions of synovial membrane through weakened portions of capsule. These are most commonly seen in the popliteal space as a complication of osteoarthritis of the knee joint. Occasionally chondrification or ossification occurs in the synovia, and in the case of the knee joint a solid mass sometimes appears due to chondrification of the synovial membrane lining the subcrureal pouch (fig. 693). Occasionally ossified synovial villi or osteophytes become detached and form loose bodies in the joint.

In the case of the shoulder joint the tendon of the long head of the biceps is liable to become frayed, and it eventually snaps as a result of some slight muscular effort (fig. 694).

Clinical Features.—The early symptoms of osteoarthritis are pain and stiffness. Pain is characteristically aggravated

FIG. 693.—Osteoarthritis of the knee, with osteophytic formation, and chondrification of the synovia lining the subcrureal pouch.

by changes in the weather, so that the appropriate term "barometric joint" is sometimes used. Stiffness is intensified by rest, and the joint must be "worked loose" before the range of movement is recovered. In advanced cases creaking, or locking of the joint by osteophytes, is noticed.

The signs depend upon the extent to which the disease has progressed. In the early stages some effusion and

irregular or villous thickening of synovial membrane are the only features. At a later stage lipping or osteophytes are sometimes palpable, while grating or creaking is detected on movement. Any communicating bursæ should be palpated, and in the case of the knee joint, the popliteal fossa must always be examined for Baker's cysts.

FIG. 694.—Osteoarthritis of the right shoulder, complicated by rupture of the long head of the biceps, and consequent "bunching" of the muscle. The patient is also suffering from a left-sided Erb's palsy.

Treatment.—In the early stages, the joint should be protected from exposure and cold, and in the case of the knee joint, a knitted woollen cap should be worn. Rest to the joint should only be permitted during painful exacerbations, and movements and massage are resumed as soon as they can be tolerated. Radiant heat baths, diathermy, and rubefacients are useful. The possibility that some chronic infection is undermining the resistance of the joint is borne in mind, and such conditions as chronic urethritis or pyorrhœa must receive due attention.

Operative treatment is sometimes necessary in order to remove interlocking osteophytes (cheilotomy), or if pain is intolerable. Excision of a stiff and painful knee will probably result in years of comfort to the patient, while in the case of the hip joint, arthroplasty is occasionally required if the characteristic, deep-seated, boring pain interferes with sleep, and renders the sufferer's life a misery.

Finally, it should be mentioned that if economically possible patients who are prone to osteoarthritis of any type should seriously consider a change of residence. Some localities undoubtedly predispose to osteoarthritis, and a change to a warmer or drier climate sometimes prevents painful and crippling deformities.

Loose Bodies in Joints

Loose bodies in joints include foreign bodies introduced from without, otherwise they arise from the various constituents of the joint, e.g. :

Synovial Fluid.—A single fibrinous body sometimes results

Fig. 695.—A loose body in the knee joint, following influenzal arthritis.

from a hæmorrhagic or inflammatory effusion (fig. 695). In tuberculous disease flattened " melon-seed " bodies may be present in large numbers.

Synovial Membrane.—Villous processes, such as those which occur in osteoarthritis, become detached, especially if bone or cartilage develop within them.

Cartilage.—In the knee joint a portion of a semilunar cartilage sometimes becomes detached, and in any joint it is possible for a localised injury to chip off a portion of articular cartilage.

Bone.—Injury may cause separation of a small portion of bone, e.g. a tibial spine. Osteophytes are occasionally detached in cases of osteoarthritis. If the loose body con-

tains living cells, growth may continue, nutriment being obtained from the synovial fluid.

The main symptom caused by a loose body is locking of the joint. This causes severe pain and is followed by synovial effusion. Repeated attacks cause stretching of the capsule and ligaments, after which locking is often only momentary, and some slight manœuvre of the joint by the patient causes the body to slip out from between the bones and so unlock the joint. Repeated attacks of locking and synovitis eventually result in degeneration of the joint and consequent osteoarthritis. Occasionally the patient learns to manipulate the joint so that the loose body becomes palpable, in which case it is felt to slip away from under the examining finger when the position of the joint is altered. A radiograph reveals the presence of the body, provided that it is sufficiently dense and not obscured by adjacent bone (fig. 695).

Treatment.—Unless the joint is already disorganised, the loose body should be removed in order to relieve symptoms, and prevent the onset of degenerative changes. In the case of the knee joint, the body should be manipulated, if possible, so that it comes to lie in the subcrureal pouch. It is then imprisoned in that situation by a firm bandage passed around the extended joint, so that a small vertical supra-patellar incision is sufficient to allow removal. Otherwise the affected joint is opened by a suitable incision, and if the loose body cannot be found, it may be dislodged by a stream of sterile saline forcibly injected by means of a Higginson's syringe.

Ankylosis

This term indicates a condition in which the normal range of movement of a joint is diminished. The cause is either outside the joint (false ankylosis) or intra-articular (true ankylosis).

False ankylosis is due to many conditions, some examples of which are :

Skin.—Scars, following burns.

Fascia.—Dupuytren's contracture.

Muscles.—Myositis fibrosa.

Tendons.—Stiffness following a Colles's fracture.

Nervous System.—Contractures due to paraplegia.

True ankylosis is either due to fibrous adhesions in the joint, or to actual bony union between the articular ends of the bones. As a rule some degree of movement can be obtained if the ankylosis is fibrous in character. However, if adhesions are so dense that no movement is possible, the two varieties are distinguished in that vigorous passive attempts at movement cause pain in the case of a fibrous ankylosis.

Fibrous ankylosis follows prolonged immobilisation, bleeding into a joint, low-grade pyogenic infection, or tuberculous disease. Bony ankylosis follows a virulent infective arthritis, or a tuberculous infection complicated by secondary infection.

Treatment.—Many cases require no treatment, as the function of the joint is adequate. The two main indications for active interference are to increase or regain mobility, or to improve the position of the joint.

(*a*) *To increase or regain Mobility.*—The procedures which can be adopted include manipulations (often with the assistance of various appliances), anæsthesia and stretching or rupture of adhesions, and open operation. In connection with forcible stretching of adhesions, care must be taken to avoid fracture of bones which are often atrophic, and it must be remembered that torn adhesions will bleed, and so predispose to re-formation. Old-standing cases of tuberculous arthritis should never be manipulated, as latent infection is thereby stimulated to activity. Open operations include wide excision of bones, as in the case of the jaw or elbow joint, and arthroplasty, e.g. the head of the femur is exposed and surrounded by a flap of fascia. In either case early movements must be instituted.

In the case of false ankylosis of the jaw, e.g. following fibrosis of the masseter muscle secondary to an alveolar abscess, the formation of a false joint may be considered when other measures have failed. The operation entails removal of a wedge-shaped piece of jaw in the region of the angle, and suturing portions of the internal pterygoid and masseter muscles together so that formation of a false joint is encouraged (Esmarch).

(*b*) *To improve Position.*—The necessity for dealing with this contingency theoretically should not arise, as ankylosis should only be allowed to occur in a satisfactory position. However, if alteration in the position of the joint will result in improvement of function, then excision of the joint or osteotomy are the usual procedures. Thus, a flexed knee is excised, and arthrodesis secured in the completely extended position, with a slight degree of genu valgum. By this means a rigid leg, nearly equal in length to its fellow, is obtained, the only remote drawback being the slight risk of fracture of the now unyielding bone which extends from hip to ankle.

In some cases osteotomy is preferable to excision, e.g. in the case of a quiescent tuberculous hip joint with marked adduction. A Gant's subtrochanteric osteotomy, possibly combined with division of some of the adductor muscles close to their origins, is a simple operation which permits correction without risk of lighting up tuberculous infection.

HÆMOPHILIA

This condition is a familial disease, but only males are affected. It is due to deficiency of prothrombin in the blood, and in the composition of the blood platelets, which normally number about 250,000 per c.mm. The coagulation time of the blood is prolonged, but is diminished by the addition of normal blood.

Extravasations of blood are characteristic of this condition, and joints are commonly affected, notably the knee joint. A rapid hæmorrhagic effusion occurs, which is followed by an inflammatory reaction, so that the joint feels hot and somewhat tender. As absorption occurs, the thickened synovial membrane remains palpable, and this feature, with its associated stiffness and wasting due to enforced rest, may simulate tuberculous disease.

If repeated hæmorrhages are allowed to take place, degenerative changes follow, similar to those seen in osteoarthritis.

Treatment consists in rest and the application of cooling lotions to the affected joint. A small intravenous transfusion prevents further hæmorrhage, but intramuscular hæmoplastin or horse serum are suitable substitutes. Monthly injections of blood should be given until the child outgrows the tendency to bleed.

It may here be mentioned that recent research indicates that bleeding in hæmophilics can be arrested by the local application of the venom of Russell's viper. The venom is kept in the dry state to prevent decomposition, and is applied in 1 : 10,000 dilution. In this strength the venom still possesses powerful coagulant properties, but the poison is harmless.

CHAPTER XXXVII

MUSCLES, TENDONS, AND BURSÆ

Injuries of Muscles and Tendons

Contusion of a muscle following a direct injury, or a strain due to sudden powerful contraction, is likely to result in tearing some of the muscle fibres. In either case localised pain follows attempts at contraction, and an extravasation of blood occurs within the muscle sheath. This extravasation often appears at a considerable distance from the actual site of injury, e.g. hæmorrhage from a torn rectus femoris in its upper part may appear near the patella. As with all hæmatomata, blood-borne infection is a possibility, in which case suppuration is liable to ensue.

Cold applications and relaxation of the muscle are required for the first two days, and, when risk of further extravasation has passed, massage and movements will expedite absorption, and prevent, or limit, subsequent stiffness.

Rupture of a muscle occasionally occurs, the tear usually occurring at the junction of tendon and muscle itself. Thus the quadriceps extensor ruptures immediately above the patella. The condition somewhat resembles a fractured patella, and repair with mattress or interlocking stitches is necessary. The prognosis is less favourable than in the case of a fractured patella, as approximation of muscle is more difficult than bone, and the fibrous union in the muscle subsequently tends to stretch.

Two varieties of "tennis leg" are, partial rupture of the inner head of the gastrocnemius, and snapping of the plantaris muscle at the junction of the tendon and muscular belly, i.e. about 2 to 4 in. below the knee joint. In either case sudden pain results, which is often so severe that the

sufferer imagines that he has been struck by a stone or racket. Rest, relaxation, and cold applications are indicated, to be followed later by strapping and massage.

"Tennis elbow" is commonly due to tearing of part of the deep head of the pronator radii teres. It follows the abrupt pronation necessary to impart "top spin" on the ball. Pain is localised to the antecubital fossa, and is accentuated on efforts to pronate the forearm.

A "mallet" finger (*syn.* baseball finger) is due to avulsion of an extensor tendon of the finger, which often includes a small flake of bone from the base of the proximal phalanx. A malleable splint is strapped to the palmar aspect of the hand and finger, the distal inch of which is bent backwards so as to hyperextend the last phalanx. A small pad of sorbo rubber or felt is fixed over the base of the first phalanx, so as to approximate the torn tendon with its insertion (fig. 696). The splint is retained for at least three weeks. Unless treated promptly and efficiently, much disability results, and efforts at suture give poor results, owing to the difficulty of suturing the tendon to the periosteum.

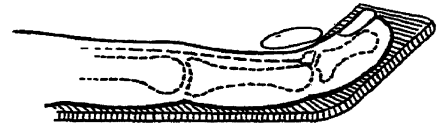

FIG. 696.—Splint and pad applied for a mallet finger.

The long tendon of the biceps is sometimes torn at its junction with the muscle, or in the case of osteo-arthritis of the shoulder joint, the frayed tendon may snap. Recognition is easy, as on flexing the forearm the soft muscular belly is drawn downwards towards the elbow. Some hypertrophy of the short head partially compensates for the resulting deficiency, and efforts at repair are unlikely to be successful.

The pubic attachment of the adductor longus muscle is sometimes partially avulsed when riding a frisky horse. Myositis ossificans may subsequently supervene. Tetanus or strychnine poisoning has been known to cause violent contractions and consequent rupture of the rectus abdominis muscle (fig. 6).

Hernia of a muscle sometimes follows a tear of the muscle sheath, the adductors and biceps brachii being the muscles most commonly affected. On contraction muscular fibres protrude through the aperture in the sheath. This feature distinguishes a torn sheath from a torn muscle, as in the latter case a gap appears between the two portions on contraction. If disability ensues, the sheath is sutured.

Displacement of tendons occasionally occurs where these structures traverse fibro-osseous canals, e.g. in the region of the wrist or ankle, or the long head of the biceps in the arm. Sudden pain occurs, followed by a sensation of weakness and further pain on attempted movements. The displaced tendon, if superficial, e.g. the peroneus longus, can be palpated in its abnormal position. The replaced tendon should be immobilised for at least eight weeks. Recurrence is likely, and if disability persists, the tendon is fixed in position, if necessary a flap of periosteum being raised from the bone in order to form a tunnel for the tendon. A "snapping hip" is due to that portion of the gluteus maximus which is inserted into the ilio-tibial band hitching over the great trochanter.

Inflammation of Muscles.—Acute suppurative myositis follows either direct infection, or local extension from adjacent structures, e.g. osteomyelitis. "Rheumatic" myositis is a troublesome complaint, and mainly affects fascial aponeuroses, tendinous insertions, or muscular sheaths, and in these cases the term "fibrositis" is applied. The condition often arises abruptly, e.g. in the case of lumbago, on attempting to get out of bed the affected person may be seized in the midway position, and be unable to move without assistance. In some cases exposure precipitates an attack, e.g. a draught may result in a stiff neck. Some focus of infection is frequently a predisposing cause, and should always be sought. Treatment consists in local warmth and rubefacients. Radiant heat baths, ionisation, or diathermy may be useful. In severe localised cases injection of quinine and urea should be tried if the condition fails to respond to other measures. Aspirin and anti-rheumatic remedies are

prescribed. Tuberculous myositis is due to extension from some neighbouring focus of infection, e.g. a psoas abscess in connection with a tuberculous spine. Syphilitic myositis may occur as a localised gumma, particularly in the sterno-mastoid muscle or tongue. An indurated swelling appears, which gradually involves the overlying skin or mucous membrane. More rarely a diffuse myositis occurs, e.g. parenchymatous glossitis, the tongue eventually becoming fibrotic.

Myositis ossificans of the generalised type is a rare condition, commencing in young adults, in which muscles are gradually transformed into bone. The condition usually commences in the flat muscles of the back, and spreads to the spinal and thoracic muscles. The condition steadily progresses, and the patient gradually becomes more rigid ("poker" man), until fatal respiratory complications supervene. Congenital deficiency of the last phalanx of the big toes is sometimes associated with the condition.

Myositis fibrosa and traumatic myositis ossificans are considered in connection with fractures.

Tumours of Muscles.—*Innocent.*—Lipomata and fibromata occasionally occur in connection with muscles.

Malignant.—Primary fibro-sarcoma is not uncommon, and arises from the muscle sheath. This tumour was formerly confused with a fibroma, and it is sometimes difficult to be dogmatic in distinguishing a fibroma from a slowly growing fibro-sarcoma. Failure to realise the sarcomatous nature of these tumours accounts for Paget's description of them as "recurrent fibroids" (fig. 15). A slowly growing swelling appears, which is firm, circumscribed, and connected with the muscle. Exploration is necessary if the tumour is deeply situated, and on confirmation the tumour is removed with a wide margin of surrounding muscle.

Secondary invasion of muscles sometimes occurs, e.g. the pectoralis major, following carcinoma of the breast.

Tendon Sheaths

Simple teno-synovitis follows excessive or unaccustomed use, and is most commonly seen in connection with the extensor tendons of the hand. Pain and puffiness are present, and a characteristic soft crepitus is palpable when

the fingers are moved. An adequate period of rest, followed by counter-irritants and massage, suffices to effect a cure, but relapse is probable unless care is taken to prevent a repetition of the initial lesion.

Acute infective teno-synovitis either follows wounds, e.g. extension from whitlows, or is blood-borne, as in the case of gonococcal infection. Severe pain results from any movement which causes the tendon to glide in its sheath. If

FIG. 697.—Compound palmar ganglion, showing swelling above the anterior annular ligament.

due to a virulent organism, suppuration is probable, which rapidly extends along the tendon sheath. Unless early and adequate incisions are made, sloughing of tendons is likely to occur. If this complication is avoided, early movements are indicated in order to discourage the organisation of exudate and consequent crippling adhesions.

Tuberculous teno-synovitis is of two types:

(*a*) The endothelial lining of the sheath is replaced by œdematous granulation tissue, containing miliary tubercles. Very little free fluid is present. A soft elastic swelling

appears, and if the disease progresses, pus may form, and track into neighbouring sheaths or joints.

(*b*) An effusion occurs in the tendon sheaths, and melon-seed bodies are usually present in large numbers, so that a soft, coarse crepitus may be detected on pressing fluid from one part of the sheath to another. These melon-seed bodies may be rounded, as distinct from the flat variety found in joints, and in appearance resemble grains of boiled sago. The term "compound palmar ganglion" is applied to this condition when it occurs in connection with the flexor tendons of the fingers. A soft, painless swelling appears (fig. 697), and fluctuation may be transmitted above the



FIG. 698.—Simple ganglion in connection with the tendon of the peroneus brevis muscle.

wrist, under the anterior annular ligament. As with all forms of tuberculous disease of bone, joint, or tendon, marked wasting of adjacent muscles is present. Treatment consists in the usual anti-tuberculous remedies, and careful dissection and removal of the diseased tendon sheaths.

A simple ganglion appears as a localised, tense swelling in connection with a tendon sheath, and contains clear gelatinous fluid. It is possibly due to herniation of the endothelial lining of the tendon sheath through the fibrous covering, which is ruptured by direct trauma, e.g. rapping a child's knuckles. Rupture of the sheath as a result of trauma is most likely to occur where the tendon lies on bone,

and this coincides with the fact that simple ganglia are so commonly found on the dorsum of the wrist and foot (fig. 698). Rupture of the ganglion can be accomplished by pressure, or a blow, but recurrence is likely. Some cases are cured by aspiration with a wide-bore needle and injection with collodion, followed by firm pressure for a few days If simple measures fail excision should be performed, and even then recurrence frequently occurs, as it is impossible to close the small aperture in the fibrous sheath, and adventitious adhesions are unreliable.

Tumours of tendon sheaths occasionally occur, and are designated *teno-synoviomata*. These tumours arise from the synovial membrane lining the tendon sheath, and are either innocent or malignant. Innocent tumours are apt to undergo metaplasia, and are liable to contain fibrous tissue, cartilage, or even bone. In both the innocent and malignant types "foam" cells are characteristic, which are large and spheroidal, and contain numerous fat droplets.

Operations on Tendons

Tenotomy is performed either by the open or the subcutaneous method. The latter is to be preferred in situations where there is little risk of damage to important structures. Thus the tendo Achilles is divided by the insertion of a tenotomy knife under the tendon, from the inner side, about 1 in. above its insertion. Dorsi-flexion of the foot facilitates division of the tendon. Deformity should not be corrected until about two weeks after division, which lapse of time allows granulation tissue to form between the two ends of the tendon, and thus the risk of non-union is diminished. In children over the age of 5 years, open operation and deliberate lengthening of the tendon by the "Z" method is advisable, as otherwise excessive retraction and non-union are liable to follow.

Three tendons should be divided by the open method. These are: the biceps cruris, in order to avoid injury to the external popliteal nerve; the sterno-mastoid tendon and muscle, on account of important adjacent structures and also to allow division of fascia; and the adductors in the case of gross coxa vara. In the latter case division of muscle will also be necessary, as well as division of the

tendon, and the femoral vessels may be displaced inwards, so these are thus avoided as well as the internal saphenous vein and obturator nerve.

Shortening of a tendon is best accomplished by the "Z" method. The two halves of the tendon, after separation, are shortened as required, and the tendon is then stitched.

Tendon transplantation is performed in order to restore muscular balance, or to supplement the action of ligaments. In the former case care must be taken that tendons act as far as possible in their normal alignment, and that they supplement deficient muscles of the same group, otherwise complicated re-education is necessary, which is often incomplete. If possible tendons should be fixed to bone, for if inserted into tendons connected with paralysed muscles, stretching of the paralysed tendon is certain to occur, so that results at first hopeful become progressively disappointing.

Diseases of Bursæ

Injury.—Acute non-infective bursitis follows injury. Thus a blow on the shoulder may cause subdeltoid bursitis (Codman's disease). If effusion follows, the rounded shoulder suggests an effusion into the joint, but absence of swelling in the axilla excludes the latter condition.

Non-infective bursitis may also follow unaccustomed exercise, e.g. inflammation of the bursa under the tendon of Achilles after a cross-country run.

Chronic bursitis is the result of repeated slight injuries, or constant pressure, e.g. housemaid's knee (prepatellar), parson's knee (pretubercular), student's or miner's elbow (olecranon), weaver's bottom (tuber ischii). Certain bursæ show a marked tendency to enlarge, e.g. those in the popliteal space. The bursa between the inner head of the gastrocnemius and the semi-membranosus tendon is commonly affected, a rounded, painless swelling resulting (fig. 699). Examination in both flexion and extension is imperative, as in extension pressure by adjacent tendons renders the bursa tense, and it may be mistaken for cancellous osteoma, whereas the flaccidity which accompanies

flexion indicates the cystic nature of the swelling. Popliteal bursæ, which communicate with the knee joint, sometimes enlarge as a result of such conditions as osteo-arthritis of the joint, and similarly enlargement of the psoas bursa may follow any chronic effusion into the hip joint. Thus distension of bursæ which communicate with a joint is a warning that some underlying disease of the joint may be present.



FIG. 699.—A semi-membranosus bursa, tense in extension and flaccid in flexion.

Adventitious bursæ form as a result of prolonged pressure over bony prominences, e.g. Billingsgate hump, due to pressure of a fish-basket over the seventh cervical spinous process, or in connection with the head of the first metatarsal bone in cases of hallux valgus, the term "bunion" being applied to this latter bursa when inflammation supervenes. Chronically inflamed bursæ are excised if troublesome.

Infection.—Acute infective bursitis is due to direct infection by penetrating wounds, or from local extension, e.g. "gravel rash" over the patella may cause subcutaneous infection and involvement of the prepatellar bursa. In the case of prepatellar bursitis, a sympathetic effusion into the knee joint sometimes follows, but confusion with infective arthritis should be avoided, as in the latter condition any attempt to move the joint is painful, and pain is elicited on pressure in the popliteal space. If suppuration ensues, drainage is necessary.

Chronic infective bursitis is either tuberculous or rarely syphilitic.

Tuberculous bursitis resembles tuberculous teno-synovitis, in that one of two varieties occur: either an effusion

containing melon-seed bodies, or a variety in which the bursa becomes lined with granulation tissue, and which may progress to abscess formation, and eventually fistulæ. The gluteal bursa between the insertion of the gluteus maximus and the great trochanter is particularly prone to tuberculous infection. A rounded swelling occurs below the great trochanter, and the limb is held abducted and everted, in order to relax the gluteus maximus. The condition thus somewhat resembles the first stage of a tuberculous hip joint, but flexion is absent, and movements of the hip joint are not unduly restricted.

A tuberculous bursa should be completely excised, an operation often of considerable difficulty, on account of ramifications and lobulations of the bursa.

Syphilitic bursitis occurs during the secondary stage, and gives rise to transitory, and often symmetrical, effusion. During the tertiary stage, a local gumma or a diffuse gummatous bursitis are uncommon manifestations.

New-growths.—An endothelioma from the lining membrane, or fibro-sarcoma from the wall, rarely occur.

CHAPTER XXXVIII

DEFORMITIES

DEFORMITY is due to the following anatomical causes :

(i) Skin and subcutaneous tissues, such as scars or burns, or Dupuytren's contracture.

(ii) Muscles and tendons, e.g. unbalanced muscular action in infantile paralysis, or adherent tendons following a thecal whitlow.

(iii) Ligaments, e.g. relaxation following distension of a joint, or fibrosis, as in polyarticular osteoarthritis.

(iv) Joints, e.g. congenital deformities, or prolonged malposition.

(v) Bones, e.g. irregular growth, as in partial destruction of an epiphyseal line following osteomyelitis.

(vi) Nervous lesions, either peripheral, such as claw-hand following division of the ulnar nerve, or central, as with spastic paraplegia.

Consideration of the above causes will suggest that deformities are often preventable, and many extensive and sometimes mutilating operations would be rendered unnecessary if care and foresight were used in the early treatment of cases in which deformity may subsequently occur. The following summary indicates the surgical procedures which may be adopted for the correction of deformities :

(i) Manipulation, such as stretching the sterno-mastoid muscle in early cases of congenital torticollis.

(ii) Manipulation with retentive apparatus, as by stretching the tendo Achilles in a case of talipes equinus and applying a tin night shoe.

(iii) Anæsthesia and forcible correction, e.g. wrenching a flat-foot, and maintaining the corrected position in a plaster of Paris case.

(iv) Operations on soft parts, such as fasciotomy, tenotomy, or muscle-sliding operations.

(v) Operations on joints, as by performing arthrodesis for a flail ankle joint.

(vi) Operations on bones, either osteotomy, excision, or amputation.

Torticollis

Acquired torticollis is due to the following causes :

(i) *Rheumatic.*—This is due to exposure to cold or a draught, e.g. a chilly drive in an open car. The onset is sudden, and muscles are tender on pressure. A radiant heat bath in the early stages usually leads to rapid recovery. Salicylates or aspirin, and local applications to promote hyperæmia, are useful adjuncts.

(ii) *Spasmodic.*—This distressing condition, fortunately uncommon, occurs chiefly in neurotic, middle-aged ladies. It is characterised by clonic spasms of the sterno-mastoid and trapezius muscles on one side of the neck, and later the deep cervical muscles on the opposite side may be affected. The head is continually jerked downwards towards one shoulder, particularly during excitement, and mental instability commonly follows. Treatment is unsatisfactory, but every effort is made to discover any possible source of peripheral irritation, and sedatives are prescribed. Division of the spinal accessory nerve on one side, and of the opposite posterior primary divisions as they lie in the semi-spinalis colli, is sometimes necessary, but even this procedure is not always successful, as cortical changes may be present.

(iii) *Reflex* —This is due to some associated source of peripheral irritation, e.g. teeth, nose, or air sinuses.

(iv) *Inflammatory.*—Parotitis, or an inflamed gland adjacent to the spinal accessory nerve, is liable to cause temporary contraction of the sterno-mastoid muscle.

(v) *Hysterical.*—Torticollis, in common with almost any deformity, is sometimes due to hysteria.

(vi) *Compensatory.*—Torticollis may develop as a result of scoliosis, in order to maintain the eyes on a horizontal level.

Congenital torticollis is due to myositis fibrosa of the

sterno-mastoid muscle, following temporary interference with its blood-supply. Acute lateral flexion of the head, if sustained for a short time, either squeezes the blood out of the sterno-mastoid, or kinks the arteries which supply it, and which are alleged to be " end " arteries. In either case the muscle is temporarily deprived of blood, degeneration follows, and changes occur similar to those associated with Volkmann's ischæmic contracture. That lateral flexion of the head does certainly occur in some of these cases is proved by the fact that Erb's palsy of the opposite arm is occasionally associated, and this condition is known to follow acute lateral flexion of the head to the opposite side, i.e. the side upon which the torticollis occurs. Hemiatrophy of the face follows, due to lack of use ; thus the nose appears flattened, the eyebrow is less arched, and the distance between the outer canthus and the angle of the mouth is less on the affected side than on the normal. The bodies of the cervical vertebræ become wedge-shaped, and a compensatory curve develops in the dorsal spine so as to maintain the eyes on a horizontal level.

The diagnosis of congenital torticollis is easily made, as the sterno-mastoid tendon is apparent as a rigid subcutaneous bar, and the muscle can be palpated as a tense band, postero-lateral to the tendon.

Applying the principles already enunciated, the following lines of treatment may be adopted :

(i) *Manipulation.*—As soon as the condition is recognised, the mother or nurse is instructed to rotate the child's head so as to stretch the contracted muscle, i.e. the chin must be rotated to the affected side, the rotation being combined with extension of the head. In early cases patience and perseverance will be rewarded, and satisfactory results are obtained.

(ii) *Manipulation with Retentive Apparatus.*—In addition to the above, maintenance in the correct position can be obtained by an apparatus which consists of two padded leather straps which encircle the forehead and axillæ respectively. An elastic band is attached to the forehead strap above the mastoid process on the unaffected side, and a constant pull is maintained by fixing this band to the lower strap on the opposite side of the front of the body.

(iii) In old-standing cases, or under circumstances where the child will not receive careful or intelligent attention, division of the sterno-mastoid muscle should be performed.

Subcutaneous division of the tendon alone is readily performed, but little improvement is likely, as contraction of the muscle and underlying fascia still persists. The tendon is displaced forwards to such an extent that division of it alone from before backwards can be performed with safety. Open division leaves a small scar, but is devoid of danger, and permits thorough division of the whole muscle and also of contracted underlying fascia. A transverse incision is made ½ in. above the clavicle, and the tendon and muscle are divided. The anæsthetist rotates the head, and successive tense fascial bands are divided. Large veins, particularly the anterior jugular as it passes outwards underneath the muscle, must be carefully avoided, as injury is liable to cause troublesome hæmorrhage. The head is subsequently fixed in the corrected position between sand-bags for about a fortnight. Subsequent treatment depends upon the child's surroundings. The constant and intelligent performance of exercises under supervision will remedy the deformity, but if this is impossible, then the head should be fixed by a plaster of Paris collar for a month or six weeks. Hemiatrophy of the face sometimes persists as a permanent condition.

Spinal Deformities

Scoliosis.—This condition consists of lateral curvature of the spine, accompanied by rotation of the vertebræ. It occurs as a congenital deformity but rarely, and is then due to a wedge-shaped vertebral body following maldevelopment. The acquired cases may be classified as follows :

(i) General disease of bone, such as rickets, osteomalacia.

(ii) Local disease of bone, e.g. Pott's disease, osteomyelitis.

(iii) Unbalanced muscular support, as with infantile paralysis of one erector spinæ, the normal muscle acting as a bowstring so that the concavity of the spine is towards the sound side. Increased spasticity of one erector spinæ exerts a similar effect, e.g. in cases of syringomyelia, in which asymmetrical dilatation of the central canal of the cord irritates one pyramidal tract to a greater extent than its fellow, thus causing spasticity of the corresponding group of spinal muscles.

(iv) Compensatory, e.g. irregularity in the length of the legs, collapse of one side of the chest, or torticollis.

(v) Static, by which is meant a deformity which is due to

no actual disease, but to a combination of some or all of the following conditions :

(*a*) Excessive fatigue, e.g. prolonged standing.

(*b*) Habitual assumption of a faulty posture, e.g. a nursemaid carrying a baby always on the same arm—both suffer.

(*c*) Adolescence, with its associated asthenia, rapid increase in weight, etc.

(*d*) Hygienic conditions, such as unsuitable food, poor ventilation, etc.

Static scoliosis is the most important group from the surgeon's standpoint, as early recognition and adequate treatment will prevent lifelong deformity, with its associated physical and psychical effects. Usually two curves are present, the primary being in the lumbar region and the compensatory in the dorsal. In addition to the lateral curvature and rotation of the vertebræ, changes also occur in the thoracic wall ; thus, the ribs on the side of dorsal convexity are separated, and the scapula projects or " grows out " on that side, while the chest appears flattened in front. On the other hand, the ribs on the side of the concavity are crowded together, and the chest as seen from the front is unduly prominent, also the costocristal space on this side is narrowed, and the hip appears to project (fig. 700).

FIG. 700.—Adolescent scoliosis, showing " growing out " of the right shoulder and left hip. (Photo by Dr. R. V Harris)

In severe cases neuralgia occurs from pressure on spinal nerves, and osteoarthritis of the spine may eventually supervene. Right heart failure or intercurrent lung complications sometimes contribute to a fatal issue.

Treatment.—For the purpose of treatment, static scoliosis is divided into three stages :

Stage 1.—The patient is allowed to assume a position of ease, so that deformity is apparent. The spinous processes

are marked by means of a flesh pencil, so that the extent and situation of the curve are obvious. The curve, as indicated by the spinous processes, is less than that assumed by the bodies of the vertebræ, as owing to rotation, the spines are directed towards the concavity. The patient is still in Stage 1 if, on touching the toes, the curve is obliterated.

Stage 2.—As the condition advances, secondary contraction of ligaments and muscles occurs, and hence flexion of the spine fails to correct the deformity. X-ray examination, however, fails to reveal any bony change.

Stage 3.—The effect of prolonged contraction of ligaments and muscles, and consequent protracted interosseous pressure, is to cause pressure absorption of vertebral bodies, which consequently become wedge-shaped (a condition revealed by a radiograph) (figs. 701 and 702).

The treatment of static scoliosis which is still in its first stage consists in careful attention to the patient's health and hygiene, remedial exercises well within the limit of fatigue, and adequate rest, including a definite period during the daytime, in the supine position. Care should be taken to obviate faulty posture, e.g. badly constructed school desks, or the constant twist of the body in order to view a blackboard continuously from the same angle. These measures, if practicable, are curative in the early stages. If for economic reasons such ideal treatment cannot be carried out, then a corset or spinal jacket should be worn, except during periods of rest, and the above general treatment is modified to the circumstances of the patient.

When the second stage has developed, spinal jackets prevent the condition progressing, and often effect an improvement. A poroplastic jacket should be fitted for a child, as it is cheap, and can be economically renewed as growth occurs. A hinged flap is provided so that continuous pressure is exerted over the prominent ribs. The general principles indicated in connection with the first stage are applied as adequately as circumstances permit. In the case of patients so situated that considerable time can be devoted to treatment, the application of Abbot's jacket should be

considered. This consists of a plaster jacket which is applied while the patient lies on a canvas frame, or is suspended in order to obliterate curves as completely as possible. Apertures are cut in the jacket over the concavity and convexity of the chest, and felt pads are inserted over the

FIG. 701.—Third degree of static scoliosis, early stage The bodies of the vertebræ are becoming wedge-shaped. (R.C S. 4813 1.)

FIG. 702.—Third degree of static scoliosis, advanced stage. The bodies of the vertebræ are excessively rotated, and ribs on the concave side are crowded together. (R C S. 4182.1.)

prominent ribs in order to exert continuous pressure on them, while the aperture over the concavity encourages expansion of that portion of the chest. Jackets are renewed at intervals of about three months, and the application of three or four jackets usually results in marked improvement.

When the third stage is established, remedial treatment

may still improve the condition if it is persevered with over a period of years, particularly if the patient is adolescent. The application of a plaster of Paris bed with proper sling straps, worn continuously every night, will improve even severe cases.

Other types of scoliosis are treated by dealing with the cause of the trouble, e.g. rickets is combated by means of hygiene and diet, while inequality in the length of the legs needs correction. Compensatory scoliosis due to collapse of a lung is readily recognised by flattening of the chest, as distinguished from the usual prominence of the ribs in front on the side of the concavity, and no treatment is necessary for this type. Scoliosis due to unbalanced muscular action should be kept in check by a spinal support, e.g. a Taylor's brace or Chance's splint.

Kyphosis is a term applied to a condition of increased dorsal convexity of the spine. Its causes are similar to those of scoliosis, and are as follows :

(i) General disease of bone, such as osteitis deformans, osteoarthritis of the spine, senile atrophy.

(ii) Local disease of bone, which may be associated with Pott's disease, secondary carcinoma, fracture.

(iii) Static, especially the " round shoulders " of children, and in those whose occupation entails stooping or carrying heavy weights, e.g. porters.

Kyphosis is divided into three stages, corresponding to those of scoliosis, i.e. when posture corrects the deformity ; secondly when the deformity persists in spite of posture, but no bony change is seen in a radiograph ; and thirdly, when a lateral X-ray shows alteration in the shape of the vertebræ.

TREATMENT consists of dealing with any preventable cause, attention to the general health, adequate rest, and suitable exercises. A spinal support may be necessary in advanced cases, or when the patient, owing to economic considerations, is unable to devote the necessary time for general treatment.

Lordosis consists in an exaggeration of the anterior lumbar curve, and is usually compensatory. Thus it is present in cases of bilateral congenital dislocation of the hip (fig. 708), in order that the centre of gravity of the body may pass behind the hip joints, as is normally the case. Increase of

weight of the abdominal contents, e.g. fat, tumours, or pregnancy, causes lordosis for the same reason.

TREATMENT consists in dealing with any removable cause.

Spondylolisthesis is a rare deformity, in which the lower lumbar vertebræ slip forward on to the front of the sacrum. It is due to imperfect development of the pedicles of the fifth lumbar vertebra, and any tendency to lordosis, e.g. pregnancy, encourages the displacement forward of the vertebræ. Cases have also been attributed to fracture of the lumbo-sacral articular processes. Pain, local and referred, results, and on examination a hollow is seen posteriorly, and the displaced vertebræ may be palpable through the abdominal wall. The lower ribs descend, and sometimes rest on the iliac crests, and stature diminishes.

TREATMENT consists in rest and supports, so arranged that part of the body weight is transmitted from the axillæ to a pelvic band by means of lateral irons.

UPPER EXTREMITY

Congenital elevation of the shoulder (*syn.* **Sprengel's shoulder**) is a condition in which the scapula is smaller than normal, and situated at a higher level. The inferior angle is rotated inwards. In bilateral cases the appearance of the patient at first suggests that the neck is abnormally short (fig. 703). The rhomboid muscles are partially fibrous or even cartilaginous, and the trapezius and serratus muscles are sometimes deficient.

TREATMENT consists in exercises and massage, and surprisingly little disability results.

FIG. 703.—Sprengel's shoulder (from the *Edinburgh Medical Journal*, and courtesy of Stewart Middleton).

Cubitus valgus or varus results from separation of the lower epiphyses of the humerus, fractures, or inflammatory conditions, e.g. osteomyelitis. Normally, the forearm is in a position of abduction as compared with the arm, this "carrying angle" being 13° in men, and 15° in women. Increase of this angle, or cubitus valgus, may give rise to a localised patch of neuritis in the ulnar nerve, as the groove behind the internal condyle acts as a pulley, and friction results. Anterior transposition of the nerve is sometimes

necessary. The treatment of cubitus valgus or varus is largely preventive, but if the condition is established and disability results, supracondylar osteotomy is considered.

Congenital absence of the radius occasionally occurs, in which case growth of the ulna pushes the hand to the radial side. The lower articular surface of the ulna is expanded, and articulates with the proximal row of carpal bones.

Contraction of the palmar fascia (*syn.* **Dupuytren's contracture**) occurs in individuals whose work entails pressure on the palms, e.g. cobblers, and is consequently more frequently seen in men than in women. The condition commences as a local patch of induration in the palm, and contraction first affects the ring finger, which becomes



FIG. 704.—Splint for Dupuytren's contracture.

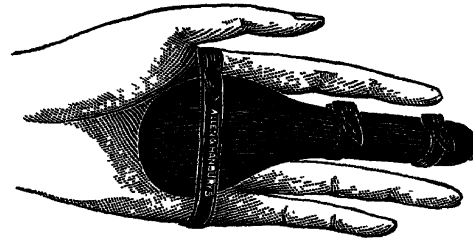

FIG. 705.—The splint applied.

drawn into the palm. The little finger is usually next affected, and other fingers may follow. The thumb is rarely involved. The condition is readily diagnosed by the presence of palmar induration, and the fact that the contracture is not influenced by the position of the wrist.

In the early cases splinting sometimes effects a cure (figs. 704 and 705), but when the condition is established, free excision of the affected palmar fascia is indicated, and splints should be applied during healing. In advanced cases excision of the heads of the first phalanges is also necessary.

Trigger finger is a condition in which extension of a finger or thumb is arrested, but when assistance is forthcoming with the other hand, the flexed finger extends with a jerk or snap. The cause of the condition is some obstruction under the transverse ligament of the fingers, or between the

sesamoid bones of the thumb, such as a ganglion or a fibroma growing from the nerve sheath.

Treatment consists in removal of the cause.

Congenital deformities of the fingers include the conditions of syndactylism, macrodactyly, and congenital contracture. Syndactylism, or webbed fingers, is a condition in which two or more fingers are joined together. An X-ray should be taken, and if normal bones are present, separation of the fingers will improve the function of the hand.

The two-stage operation (Didot) should be performed, the first step of which consists in establishing an epithelialised tunnel at the base of the web. This is obtained by dividing the base and stitching a flap of adjacent skin over the raw surface. A glass rod is inserted between the fingers and kept in position until the tunnel is covered by epithelium. The second stage consists in a plastic operation, two flaps of skin, the length of the web, being dissected from the front and back of the fingers respectively, in such a manner that when the web is divided the raw surfaces of the fingers are covered, one by the dorsal, and the other by the palmar, flap. Syndactylism of the toes needs no treatment. Macrodactyly consists of overgrowth, possibly enormous, of a digit. A plastic operation, or amputation, is occasionally necessary.

Congenital contracture of a finger most commonly affects the little finger, and is due to contraction of the central slip of palmar fascia. Hyperextension occurs at the metacarpophalangeal joint, and flexion at the two interphalangeal joints. If necessary, a posterior splint is applied, or if sufficient disability exists, the central slip of fascia is excised.

Deformities of the Lower Extremity

Congenital dislocation of the hip, of the posterior variety, is a not uncommon condition ; about a quarter of the cases occur in boys, and about the same proportion are bilateral.

The condition is due to lack of development of the iliac portion of the acetabulum, and at birth the head of the bone articulates with the ill-formed articular cavity. When walking commences, dislocation occurs, and absence of pressure on the head of the bone results in deficient growth. Continued walking displaces the head of the bone upwards on the dorsal surface of the ilium (fig. 706), and the acetabulum assumes a triangular shape. The capsule of the joint stretches and becomes constricted about its centre,

FIG. 706.—Unreduced congenital dislocation of the hip joint.

thus forming an isthmus, while the ligamentum teres lengthens. A slight degree of coxa valga occurs, and the angle of declination, or torsion of the neck of the femur on the shaft, is increased.

Clinical Features.—The condition is not usually recognised until the child begins to walk, which is somewhat later than usual, e.g. 16 to 24 months. If the condition is unilateral a limp is noticed, whereas in bilateral cases the child " waddles like a duck."

Examination of a unilateral case reveals the following features :

(*a*) *Inspection.*—Lordosis, if present, is obliterated by flexion of the hip, and any obliquity of the pelvis is corrected. Shortening of the leg is then apparent, and some degree of flexion is present. The great trochanter appears prominent, and muscular wasting is slight.

(*b*) *Palpation.*—This reveals loss of resistance in Scarpa's triangle, owing to absence of the head of the femur. The great trochanter is raised, and on palpation posteriorly the head of the femur is detected on the dorsum ilii as a hard,

rounded, painless swelling. Confirmation is obtained by adducting the leg and rotating the femur, when the head of the bone is felt to roll beneath the fingers.

(*c*) *Movements.*—An abnormally wide range of movements is usually obtainable, especially in the direction of adduction. "Telescopic" movements are sometimes obtained by traction on the femur, and, if the child has walked but little, reduction of the dislocation may be possible.

(*d*) *Measurement.*—This confirms shortening of the limb. The tip of the great trochanter is above Nélaton's line, which connects the anterior superior spine and the tuber ischii; and the base of Bryant's triangle, i.e. the side connecting the great trochanter and the anterior superior iliac spine, is shorter than on the normal side.

Morris's bitrochanteric measurement, which is obtained by means of a calliper, shows that the great trochanter on the affected side is nearer the midline than its fellow.

(*e*) *Trendelenburg's Test.*—The child stands on the affected limb, with the sound limb raised from the ground. The pelvis tilts downwards towards the sound limb owing to inability of the muscles to steady the lax joint on the affected side. In the case of a normal joint, contraction of muscles fixes the hip joint and no tilting occurs (fig. 707).

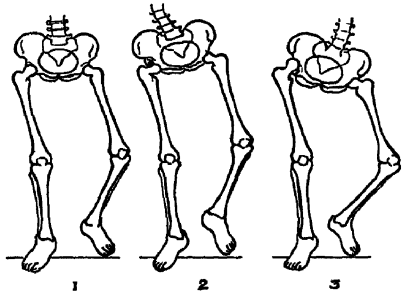

FIG. 707. — Trendelenburg's test 1. Normal hips: the pelvis remains level on raising one leg. 2. Coxa vara: on raising the sound leg the pelvis tilts upwards on that side. 3. Congenital dislocation: on raising the sound leg the pelvis tilts downwards.

(*f*) X-ray confirms the deformity and supplies information concerning the condition of the acetabulum and head of the femur.

In *bilateral* cases marked lordosis is present, which gives the appearance of prominent

FIG. 708.—Congenital dislocation of both hips, showing lordosis and perineal gap.

genitalia. Bilateral adduction causes a perineal gap, and in marked cases "scissors" deformity of the legs may result (fig. 708).

Treatment.—1. *Manipulative.*—This should be commenced as soon as the condition is recognised. The application of plasters must be postponed until the child has enjoyed complete control of the sphincters for at least three months, but in the meantime daily reduction should be performed in order to encourage development of the acetabulum and prevent contracture of muscles.

In order to apply the plaster, general anæsthesia is necessary, and the pelvis is steadied by an assistant. The flexors, extensors, and adductors are successively stretched, and the dislocation is reduced. Reduction is indicated by a "click," which can be seen, felt, and heard, also the loss of resistance in Scarpa's triangle disappears, and the hamstring muscles become taut. The limb is then fixed in plaster of Paris in the fully flexed and abducted position, with perhaps slight internal rotation. The plaster reaches to the ankle on the affected side, and includes the upper part of the opposite thigh, so as to fix the pelvis. A subsequent X-ray will be sufficiently clear to confirm the reduction. The plaster is removed in about three months, and reapplied in a less abducted position, this procedure being repeated at intervals. Walking is encouraged as soon as possible in order to force the head of the femur into the acetabulum. One year or more is necessary for completion of treatment.

2. *Operative.*—Operation may be considered after the age of 7 or 8 years until puberty, or in cases in which manipulation has failed owing to impossibility of reduction on account of the hour-glass contraction of the capsule.

Before open reduction is attempted, shortening of the limb must be reduced to 1 in. or less by means of weight extension in the abducted position, supplemented, if necessary, by division of the adductors, otherwise an undue amount of muscle and other soft tissues will need division in order to bring the head of the bone down to the level of the acetabulum. The usual anterior incision is made, passing downwards and slightly inwards from the anterior superior spine between the tensor fasciæ femoris and gluteal muscles on the outside, and the sartorius and rectus femoris on the inner side. If necessary the incision is prolonged upwards and outwards under the iliac crest. The capsule of the joint is opened and the isthmus divided, and the acetabulum is deepened by means of a burr. The head of the femur is trimmed if necessary and reduction is effected. An attempt may be made to reinforce the upper lip of the acetabulum by means of a bone graft, or the periosteum can be stripped up in order to encourage bony outgrowth. The limb is

fixed in abduction for some months, but walking is permitted after a few weeks.

The results of open reduction are not completely satisfactory, and considerable limitation of movement usually results. However, stability is correspondingly obtained, and shortening is reduced.

3. *Palliative.*—If reduction fails, and operation is contra-indicated on account of the condition of the patient, or if the child has reached puberty, then a high boot should be worn in order to correct shortening of the limb and prevent the development of compensatory scoliosis. The joint can be steadied by means of a pelvic band, to which is attached a leather cap, which is situated so that it exerts pressure over the great trochanter.

Anterior dislocation of the hip is a rare deformity, and gives rise to little disability. This being the case, some surgeons perform anterior re-position of the head of the femur in cases of posterior dislocation rather than reduction by open operation. The leg is manipulated so that the bone is brought to lie beneath the anterior superior spine, and it may be steadied in this position by raising a periosteal flap with a flake of bone attached, so that a false acetabulum is partially formed.

Coxa Vara.—This term indicates a diminution of the angle between the neck and shaft of the femur, which is, in adult males, about 135°. The angle is less in females, and gradually diminishes with age in both sexes. In addition to diminution of this angle, a curvature of the neck of the femur occurs, with its convexity forwards (fig. 709). Coxa vara is due to the following causes :

(i) General disease of bone, such as rickets, osteomalacia, or osteitis deformans.

(ii) Local disease of bone, e.g. osteomyelitis, pseudo-coxalgia, or a local cyst.

(iii) Trauma, as by separation of the epiphysis or fracture of the neck of the femur. A more important cause is "slipped epiphysis," which condition occurs during adolescence, and may date from a definite injury, or be due to repeated slight injuries, e.g. telegraph boys who repeatedly jar their right leg in dismounting from a bicycle. The clinical features of "slipped epiphysis," which from the surgical standpoint is the most important type of coxa vara,

FIG. 709.—Advanced coxa vara, due to neglected Perthes' disease.

consist of pain, which is commonly referred to the knee, and limp, which in the early stages is due to pain, and later to actual shortening.

Examination reveals the following signs :

(i) *Inspection.*—The limb is adducted, and usually slightly everted. If definite bony change is present, a corresponding degree of shortening is apparent, and the great trochanter is prominent, owing to the fact that as it rises towards the anterior superior spine it becomes more superficial. Wasting is detectable in established cases.

(ii) *Palpation.*—No tenderness or loss of resistance can be detected in Scarpa's triangle. The prominence of the great trochanter is verified.

(iii) *Movements.*—These are characteristic, abduction and internal rotation being limited. The narrowing of the angle between the neck and shaft of the femur explains the limitation of abduction, and adduction is correspondingly increased. Limitation of internal rotation is due to the anterior curvature of the neck of the femur, which comes in contact with the anterior rim of the acetabulum when inversion is attempted.

If the limb is examined during an exacerbation of trau-

matic synovitis, movements of the limb in all directions are restricted. A few days' rest in bed allows the synovitis to subside, and then the above characteristics are demonstrable.

(iv) *Measurement.*—Shortening of the limb is confirmed, and Bryant's triangle and Nélaton's line indicate that the shortening is above the great trochanter.

Treatment.—The treatment of slipped epiphysis depends upon the extent to which the condition has progressed. In the early stages weight extension should be applied to the limb in the abducted position, until free abduction is obtained, which is usually a period of about six weeks. Some surgeons, in order to shorten the time necessary for treatment, obtain abduction by means of traction under anæsthesia, but care and experience are necessary if accidents, such as a fracture of the neck of the femur, are to be avoided. When full abduction is obtained, a plaster of Paris spica casing is applied for six to eight weeks, after which a walking calliper is worn for some months until the neck of the femur has consolidated.

In the later stages, in which marked deformity is present, osteotomy provides the quickest and most certain line of treatment. Adams's osteotomy through the neck of the femur is difficult in these cases, owing to thickening and sclerosis of the bone, and presents the further objection that it is performed through the hip joint. Gant's method of subtrochanteric osteotomy is therefore usually adopted, and may be performed either through a stab wound, or a larger incision may be made in order to allow separation of the periosteum from the femoral shaft prior to division of the bone. The adductor muscles are forcibly stretched, or if necessary divided through an open wound which permits of free division and avoids injury to the saphenous vein and femoral vessels. Weight extension in abduction is then applied for six or eight weeks, after which a plaster or walking calliper is provided.

Genu Valgum.—Knock-knee is due to :

(i) General disease of bone, such as rickets.

(ii) Local disease of bone, as in cases of acute osteomyelitis with irregular epiphyseal growth.

(iii) Static, which is often associated with flat-feet or scoliosis. The normal angle at which the femur meets the tibia causes a great proportion of weight to be transmitted through the outer condyle and tuberosity. This causes a strain on the inner side of the knee joint, and explains why the internal lateral ligament is attached to the shaft of the tibia rather than to the epiphysis. When influences which predispose to a static deformity are in operation (*vide* scoliosis), the internal lateral ligament stretches, the outer condyle becomes atrophic from excessive transmission of weight, while the inner condyle increases in size, and thus knock-knee follows. No enlargement of the inner condyle occurs in the antero-posterior direction, and thus the deformity disappears when the knee is flexed. In advanced cases outward dislocation of the patella sometimes occurs.

Treatment.—Any predisposing cause receives adequate treatment, and in early rachitic or static cases improvement follows without any local treatment. In later cases massage and splinting are necessary, the splints reaching along the outer sides of the leg from the axilla or waist to the external malleolus. It is inadvisable to apply splints so as to keep the child completely off its legs, as thereby the circulation and consequent nutrition of the limb are adversely affected.

If the condition is advanced to such an extent, and the age of the child precludes hope of adequate improvement by conservative methods, (e.g. four years and upwards), then osteotomy should be considered on the appropriate bone. Thus, if deformity disappears on flexion of the knees, the femur is the seat of the disability ; however, unless marked deformity exists in the tibia, osteotomy of the femur gives satisfactory results, but if the tibia is mainly at fault (which is rare), it must be divided just below the patellar tubercle.

Operation.—The leg is flexed, and lies on its outer side supported by a sand-bag. A point is selected ½ in. in front of and above the adductor tubercle, and at this point a vertical stab wound is made to the bone with a broad-bladed scalpel. If gross deformity exists these measurements do not ensure the safety of the outer part of the

very oblique epiphyseal line, and in such cases the stab wound is made at the intersection of two lines—a vertical line ½ in. in front of the adductor tubercle, i.e. over the shaft of the femur, and a transverse line ½ in. above the upper limit of the external condyle, which indicates the outer extermity of the epiphyseal line. An osteotome is inserted in the wound, passed down to the bone, and then rotated through a right angle. The dense posterior part of the bone is first divided, then the anterior, and after division of part of the intermediate portion the remainder is fractured. Bleeding may occur from the anastomotica magna artery, but is controlled by a firm bandage. Injury to the popliteal artery has occurred from omitting to keep the ulnar side of the hand which grasps the osteotome resting on the limb. In the event of this rare complication the damaged first part of the popliteal artery (or lower part of the superficial femoral) must be exposed, and the divided ends sutured or ligatured. After division of the bone the limb is splinted for ten days, i.e. until the wound has healed, and swelling due to extravasated blood has disappeared. A plaster casing is then applied to the limb in its corrected position for about six weeks, after which a walking calliper is worn for a few months.

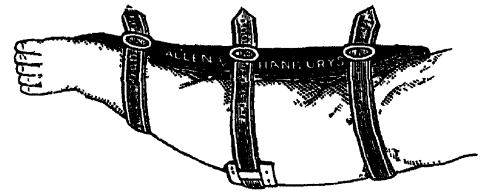

FIG. 710.—Splint applied to correct a bow-leg.

Curvature of the Tibia.—This is due to either :

(i) Weakening and consequent bending of the bone.

(ii) Change in its shape owing to deposition of new bone on its anterior aspect.

The first group includes such diseases as osteitis deformans, osteomalacia, and rickets. The treatment of a rachitic tibia is first constitutional, combined, if necessary, with suitable splints (fig. 710). If the deformity is marked and little improvement results, then manual osteoclasis is performed before the age of 5 years, i.e. while the bone is still comparatively soft. This simple operation consists in holding the leg, resting on its outer side, over a rubber-covered wedge (fig. 711). Pressure, gradually increased, first snaps the fibula and then the tibia. Care must



FIG. 711.

be taken to grasp the leg as close to the site of curvature as possible, as pressure near the end of the bone may wrench off the lower epiphysis of the tibia. A subperiosteal fracture occurs, and the straightened limb is put in a plaster case for about a month, union readily occurring. In older children with considerable deformity, open osteotomy, either linear or cuneiform, is necessary.

Curvature of the tibia due to deposition of bone is commonly due to syphilis, either congenital or acquired. The deformity is only antero-posterior, and chiefly occurs at the centre of the bone (*vide* Syphilis of Bones).

Flat-foot.—The inner longitudinal arch of the foot, which extends from the inner tuberosity of the os calcis to the head of the first metatarsal bone, is supported and maintained as follows :

(i) By the plantar fascia and short muscles of the foot, which act as somewhat weak "tie beams," connecting the ends and component parts of the arch.

(ii) By ligaments, particularly the long and short plantar ligaments (calcaneo-cuboid), and the spring ligament (inferior calcaneo-scaphoid), which supports the head of the astragalus, and in some cases is responsible for a facet on the under surface of that bone.

(iii) By tendons, particularly the tendon of the tibialis posticus, which is attached to all the tarsal bones, excepting the astragalus, and also to the middle three metatarsals.

(iv) By reciprocal modelling of the tarsal bones, which by their shape encourage the formation and maintenance of an arch.

The outer longitudinal arch is very shallow, and is normally in apposition with the ground when walking. The transverse arch owes its existence to the two longitudinal arches, and varies in prominence with the height of the instep. As the inner longitudinal arch sinks, so the transverse arch disappears. Interosseous ligaments and the tendon of the peroneus longus form the main supports of this arch.

Flat-foot is due to the following causes :

1. *Congenital.*—At birth the neck of the astragalus deviates inwards from the axis of the body to an extent of 30°, which accounts for the apparent varus deformity in a new-born child. As the child grows, the angle of deviation diminishes, but any diminution of this normal angle predisposes to flat-foot.

2. *Acquired.*—(i) *Static.*—This is the commonest cause, and is often associated with other static deformities, e.g. genu valgum or scoliosis. The factors contributing to a static deformity have been mentioned (*vide* Scoliosis). A similar condition is frequently seen in females at the menopause, due to increase in weight and decrease of muscular tone.

The patient complains of weakness and fatigue, these sensations being experienced in the sole and calf, and being more marked during and after exertion. As the arch sinks pain is felt across the dorsum of the foot, and later, as extension occurs, the external malleolus comes into contact with the outer side of the os calcis and causes local pain at the site of pressure. Finally, osteoarthritic changes occur in the tarsal joints, but when the arch has completely collapsed, pain diminishes and the gait becomes shuffling.

(ii) *Traumatic.*—Injury to any structures which form or maintain the inner longitudinal arch, or which cause eversion of the foot, is liable to result in flat-foot. Thus a fall on to the foot sometimes ruptures the spring ligament or fractures the sustentaculum tali, or a car in passing over the foot may fracture the first (or other) metatarsal bones. Flat-foot is, unfortunately, a common sequela of Pott's fracture, due to incomplete reduction, or non-maintenance of inversion during union.

(iii) *Inflammatory.*—Disease of the bones which form the arch sometimes results in partial collapse, e.g. tuberculous disease of the scaphoid. Softening of ligaments due to periarticular gonococcal arthritis predisposes to flat-foot unless temporary supports are worn, or walking curtailed.

(iv) *Paralytic.*—Paralysis of the flexor muscles of the leg, particularly the tibialis posticus, or of the intrinsic muscles

of the foot, predisposes to flat-foot by weakening a normal method of support.

(v) *Spastic.*—Spasm of the peroneal muscles is not uncommon, and usually occurs during adolescence. Eversion of the anterior part of the foot follows, and the contracted peroneal tendons are visible beneath the skin behind the external malleolus. The spasm disappears under anæsthesia.

Treatment.—In the case of static flat-foot, treatment depends upon the stage to which the condition has advanced.

Stage 1.—The deformity can be corrected by the patient; thus standing on the toes with the feet inverted restores the arch by the pull of the posterior tibial muscles.

Treatment of this stage consists in general treatment for debility, combined with adequate rest and suitable graduated exercises, the simplest being toe-raising on inverted feet, which strengthens the short muscles of the sole. Electrical treatment further stimulates weakened muscles. Boots or shoes must be low-heeled and not pointed. The heel should be prolonged on the inner side to support the arch, and the inner border of the sole raised ¼ in. in order to throw the weight of the body on to the outer side of the foot. If, for economic reasons, the patient is precluded from following this line of treatment, more substantial support is given to prevent further collapse, e.g. boots as above, combined with valgus pads.

Stage 2.—This stage can be corrected by the surgeon, who, while the leg is flexed, can forcibly invert the foot and restore the arch Treatment is carried out on the above lines, the arch being supported by adjustments to the boot, or valgus pads, but in severe cases, or when, owing to economic reasons, the ideal treatment must be modified, a surgical boot should be worn with an outside steel support and a valgus T-strap.

Stage 3.—If neither the patient nor the surgeon can correct the deformity, wrenching under an anæsthetic can be employed, the foot being encased in plaster in an over-corrected position, and the patient should wear a walking

instrument continuously. The instrument consists of lateral irons to the knee, with a valgus T-strap, a surgical boot with the heel prolonged, and a valgus pad. In cases in which the patient is unwilling to be so encumbered, or in which pain persists from osteoarthritis of tarsal joints, Dunn's arthrodesis is performed, in which the scaphoid bone is removed and the mid-tarsal joint is arthrodesed.

Cases of flat-foot, other than static, are dealt with according to the cause of the condition. Thus spastic flat-foot is wrenched under anæsthesia, so as to stretch the peroneal muscles, and the foot put up in plaster in the over-corrected position. Traumatic flat-foot should be prevented by anticipatory measures, but if the condition has occurred following a Pott's fracture, reconstruction of the fracture is sometimes advisable.

Talipes.—Is either congenital or acquired.

1. *Congenital.*—Is rarely due to absence of one of the bones of the leg. More commonly it is associated with spina bifida, in which case it is bilateral. If no cause can be found, malposition *in utero* or a deficient amount of liquor amnii are possible explanations.

2. *Acquired.*—Talipes of the acquired variety is due to unbalanced muscular action, or the influence of gravity, particularly if prolonged or acting upon weakened muscles. The actual causes may be :

(i) Paralytic, such as infantile paralysis or injury to peripheral nerves.

(ii) Spastic, due to upper motor neurone lesions, especially spastic paraplegia or syringo-myelia.

(iii) Compensatory, e.g. equinus, owing to shortening of the affected leg.

(iv) Muscular contractions, as with myositis fibrosa, or infective myositis of the calf muscles.

(v) Postural, such as talipes decubitus from prolonged confinement to bed.

The four primary varieties of talipes are as follows :

Talipes equinus, or plantar flexion, the patient walking on the toes.

Talipes calcaneus, or dorsiflexion, the patient walking on the heel.

Talipes valgus, produced by abduction and eversion of the anterior part of the foot.

Talipes varus, in which the anterior part of the foot is abducted and inverted.

Usually mixed forms of talipes occur, talipes equino-varus being the commonest.

In comparing the clinical features of talipes due to congenital causes, and the acquired variety which follows infantile paralysis, the following distinctions are found :

Congenital	*Acquired*
1. From birth.	Born healthy.
2. Often bilateral.	Usually unilateral.
3. No trophic changes ; therefore :	Trophic changes present ; therefore :
(*a*) Skin healthy.	(*a*) Skin may be ulcerated.
(*b*) Subcutaneous fat present with creases in soles.	(*b*) Subcutaneous fat and creases disappear.
(*c*) Circulation good and limb warm.	(*c*) Circulation poor, limb blue and cold.
(*d*) Muscles little wasted and electrical reactions present.	(*d*) Marked wasting and reactions much impaired.
(*e*) Bones unaffected in length.	(*e*) Growth deficient.

Treatment.—*Congenital.*—Treatment is adopted according to the lines already suggested for any congenital deformity, and intelligence, combined with patience, often yields surprisingly good results.

(*a*) *Manipulation.*—As soon as the affected part is born regular manipulation should be carried out in order to correct the deformity, and in slight cases this may be sufficient to cure the condition.

(*b*) *Manipulation and Retentive Apparatus.*—Tin night shoes, malleable splints, etc., are worn and removed as often as necessary to allow manipulation to be applied.

Repeated plasters and wedging often yield excellent results.

If a dual deformity is present, such as talipes equino-varus, the foot should first be brought in line with the leg so that dorsi-flexion of the foot will exert the maximum pull on the contracted tendo Achilles. Hence the varus deformity is first corrected, after which the plantar flexion is overcome by manipulation and suitable splints.

(*c*) *Anæsthesia and Forcible Correction.*—Manipulation is forcibly applied manually, or by some mechanical contrivance, e.g. a Thomas's wrench, in which case the site of application of force is protected by a bandage or a towel. After forcible correction, or over-correction, a plaster of Paris casing, or some suitable apparatus, is applied.

(*d*) *Operations on Soft Parts.*—Portions of fascia or ligaments are excised, or tendons are divided or lengthened. Thus in a case of equino-varus, tenotomy of the tibialis anticus (and possibly tibialis posticus) is performed, after which the tendo Achilles is lengthened.

(*e*) *Operations on Joints.*—Joints are excised, or arthrodesis performed. Whitman's operation yields good results in old-standing or neglected cases of talipes, notably in cases of calcaneo-valgus. The operation consists in removal of the astragalus and displacement of the foot backwards, so that the external and internal malleoli are in contact with the outer side of the os calcis and sustentaculum tali respectively. Owing to backward projection of the heel, a specially constructed boot is subsequently necessary.

(*f*) *Operations on Bones.*—Osteotomy, tarsectomy, or even amputation are sometimes necessary. Thus in cases of advanced equino-varus a cuneiform tarsectomy is performed, a wedge of bone being removed with an osteotome, irrespective of joints, the base being on the outer side of the foot.

Infantile Paralysis.—This condition occurs most commonly in the summer months. The responsible organism is ultra-microscopic, passes through a porcelain filter, and can be transmitted to apes. The infection commences in the nose, and passes through the cribriform plate along the olfactory nerves, causing a meningeal reaction, the

cerebro-spinal fluid being under pressure and containing an excess of cells and albumen. The anterior horn cells in the cord are then attacked and the corresponding muscles are paralysed. Anterior poliomyelitis is a notifiable disease, and may be transmitted by the nasal secretion of "carriers."

The disease can be divided in three stages :

(*a*) *Stage of Invasion.*—The onset is usually sudden, and is characterised by a rise of temperature, pain in the head and spine, and usually more or less widespread cutaneous hyperæsthesia. Head retraction and muscular spasticity are frequently present. Paralysis is usually evident after five or six days, and the true nature of the condition is frequently unsuspected until the paralysis is discovered. The commonest muscles to be affected are those below the knee, but if the arm is involved the muscles above the elbow and of the shoulder girdle (particularly the pectorals) are most commonly paralysed. Spinal and abdominal muscles are occasionally affected, the former leading to scoliosis and the latter predisposing to the formation of herniæ. Paralysis is very variable in extent and distribution ; in severe cases the bulk of the skeletal muscles are initially affected, while in others merely one or two isolated muscle groups suffer.

(*b*) *Stage of Recovery.*—This stage commences with the cessation of paralysis, and is most marked during the ensuing two years, although improvement often continues to an appreciable degree for many subsequent years.

Response to galvanic stimulation first returns, and while this reaction of degeneration is present, complete recovery is a possibility. Continued recovery is indicated by response to faradic stimulation, and finally by voluntary movements.

(*c*) *Stationary Stage.*—This is reached approximately after a period of two years, but it must be remembered that further slight improvement is probable.

Treatment.—(*a*) *Stage of Paralysis.*—Symptomatic treatment is all that can be attempted. Diaphoretics and sedatives are given, and the affected limb or trunk is wrapped in cotton-wool and immobilised. Local treatment, such as massage or electricity, is harmful, in that the affected

muscles require absolute rest. Lumbar puncture is indicated if meningeal irritation persists, and withdrawal of fluid under pressure gives relief. Serum therapy has been tried, but the results are disappointing.

(*b*) *Stage of Recovery.*—During this period three principles of treatment must be observed :

(i) Relaxation of paralysed muscles. If paralysed muscles are allowed to become stretched, as by the pull of healthy antagonistic muscles or by the influence of gravity, any subsequent recovery of tone is neutralised by the "slack" which has been allowed to develop. Therefore splints, surgical boots, and other forms of apparatus must be worn constantly to prevent over-stretching of affected muscles.

(ii) Maintenance of nutrition. Massage, electrical baths, radiant heat, are all useful in stimulating the circulation and improving nutrition. Care must be taken that weak muscles are not over-stimulated, and that the limb is maintained in such a position as to relax affected muscles during treatment.

(iii) Exercise. As recovery occurs, active muscular contractions are encouraged, provided that the effort is well within the powers of the weakened muscle.

(*c*) *Stationary Stage.*—After a period of two years the value of the affected muscles can be assessed, although it should be remembered that some degree of improvement may still occur. The principle of treatment is to restore muscular balance, either by means of surgical apparatus or by operative procedures, which have the advantage that appliances can thus be discarded or simplified. If widespread paralysis exists arthrodesis of a flail joint is sometimes advantageous.

The following procedures may therefore be adopted :

(i) Tenotomy, which has little scope in the treatment of infantile paralysis, as muscles are already weakened and contraction of stronger muscles should have been prevented.

(ii) Tendon transplantation, by which means the action of a stronger muscle is transferred to a weaker group, or the direction of muscular pull is altered so as to overcome deformity. Implantation of a healthy tendon into a para-

lysed one yields disappointing results, as the paralysed portion gradually stretches.

The following principles should be considered in connection with tendon transplantation :

(*a*) If possible the tendon is selected from muscles with the same innervation as those affected, so that re-education is simplified.

(*b*) The detached tendon should be fixed to bone rather than implanted into a paralysed tendon.

(*c*) The path of the transplanted tendon should be as direct as possible.

(*d*) The limb must be relaxed before the tendon is fixed.

(iii) Tendon fixation has been used in order to assist in the fixation of a flail joint. Thus in the case of the ankle joint the selected tendon is fixed to the bone on either side of the joint in order to secure stabilisation. Results are disappointing, as paralysed tendons readily stretch when subjected to strain.

(iv) Arthrodesis is a useful procedure, in that it obviates the continued use of surgical apparatus devised to stabilise the joint. The operation consists in removal of the articular cartilage, and securing bony union between the bones which comprise the joint.

A rare sequela which may follow arthrodesis of the knee joint is fracture of the leg, usually through the lower third of the femur, owing to the length of rigid bone which extends from the hip to the ankle, and which is therefore subjected to severe strain in the case of minor accidents, such as stumbling.

(v) Amputation. This is sometimes necessary in the case of extensive paralysis associated with stunted growth and trophic ulceration. It may be combined with other procedures ; thus, in the case of gross paralysis of the leg, an arthrodesis of the knee and a Syme's amputation of the foot will provide the patient with a stable and adequately nourished lower extremity.

Pes cavus (*syn.* **claw-foot**) is due to an increased concavity of the arch of the foot, so that the instep is unduly high. It is sometimes associated with nervous diseases, e.g. Friedreich's ataxia, or arise as a compensatory condition in cases of talipes equinus. In many cases the condition occurs idiopathically, and a possible explanation is that it is due to a transient mild poliomyelitis affecting the extensors of the foot and toes.

Pes cavus is divided into three stages :

Stage 1.—An increase of normal arch is present. This can be remedied by the wearing of a metatarsal bar, which consists of leather about ⅓ in. in thickness, and is fixed obliquely across the sole of the boot just behind the heads of the metatarsal bones. The bar causes slight dorsiflexion, and tends to stretch the Achilles tendon. In long-standing cases, or if improvement is slow, then lengthening of the Achilles tendon should also be performed.

Stage 2.—The heads of the metatarsal bones, particularly the first, project into the sole of the foot, and hammer-toes develop. The deformity can be remedied by firm pressure on the sole of the foot, so that the heads of the metatarsal bones are raised, and hammer-toes straighten.

Treatment of this stage usually requires excision of the plantar fascia and lengthening of the Achilles tendon, and these procedures may be combined with slinging up the head of the first metatarsal by means of the extensor longus hallucis tendon, which is detached and passed through a hole drilled in the head of the metatarsal bone. The foot is maintained in its corrected position in a plaster of Paris case for one month.

Stage 3.—Permanent hammer-toes are present, and painful callosities develop over the heads of the metatarsals on the sole of the foot, and over the hammer-toes on the dorsum. Much pain and considerable crippling result, and walking is reduced to a painful limp.

When this stage is reached excision of the head and part of the shaft of all the metatarsals is necessary. The excision is performed through dorsal incisions, and toes can then be straightened. In the worst cases, amputation of the toes, including part of the metatarsals, and astragalectomy yield a serviceable foot.

Hallux Valgus.—Is usually due to the wearing of boots or shoes with pointed toes, and is thus met with more commonly in females and Hebrews. The deformity, which consists in adduction, or outward displacement, of the big toe, tends to be progressive, as the direction of pull of the extensor longus

hallucis tendon further increases the deformity when once outward displacement has occurred. The following conditions are often associated :

(i) Hammer-toe, owing to the misplaced big toe exerting pressure on the adjacent toes, especially the second toe.

(ii) A bunion, which is an inflamed adventitious bursa, developing over the prominent head of the first metatarsal bone as a result of pressure. Suppuration sometimes follows, and the big toe joint may be secondarily affected.



FIG. 712.—Application of leukoplast for hallux valgus.

(iii) Osteoarthritis of the big toe joint, owing to pressure, malalignment of the bones, etc. Severe pain results, varying with the weather, and X-rays frequently show osteophytic outgrowths.

Treatment consists, in the early stages, in wearing roomy boots with a straight inner border. New socks or stockings should be washed before being worn, so as to minimise their elastic properties, which otherwise tend to crowd the toes together. If the condition is established, the stocking should be constructed so that the big toe is separated from its neighbour, and a peg is introduced into the shoe so that it is maintained in its correct position. The application of leukoplast strapping is a simple and efficient method of overcoming early deformity (fig. 712).

In advanced cases part of the head of the first metatarsal is removed. A flap of skin is raised on the inner side over the prominent head, and sufficient bone is removed by means of an osteotome to allow correction of the deformity. Some surgeons mobilise the long extensor tendon of the big toe and stitch it over the inner side of the joint, so that contraction of the muscle will tend to draw the terminal phalanx inwards. The foot is carefully

bandaged so as not to compress the toes, and a pad of wool is inserted between the first and second digits. Passive movements are commenced within a few days, and walking is attempted as soon as possible in order to encourage the formation of a movable joint. Some surgeons remove the base of the proximal phalanx rather than the head of the metatarsal, so as to avoid interference with the arch of the foot.

Hammer-toe.—Consists in hyperextension of the first phalanx, flexion of the second, and either flexion or extension of the terminal phalanx. Callosities form over the bony prominences, and in long-standing cases adventitious bursæ develop. Fascia and ligaments become secondarily contracted.

Hammer-toes sometimes develop from overcrowding, either by small or pointed shoes, or as a result of hallux valgus. Pes cavus, as an associated condition, has already been mentioned.

Treatment consists in correcting any predisposing cause and wearing a corrective splint. If the deformity is established removal of the head of the proximal phalanx is necessary. This is accomplished through a lateral incision, so that the scar is protected from pressure. The adjacent toes are readily held aside by gauze bands, and the head of the phalanx is snipped off by means of fine bone forceps.

CHAPTER XXXIX

THE SKIN

Acute Infections

Boil (*syn.* Furuncle).—A boil is due to infection of a hair follicle or sebaceous gland ; the offending organism is most commonly staphylococcus aureus. A painful and indurated swelling appears which gradually extends. After two or three days the centre softens and a small slough is discharged with a bead of pus and in the large majority of cases the condition then subsides. A " blind boil " is a term applied to infection which subsides without suppuration.

Complications

(i) Cellulitis, which sometimes spreads extensively, especially in debilitated subjects.

(ii) Adenitis of the glands draining the affected part.

(iii) Secondary boils, due to infection of neighbouring hair follicles, or sebaceous glands.

Special Sites

A Stye (*syn.* Hordeolum) is due to infection of an eyelash follicle. Infection of perianal follicles and consequent suppuration are likely to result in a blind external fistula. Furunculosis of the external auditory meatus is extremely painful, as the skin is attached to the underlying cartilage, and swelling is accompanied by considerable tension.

Treatment consists in improving the general health of the patient, and boils are frequently an indication of overwork, worry, debility, or other undermining influences. If considered necessary a small incision is made into the indurated area. Should softening occur around a hair follicle, particularly an eyelash, removal of the hair allows the ready escape of pus. Vaccines are frequently useful, especially if

they are autogenous. Smearing the surrounding skin with a mild antiseptic ointment, such as dilute nitrate of mercury, discourages the development of secondary boils.

Carbuncle.—Is an infective gangrene of the subcutaneous tissues, and is also usually due to staphylococcal infection.

Carbuncles frequently occur on the nape of the neck, as in this situation the skin is coarse and ill-nourished, and in some cases abrasions caused by a stiff collar encourage invasion by organisms (fig. 713). Carbuncles are especially liable to occur in diabetic subjects, and the appearance of a carbuncle sometimes leads to the discovery of this disease. At the same time it must be remembered that a transient glycosuria occasionally results from a carbuncle.

FIG. 713.—A typical carbuncle of the neck.

The patient complains of tenderness and stiffness at the site of origin of the carbuncle. The subcutaneous tissues become painful and indurated, and the overlying skin is red. Gradual extension occurs, and after a few days areas of softening appear. The skin then gives way and thick pus and sloughs discharge. The condition sometimes extends widely, and fresh openings appear in the skin, and tend to coalesce with those previously formed (fig. 714).

Carbuncles on the cheeks and upper lip are particularly dangerous, owing to the risk of cavernous sinus thrombosis, via the facial and ophthalmic veins, or the deep facial vein and the pterygoid plexus (p. 104).

Treatment consists, in the first place, in improving the general resistance of the patient by means of tonics, stimulants, fresh air, heliotherapy, and vaccines. In the early stages the injection of one minim of carbolic acid at intervals around the indurated area tends to limit extension and may succeed in aborting the carbuncle. Painting the surround-

ing skin with tincture of iodine is alleged to produce hyperæmia and so raise the local resistance to infection.

A method recently introduced, which cuts short the extension of a carbuncle, consists of injection of blood round the periphery. Gas and oxygen are administered, and 20 c.c. of blood is withdrawn from the patient into a syringe containing 2 c.c. of 2 per cent. sodium citrate. The blood is injected at various points, each injection commencing in the subcutaneous tissue, and terminating in the necrotic area. In order to prevent auto-infection a clean needle should be used for each injection.

FIG. 714.—Extensive destruction of skin and subcutaneous tissue resulting from a carbuncle.

Boracic fomentations relieve pain, but when discharge is present care must be taken to protect surrounding skin with antiseptic lotion or ointment in order to prevent auto-inoculation, although multiple carbuncles are unusual.

If operation is deemed necessary total excision of the carbuncle is the method of choice. Under gas and oxygen anæsthesia an incision is made a quarter of an inch from the edge of the infected area, and carried down as far as the deep fascia. The diseased skin and infected subcutaneous tissue are cut away, and any adherent sloughs removed with a sharp spoon. A hot saline pack is pressed into the wound for a few

moments, and further oozing controlled by means of an ample dressing and a firm bandage. Some surgeons smear the wound with pure carbolic acid, which acts both as a hæmostatic and a bactericide.

Chronic Infections

Cutaneous Tuberculosis is commonly seen in the form of lupus vulgaris. This disease usually occurs between the

Fig. 715.—Lupus vulgaris, before and after treatment. (Dr. H. C. Semon's case.)

ages of 10 and 25, the face being the site of election for its commencement. One or more subcutaneous nodules appear, with congestion of the surrounding skin. On applying pressure with a glass tongue depressor the nodules are seen to be the colour of apple jelly. Induration spreads, and the skin is likely to ulcerate (fig. 715). The resulting ulcer tends to heal in one situation as it extends in another. The healed portion is covered with a thin layer of epithelium which is likely to re-ulcerate. The corresponding lymphatic glands are liable to become affected

by the secondary infection, or less commonly by tubercle bacilli. The mouth and nose are sometimes attacked, either primarily or by extension from the face. Infection of the nose is followed by necrosis of underlying cartilage.

Treatment is directed towards improving the general health of the patient.

Local treatment in the early stages consists in exposure of the affected part to some variety of intensified light. A Finsen or mercury vapour lamp gives good results in the absence of ulceration, but prolonged treatment is necessary. When the skin has broken down X-ray therapy is indicated, and extermination of the disease is sometimes hastened by curetting the ulcer or scraping out persistent nodules.

Lupus verrucosis is a tuberculous lesion of the skin, in which a circumscribed area becomes irregularly nodular and indurated. The corresponding lymphatic glands are frequently affected, and present the usual features of tuberculous glands. When the condition is very localised it resembles a wart, and the terms " anatomical tubercle " and " butcher's wart " have been applied. The most expeditious treatment is to excise the patch of affected skin and any lymphatic glands which are involved.

Bazin's disease (*syn.* erythema induratum) is probably a tuberculous condition which particularly affects adolescent girls. Symmetrical purplish nodules appear, especially on the calves, and gradually break down to form indolent ulcers, which leave in their wake pigmented scars. The condition slowly responds to rest and general treatment.

New-growths

Basal-cell carcinoma (*syn.* Rodent Ulcer) commences in the basal cells of the skin or in the cells of the sebaceous glands. It rarely occurs before middle-age, and is commoner in males. Over 90 per cent. commence above a line joining the ala of the nose and the tip of the ear, the commonest sites being the naso-labial fold and the periphery of the orbit (p. 120). At first the growth appears as a pearly nodule, with one or two venules on the surface. The epidermis is then eroded, and a small circular or oval ulcer appears. As the ulcer extends surrounding skin is destroyed and finally the deeper

FIG. 716.—An advanced stage of rodent ulcer.

tissues are invaded, and air sinuses or even the dura mater are exposed eventually (fig. 716).

A typical rodent ulcer presents the following features. The edge is raised or beaded but not everted, as is the case with an epithelioma (fig. 717). The floor is granular, and is occasionally covered by a thin layer of epithelium which extends over it from the adjacent margin. This attempt at healing is merely temporary. The base is less indurated than in the case of an epithelioma, but secondary infection adds to the degree of induration. Metastases do not occur, and lymphatic glands are only enlarged as a result of secondary infection.

Microscopic section reveals masses or columns of epithelial cells which tend to spread in a lateral direction rather than downward, as in a carcinoma. The cells vary in size and shape; usually the peripheral cells are columnar, and arranged in a more or less definite layer. The central cells are smaller and polyhedral, and although a few prickle cells are sometimes seen, cell nests are practically absent, owing to lack of keratinisation. Degeneration of central cells results in the formation of small cystic spaces.

FIG. 717.—Early rodent ulcer, showing the typical rolled and beaded edge.

TREATMENT.—Excision yields good results, but owing to the fact that most rodent ulcers occur on the face, this line of treatment is not often feasible. Should the lesion be situated on the trunk, limbs, or forehead, excision removes the ulcer in a satisfactory manner with little waste of time.

Formerly small ulcers or suspicious nodules were destroyed

by carbonic acid snow, but this method has been replaced by radium, which is also used for larger ulcers. Radium is commonly utilised in the form of a plaque, but radium needles are sometimes implanted into the base of the ulcer, and around the edge. Forty to eighty mgrm.-hours per square centimetre are required, depending on the depth of the ulcer.

X-rays also yield satisfactory results, but this method is generally reserved for cases in which bone or cartilage is invaded, as the rays penetrate to a greater depth than radium. In advanced cases surgical removal of part of the diseased tissue is advisable as an adjunct to radio-therapy.

Squamous-celled carcinoma (*syn.* Epithelioma) usually occurs on exposed surfaces, especially in men whose occu-



FIG. 718.—Squamous-celled carcinoma of the hand. The patient was a chemical worker.

pation entails contact with irritating substances, such as dyes or tar (fig. 718). Formerly, "chimney-sweeps' cancer" was not uncommon owing to soot lodging on the rugæ of the scrotum. Improved personal hygiene has almost exterminated the disease. Epithelioma occasionally develops on an old scar, especially if deficient in vitality or irritated by friction. Scars of old lupus are especially prone to malignant change, which is encouraged by the irritation of the otherwise remedial light or X-ray therapy.

An epithelioma which develops in a scar (*syn*. Marjolin's ulcer) presents the following characteristics :

(i) It grows slowly, as the scar is relatively avascular.

(ii) It is painless, as scar tissue contains no nerves.

(iii) Secondary deposits do not occur in the regional glands, as lymphatic vessels have been destroyed. When the ulcer eventually invades normal tissue surrounding the scar it extends at a normal rate, and lymphatic glands are liable to be involved.

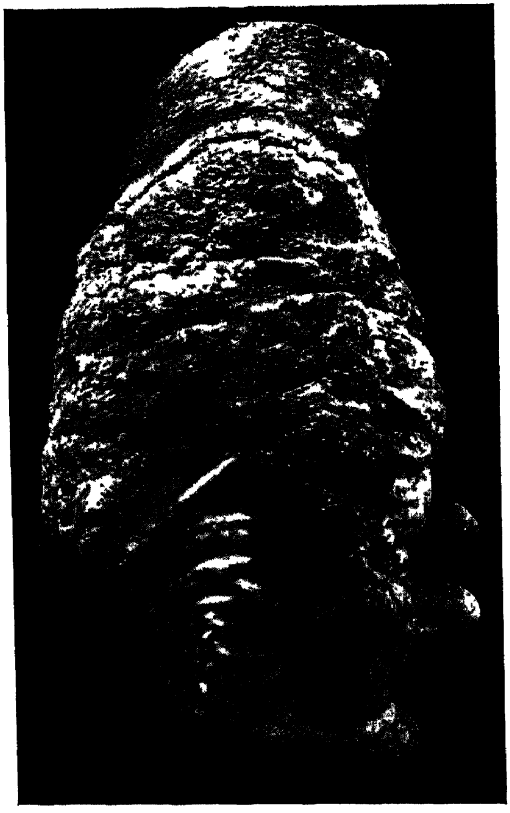

FIG. 719.—Extensive epithelioma of the hand.

A typical epithelomatous ulcer is irregular in outline, the edges are raised and everted (fig. 719). The base is indurated and sooner or later becomes attached to the deeper structures. A sanious discharge occurs, which is increased in amount with the advent of secondary infection. The regional glands are involved, and are liable to undergo mucoid degeneration, to which secondary infection is often added.

TREATMENT. — If the situation of the ulcer allows such a procedure, wide excision is indicated, the corresponding lymphatic glands being removed either at the same time or at a subsequent operation.

In situations where excision is likely to lead to deformity, such as the orbital region, radium yields excellent results. The regional lymphatic glands are removed if possible, but if fixed some degree of regression is obtained by the external application of radium in a Columbia paste collar.

Sebaceous Glands

Sebaceous adenomata arise in connection with a sebaceous gland or cyst. These are usually seen on the face or scalp, and occur as slowly growing, well-defined tumours, which are firm in consistency. They were formerly believed to be a precursor of rodent ulcer, but malignant changes are uncommon.

Removal is indicated if the adenoma is unsightly or troublesome, or increasing in size.

Sebaceous cysts follow obstruction to the mouth of a sebaceous duct, and are therefore retention cysts. They commonly occur on the face or scalp (p. 561), but can occur anywhere on the surface of the body, with the exception of the palms and soles.

A typical cyst appears as a hemispherical swelling, firm or elastic in consistency, and with no definite edge. It is more or less adherent to the skin, especially if it has been previously inflamed, or is subjected to pressure. The orifice of the obstructed duct can sometimes be seen on the summit of the cyst, and sebaceous material may be expressed from the duct. An uncomplicated cyst contains yellowish-white material composed of fat and epithelial cells, of a putty-like consistency.

Complications

(i) *Infection.*—The cyst becomes enlarged and painful, and the overlying skin is red. After a few days the inflammation usually subsides, but recurrence is the rule. Recurrent attacks of infection cause the cyst wall to become adherent to surrounding subcutaneous tissue, and consequently more difficult to remove. The contents of an infected cyst become semi-liquid and fœtid.

(ii) *Ulceration.*—An infected cyst occasionally breaks down and discharges its contents. A foul ulcerated surface remains, which in appearance somewhat resembles a carcinoma. The term "Cock's peculiar tumour" was formerly applied to a broken-down sebaceous cyst on the scalp.

(iii) *Sebaceous Horn.*—The contents of a cyst sometimes

slowly escape from the duct orifice and dry in successive layers on the adjacent skin. This "horn" is firmly attached at its base, and may grow several inches in length (fig. 720).

FIG. 720.—Sebaceous horn. (The owner, the widow Dimanche, was a watercress vendor in Paris.)

Removal of a sebaceous cyst is accomplished either by transfixion or dissection.

Transfixion is useful if the cyst is not adherent. Unless cysts are large or multiple a local anæsthetic is sufficient. A bistoury is pushed beneath the cyst so as to emerge on the opposite side (fig. 721). The cyst and overlying skin are then divided. The contents are expressed and the cyst wall seized with artery forceps and avulsed, assisted by a few touches of the knife if necessary.

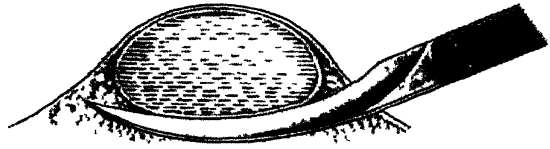

FIG. 721.—Transfixion of sebaceous cyst.

Dissection is necessary for cysts which have been previously inflamed or which are ulcerated. An incision is made over the cyst, the wall is defined, and if possible the cyst is dissected from adjacent tissue and removed intact. Unless the wall is completely removed recurrence is probable.

CHAPTER XL

INFECTIONS OF THE HAND

THIS last chapter is not the least in importance. Infections of the hand are still but improperly understood and, as a result, on the whole are badly treated. If even the few pages which follow are understood, digested, and remembered it is less likely that suppurative tenosynovitis will be left until the fascial spaces and even the arm are extensively infected; that incisions will be made into the œdematous dorsum when the pus lies in the palm; or that pulp infections by improper incision will be turned into suppurative tenosynovitis—all of which only too often have occurred in the past.

PARONYCHIA

Organisms gain entrance through a "hang-nail" and the tissues about the base of the nail become inflamed. Sup-



FIG. 722.—Incisions for turning back a flap for the treatment of paronychia. *a*. Paronychia, incisions for turning back the flap. *b*. A wisp of gauze soaked in paraffin is used to maintain elevation of the flap. *c*. When there is pus under the nail a portion (B) is removed and the portion (A) is retained.

puration follows frequently and in 63 per cent. of cases pus accumulates under the nail, as well as beneath the cuticle.

Prophylaxis.—The loose tag of skin should be cut off with scissors and the associated fissure sterilised with iodine and kept clean.

Treatment is early operation. Lateral incisions are made (fig. 722 *a* and *b*) and a flap is turned back. In order to keep the flap elevated a wisp of gauze soaked in paraffin is inserted. Hot saline dressings are applied to the whole finger for forty-eight hours, after which paraffin dressings are used until the wound granulates. In cases where there is pus under the nail the proximal (shaded) portion is removed (fig. 722 *c*). The distal part which remains acts as a protection to the sensitive quick until the new nail grows up, a process which takes at least two months.

Paronychia is a common and painful condition, but it is seldom serious.

Infection of the Terminal Pulp Compartment

The pulps of the fingers and thumbs are subjected to more pricks, and therefore infections, than any other part of the

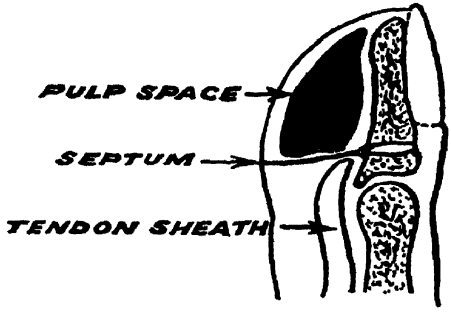

Fig. 723.—The boundaries of the pulp space.

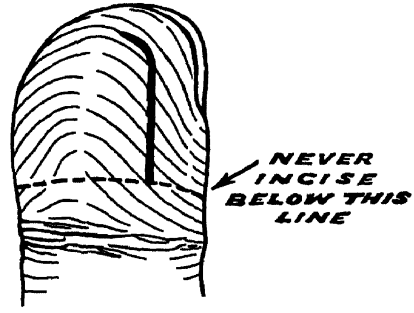

Fig. 724.—Incision for draining the pulp space.

body. Nature has provided in this situation a closed fascial compartment which extends from the tip of the digit to the level of the epiphyseal line of the terminal phalanx (fig. 723).

Clinical Features.—There is tenderness over the pulp and, later, swelling.

Treatment.—As soon as tender induration is present a deep hockey-shaped incision (fig. 724) is made into the pulp. *The incision must on no account extend in a proximal direction further than half an inch from the terminal flexor crease.* The

wound is irrigated each day with eusol, and hand baths and fomentations are instituted. Usually the diaphysis of the terminal phalanx is extruded as a sequestrum two or three weeks later and the dead bone is easily withdrawn, after which the wound soon heals. This leaves a shortened phalanx with rather an ugly curved nail, but with full function of the digit.

Paronychia and infections of the terminal pulp compartment together with boils on the dorsum of the hand and strictly limited superficial cellulitis are the only types of infected hand which should be treated in the Out-patient department or in the consulting-room. The more serious infections which we are about to consider must be admitted urgently and treated as major lesions.

SERIOUS INFECTIONS OF THE HAND

Grave infections of the hand fall into three categories :

1. Lymphangitis.
2. Suppurative tenosynovitis.
3. Fascial space infections.

Lymphangitis

Organisms, almost always streptococci, gain entrance through an abrasion, which may be minute. A portion of the hand immediately adjacent becomes swollen and painful, and there is often considerable elevation of the temperature. Later red streaks, so characteristic of lymphangitis, can be seen coursing up the arm. It is of cardinal importance to distinguish lymphangitis from suppurative tenosynovitis and fascial space infections. The latter require urgent operation, while in lymphangitis in its early stages incision is highly mischievous. Lymphangitis is discussed on p. 90.

Suppurative Tenosynovitis

The essential signs of an infected tendon sheath are :

1. Swelling of the finger.
2. Flexion of the finger with exquisite pain on extension.
3. Tenderness, maximally over the infected sheath (fig. 725).

When the ulnar and/or the radial bursæ are involved, in addition to tenderness over the individual sheaths there

is œdema of the whole hand, especially of the dorsum, and a fullness immediately above the anterior annular ligament. It should be noted that these two sheaths intercommunicate in a large percentage of cases, and only too often after an infection of one has been present for more than forty-eight hours the other becomes affected.

Treatment.—Early operation is imperative. An anæsthetic is administered; the arm is held up for three minutes. After a tourniquet has been applied suitable incisions are made to drain the infected sheath.

In the case of a digit an incision somewhat to one side of the middle line (fig. 726) is made. If there is much

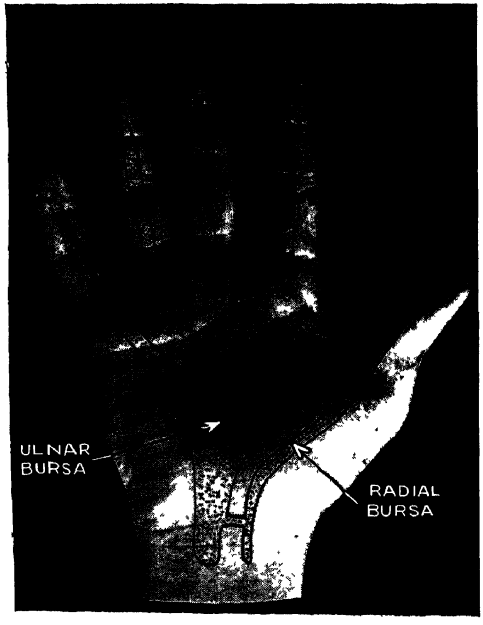

FIG. 725.—The arrangement of the flexor tendon sheaths.

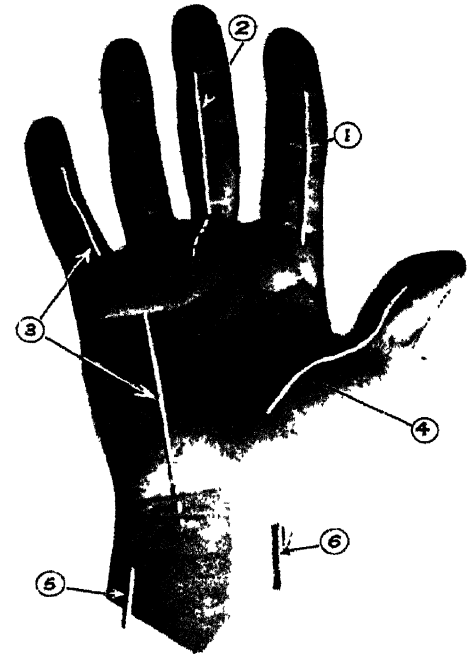

FIG. 726.

1. Usual incision for opening an infected tenon sheath.
2. When a lumbical canal is infected in addition the incision is prolonged into the appropriate web space.
3. Incisions for opening an infected ulnar bursa.
4. Incision for opening an infected radial bursa.
5. Incision for opening all infections of the forearm from the hand.
6. Counter-incision used in the case of infection of the forearm from the radial bursa.

œdema the incisions are joined. A slightly lateral incision tends to obviate prolapse of the tendon. In the case of the radial bursa the opening in the sheath is followed downwards through the thenar eminence to within a thumb's breadth of the anterior annular ligament, but no further, for the motor nerve to the thenar muscles crosses the sheath a little proximal to this point. When draining the ulnar bursa the incision passes through the radial side of the hypothenar eminence and can be prolonged through the anterior annular ligament (fig. 726).

Drainage of the Forearm in all Infections of the Forearm from the Hand.—When there is swelling above the anterior annular ligament or when, during an operation for radial or ulnar bursa, pus can be expressed by pressure over the wrist, the forearm must be drained in the following manner. The styloid process of the ulna is palpated and an incision is commenced 1½ in. above this point upon the flexor surface of the ulna passing right down to the periosteum. The incision is at least 2 in. long. A hæmostat is thrust across the flexor surface beneath the flexor tendons, and the jaws of the forceps are opened, after which the proximal extremity of the infected bursa is ruptured thoroughly into the space beneath the flexor tendons. In the case of a radial bursa infection a counter-incision is made at the radial side (fig. 726).

Fascial Space Infections

The Thenar Space

Boundaries (fig. 727).

Palmar Aspect.—The palmar fascia.

Dorsal Aspect.—The adductor transversus pollicis.



Fig. 727.—The boundaries of the thenar space.

Ulnar Aspect.—A septum of strong fascia attached to the middle metacarpal

bone. This septum separates the thenar from the middle palmar space.

Source of Infection.—The thenar space can be infected directly from a wound. Much more frequently, it is involved by bursting of an infected and untreated tenosynovitis of the index finger (fig. 727).

FIG. 728.—Incision for draining the thenar space.

Clinical Features.—There is ballooning of the thenar eminence. Flexion of the terminal interphalangeal joint is considerable, but it lacks the resistance to extension so characteristic of infection of the radial bursa.

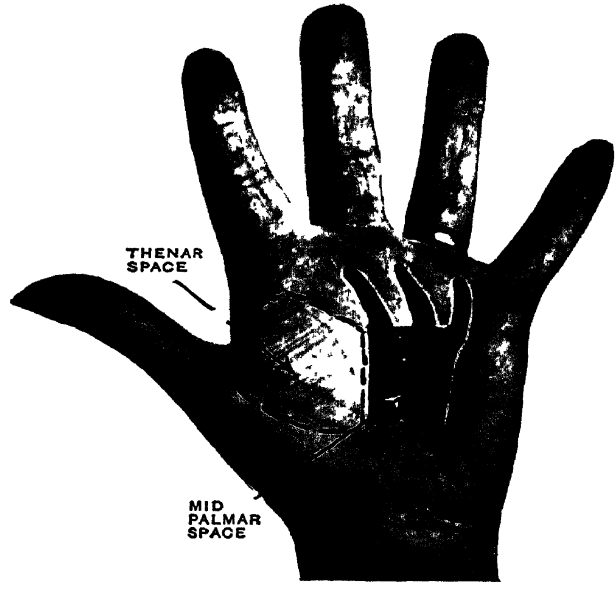

FIG. 729.—The thenar space and the middle palmar space with its three diverticula, the lumbrical canals.

Treatment.—An incision is made on the dorsum (fig. 728) and a hæmostat is passed into the space. This gives perfect

drainage. It is essential to drain the infected flexor sheath of the index finger, if infection is present.

Middle Palmar Space (fig. 729).

Boundaries.

Palmar Aspect.—Fascia separating it from the flexor tendons of the fingers and their lumbricals.

Dorsal Aspect.—Fibrous tissue separating it from the interosseous muscles.

Radial Aspect.—The fascial septum alluded to above separating it from the thenar space.

The middle palmar space has three diverticula which are the lumbrical canals. *It is overlapped on the ulnar side by the ulnar bursa, and therefore must never be incised directly*, otherwise the ulnar bursa will become infected.

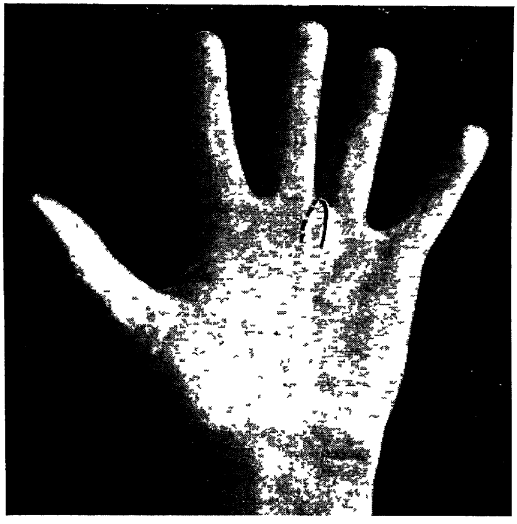

FIG. 730 —The middle palmar space is drained by splitting a web space and inserting a hæmostat downwards under the flexor tendon The middle palmar space must never be drained by a direct incision.

Source of Infection.—Sometimes the space is infected directly by penetrating wounds or from osteomyelitis of the ring or middle metacarpal bones. Usually the space becomes involved from rupture of an infected tendon sheath of the middle, ring, or little finger.

Clinical Features.—Infection of the middle palmar space gives rise to those enormous hands which have been likened to a whale's flapper. The concavity of the palm is obliterated. Obliteration of the concavity of the palm with slight bulging thereof is almost pathognomonic of a middle palmar space infection.

Treatment.—The space is drained through a web space, usually between the middle and ring fingers (fig. 730). A

closed hæmostat is inserted under the flexor tendon, and its edges opened widely. The necessity of treating the primary cause, if it is suppurative tenosynovitis, is again stressed.

AFTER-TREATMENT OF SERIOUS INFECTIONS OF THE HAND

Frequent arm-baths of hot saline are employed (fig. 731). During the intervals between the baths the hand should be splinted in slight hyperextension to prevent prolapse of tendons. At night hot magnesium sulphate fomentations are applied. When, as is often the case, after several days, the skin becomes sodden, dressings of glycerol, which is hygroscopic, are useful. If suppuration continues for more



FIG. 731.—Arm-bath for serious infections of the hand.

than fourteen days the hand should be X-rayed for evidence of bone necrosis. Lifeless tendon is a potent source of prolonged suppuration and much time will be saved by excising the diseased portion ; care being taken to anchor its proximal end by sutures to prevent the cut end being carried into the forearm by muscular contraction and thereby spreading infection. Massage and exercises form an important part of the late after-treatment. In the case of fingers it should be remembered that total amputation of a digit is better from every point of view than a stiff finger, but amputation should seldom be undertaken until the infection has abated. The surgeon's watchword for the thumb in all lacerations and infections is always " Save all possible."

INDEX

Abbot's jackets, use of, 903
Abdomen, acute, and acute osteomyelitis of ileum, differential diagnosis of, 795
  burst, 436
    complicating pancreatitis, 279
    following spleen removal, 240
    prophylaxis of, 436
    treatment of, 436
Abdominal wall, 435–439
    desmoid tumour of, 437
    fibroma of, ætiology and pathology of, 437
    infections of, 436
    injury to, 435
    neoplasms of, 437
    sarcoma of, 437
Abdomino-perineal operation for rectal carcinoma, 406
Abscess :
  acute, 2
    symptoms and signs, 3
    treatment of, 4
  alveolar, 106
    treatment of, 106
  amœbic, 252
  appendicular, 362
    treatment of, 369
  Brodie's, 3
  cerebral, acute, 575
    chronic, 578
    clinical features of, 576
    subacute, 576
    treatment of, 577
  collar-stud, 94, 152, 153
  DuBois, 183
  dysenteric, 252
  extradural, symptoms and treatment of, 574
  formation in Pott's disease, 618, 619, 621
  in diverticulitis, 321
  ischio-rectal, ætiology of, 385
    clinical features and treatment of, 385
    tuberculous, 385
  mammary, 678
  of abdominal wall, 436
  of liver, 251
Abscess (*cont.*) :
  of spleen, 241
  parapharyngeal, 192
  pelvi-rectal, 385
  pelvic, complicating peritonitis, 290
  peri-anal, 384
  perigastric, 221
  perinephric, 470
  perinephritic, 3
  peritonsillar, 191
  periurethral, bulbar, 524
    extravasation complicating, treatment of, 518
    penile, 524
  prostatic, 508
  pulmonary, 710
  retro-mammary, 679
  retropharyngeal, acute, 192
    chronic, 192
    in Pott's disease, treatment of, 192, 619, 621
  root, 107
  solitary, 252
  submucous of rectum, 384
  subphrenic, ætiology of, 292
    anatomy of, 291
    clinical features of, 293
    complicating peritonitis, 291
    differential diagnosis of, 294
    methods for investigation of, 294
    treatment of, operative, 295
      prophylactic, 294
  tropical, diagnosis from subphrenic, 294
  tuberculous, of mesentery, 306
Acetabulum, fractures of, 770
  travelling, 876
Achalasia of cardia, 203
Achondroplasia, 834
Acid, ammonium phosphate and ammonium chloride, as urinary antiseptic, 468
Acromegaly, 593, 835
  operation in, indications for, 835
Acromial tip, fracture of, 747
Acromico-clavicular joint, dislocation of, 840

Acromion process, fracture of, 750
Actinomycosis, 18
of liver, 255
of neck, 153
modes of spread and treatment, 154
of right iliac fossa, 371
sites of, abdomen, 20
facio-cervical, 19
thorax, 19
treatment of, 20
Adenitis, cervical, tuberculous, 151
differential diagnosis of, 151
complicating boils, 929
of facial lymph glands, 126
Adeno-carcinoma, 52
Adenoma, 48
basophil, Cushing's, 595
sebaceous, 937
toxic, 177
Adhesions causing intestinal obstruction, 340
colonic, in diverticulitis, 321
Adiposis dolorosa, causes of, 595
Aero-urethroscopy in diagnosis of strictures, 519
Air passages, foreign bodies in, 186
Albee's operation for Pott's disease, 623
Alveolus, tumours of, 110
Amazia, 674
Amputation in acute infective arthritis, 859
in acute infective osteomyelitis, indications for, 800
in aneurism, 81
in diabetic gangrene, spinal anæsthesia indicated, 65
in fractures, indications for, 740
in infantile paralysis, 925
in irremediable nerve injuries, 642
in periosteal sarcomata, 827
in senile gangrene, 64
in tuberculous arthritis, 875
stump, neuroma of, 51
Amyloid disease, 5
Anæmia, pernicious, 247
splenic, stages of, 241
treatment of, 242
Von Jaksch's, 243
treatment of, 244
Anæsthesia, choice of, for empyema operation, 701
in intestinal obstruction, 332
for sympathetic, 663
local, in fractures, 728
sacral, 634
spinal, 633
in diabetic gangrene, 65
Anæsthesia (*cont.*):
spinal, in intussusception in infants, 337
Anal canal and rectum, 373–407
fissure, clinical features of, 392
ætiology of, mucosal-stretching theory, 391
valve theory, 391
definition of, 391
sentinel pile in relation to, 391, 392, 393, 396
treatment of, by dilatation, 393
by division of sphincter and excision of fissure, 393
by injection, 393
verge, veins of, dilatation of, 396
Anatomical tubercle, 933
Anel's operation in aneurism, 80
Aneurisms, 78
arterio-venous, 82
cirsoid, 561
false, 82
of splenic artery, 240
true, 78
clinical features of, 78
differential diagnosis of, 79
natural termination of, 79
treatment of, 80
varicose, 82
Angina, Ludwig's, 149
Vincent's, 122
Angioma, cavernous, 88
plexiform, 89
Ankle-joint, dislocations of, 851
fractures of, 787
tuberculosis of, 877
Ankyloglossia, 134
Ankylosis, 885
bony, 886
false, 885
fibrous, 886
in tuberculous arthritis, 870
true, 886
true and false, complicating fracture, 735
Ano-proctitis, causes and treatment of, 381
Ano-rectal syphilis, 383
Anorchism, 539
Anosteoplasia, 834
Antero-latero tracts, division of, 631
Anthrax, 13
alimentary, 14
cutaneous, 13
of face, 119
differential diagnosis of, 119
incubation period of, 13
pulmonary, 14

Anthrax (*cont.*):
treatment of, 14
types of, 13
Antiseptics, intravenous, 8
urinary, 468
Antrum, growths of, 113
Anuria, calculus, 462
clinical features and treatment, 463
Anus, condylomata of, 383
gummata of, 383
imperforate, treatment of, 376
syphilis of, 383
Apicolysis, treatment of, 710
Appendicectomy, incisions for, 362
retrograde, 364
Appendicitis, acute, 347
ætiology of, 350
abuse of purgatives, 351
concretions and strictures, 351
familial susceptibility, 350
foreign bodies, 351
race and diet, 350
trauma, 351
worms, 351
atypical, 357
bacteriology of, 352
clinical features, 354
complications of, 362
conditions simulating, 358–362
differential diagnosis of, 358–362
erroneous diagnosis of, 358
pathology of, 352
proper, 352
pseudo, 358
treatment of, 362
appendicectomy, 362
drainage in, 364
immediate, 365
incisions for, 362
Ochsner-Sherren (delayed), 365
post-operative complications, 369
with diarrhœa, 357
with high temperature, 357
without abdominal rigidity, 358
causing gastric ulcer, 213
subphrenic abscess, 292
chronic, 370
recurrent, 369
subacute, 369
Appendicostomy in chronic ulcerative colitis, 315
Appendicular colic, 355
differential diagnosis of, 356
Appendicular obstruction, acute, 353
symptoms of, 355
Appendix, vermiform, 347–372
abscess of, 362
treatment of, 368
carcinoma of, true or false, 371
coats of, 348
diverticulosis of, 371
location of, 349
obstruction of, acute, 353. *See also* Appendicular obstruction.
positions of, 349
removal of, 363
size of, 347
surgical anatomy of, 347
tumours of, 371
vascular and lymphatic supply of, 348
Argentaffin tumour of appendix, 371
Arm, brawny, 692
Arteries, injuries of, 77
thyroid, superior, preliminary ligature of, 175
Artery, appendicular, culpability of, 351
splenic, aneurism of, 240
Arthritis, 2
acute, 2, 861
and acute infective osteomyelitis, differential diagnosis, 794
infective, 856
clinical features, 857
position of ease in, 857
treatment, 858
chronic plastic, 861
deformans, 880
gonococcal, treatment, 861
types, 860, 861
in typhoid, 317
periarticular, 861
subacute polyarticular, 861
tuberculous, clinical features, 867
prognosis, factors influencing, 869
results of, 870
treatment of, conservative, 871
general, 871
local, 871
operations for, 874
operative, indications, 872, 873
types of, 867
Arthrectomy in tuberculous arthritis, 874
Arthrodesis in infantile paralysis, 925
in injury of sciatic nerve, 642

Arthrotomy and closure in acute infective arthritis, 858
and drainage in acute infective arthritis, 859
in tuberculous arthritis, 874
Artificial pneumothorax, technique of, 707
Ascaris vermicularis causing anoproctitis, treatment of, 382
Ascites, causes of, 299
differential diagnosis of, 299
tapping of, points of puncture, 300
types of, 299
Ascitic tuberculous peritonitis, 297, 299
Aspermia, 553
Asphyxia, traumatic, 697
Aspiration and irrigation in acute infective arthritis, 858
in acute infective arthritis, 858
in empyema, 700, 701
in tropical liver abscess, 254
Asthenia, pancreatic, 279
Asthma, thymic, 183
Astragalus, dislocations of, 851
fractures of, 790
Auricle, cervical, 156
Autohæmotherapy in carbuncle, 931
Axilla, injury of musculo spiral nerve in, causes of, 655
Azoospermia, 553

Bacilluria, 467
Bacillus anthracis, 13
coli, 2, 352, 497, 508
pyocyaneus, 2
sporogenes, 66
tetani, 15
typhosus, 2, 241
Welchii, 66, 331, 352
Bacteræmia, 8
Baker's cysts, 47, 881, 883
Balanitis, acute and chronic, 528
Balfour's operation for gastric ulcer, 217
Balkan beam, use of, 780
Ballance's sign in ruptured spleen, 238
Bandages, elastoplast, in varicose ulceration, 86
Bands causing intestinal obstruction, 340
Bankhart's incision in cervical rib, 160
Banti's disease, 241
ascites in, 299
Barium meal in diagnosis of gastric ulcer, 214, 215
of gastroptosis, 228
Barium meal (*cont.*):
in diagnosis of œsophageal stricture, 197
of ulcerative colitis, 315
Baseball finger, 889
Basophile cell, 71
Bassini's principle in herniorrhaphy, 416
Battle's incision for appendicectomy, 363
Bazin's disease, 933
Bed-sores, 67
in spinal cord injury, 604, 606, 609
Benda's test in acute pancreatitis, 276
Bendien test for cancer, 53
van den Bergh, reaction in carcinoma of head of pancreas, 284
Bile ducts, abnormalities of, congenital, 263
absence or obliteration of, 263
and gall bladder, 263–284
common, carcinoma of, 284
obstruction of, chronic pancreatitis with, 281
reconstruction of, 275
stones in, 270
cysts of congenital, 263
rupture of, 263
Bilharzia of rectum, 382
papilloma, 499
Billingsgate hump, 896
Billroth operations No. 1 and No. 2 for gastric ulcer, 218
Bismuth in syphilis, 29
Black eye, diagnosis from fracture of anterior fossa extending to orbit, 572
Bladder and prostate, 481–510
calculus, 492
carcinoma, 499
varieties and treatment, 499, 500
decompression by Kidd's **U**-tube, 482
diverticula of, ætiology and pathology, 487
complications and treatment, 488
in relation to femoral hernia, 421
effects of prostatic enlargement on, 501
foreign bodies in, 495
Hunner's ulcer of, 497
inflammation of, 495
neck of, contracture, 506
neoplasms, 498
pain, 440

Bladder (*cont.*) :
pain in, presacral neurectomy in, 666
papilloma, 498
bilharzia, 499
malignant, 499
treatment, 499
rupture of, ætiology, 490
prognosis of, 492
treatment, 492
sacculation of, 501, 502
" thimble," 497
trabeculation of, 501
ulcer of, carcinomatous, 499
submucous, 497
Blair's operation in acute parotitis, 139
Blastomata, 40
Blaxland's sign in differential diagnosis of ascites, 299
Blood and blood-vessels, 71–89
bacteriology of, 73
cells, 72
changes in, following splenectomy, 237
chemical constituents, 72
chemistry of, in urinary investigation, 442
coagulation time, 73
colour index, 71, 73
count in hydatid disease of liver, 257
in subphrenic abscess, 294
Schilling's, 72
cytology of, in disease, 72
diseases of, and lymphatic enlargement, 96
groups, 73
normal constituents of, 71
platelets, 71, 73
count, normal, 247
serology of, 73
sugar, 73
transfusion, 73
cross-matching, 74
in acute gastric ulcer, 213
in splenic anæmia, 243
in von Jaksch's anæmia, 244
methods of, 74
technique of grouping, 74
urea, 73
Bloxam's cradle, use of, 785
Boas's sign in gall-stones, 270
Bohler's method of treating fractures, 730
redresseur, use of, 790
Boils, 1, 67, 929
complications of, 929
of face, 119
Boils (*cont.*) :
special sites of, 929
Bone-grafting in Pott's disease, indications for, 623
marrow, changes in, following splenectomy, 237
Bone, portion of, in knee joint, in internal derangement, 855, 884
Bones, contusion of, 724
cysts of, 814
diseases of, 792–836
Calve's epiphysitis, 833
inflammation, 792
Keinboch's disease, 832
Kohler's disease, 832
leontiasis ossea, 816
Madelung's disease, 833
Osgood's disease, 832
osteitis deformans, 810
osteitis fibrosa, 813
osteochondritis juvenalis, 830
osteogenesis imperfecta, 817
osteomalacia, 815
Perthes's disease, 831
Schlatter's disease, 832
syphilitic, acquired, 803
congenital, 801
tuberculous, 805
treatment, 806
fractures of, 724. *See also* Fractures *and under names of bones.*
generalised fibrocystic disease of, 724
injuries to, 724–791
long, bending of, in rickets, 808
metastases in, 829
secondary deposits in, situation in relation to primary growth, 829
tumours of, chondroma, 817
classification of, 817
ecchondroma, 818
enchondromata, 817
myeloma, 820
treatment, 822
white, 822
osteoma, ivory and cancellous, 819
sarcoma, 824
prognosis, 829
treatment, 827
secondary, carcinoma, 829
Bougies, English, 520
filiform, 521
French, 520
gum-elastic, 520
Brachial plexus :
lesions of, complete, 651
incomplete, 651

Brachial plexus (*cont.*):
lesions of, treatment of, 653
operative, 652
lower, lesions of, 652
upper, lesions of, 652
Brain and membranes, inflammatory conditions of, 574
cysts of, treatment of, 591
embolism of, 83
glioma of, 586
gliomatous cyst of, 586
gumma of, 586
injuries of, compression, 580
concussion, 578
irritation of, causes and treatment of, 584, 585
tumours of, 586
secondary, 586. *See also* Cerebral tumours.
Branchial:
apparatus, anomalies of, 155
cartilage, 156
cyst, 156
and tuberculous cervical adenitis, differential diagnosis of, 152
fistula, 155
fluid, 157
Branchiogenetic carcinoma, 157, 162
Brasdor's operation in aneurism, 81
Brawny arm, 692
Breast, 672–696
abnormalities, congenital, 674
abscess, 678
accessory, 674
amputation of, complete, 693
carcinoma, 685
atrophic scirrhus, 686
colloid, 686
duct, 690
encephaloid, 689
intracystic papilliferous, 690
metastases in, 693
phenomena resulting from lymphatic obstruction, 692
relationship of chronic interstitial mastitis to, 682
scirrhus, 687
macroscopical characters, 688
secondary deposits in, 829
spread of, 693
treatment of, by radium, 695
operative, 693
results, 695
varieties, clinical classification, 686
cyst adenoma of, 684
cysts, 680
duct papilloma, 684
Breast (*cont.*):
fibroadenoma, 684
hæmatoma, 675
hypertrophy of, diffuse, 675
inflammation of, acute and subacute, 672
injuries, 675
mastitis carcinomatosis, 689
milk fistula, 675
neoplasms of, benign, 684
sarcoma, 696
syphilis, 680
traumatic fat necrosis, 675
tuberculous, 679
tumours of, benign, 684
massive, 685
Bright's disease, surgical treatment, 474
Brodie, sero-cystic disease of, 684
Bronchiectasis, causes and clinical features of, 712, 713
treatment of, by artificial pneumothorax, 714
by lobectomy, 714
by phrenic evulsion, 714
by thoracoplasty, 714
Bronchus, carcinoma of, 716
secondary deposits in, 829
Brophy's operation for cleft-palate, 101
Brown's method in treatment of intussusception, 339
Bryant's triangle, 773, 774
Bubo, 530
Buerger's disease, lumbar ganglionectomy in, 664
Bunion, 896, 927
Burns and scalds, 69
Curling's ulcer following, 235
Bursæ diseases, 895
injury, 895
new-growths, 897
olecranon, 895
popliteal, 896
prepatellar, 895
pretubercular, 895
tuber ischii, 895
under tendon of Achilles, 895
Bursitis, acute infective, 896
acute non-infective, trauma in, 895
chronic, 895
chronic infective, 896
gummatous, 897
subdeltoid, 895
syphilitic, 897
tuberculous, 896
Butcher's wart, 933
Butlin's laryngotomy tube, 185
operation, 129, 130

Cæcoptosis, 314
Cæcum, carcinoma of, 328
failure of descent of, 309
intussusception of, 335
tuberculosis of, diagnosis from intussusception, 337
hyperplastic, 318
volvulus of, 339
Calculus, anuria, 462
gall bladder, 267
pancreatic, 280
parotid, 141
prostatic, clinical features and treatment, 509, 510
renal, ætiology and clinical features, 459
complications of, 462
quiescent, 459
treatment, 461
varieties, 457
salivary, composition, 139
submaxillary, 139
clinical features, 140
treatment of, 141
ureteric, clinical features, 464
treatment of, operative, 465
urethral, 524
vesical, clinical features, 493
diagnosis and treatment, 494
Callaway's test for shoulder dislocation, 842
Calve's epiphysitis, 833
Cammidge reaction in chronic pancreatitis, 282
Cancer. *See* Carcinoma *and under names of organs and regions.*
Cancer en cuirasse, 692
Cancrum oris et noma, 67, 123
Canny Ryall's cystoscopic lithotrite, 494
Cantlie's method of treating tropical liver abscess, 254
Carbolic acid causing gangrene, 68
Carbuncles, 1, 67
of face, 119
of kidney, 469
of lip, 104
sites of, 930
treatment of, 930
autohæmotherapy, 931
operative, 931
Carcinoma, 51
basal-celled, 53, 120, 933
biochemical diagnosis of, 53
chimney-sweeps', 935
classification of, 52
colloid, 52
glandular, adeno-carcinoma, 52
alveolar, 52
Carcinoma (*cont.*):
glandular, colloid, 52
types of, 52
papilliferous, causing intussusception, 337
squamous, 53
See also under names of organs and regions.
Cardia, achalasia of, 203
carcinoma of, 233
Cardiospasm, clinical features, 203
treatment, 204
Caries, dental, 106
sicca, 867
Carotid body, tumour of, 162
Carpal bones, dislocation of, 846
fracture of, 764
Carrel-Dakins' irrigation, 10
in chronic empyema, 705
Carriers:
typhoid, 2
cholecystectomy in, 267
Cartilage, loose, in joints, 884
injuries of, 853
Caruncle of female urethra, 526
Casoni and Fairlie's intradermic test, 257
Catheter, bi-coudé, 242
life, 505
Malecot, 483
olivary, 242
suprapubic, technique of inserting, 483
Catheterisation:
in spinal fractures, importance of, 606
intratracheal, 186
suprapubic, 483
Cauda equina:
injuries of, results of, 605
tumours of, features of, 629
Causalgia, ætiology of, 638, 661
ganglionectomy in, 666
Cauterisation, linea, for rectal prolapse, 379
Cavernous sinus, thrombophlebitis of, 104
Cellulitis, 1, 5
and acute osteomyelitis, differential diagnosis of, 795
complicating boils, 929
of neck, 149
of stomach, acute suppurative, 234
orbital, 118
special situations, 6
spreading, of abdominal wall, 436
treatment of, 6

Cerebral tumours, 586
clinical features of, focal, 586
localising, 586
pressure effects, 586
investigation of, nature of, 587
site of, 587
treatment of, 589
by craniotomy, 589
by decompression of posterior fossa, 591
See also Brain.
Cervical plexus, injuries to, 650
rib, 157
symptoms of, 159
treatment of, 159
varieties of, 158
Chancre :
Hunterian, 22, 104
of penis, 529
of lip, 104
of nipple, 673
primary, differential diagnosis of, 23
of anus, 383
sites of, 22
soft, of penis, 529
Chancroid of penis, 529
Charcot, intermittent hepatic fever of, cause of, 271
Charcot's joints, 863
Chauffeur's fracture, 759, 760
Cheilotomy in chronic monarticular osteoarthritis, 883
Chemosis, 118
Chest, compression of, 697
Chimney-sweeps' cancer, 558, 935
Cholangitis, suppurative, cause of, 271
Cholecystectomy :
in typhoid carriers, 267
technique of, 273
Cholecystgastrostomy :
for carcinoma of pancreas, 284
for gastric ulcer, 218
Cholecystitis, 2
acute, clinical features, 264
treatment of, 265
chronic, 265
symptoms of, 266
treatment of, 267
non-obstructive, acute, 264
obstructive, acute, 264
Cholecystography, 266
Cholelithiasis. *See* Gall-stones.
Chondroarthritis, 862
Chordee, 528
Chylorrhœa, 165
Circumcision, technique, 527
Clavicle, fracture of, 747
Claw-foot, 925
Cleft-palate, degrees of, 99, 100
treatment of, Brophy's operation, 101
Gillies-Fry operation, 102
Lane's operation, 101
Langenbeck's operation, 101
See also Hare-lip.
Cline's lateral splint, use of, in fractured tibia, 785
Cloaca, persistence of, 375
Clutton's joints, 861, 862
in congenital syphilis, 31
Coccyx, fractures of, 771
Cock's peculiar tumour, 561, 937
Codman's disease, 895
Coffey's method of implanting ureters, 486
modification of abdomino-perineal operation, 407
Coin-catcher, 199
Coley's fluid in carcinoma of tonsil, 193
in periosteal sarcomata, 828
Colic, appendicular, 355
differential diagnosis of, 356
gall-stone, 269
pseudo-biliary, 453
renal, 459
Colitis, ulcerative, chronic, 315
treatment of, surgical, 315
Collar-stud abscess, 94, 152, 153
Colles's fracture, 759, 760
Colo-colic intussusception, 335
Colon :
carcinoma of, 325
clinical features of, 326
spread of, 325
test of operability, 326
treatment of, 328
in relation to site, 328–329
congenital dilatation of, 311
diverticula of, 319. *See also* Diverticulosis.
tuberculosis of, generalised, 318
Colonic stasis, ganglionectomy in, 667
lumbar sympathectomy in, 667
Colopexy of sigmoid for rectal prolapse, 380
Colostomy in carcinoma of rectum, 405, 406
in diverticulitis, 322
left inguinal, for imperforate anus, 376
permanent, for rectal stricture, 402
Colpotomy, posterior, in pelvic cellulitis, 7

Complement fixation tests, 73
Compressed-air rupture of colon, 315
of rectum, 381
Compression and concussion, differential features of, 579
cerebral, causes of, 580
clinical features of, 581
treatment of, 583
Concato's disease, ascites in, 299
Concussion and compression, differential features of, 579
clinical features of, 579
theories of, 578
treatment of, 580
Condyles of humerus, fractures of, 758
Condylomata of anus, 383
infectious nature of, 24
treatment of, 28
Conjunctivitis, 2
Constipation, chronic, in visceroptosis, 314
Contracture, Dupuytren's, 907
Coope's test in chronic pancreatitis, 282
Cope's method in treatment of intussusception, 338
Coronoid process of jaw, fracture of, 745
Corpuscles, red, 71
Countryman's lip, 105
Courvoisier's law, 271, 283
Coxa plana, 831
vara, causes of, 912
treatment of, 914
Cranial bones, inflammation of, acute, 565
chronic, 565
contents, escape of, in fracture of skull, 571, 572
Cranio-cleido dystrophy, 834
Cranio-pharyngeal tumours, 596
Craniotabes, 801
in rickets, 809
Craniotomy, technique of, 589
Crepitus in fractures, 726
Cretinism, 168
treatment of, 169
Crile's method of block dissection of neck, 137, 164
of "stealing" the thyroid, 175
Crises in acholuric jaundice, 244
Dietl's, 453
Crutch palsy, ætiology of, 655
in fractures, 732
Cruveilhier's sign in saphena varix, 423
Cryptitis, 384
Cubitus valgus and varus, 906
Cubley's tracheotomy tube, 185
Curling's ulcer, 235
Cushing's basophile adenoma, 595
Cut throat, 147
complications of, 148
sites of, 148
treatment of, 147
Cyanosis in acute pancreatitis, 277
Cylindroma, 59
Cystectomy for bladder carcinoma, 500
Cystico-duodenal band, 314
Cystitis, 495
B. coli, 497
in spinal injuries, 606, 609
intramural, 497
treatment, 496
tuberculous, 497
typhoid, 317, 497
Cysto-diathermy for bladder papilloma, 498
Cystoscopy, 442
in calculous anuria, 463
in renal tuberculosis, 473
in vesical calculus, 494
in vesical diverticula, 488
in vesico-intestinal fistulæ, 489
Cystotomy:
suprapubic, for rupture of bladder, 492
for vesical calculus, 494
Cysts, Baker's, 47, 881, 883
branchial, 156
dental, 108
dentigerous, 108
median, over root of nose, 116
Meibomian, 115
of bile ducts, 263
of bones, 814
of brain, 586, 591
of breast, 680
of epididymis, 537
of hydatid of Morgagni, 538
of intestine, 318
of kidney, 448, 450
of liver, 255
of meninges, 586
of mesentery, 305
of mouth, 123
of orbital margin, 115
of ovary, diagnosis from ascites, 299
of ovary, lutein, 361
of pancreas, 280
of semilunar cartilage, 854
of spleen, varieties of, 247
pseudo, of pancreas, 280
retention, 123

Cysts (*cont.*):
retention, of gland of Montgomery, 673
sebaceous, 937
complications of, 937
of scalp, 561
of scrotum, 558
removal of, 938
thymic, 183
thyroglossal, 182

Dactylitis, syphilitic, 802
tuberculous, 805
Daw's method in treatment of intussusception, 338
Decompression of posterior fossa for cerebral tumour, 591
Deformities, 898–928
anatomical causes of, 898
correction of, surgical procedures in, 898
in acute infective osteomyelitis, 796
in fractures, 726
spinal, 901
Delirium tremens in fractures, 731
treatment, 732
Dental cyst, 108
Dentigerous cyst, 108
Derbyshire neck, 171
Dercum's disease, causes of, 595
Dermatol, use of, 67
Dermoid, external angular, 115
of mesentery, 305
of scalp, 562
post-anal, 377
sublingual, 125
Desmoid fibroma, treatment of, 44, 437
Diabetes:
chronic pancreatitis with, 282
insipidus, causes of, 595
Diaphyseal aclasis, 835
Diarrhœa in appendicitis, 357
Diathermy:
in carcinoma of œsophagus, 203
in cavernous angioma, 88
in chronic monarticular osteoarthritis, 883
in gonorrhœal arthritis, 861
rectal, in chronic gonorrhœa, 37
surgical, of malignant disease of upper jaw, 114
of rodent ulcer, 121
of tongue, 133, 136
Didot's operation for syndactylism, 908
Dietl's crises, 453
Dilatation of œsophageal strictures, 202
of rectal strictures, 402
of urethral strictures, 520
Dislocations, congenital, 837
fracture, of shoulder, 844
pathological, 837
traumatic, clinical features and treatment, 838
unreduced, 839
See also under names of joints.
Diverticulitis:
clinical features of, 320
complications of, 321
conditions simulating, 320
definition of, 319
hyperplastic, 320
Meckelian, 311
treatment of, 322
types of, 320
Diverticulosis:
clinical features of, 320
definition of, 319
of appendix, 371
Diverticulum, duodenal, 235
pharyngeal, 194
pressure, 194
pulsion, 194
Drainage, in appendicitis, 364
in empyema, open and closed, 701, 702
in infections of hand, 943
in pyopericardium, 722
DuBois abscesses, 183
Dugas' test for shoulder dislocation, 842
Duodenal ulcer:
causing subphrenic abscess, 292
chronic, 224
conditions simulating, 227
history in, 224
following burns, 235
perforated, 226
treatment of, medical, 225
surgical, indications for, 226
methods for, 226
Duodenectomy for duodenal ulcer, 226
Duodeno-gastrectomy, partial, for duodenal ulcer, 226
Duodenum and stomach, 207–235
occlusion of, congenital, 209
rupture of, traumatic, 235
surgical conditions of, 234
Dupuytren's classification of burns, 69
contracture, 907
fracture, 788

Dupuytren's splint, use of, in fractures of ankle joint, 789
Dwarfism, causes of, 594
renal, 833
Dysenteries, treatment of, surgical, 315
Dyspepsia :
appendicular, simulating duodenal ulcer, 228
chronic, causes of, pancreatitis, 282
features of, in chronic gastric ulcer, 215
Dysphagia in carcinoma of tongue, 134
Dyspnœa, following thyroid operation, 176
obstructive, relief of, 184
Dystrophia adiposa genitalis, causes of, 595
Dysuria in prostatic enlargement, 503

Ectopia vesicæ, 485
treatment of, 486
Edebohl's operation in Bright's disease, 474
Effusion :
peritoneal, following spleen removal, 239
pleural, following spleen removal, 239
or peritoneal in breast carcinoma, 692
Elbow-joint dislocations, 845
fractures, 755
tuberculosis, 878
Electrolysis in cavernous angioma, 89
Elephantiasis :
filarial, scrotal, 559
neuromatosa, 51
Elsberg's method of extrusion of intramedullary tumour, 633
Embolectomy, 84
in embolic gangrene, 65
in prevention of gangrene, 68
technique of, 721
Embolism, 83
fat, 83
following injection of varicose veins, 88
pulmonary, 718
predisposing causes of, 719
prophylaxis of, during operation, 720
post-operative, 720
pre-operative, 720
severity of, degrees of, 720
Embolism (*cont.*) :
pulmonary (*cont.*) :
treatment of, by Trendelenburg's operation, 721
results of, 83
situations of, 83, 84
Embolus, mesenteric, causing gangrene, 342
Emphysema, surgical, in lung laceration, 697
Empyema :
acute, causes of, 699
clinical features of, 699
drainage in, open and closed methods, 701, 702
needling of chest in, 700, 701
treatment of, by rib resection and drainage, 700, 701
bilateral, treatment of, 702
chronic, causes of, 704
treatment of, 704
by operations on lung, 706
by operations on chest wall, 706
diagnosis from subphrenic abscess, 294
due to lung laceration, 698
interlobular, treatment of, 703
necessitatis, 700
pneumococcal, 700
postpneumonic, 700
streptococcal, treatment of, 701
synpneumonic, 700, 701
Encephalocele, 563
Endocarditis, 2
ulcerative, 1
Endosteal sarcomata, 824
Endothelioma, 58
of bursa, 897
sites of, 58
Enemata :
administration of, injury to rectum in, 374, 381
precautions in, 374
varieties of, 373, 374
Entamœbæ histolytica, in tropical liver abscess, 252
Enteritis, acute, diagnosis from intussusception, 337
Enterocele, 409
strangulated, 412
relief of, 413
Enteroptosis, 312
kinks, membranes, and bands associated with, 313
Enterostomy in chronic ulcerative colitis, 316
Epididymectomy for chronic tuberculous epididymo-orchitis, 547

Epididymis, cysts of, 537
Epididymo-orchitis :
acute, 544, 545
B. coli, 545
clinical features and treatment, 545
of mumps, 545
post-operative, 545
staphylococcal, 545
tuberculous, 545
typhoid and paratyphoid, 545
chronic, 546
syphilitic, 547
tuberculous, acute, 546
chronic, treatment, conservative, 547
operative, 547
physical signs, 551
Epiphysis :
enlargement of, in rickets, 808
lower, of femur, separation, 781
of humerus, separation, 757
of radius, separation, 762
slipped, in coxa vara, 912
upper, of femur, separation, 776
of tibia, separation, 784
Epiphysitis, Calve's, 833
syphilitic, 801
Epiplocele, 409
Epispadias, 512
Epistaxis in skull fracture, 572
Epithelioma, 935
treatment of, 936
Epulis, 110
varieties and treatment, 110
Erb's paralysis, 652
Ergot, gangrene from, 64
Eruption, syphilitic, features of, 24
Erysipelas, 1, 11
and acute osteomyelitis, differential diagnosis of, 795
complications of, 12
migrans, 12
symptoms and signs of, 11
treatment of, 12
Erythema induratum, 933
Estlander's operation for empyema, 706
Ethmoid, carcinoma of, 162
sarcoma of, 114
Eusol, 8
Eve's hypothesis of acute pancreatitis, 276
Ewing's tumour, 825
Exanthemata, acute, and acute osteomyelitis, differential diagnosis of, 795
Excision :
in acute infective arthritis, 859
in tuberculous arthritis, 875
Exercises in prevention of pulmonary embolism, 721
Exomphalos, 428
Exophthalmos, pulsating, 117
Exostosis, subungual, 820
Extradural tumours, 627
Extramedullary tumours, 627
Extremity :
lower, deformities of, 908
fractures of, 768
upper, deformities of, 906
fractures of, 747
Eye, injuries, 118
Eyeball, evisceration, 119
excision, 118

Face, acute infection, 119
and jaw, fractures, 743
including palate, 98–121
carcinoma of, basal-celled, 120
embryology, 98
new-growths, 120
wounds, 119
Fæcal concretion in appendix, 353
Fæces in chronic pancreatitis, 282
"Faggot" method in urethral strictures, 521
Fat embolism, 83
in fractures, 731
Feet :
small bones of, tumours of, 817
Ewing's, 825
Femoral ring, anatomical relations of, 420
Femur :
fractures of, extracapsular, 774
intracapsular, 772
lower end, 781
shaft, 776
splints for, 778
through trochanters, 775
upper end, 772
Fever, aseptic traumatic, in fractures, 731
intermittent hepatic of Charcot, cause of, 271
Fibroids, recurrent, 44, 891
Fibro-lipoma, 46
Fibroma, 43
desmoid, 44
hard, 43
keloid, 44
of abdominal wall, 437
of muscles, 891
recurrent, 44
sites of, 43

Fibroma (*cont.*):
soft, 43
types, 43
Fibromatosis, gastric, 233
Fibro-sarcoma, 54
of bursa, 897
of muscles, 891
Fibrositis, 2, 890
Fibula and tibia, fractures of, 786
fracture of, 786
Filariasis, treatment of, 91
Fingers:
baseball, 889
congenital deformities of, 908
mallet, 766, 889
terminal pulp compartment, infection of, 940
trigger, 907
Finsterer's sign in Keinboch's disease, 832
Fistulæ.
acute abscess, 4
treatment of, 4
biliary, due to stone ulcerating through wall of gall bladder, 272
post-operative, 272
branchial, 155
congenital, of lower lip, 102
duodenal, 235
fæcal, 323
complicating diverticulitis, 321
gastro-jejunal-colic, 230
median mental, 112
milk, 675
œsophageo-tracheal, 205
parotid, sympathetic surgery in, 667
pelvi-rectal, 387
pilonidal, 377
post-anal, congenital, 377
salivary, symptoms of, 142
treatment of, 143
thyroglossal, 181
umbilical, 438
urethral, 524
vesico-colic, complicating diverticulitis, 321
vesico-intestinal, 489
Fistula-in-ano: ætiology of, 387
blind external, treatment of, 390
internal, treatment of, 390
clinical features and diagnosis of, 387
definition of, 386
multiple, 387
treatment of, by excision, 389
by fistulectomy, 389
by laying open fistula, 388
after-treatment, 389
Fistula-in-ano (*cont.*):
treatment of, by the seton, 390
pre-operative, 388
tuberculous, treatment of, 391
with multiple openings, treatment of, 391
varieties of, 386
Fistulectomy, 389
Fixation of fracture, 729
Flat bones, chondroma of, 819
Flat-foot, acquired, 918
causes, 918
congenital, 918
treatment, stages of, 919
Focal signs of cerebral abscess, 577
Forearm, drainage of, in infections from hand, 943
Foreign bodies:
causing appendicitis, 351
in air passages, symptoms, 186
treatment of, 187
in bladder, 495
in œsophagus, 199
in rectum, 381
in stomach, 209
Fournier, ano-rectal syphiloma of, 383
Fournier's gangrene, 558
Fovea coccygea, 376
Fowler's positions in treatment of peritonitis, 287, 288
Fracture blisters, 787
Fracture-dislocation of shoulder, 844
Fractures, chauffeurs', 759, 760
clinical features, 726
Colles', 759, 760
comminuted, 725
complications, 725
general, 731
indications for operation, 738
local, in blood-vessels, 737
in bone, 732
in joint, 735
in muscle, 734
in nerves, 737
infection, 738
new-growth, 734
pressure sores, 737
compound, 725
indications for operation, 739, 740
dis-union, 732
Dupuytren's, 788
greenstick, 726
impacted, 726
indications for operation, immediate, 739
intermediate, 740
remote, 742

Fractures (*cont.*):
Kocher's pertrochanteric, 775
local anæsthesia in, method of injection, 728
mal-union in, 732
march, 791
non-union, 733
treatment, 734
of metatarsal bones, 789
of tarsal bones, 789
predisposing causes, general, 724
local, 725
simple, 725
treatment, fixation, 729
reduction, 727
restoration of function, 730
Smith's, 760
spontaneous, 726
in osteitis deformans, 813
treatment of, first-aid, 727
Bohler's method, 730
union of, 727
varieties of, 725
See also under names of bones.
Freyer's method of prostatectomy, 504
"Frog-faced man," 115
Frohlich's syndrome, causes of, 595
Frost-bite, 69
Function, restoration of, in fractures, 730
Funiculitis, 33
acute epidemic, 536
Furuncle, 929
of face, 119
Furunculosis of external auditory meatus, 929

Galactocele, 680
Gall bladder, infection, 1
abnormalities of, congenital, 263
and bile ducts, 263–284
carcinoma of, 275
complications in typhoid fever, 317
duplication of, 263
inflammation of, 264
mucocele of, 264
rupture of, 263
torsion of, 263
Gallow's splint, use of, in fractured femur, 779
Gall-stones, 267
causing intestinal obstruction, 341
chronic pancreatitis with, 281
colic, 269
impaction of, 271
results of, 271
Gall-stones (*cont.*):
in common duct, treatment of, 274
inaugural symptoms, 269
physical signs, 270
silent, 269
treatment of, 273
types of, 267, 268
Ganglion, compound palmar, 893
simple, 893
Ganglionectomy:
cervicodorsal, technique of, 669
cervico-thoracic, in scleroderma, 665
in causalgia, 666
in colonic stasis, 667
in Hirschsprung's disease, 667
in infantile paralysis, 665
in megacolon, 667
in polyarticular osteoarthritis, 665
in Raynaud's disease, 665
lumbar, in senile gangrene, 64
in thrombo-angiitis obliterans, 664
technique of, 670
technique of, 669
thoracic, in retinitis pigmentosa, 665
Ganglioneuroma, 49
Gangrene, 61
diabetic, 65
dry, 62
embolic, 64
ergot, 64
Fournier's, 558
gas, 65
treatment, 66
in intussusception, 334
infective, 65
moist, 62
physical and chemical causes of, 68
senile, 64
symptomatic, 63
traumatic, direct, 67
indirect, 67
treatment, 63
varieties, 63
Gastralgia, 212
Gastrectomy, partial ·
for carcinoma, 223
for gastric ulcer, 217
Gastric tetany, 210
ulcer, acute, clinical varieties and treatment of, 212, 213
causing subphrenic abscess, 292

Gastric tetany (*cont.*):
ulcer, chronic, 213
complications of, acute, 219
adherence and penetration to pancreas, 223
carcinoma, 223, 232
chronic, 222
hour-glass stomach, 222
intermediate, 221
pyloric stenosis, 222
conditions simulating, 227
diagnosis of, 214
history in, 214
pathology of, in living, 213
treatment of, surgical, methods employed, 217
perforated, 219
treatment of, 220
treatment of, indications for operation, 216
removal of plexus around cœliac artery, 665
Gastritis, phlegmonous, acute, 234
Gastrocnemius, rupture of, 888
Gastro-duodenostomy for duodenal ulcer, 226
Gastro-jejunostomy:
complications of, 229
for duodenal ulcer, 226, 227
for gastric ulcer, 217
for pyloric stenosis, 222
Gastro-photography in diagnosis of gastric ulcer, 216
Gastroptosis simulating ulcer, 227
Gastrostomy in œsophageal carcinoma, 202
Gastrotaxis, 212
Gaucher's disease, 245
ætiology of, 59
Genito-urinary complications of typhoid fever, 317
Genu valgum, causes, 914
treatment, 915
Gestation, ectopic, diagnosis from appendicitis, 361
Gigantism, causes of, 593
Gillies-Fry operation for cleft-palate, 102
Gingivitis, 109
Glandulæ concatenatæ, 95
Gleet, treatment of, 37
Glénard's disease, 312
Globus hystericus, 203
Glossitis:
acute parenchymatous, 128
acute superficial, 127
chronic superficial, ætiology and clinical features, 128
Glossitis (*cont.*):
chronic superficial, treatment, 129
leukoplakia, 128
parenchymatous, 891
Glottis, acute œdema of, 184
Glycerine enema, 374
Glycosuria due to pituitary tumours, 596, 597
Goitre, adeno-parenchymatous, ætiology of, 171
clinical features, 171
treatment, 172
adolescent, 170
colloid, of puberty, 170
endemic, 171
exophthalmic, 173
treatment of operative, complications of, 176
post-operative treatment, 176
preliminary ligature of superior thyroid arteries, 175
pre-operative regime, 174
technique of, 175
thyrotoxic, 173
" Golf-hole " ureteric orifice, 91
Gonococci, 2, 32
Gonorrhœa, 32
acute, treatment of, 36
chronic, treatment of, 37
complications of metastatic, 36
incubation period of, 33
in female, chronic or latent stage, complications of, 35
symptoms of, 34
in male, acute stage, 33
complications of, 33
chronic or latent stage, 34
complications of, 34
treatment of, abortive, 36
prophylactic, 36
Granuloma inguinale, 530
Gravel rash, 896
Graves's disease, primary, 173
pre-operative treatment, 174
symptoms and treatment, 173, 174
secondary, 177
Grawitz's tumour of kidney, 475, 477
Grey Turner's sign in acute pancreatitis, 278
Gridiron incision for appendicectomy, 363
Gum-elastic bougies, 520
Gumma, endosteal, 804
of anus, 383
of brain, 586
of testis, 548
of tongue, 131

Gumma (*cont.*):
periosteal, 803
synovial, local, 862
treatment of, 25, 28
Gummata and tuberculous cervical adenitis, differential diagnosis of, 152
Gummatous ulcer, diagnosis from varicose, 27
Gums, hypertrophy of, 109
Gynæcomazia, 674

Hæmangioma, 88
Hæmangiomata
cutaneous, 120
of mouth, 105, 126
Hæmatemesis:
in acute gastric ulcer, 212
in chronic gastric ulcer, 215
post-operative, 229, 240
severe causes and treatment of, 220, 221
Hæmatocele of testis, 538
simulating malignant testis, 552
Hæmatoma of breast, 675
intramural, 435
juxta-epiphyseal, 792
perinephric, 451
treatment of, 452
Hæmaturia, causes of, 440
in bladder neoplasms, 498
in injuries of kidney, 450
in prostatic enlargement, 503
in renal calculus, 460
in renal neoplasms, 477
in renal tuberculosis, 472
in vesical calculus, 493
significance of, 440
Hæmoperitoneum, 250
Hæmophilia, 887
treatment of, by snake venom, 887
Hæmorrhage, 75
after tonsillectomy, 191
arterial, primary, 76
reactionary, 76
secondary, 76
following thyroid operation, 176
intradural, 585
meningeal, middle, clinical features of, 581
treatment of, 583
venous, 77
Hæmorrhoids, 394
ætiology and pathology of, 395
arterial, 395
cutaneous, 396
external, 395
injection treatment contra-indicated, 400
Hæmorrhoids (*cont.*):
external, treatment of, 396
varieties of, 396
internal, 396
complications of, prolapse, 398
thrombosis, 398
physical signs of, 397
treatment of, by clamp and cautery, 401
by clamp and suture, 400
by injection, 399
by simple ligature, 401
by Whitehead's operation, 401
intero-external, 394
treatment of, 400
pregnancy, 395
prolapsed strangulated, treatment of, 398
thrombotic, 396
varieties of, 394
Hæmostasis, importance of, in nerve suture, 639, 640, 641
Hæmothorax, 697
Hagner's operation for aspermia, 553
Hair-ball of stomach, 209
Hallux valgus, 896, 926
Halstead principle in herniorrhaphy, 416
Hamilton's ruler test for shoulder dislocation, 842
Hammer-toe, 928
Hand, "ape-like," 657
fascial spaces of, infections of, 943
infections of, 939–946
serious, 941
after-treatment of, 946
middle palmar space, boundaries of, 945
infections of clinical features and treatment of, 945
pulp space, infections of, clinical features and treatment of, 940
"Simian," 657, 658
small bones of, Ewing's tumour of, 825
tumours of, 817
thenar space, boundaries of, 943
infections of, 944
clinical features of, 944
treatment of, 944
Hare-lip and cleft-palate:
clinical features, 99
sex incidence, 99
treatment, 100
double, associated with premaxilla, treatment, 102

Hare-lip (*cont.*):
lateral and bilateral, incidence, 99
treatment of, Owen's operation, 102
Rose's operation, 102
See also Cleft-palate.
Harris's lines, 836
method of prostatectomy, 504
Head, 560–598
injuries, sequelæ of, 580
treatment of, 573
Heart and pericardium, 722
failure, ascites in, 299
wounds of, 723
treatment of, 723
Heberden's nodules, 880
Helio-therapy:
in abscess fistula and sinus, 5
in carbuncles, 930
in chronic tuberculous epididymo-orchitis, 547
in chronic tuberculous peritonitis, 298
in tuberculosis of colon, 318
in tuberculous lymphadenitis, 153
Henoch's purpura, diagnosis from intussusception, 337
Hepatic ducts, stones in, 270
Hepatoptosis, 260
partial, 260
Heredity in hernia, 409
Hernia, 408–439
ætiology of, 408
clinical features of, 410
coverings of, 410
diaphragmatic, 434
fatty, of linea alba, 432
treatment of, 432
femoral, 420
bladder diverticulum in relation to, 421
clinical features of, 421
differential diagnosis of, 422
irreducible, diagnosis from enlarged femoral lymphatic gland, 424
from femoral aneurism, 424
from irreducible inguinal, 424
from lipoma, 424
from rupture of adductor longus, 424
reducible, diagnosis from inguinal, 422
from obturator, 423
from psoas abscess or bursa, 423
from saphena varix, 423
Hernia (*cont*).:
femoral, strangulated, 426
treatment of, 427
surgical anatomy of, 420
treatment of operative, Hey Groves's operation, 426, 428
inguinal (Lotheisen's) operation, 425, 428
lower operation, 425, 427
treatment of palliative, 424
gluteal, 434
differential diagnosis of, 435
incarcerated, 412
incidence of, 408
incisional, 433
incarceration in, 431, 433
inguinal, 414
congenital, 414
direct, 418
indirect, ætiology of, 414
clinical features, 414
differential diagnosis of, 415
treatment of, operative, 416
palliative, 415
oblique, 414
special forms of, 418
strangulated, 417
treatment of, by taxis, 417
operative, 418
postural, 418
surgical anatomy of, 414
internal, causing intestinal obstruction, 343
sites of, 343
interparietal, 420
interstitial, 420
abnormalities associated with, 420
irreducible, 411
taxis in, 412
treatment of, 412
Littré's, 410
lumbar, 434
differential diagnosis of, 434
obstructed, 412
obturator, 433
paraumbilical, of adults, 429
incarceration in, 431
pathological anatomy of, 409
phantom, 434
reducible, physical signs of, 410
treatment of, 410
Richter's, 409
frequency of, 426
sac of, 409
contents of, 409
sciatic, 434
differential diagnosis of, 435
sliding, 419

Hernia (*cont.*):
strangulated, 334, 412
treatment of, 412
treatment of, operative, 411
palliative, 410
truss for, particulars required when ordering, 415
umbilical, 428
congenital, 428
infantile, 429
in tuberculous peritonitis, 298
Mayo's operation for, 430
strangulated, 431
treatment of, 431
varieties of, 428
use of truss in, 410
varieties of, 408
ventral, 431
lateral, 433
Hernie-en-glissade, 419
Herniopiasty, 411
for indirect inguinal hernia, 416
Herniorrhaphy, 411
for indirect inguinal hernia, 416
Herniotomy, 411
for indirect inguinal hernia, 416
Herpes, penile, 529
Hesselbach's triangle, 418
Hexamine, use of, 468
Hey Groves's operation for femoral hernia, 426, 428
Hibbs's operation for Pott's disease, 623
Hiccough, persistent, following spleen removal, 240
Hilton's method of treating abscess, 4
Hip-joint:
congenital dislocation of, clinical features, 909
treatment, manipulative, 911
operative, 911
palliative, 912
dislocation of, anterior and posterior, 848, 912
snapping, 890
tuberculosis, 876
differential diagnosis and treatment, 876
Hirschsprung's disease, 311
ganglionectomy in, 667
lumbar sympathectomy in, 667
treatment of, 312
Hodgen's splint, use of, in fractured femur, 779
Hodgkin's disease, 96, 163
and tuberculosis cervical adenitis, differential diagnosis of, 151
Hordeolum, 929
Horse-shoe kidney, 446
"Hospital gangrene," 123
Hot-cross bun head, 801
Housemaid's knee, 895
Houston's values, 373
Humerus, fractures of lower end, 755
shaft, 753
upper end, 751
Hunner's ulcer of bladder, 497
Hunterian chancre, 22
of lip, 104
of penis, 529
Hunter's operation in aneurism, 81
Hutchinson's pill in syphilis, 29
teeth, 802
wart, 24, 131
Hydatids of liver, 255
of mesentery, 306
of pancreas, 280
of spleen, 247
Hydrencephalocele, 563
Hydrocele, acute, 536
ætiology and varieties, 533
bilocular, 534
chylous, 536
complications, 535
congenital, 534
in tuberculous peritonitis, 297
diagnosis of, golden rule for, 534
encysted, of cord, 534
fluid, 533
hour-glass, 534
infantile, 534
of breast, 92
of canal of Nuck, 535
of femoral hernial sac and irreducible femoral hernia, differential diagnosis of, 424
of hernial sac, 536
post-operative, 558
secondary, 536
treatment of, operative, Jaboulay's operation, 536
subtotal excision, 536
tapping, 535
tapping and injection, 535
vaginal, 534
Hydrocephalus, acquired, 564
congenital, 563
Hydronephrosis:
ætiology and clinical features, 455
complications, 456
pathology, 454
periarterial sympathectomy in, 668
presacral neurectomy in, 668
rupture, 452
treatment, 456

Hydrops in tuberculous arthritis, 867
Hydroureter, periarterial sympathectomy in, 668
presacral neurectomy in, 668
Hygroma, cystic, 161
Hyperæmia, artificial, in acute parotitis, 138
Hypernephroma, 475
Hyperthyroidism, post-operative, acute, 176
Hypospadias, varieties and treatment, 512
Hypothyroidism :
adult, 169
infantile, 168
Hysteria, joint complications, 866

Ileo-cæcal intussusception, 335
Ileo-colic intussusception, 335
Ileo-ileal intussusception, 335
Ileum, atresia of, congenital, 333
tuberculosis of, 317
Ileus, adynamic, 343
duodenal, chronic, 235
paralytic, causes and treatment of, 343
Iliac fossa :
right, actinomycosis of, 371
glands, inflammation of diagnosis from appendicitis, 359
Immuno-transfusion in septicæmia, 73
Impalement of rectum, 380
Impotence, 553
in prostatic enlargement, 502
Incontinence, rectal, 380
Industrial carcinoma of scrotum, 558, 935
Infantile paralysis. *See* Paralysis, infantile.
Infections :
in relation to treatment of joint injuries, 860
non-specific, and wounds, 1–10
wound, 7
Infectious diseases, specific, 11–37
Influenza, abdominal, diagnosis from appendicitis, 359
Injection :
treatment of anal fissure, 393
carbuncle, 931
hæmorrhoids, 399
hydrocele, 535
rectal prolapse, 380
trigeminal neuralgia, 644
varicocele, 556
varicose veins, 86
Interphalangeal dislocations, 847
Intertrigo, submammary, 679
Intestinal obstruction, 2, 330–346
acute, 330
of new-born, 333
treatment of, 332
in varying circumstances, 332
acute-on-chronic, clinical features of, 342
special complication of, 346
treatment of, 342
cause of death in, 331
chronic, causes of, in adult, 346
in child, 346
classes of, 330
due to adhesions, 340
due to bands, 340
due to gall-stones, 341
due to internal herniæ, 343
due to invagination, 334
due to mesenteric embolus and thrombosis, 342
due to stercolith, 342
due to strictures, 340
due to volvulus, 333
due to worms, 342
theories of toxæmia in, 331
in relation to treatment, 331
toxæmia in, alkalosis theory, 331
bacterial theory, 331
chemical theory of, 331
dehydration theory, 331
tuberculosis of mesenteric glands causing, 304
Intestines, 308–329
adenomatous polypi of, 324
carcinoma of, 325
congenital malformations of, 309
diverticula of, 319. *See also* Diverticulosis *and* Diverticulitis.
embryology of, 309
hæmorrhage of, in typhoid, 317
inflammation of, 315
invagination of, 334. *See* Intussusception.
kinks of, 313
lipomata of, 324
lympho-sarcoma of, 324
Meckel's diverticulum of, 309
neoplasms of, benign, 324
malignant, 324
obstruction of. *See* Intestinal obstruction.
perforation of, in typhoid, 317
pneumatosis of, 318
rupture of, traumatic, 314
small, cystic pneumatosis of, 318

Intestines (*cont.*):
small, neoplasms of, 324
stricture of, 340
volvulus of, 339
stasis of, chronic, 314
strictures of, 340, 341
surgical anatomy of, 308
tuberculosis of, 317
volvulus of, varieties and treatment of, 339
Intra-abdominal pressure, increased, in ætiology of hernia, 409
Intracranial pressure in cerebral abscess, 577
Intradermic test in hydatid disease of liver, 257
Intramedullary tumours, 628
Intrathoracic neoplasms, 714
Intubation, 187, 202
Intussusception:
acute, 334
ætiology of, 335
varieties of, 335
ætiology of, 335
gastro-jejunal, 230
idiopathic, 337
in adolescents, 337
in infants, ætiology of, 335
clinical features of, 336
differential diagnosis of, 337
treatment of operative, 337
after-treatment, 339
Intussusceptum, the, 334
Intussuscipiens, the, 334
Iodine in goitre, 172, 174
therapy in actinomycosis, 154
in goitre, 172
Irritation, cerebral, causes and treatment of, 584
Ischial tuberosity, fractures of, 770

Jaboulay's operation for hydrocele, 536
Jackson's membrane, 314
Jaundice:
acholuric, 244
treatment of, 245
depth of, in impacted gallstones, 271
in carcinoma of pancreas, 283
rare in acute cholecystitis, 264
Jaws:
and face, 98
fractures of, 743
false ankylosis of, 886
lower, dislocation of, 839
necrosis, 111
Jaws (*cont.*):
osteomyelitis of, acute, 111
chronic, 111
upper, excision of, 114
malignant disease of, 112
differential diagnosis, 113
treatment, 114
sarcoma of, 113
Jejunostomy, temporary, for gastric ulcer, 218
Joints:
ankylosis of, false, causes, 736, 885
treatment, 886
true, causes of, 736, 886
barometric, 882
Charcot's, 863
Clutton's, 861, 862
diseases of, 856–887
acute infective arthritis, 856
neuropathic, 863
osteoarthritis, 879
synovitis, 856
syphilitic, acquired, 862
inherited, 861
tuberculous, 867
effusions in, painless, 861
in hysteria, 866
in syringomyelia, 865
injuries to, 837–855
loose bodies in, 884
treatment, 885
neuropathic, 863
penetrating wounds of, 859
treatment, infection in relation to, 860
Jutte's tube, use of, 211

Kashiwado's test in chronic pancreatitis, 282
Kehr's sign in ruptured spleen, 238
Keinboch's disease, 832
Kelly's test in saphena varix, 423
Keloid, treatment of, 44
Ketogenic diet in urinary infections, 468
Kidd's **U**-tube, use of, 482, 483
Kidneys:
abnormal renal vessels, 447
treatment, 448
abnormalities of, congenital, 445
adenoma of, 474
and ureters, 440–480
embryology of, 444
angioma of, 474
calculus, 457. *See* Calculus, renal.
carbuncle of, 469
carcinoma of, 476, 478
secondary deposits in, 829

Kidneys (*cont*):
congenital cystic, clinical features, 449
cyst of, solitary, 450
decapsulation in Bright's disease, 474
effects of prostatic enlargement on, 502
embolism of, 84
failure of, ascites in, 299
clinical characteristics of, 441
floating, 452
Grawitz's tumour of, 475, 477
horse-shoe, 446
infections of, 467
injuries of, clinical features, 450
rare, 452
treatment, 451
indications for operation, 451
movable, 452
crises in, 453
treatment, operative, indications and contraindications, 454
palliative, 454
neoplasms of, 474
clinical features, 477
conditions simulating, 477
treatment, 478
unilateral, 478
operations on, anterior route, 479
posterior route, 478
pain, 440
pelvis, papilloma of, 474
pouch, Rutherford Morison's, 292
rupture of, intraperitoneal, 452
sarcoma of, 476
surgical, 468
tuberculosis of, clinical features, 470
treatment, 474
Wilm's tumour of, 476, 477
Kirschner's wire in fracture of femur, 777
"Kiss cancer," 498
Klumpke's paralysis, 652
Knee-joint, dislocation of, 850
internal derangement of, 851
penetrating wounds of, 859
tuberculosis of, 877
Knock-knee, 914
Kocher's:
method of treating shoulder dislocation, 843
operation for tongue excision, 137
Kohler's disease, 832
Kollmann's adjustable dilator, 37
dilator, 520
Kondoléon's operation in lymphatic obstruction, 91
Krukenburg's tumours, ætiology of, 232
Kummel's disease, causes of, 602
Kyphosis, 905
in Pott's disease, 617
in rickets, 809
treatment, 905

Lachrymal sac, mucocele of, 115
Laminectomy:
anæsthesia for, 632
in spinal fractures, 609
indications for, 630
technique of, 631
Lane's first kink, 314
last kink, 314
operation for cleft-palate, 101
Langenbeck's operation for cleft-palate, 101
Laparotomy, lower, for rupture of bladder, 492
Laryngectomy for carcinoma, 189
Laryngo-fissure for laryngeal carcinoma, 189
Laryngotomy, 185
Larynx:
affections of, in typhoid, 317
and pharynx, 184–196
carcinoma of, extrinsic, 189
intrinsic, 188
neoplasms, 188
papillomata, 188
syphilis, 187
tuberculosis, 187
Lavage, gastric, 211
Leather-bottle stomach, 233
Leontiasis ossea, 816
differential diagnosis of, 113
Leriche's operation, 668
Leucocytes
eosinophile, 71
polymorphonuclear, 71
types of, 71
Leucocythæmia, 247
Leukæmia, lymphatic, 96
Leukoplakia glossitis, 128
of penis, 528
Ligaments of knee-joint, injuries of, 852
Ligature in continuity, 77
Limbs, embolism of, 84
Linea alba, fatty hernia of, 432
Linitis plastica, 233
Lip, cancer of, 105
carbuncle of, 104
chancre of, 104
chronic enlargement of, 103

Lip (*cont.*):
cracked, 103
treatment of, 103
lower, congenital fistulæ of, 102
new-growths of, 105
Lipiodol injection:
in diagnosis of bronchiectasis, 713
in diagnosis of empyema, 705
in diagnosis of spinal canal tumours, 630, 631
Lipoma, 45
arborescens, 47, 880
circumscribed, 46
extradural, 48
intra-articular, 47
intraglandular, 48
intramuscular, 47
parosteal, 47
subcutaneous, 46
subfascial, 46
submucous, 47
subserous, 47
subsynovial, 47
diffuse, 45
in sucking-pad of infant, 126
multiple, 45
treatment of, 48
Lister's metal sound, 520
Litholapaxy for vesical calculus, contraindications to, 494
Lithotrite, Canny Ryall's, 494
Littré's hernia, 410
Liver, 249–262
abscess of, 251
in paratyphoid, 317
paths of infection in, 251
tropical, 252
pathology and clinical features of, 252, 253
treatment of, 254
actinomycosis of, 255
adenomata of, 259
angiomata of, 258
carcinoma of, primary, 259
secondary, 260
cirrhosis of, alcoholic, 261
ascites in, 299
atrophic, 261
treatment of, Talma-Morison operation, 261
Tannahill's operation, 261
cystadenoma of, 259
cysts of, congenital, 259
dislocated, 261
enlargements of, table of, 262
floating lobe of, 260
"foaming," 66
function, cessation of, due to impacted gall-stones, 271
Liver (*cont.*):
hepatoma of, 259
hobnail, 261
hydatid disease of, 255
complications of, 258
course of, 257
pathology and clinical features of, 255, 256
treatment of, 258
linguiform lobe of, 260
melanoma of, secondary, 260
movable, 261
neoplasms of, primary, 258
secondary, 260
Reidel's lobe of, 261
resection of portion of, 260
rupture of, 249
sarcoma of, primary, 260
secondary, 260
secondary deposits in, following removal of eyeball, 262
syphilis of, 255
tuberculosis of, 255
wandering, 261
Lobectomy for lung carcinoma, 718
Loewi's mydriatic test in acute pancreatitis, 277
in chronic pancreatitis, 282
Long bones.
chondromata of, 818
periosteal sarcomata of, 825, 826
Lorain's syndrome, causes of, 594
Lordosis, 905
Lotheisen's operation for femoral hernia, 425, 428
Ludwig's angina, 149–150
and cellulitis, differential diagnosis of, 149
Lugol's solution in goitre, 172, 174
Lumbar puncture:
anæsthesia, 633
in brain injuries, 580, 583
in spinal canal tumours, 630
indications for, diagnostic, 633
therapeutic, 633
technique of, 633
Lungs:
abscess of, causes of, 710
clinical features of, 711
treatment of, 711
by bronchoscopy, 712
by lobectomy, 712
by phrenic evulsion, 712
by thoracoscopy, 712
by thoracotomy, 712
and pleura, infections of, 699
injuries of, non-penetrating, 697
treatment of, 698

Lungs (*cont.*):
pleura, injuries of, penetrating, 698
treatment of, 699
tumours of, benign, 714
signs and symptoms of, 715
treatment of, 715
carcinoma of, parenchymatous, 718
decortication of, in empyema, 706
discission of, in empyema, 706
embolism of, symptoms and treatment of, 84
hernia of, 699
laceration of, 697
conditions supervening on, 697
treatment of, 698
tumours of, malignant, primary and secondary, 714, 716
Lupus verrucosis, 933
vulgaris, 932
Lymph gland, facial, adenitis of, 126
Lymphadenitis:
acute, treatment of, 93
cervical, 151
chronic, simple, treatment of, 93
specific, 93
treatment of, 94
tuberculous, 151
treatment of, 152
Lymphadenoma, 96, 163
treatment, 97, 164
Lymphangiectasis, 91, 92
Lymphangioma, capillary, 92
cavernous, 92
Lymphangioplasty, 91
Lymphangitis, 1
acute, symptoms and treatment, 90
chronic, 90
of hand, 941
Lymphatics:
and lymphatic glands, 90–97
carcinoma, 97
chronic enlargement of, causes of, 95
dilatation of congenital and acquired, 92, 93
diseases of, 90, 93
draining colon, 326
obstruction of, causes of, 91
results and treatment, 91
syphilis of, 95
tuberculosis of, 93
Lymphocyte, 71
Lympho-sarcoma, 55, 164
and tuberculous cervical adenitis, differential diagnosis of, 152
primary, 97
McBurney's point, 348
McCarthy's visual prostatic electrotome, 505
MacIntyre's splint:
use of, in fractured femur, 779
in fractured tibia, 785
Macrocheilia, 92, 103, 105
Macrodactyly, 908
Macroglossia, 92
lymphangiomatous, 103, 132
muscular, 127
syphilitic, 131
Madelung's disease, 833
Malgaigne's bulgings, 419
Malleolus, internal, fracture of, 786
Mallet finger, 766, 889
Manipulation:
in congenital dislocation of hip, 911
in congenital torticollis, 900
in deformities, 898, 900, 911, 921
in fractured femur, 777
in sacralisation of lumbar vertebra, 626
in talipes, 921
March fractures, 791
Marjolin's ulcer, 936
Marsupialisation of mesenteric cyst, 306
with partial excision in ranula, 125
Mass reflexes in spinal fractures, 603, 607, 610
Mast cell, 71
Mastitis, carcinomatosis, 689
chronic interstitial, clinical features, 681
pathology, 682
relationship to carcinoma, 682
treatment, 682
from local irritation, 676
from milk engorgement, 677
of infants, 676
of lactation, 677
of puberty, 676
Mastodynia, 681
Mata's operation in aneurism, 80
Maxilla, inferior, fracture of, 745
superior, fracture of, 743
Mayo's incision, 479
operation for umbilical hernia, 430
Mazoplasia, 681
Meatotomy, 511
Meatus, pin-hole, 511
Meckel's diverticulum, 309
in ætiology of intussusception, 335, 337
inflammation of, 311
inversion of, 311

Mediastinum :
tumours of, benign, 714
signs and symptoms of, 715
treatment of, 715
malignant, primary and secondary, 714
Megacolon, ganglionectomy in, 667
lumbar sympathectomy in, 667
Meibomian cyst, 115
Melæna, in gastric ulcer, 215
severe, 221
treatment of, 221
Melanoma :
benign, 56
malignant, 56
of lymphatics, 97
sites of, 57
treatment of, 57
" Melon-seed " bodies in joints, 867, 884
Meninges :
blood and arachnoid cysts of, 586
endothelioma of, 586
psammoma of, 586
tuberculoma of, 586
tumours of, 586
Meningioma, 586
removal of, 590
Meningitis :
in spinal injuries, 611
infective, acute, 574
serosa circumscripta following spinal injury, 609, 611
Meningocele :
and meningo-myelocele, diagnosis between, 614
situations of, 562
treatment of, 563
types of, 613
Meningo-myelocele, 613
Mercurochrome, 8, 252
Mercury in syphilis, 29
Mesenteric glands :
suppurating, 302
tuberculosis of, 303
types of, 303
Mesenteric vessels :
embolism of, 84
embolus and thrombosis of, causing intestinal obstruction, 342
Mesentery :
cysts of, 304
complications of, 306
treatment of, 306
varieties of, 305
neoplasms of, 306
torsion of, 302
wounds of, 302
Mesocolic band of Pringle, 314
Metacarpal bones, fractures of, 765
Metacarpo-phalangeal dislocations, 847
Metastases, rarity of, in rodent ulcer, 121
Metatarsals, fractures of, 790
Meteorism in injuries of kidney, 451
Micturition :
frequency of, in prostatic enlargement, 503
in renal tuberculosis, 472
in vesical calculus, 493
significance of, 440
Mikulicz's disease, 145
operation for carcinoma of colon, 329
operation in cardiospasm, 205
Milk in ætiology of tuberculosis, 303
iodised, preparation of, 154
Milroy's disease, 92
Miner's elbow, 895
Molar gland, mixed tumour of, 126
Moles, pigmented and hairy, 120
Molluscum fibrosum, 50
Monk's method of intestinal localisation, 309
Mononuclear cell, 71
Montgomery, gland of, retention cyst of, 673
Moon's turreted molar, 31, 802
Morgagni, hydatid of, cyst of, 538
Morris's bitrochanteric measurement, 910
incision, 478
Mouth and tongue, 122–137
carcinoma, 126
cysts, 123
infections, 122
tumours of, mixed, 126
Mule-spinner's cancer, 558
Mulford's serum in anthrax, 15
Murphy's sign in gall-stones, 270
Muscles, arm, innervation of, 652
contusion of, 888
hernia of, 890
inflammation of, 890
injuries of, 888
lipomata of, 891
paralysis of, due to nerve division, 637
rupture of, 888
tendons and bursæ, 888–897
tumours of, 891
Myelinic neuroma, 49
Myelitis in spinal injury, 609, 610
Myelocele, 613
Myelomatosis, 823

Myositis, acute suppurative, 890
fibrosa complicating fracture, 735
ossificans, 891
complicating fracture, 735
rheumatic, 890
syphilitic, 891
tuberculous, 891
Myxœdema, 169
facies of, 170

Nævo-lipomata, 46
Nævus, capillary, 88
lymphatic, 92
simple, 120
spider, 88
Nasal bones, fracture of, 744
Naso-pharynx, tumour of, 114
Natiform head, 801
Neck, 147–166
actinomycosis of, 153
block dissection of, Crile's method, 137, 164
cellulitis of, 7, 149
hæmangioma of, deep cavernous, 162
lymphadenitis of, 151
malignant glands of, 162
solitary lymph cyst of, 162
tuberculous glands of, 151
Needling in subphrenic abscess, 294, 295
Nélaton's line, 772, 774
Neo-salvarsan:
treatment of anthrax, 15
of syphilis, 28
Neotropin, use of, 468
Nephrectomy for renal neoplasms, 478
Nephrolithotomy, 461
Nephropexy, 454
Nephrostomy for calculus anuria, 463
Nerves, 636–642
anastomosis of, 642
anchoring of, 640
auditory, fibroma of, 586
circumflex, injuries of, 654
compression of, 636
concussion of, 636
contusion of, 636
cranial, injuries of, 643
in skull fracture, 571, 572, 573
cutaneous, external, injuries of, 660
division of, 637
complete, results of, immediate, 637
remote, 637
incomplete, 639

Nerves (*cont.*):
division of, treatment of, by primary suture, 639
by secondary suture, 639
dorsal, twelfth, injuries of, 659
eighth, injuries of, 647
eleventh, injuries of, 648
fifth, injuries of, 644
fourth, injuries of, 643
friction of, results of, 636
ilio-inguinal, injuries of, 660
injuries of, 636
irremediable, treatment of, by amputation, 642
by anastomosis, 642
by arthrodesis, 642
by tendon transplantation, 642
interosseous, posterior, injuries of, 657
laryngeal recurrent, injuries of, 648
injuries to, during thyroid operation, 177
median, injuries of, at wrist, 658
clinical features of, 657, 658
musculo-spiral, injuries of, clinical features of, 655, 656
in axilla, 655
in elbow, 657
in musculo-spiral groove, 656
ninth, injuries of, 647
of Bell, injuries of, 655
olfactory, injuries of, 643
optic, injuries of, 643
peripheral, injuries of, 654
phrenic, avulsion of, in pulmonary tuberculosis, 708
technique of, 650
popliteal, external, injuries of, clinical features of, 661
internal, injuries of, 661
rupture of, 637
sciatic, great, injuries of, clinical features of, 660
seventh, injuries of, cranial, 646
extracranial, 646
intracranial, 645
sheaths, fibrosarcoma of, 586
sixth, injuries of, 645
special, 643–671
spinal, injuries of, 650
suture of, primary, technique of, 639
results of, factors influencing, 641
secondary, technique of, 640
tenth, injuries of, 647
third, injuries of, features of, 643

Nerves (*cont.*):
twelfth, injuries of, 649
ulna, injuries of, at elbow, 658
at wrist, 659
clinical features of, 658, 659
Nervous system.
parasympathetic, 663
sympathetic, anatomy of, 661
ganglionated trunks, 662
postganglionic fibres, 662
preganglionic fibres, 662
sympathetic, surgery of, anæsthesia for, 663
cervicodorsal ganglionectomy, 669
ganglionectomy, 669
indications for, 663
circulatory disturbances 663
painful conditions, 665
secretory disturbances, 666
to relieve spasm, 667
lumbar ganglionectomy, 670
periarterial neurectomy, 668
presacral neurectomy, 668
ramisection, 669
Neuralgia, trigeminal, 644
treatment of, by injection, 644
operative, 644
Neurasthenia:
and movable kidney, 453
and varicocele, 555
traumatic, 609, 611
Neurectomy, periarterial, technique of, 668
presacral, in hydronephrosis, 668
in hydroureter, 668
in retention of urine, 668
in visceral pain, 666
technique of, 668
Neuro-blastoma, 49
Neurofibromatosis:
generalised, 51
plexiform, 51
Neuroma, 49
amputation, 51
false, 49
diffuse, 50
local, 49
myelinic, 49
true, types of, 49
New-born, acute intestinal obstruction of, 333
Nipple:
abnormalities of, congenital, 672
absence of, 672
Nipple (*cont.*):
chancre of, 673
cracked, 673
discharges from, abnormal, 673
eczema of, 673
Paget's disease of, 673, 691
and eczema, differential diagnosis, 691
papilloma of, 673
retention cyst of gland of Montgomery, 673
retraction of, 672
supernumerary, sites of, 672
Normacol, use of, 209
Nose, median cyst over, 116
Nuck, canal of, hydrocele of, 535
Nutrient enema, 374

Ochsner-Sherren (delayed) treatment of acute appendicitis, 365
results of, 368
selection of cases and exceptions to, 365, 366
Ochsner's method of treating peritonitis, 289
Odontomes, 107
treatment of, 108
varieties of, 107
Œsophagoscope, 199
Œsophagoscopy, 198
in cardiospasm, 204
Œsophagus, 197–206
abnormalities of, congenital, 205
carcinoma of, 199
clinical features, 200
diagnosis, 201
pathology, 200
site of, 201
treatment, palliative, 201
radical, 203
diseases of, investigation of, 197
diverticula of, 206
foreign bodies in, 199
injuries of, 205
measurements of, 197
obstruction of, acute, 199
causes of, 198
chronic, 199
paralysis of, 206
pouch of, 194
stricture of, simple, 205
spasmodic, 203
tumours of, simple, 206
varices of, 206
Oil of turpentine in frost-bite, 68
Olive-oil enema, 374
Omentocele, 409
strangulated, 412
relief of, 413

Omentopexy in liver cirrhosis, 261
Omentum, great, 301
torsion of, 302
Omphalo-mesenteric duct, 309
obliterated, causing obstruction, 340
patent, 310, 311
Ophthalmia neonatorum, symptoms and treatment, 35
Opisthotonus in tetany, 16
Orbit, cellulitis of, 6, 118
cysts of, 115
tumours of, classification of, 116
clinical features, 116
glioma, 116
melanoma, 116
Orchidectomy, 542
for malignant disease of testis, 551
palliative, for malignant testis, 550
with partial scrotectomy in chronic tuberculous epididymo-orchitis, 547
Orchido-cœlioplasty, 542
Orchidopexy, technique, 541
Orchitis, syphilitic, physical signs, 551
Orr's treatment of acute osteomyelitis, 799
Os calcis, apophysitis of, 832
fractures of, 789
Os magnum, dislocation of, 846
Osgood's disease, 832
Osteitis deformans, 810
changes in bones in, 810–812
clinical features, 812
complications and treatment, 813
fibrosa, generalised, ætiology of, 183
varieties of, 813
tuberculous, 805
Osteoarthritis:
acute polyarticular, 879
chronic monarticular, 880
polyarticular, 880
clinical features, 882
complicating fracture, 736
following spinal injuries, 611
of big toe-joint, 927
pathological changes, 880
polyarticular, ganglionectomy in, 665
treatment, 883
Osteochondritis juvenalis, 830
of nasal septum, 801
Osteo-chondromata, multiple congenital, 835
Osteoclasis in rickets, 810
manual, for curvature of tibia, 916
Osteoclastoma, 820
Osteogenesis imperfecta, 724, 817
Osteomalacia, 815
hunger, 810
Osteomyelitis:
acute infective, clinical features, 794
complications of, general, 795
local, 796
differential diagnosis, 794
pathology, 793
predisposing causes, 792
treatment, 798
indications for amputation, 800
Winnett Orr method, 799, 800
acute, of vertebra, 616
acute traumatic, 801
of jaws, 111
of skull, causes and treatment, 565
subacute, 801
syphilitic, 804
typhoid, 317
Osteotomy for genu valgum, 915
for rickets, 809, 810
for talipes, 922
Otitis media, 2
causing cerebral abscess, treatment of, 577
Ovary, apoplectic, 361
cyst of, diagnosis from ascites, 299
ruptured lutein cyst of, diagnosis from appendicitis, 361
Owen's operation for hare-lip, 102
Oxyuris vermicularis causing anoproctitis, treatment of, 382

Paget's disease of bone. *See* Osteitis deformans.
of nipple, 673
and eczema, differential diagnosis, 691
theories of causation, 691
treatment, 692
of penis, 532
recurrent fibroid, 44, 891
Pain, abdominal, in tuberculosis of mesenteric glands, 303
in acute infective arthritis, 857
pancreatitis, 277
in anal fissure, 392
in carcinoma of pancreas, 283
in fractures, 726
in gall-stones, 269
in osteitis deformans, 812
in renal calculus, 459
in renal tuberculosis, 472
in urinary affections, 440
in vesical calculus, 493

Pain (*cont.*):
referred, in liver abscess, 253
in renal calculus, 460
visceral, presacral neurectomy in, 666
Palmar fascia, contraction of, 907
Pancreas, 276
calculi of, 280
carcinoma of head of, 283
clinical features, 283
treatment of, 284
van den Bergh reaction in, 284
cysts of, 280
clinical features and treatment of, 281
gastric ulcer, penetration into, 223
injuries to, 280
Pancreatitis.
acute, 276
clinical features of, 276
tests in, 276, 277, 278
treatment of, 278
post-operative, 279
chronic, clinical features of, 281
conditions associated with, 281
tests for, 282
treatment of, 282
types of, 281
subacute, 279
suppurative, 279
Panophthalmitis, 6
Papilloma, 42
sites of, 43
Paracentesis peritonei, 300
Paralysis, Erb's, 652
facial, causes of, 646, 647
infantile, 922
ganglionectomy in, 665
stages of, 923
treatment, stage of paralysis, 923
stage of recovery, 924
stationary stage, 924
Klumpke's, 652
Paraphimosis, treatment, 527
Paraplegia:
in osteitis deformans, 811
in Pott's disease, 618, 621
Parasyphilis:
examination in, 863
treatment, 864
Parathyroids, 182
and suprarenals in relation to Paget's disease, 813
extirpation of, results, 183
in relation to polyarthritis, 880
tumours of, 183
Paratyphoid fever, surgical complications of, 317
Paronychia, prophylaxis, and treatment, 939, 940
Parosteal, sarcomata, 824
Parotid tumour:
mixed, 144
treatment of, 145
Parotitis, acute, 139
treatment of, operative, 139
chronic, 139
in typhoid, 317
sub-acute, 139
suppurative, 139
Parrot's nodes, 801
Parson's knee, 895
Patella, dislocation of, 850
fractures of, 782
Patent omphalo-mesenteric duct, 310, 311
urachus, 438
Pauchet's operation for gastroptosis, 228
Paul's operation for carcinoma of colon, 329
for volvulus of sigmoid, 339
Payr's membrane, 314
"Peau d'orange," 91, 687, 692
Pedicle grafting, 61
Pel-Ebstein syndrome, 97
Pelvic abscess complicating peritonitis, 290
Pelvis, cellulitis of, 7
chondroma of 819
deformities of, in rickets, 809
false, fractures of, 769
fractures of, incomplete, 770
true, fractures of, 769
Pelvo-prostatic carcinoma, 507
Penis:
abnormalities of, congenital, 526
amputation of, complete and partial, 532
carcinoma of, 530
clinical features and treatment, 531
chancroid of, 529
fracture of, 530
herpes of, 529
Hunterian chancre of, 529
leukoplakia of, 528
Paget's disease of, 532
soft chancre of, 529
soft sore of, 529
strangulation of by rings, 530
venereal warts of, 529
Peptic ulcer. *See* Gastric *and* Duodenal.
Pericarditis, suppurative, 722

Pericardostomy, technique of, 722
Pericranitis, 565
  syphilitic, 565
Perineal operation for rectal carcinoma, 406
Perineum, split, 380
"Period of illusion" in perforated gastric ulcer, 220
Periostitis, 2
  acute, 792
  traumatic, 724, 792
Perisplenitis, 248
Peritheliomata, 58
Peritoneal effusion:
    following spleen removal, 239
    in breast carcinoma, 692
Peritoneum, 285–301
  carcinoma of, 300
    secondary, ascites in, 299
  neoplasms of, 300
  pseudo-myxoma of, 301
  rupture of hepatic hydatid cyst into, 258
Peritonitis, 2
  acute, 285
    clinical features of, 286
    complications of, 290
    paths of bacterial invasion, 285
    treatment of, Fowler's position in, 287
      Ochsner's method, 289
      operative, 288
      proctoclysis, 288
  chronic, 297
  diffuse, 286
  general, due to bursting of diverticulum, 320
  gonococcal, 296
  localised, 286
    but diffusing, 286
  pelvic, due to bursting of diverticulum, 320
  pneumococcal, 295
    treatment of, 296
  streptococcal, primary, 296
  tuberculous, acute, 297
    chronic, omentum in, 301
      origin of infection, 297
      treatment of, 298
      varieties of, 297
Perthes' disease, 831
Pes cavus, 925
  stages of, and treatment, 926
Phagadæna, 528
Pharyngeal pouch, 162, 194
  treatment of, 195
Pharynx, diverticulum of, 194
  lesions of, 188
Phimosis, 526
Phlebitis in typhoid fever, 317
Phlebolith, formation of, 85
"Phossy jaw," 112
Phrenic evulsion in tuberculosis, technique of, 650, 708
Pick's disease, ascites in, 299
    association of perisplenitis with, 248
Pied forcé, 791
Piles. *See* Hæmorrhoids.
Pin-hole ureteric orifice, 445
Pituitary body, 592
    deficiency of anterior lobe, results of, 594
      of posterior lobe, results of, 595
    development and structure of, 592
    function of *pars anterior*, 593
      of *pars nervosa*, 595
      of *pars tuberalis*, 595
    over-activity of anterior lobe, results of, 593
    tumours of, 595
      adeno-carcinoma, 597
      adenoma, 595
      cranio-pharyngeal, 596
      intrasellar, 597
      mixed adenomata, 597
      suprasellar, 597
      treatment of, 597
Pleura, contusion of, 697. *See also* Lungs and pleura.
Pleural effusion:
    following spleen removal, 239
    in breast carcinoma, 692
Pleurisy, dry, causes of, 697
Pneumatosis, cystic, of small intestines, 318
Pneumaturia, diverticulitis causing, 321, 489
  in vesico-intestinal fistulæ, 489
Pneumocele, 699
Pneumococci, 1
Pneumolysis, technique of, 710
Pneumonia, ætiology of, 2
  early, and pleurisy, diagnosis from appendicitis, 359
  hypostatic, in fractures, 732
    in spinal injuries, 607, 609
Pneumothorax, artificial, technique of, 707
  causes of, 697
Poker back, 625
Polya operation, anterior, for gastric ulcer, 217
  posterior, for gastric ulcer, 218
Polycystoma, 448, 680
Polymazia, 674

Polyp, rectal, 49
Polyserositis, ascites in, 299
Portal obstruction, ascites in, 299
Porter's treatment of cavernous hæmangioma of neck, 162
Post-allantoic gut, imperfections in development of, 375
Posterior fossa, decompression of, for cerebral tumours, 591
nerve root, division of, 631
Potassium iodide in syphilis, 29
Potato tumour, 163
Pott's disease, 618
abscess formation in, 618, 619, 621
clinical features of, 617
complications, of general, 621
local, 621
features of, in cervical regions, 619
in lumbar region, 619
in thoracic region, 619
signs of, 618
symptoms of, 617
treatment of, conservative, 622
operative, Albee's operation, 623
Hibb's operation, 623
fracture-dislocation, 787
Pouch, œsophageal, 194
pharyngeal, 162, 194
post-prostatic, 502
Pregnancy, early, diagnosis from appendicitis, 359
injection treatment contraindicated, 88
pyelitis of, 466
Priapism, persistent, 528
Pringle, mesocolic band of, 314
Procidentia, 379
Proctoclysis in peritonitis, 288
Proctodæum, imperfections in development of, 375
Proctorraphy for rectal prolapse, 379
Proctotomy, linear, for stricture, 402
Prolapsus ani, 377
recti, 379
Prostate calculi, 509
carcinoma of, secondary deposits in, 829
treatment, 507
types, 507
enlargement of, ætiology, 502
clinical features, 502
effects on bladder and urethra, 501
effects on kidneys and sexual organs, 502
Prostate (*cont.*):
enlargement of, treatment of, catheterisation, 505
operative, 503. *See also* Prostatectomy.
palliative, 505
permanent suprapubic drainage, 505
fibro-myoadenoma, 502
relationships and divisions of, 501
sarcoma, 508
Prostatectomy:
complications, 505
Harris's method, 504
perineal (Young), 504
results, 505
suprapubic, complications of, urethra stricture, 523
suprapubic, one-stage (Freyer), 504
suprapubic, "open," one-stage (Thomson-Walker), 504
transurethral partial, 505
two-stage, 504
Prostatic bar, treatment, 506
Prostatism without enlargement, 506
Prostatitis, 2
acute, 508
chronic, 508
tuberculous, 509
Protein shock as test for vasodilatation, 663
"Proud-flesh," prevention of, 61
Pruritis ani, treatment of, 394
Psammoma, 58
Pseudo-appendicitis, 358
Pseudo-biliary colic, 453
Pseudo-coxalgia, 831
Pseudo-myxoma peritonei, 301
Pseudo-pancreatic cysts, 280
Pseudo-paralysis, 802
Pseudo-stricture of urethra, 523
Psoas bursa, 881
Psycho-analysis in hysterical joints, 866
Ptosis, right-sided, 314
Puberty, colloid goitre of, 170
Puerperal fever, 1
Pulmonary embolism, 84, 718
Purgatives, abuse of, causing appendicitis, 351
Purpura, 245
confusing terminology of, 245
diagnosis of rash, 246
treatment of, 247
types of, 246
with intestinal symptoms, diagnosis from intussusception, 337

Pustule, malignant, 14
of face, 119
Pyæmia, 8, 861
portal, 251, 294
Pyelitis, 2
acute, 466
treatment, 466
chronic, 467
of pregnancy, 466
Pyelography, excretion, 442
in injuries of kidney, 451
in abnormal renal vessels, 447
in renal neoplasms, 477
in renal tuberculosis, 473
instrumental, 444
in ureteric calculus, 465
Pyelonephritis, 468
Pyelotomy for calculus, 462
Pylephlebitis, clinical features of, 251, 252
diagnosis from subphrenic abscess, 294
treatment of, 252
Pyloric stenosis :
complicating gastric ulcer, 222
of infants, 207
treatment by Rammstedt's operation, 208
Pylorus, carcinoma of, 233
Pyogenic organisms, 1
Pyonephrosis, 469
Pyopericardium, causes of, 722
treatment of, by pericardostomy, 722
Pyorrhœa alveolaris, 109
Pyuria in renal calculus, 460

Quadriceps extensor, rupture of, 888
Quinine hydrochloride injection of varicose veins, 87
Quinine urethane injection of hydrocele, 537
Quinsy, 191

Radiographs, dental, 106, 107, 109
Radium treatment :
of capillary nævi, 88
of carcinoma of bladder, 500
of breast 695
of larynx, 189
of lip, 105
of œsophagus, 202
of pancreas, 284
of penis, 531
of prostate, 507
of rectum, 406
of thyroid, 180
of tongue, 136
of carotid tumour, 163
Radium treatment (*cont.*) :
of epithelioma, 936
of keloid, 44
of leucocythæmia, 247
of lingual lymphangioma, 132
of lymphosarcoma, 97, 164
of periosteal sarcoma, 828
of rodent ulcer, 121, 935
Radius and ulna fractures, 764
congenital absence, 907
dislocation of upper end, 846
fractures of head or neck, 758
lower end, 759, 760
shaft, 759
Radon therapy :
of carcinoma of pancreas, 284
of cerebral tumours, 591, 598
of Paget's disease of penis, 532
of periosteal sarcoma, 828
Railway spine, 611
Ramisection, technique of, 669
Rammstedt's operation, 208
Ranula, deep or plunging, 125
simple, 124
treatment of, 125
Raynaud's disease, 63
ganglionectomy in, 665
von Recklinghausen's disease, 51, 813
Réclus, disease of, 690
woody phlegmon of, 149
Rectum :
and anal canal, 373–407
abnormalities of, congenital, 375
embryology of, 374
inflammations of, causes and treatment of, 381
tuberculosis of, 383
abscesses of, 384
carcinoma of, 403
clinical features of, 405
pathology of, 404
site of, 404
treatment of, by abdomino-perineal operation, 406
by perineal operation, 406
by radium, 406
palliative, 405
examination of, 373
foreign bodies in, 381
incontinence of, 380
treatment of, 380
injuries of, 380
treatment of, 381
neoplasms of, classification of, 402
papilloma of, 403
polypus of, 403

Rectum (*cont.*):
prolapse of, complete, 379
treatment of, by colopexy of sigmoid, 380
by excision, 380
by linear cauterisation, 379
by pararectal injections, 380
by proctorraphy, 379
diagnosis from intussusception, 337
incomplete, ætiology of, 377
clinical features and treatment, 377, 378
exciting causes in children 377
stricture of, causes of, 401
simple, 401
clinical features, 401
treatment of, 402
syphilis of, 383
tumours of, 402
villous, 403
Rectus abdominis:
divarication of, 431
rupture of, 436, 889
Reduction of dislocation, 835
of hip-joint, 848
of fracture, 727
open, in congenital dislocation of hip-joint, 911
Reflexes in spinal-cord injuries, 603, 607, 610
Rejuvenation, 553
Renal dwarfism, 833
Retinal embolism, 83
Retinitis pigmentosa, thoracic ganglionectomy in, 665
Retroperitoneal fossæ in relation to internal hernia, 343
lipomata and sarcomata, 307
space, 306
Rheumatism, gonorrhœal, 861
Rhinorrhœa, traumatic, 572
Rhizotomy, posterior, 631
Rib, cervical, 157
chondroma of, 819
fractures of, 766
Richter's hernia, 409
frequency of, 426
Rickets, 807
clinical features, 808
late, 810
scurvy, 810
treatment of, 809
Rickety rosary, 809
Riedel's disease, 181
lobe, 260
Risus sardonicus in tetany, 16
Rodent ulcer, 53, 933
clinical features and treatment of, 934
of face, 120
treatment of, 121
Rose's operation for hare-lip, 102
Round worms, treatment of, 382
Rovsing's sign in appendicular obstruction, 355
in gastroptosis, 228
Rutherford Morison's kidney pouch, 292
Ryle's small stomach tube, 211

Sacral puncture, technique of, 634
Sacralisation of lumbar vertebra, 626
Sacro-iliac tuberculosis, 875
Sacrum, fractures of, 771
Sahli's test in chronic pancreatitis, 282
Salivary glands:
affections of, 138–146
mixed tumours of, 144
Salpingitis, diagnosis from appendicitis, 360
Salt solution, administration of, in peritonitis, 288
Saphena varix, diagnosis from femoral hernia, 423
signs of, 423
Saphenous hum, 423
Sarcoma, 53
ætiology of, 54
and carcinoma, differences in, 54
melanotic, 53
microscopic appearance of, 56
myeloid, 53
sites of, 55
spindle-celled, 55
See also under names of organs and regions.
Sauerbruch's method of thoracoplasty, 710
Sayre's method of treating fractured clavicle, 748
Scalds and burns, 69
Scalp, 560
anatomy of, 560
blood-supply of, 560
cellulitis of, 6
cirsoid aneurism of, 561
dangerous area of, 561
dermoid cysts of, 562
epithelioma of, 562
fibrosarcoma of, 562
hæmatoma of, 560
infection of, spread of, 560

Scalp (*cont.*):
lipomata of, 561
melanomata of, 562
papillomata of, 562
sebaceous cysts of, 561
wens of, 561
Scapula, chondroma of, 819
fractures of, 749
winging of, 655
Scars, epithelioma formation in, features of, 936
Schédé's operation for empyema, 706
Schilling differential blood count, 72
Schlatter's disease, 832
Schoemaker's operation for gastric ulcer, 218
Scleroderma, cervico-thoracic ganglionectomy in, 665
Sclerosis, diffuse, of bone, 805
Scoliosis:
acquired, classification of, 901
in Pott's disease, 617
in rickets, 809
static, 902
treatment of, stages of, 902, 903
treatment of, 905
Scrotum, carcinoma of, 558
elephantiasis of, 559
idiopathic gangrene of, 558
sebaceous cysts of, 558
"watering-can," 524
Scurvy rickets, 810
Sebaceous:
glands, lesions of, 937
horn, 937
Secretory disturbances, sympathetic surgery in, 666
Semen, absence of spermatozoa in, 553
Semilunar cartilage:
cyst of, 854
dislocation of, 847
injuries of, treatment, 853
Seminal vesiculography, 554
Seminoma, 551
Sensation, loss of, in nerve division, 638
Sentinel pile and anal fissure, 391, 392, 393, 396
Septicæmia, 8
Serum:
anti-gas-gangrene, 10, 66, 331, 352
antistreptococcal, 6, 8, 12
antitetanic, 10, 18, 17, 66
Sesamoid, dislocation of, 850
Seton treatment of fistula-in-ano, 390
Sexual:
hyperactivity, senile, in prostatic enlargement, 503
organs, effects of prostatic enlargement on, 502
Sherren's triangle in appendicitis, 354, 355
Shock, in burns, 69
in fractures, 731
in ruptured spleen, 238
in ruptured urethra, 517
Shoulder:
congenital elevation of, 906
joint, dislocation of, 841
complications, 845
fracture, 844
recurrent, 844
special tests for, 842
treatment, by Kocher's method, 843
by open reduction, 843
by traction, 843
varieties, 842
tuberculosis of, 878
Sprengel's, 906
Sialography:
in parotid calculi, 141
in salivary fistula, 142
Sigmoid, volvulus of, 339
Sigmoidoscopy:
in diagnosis of carcinoma of colon, 327
of colitis, 315
Signe de Dance, in intussusception, 336
Sinus, acute abscess, 4
treatment of, 4
median mental, 112
Skin, 929–938
carcinoma of basal-celled, 933
squamous-celled, 935
grafting, 120
in burn, 70
in ulcers, 61
pedicle method, 61
Thiersch method, 61
infections of, acute, 929
chronic, 932
new-growths of, 933
Skull, 562
carcinoma of, secondary, 566
fractures of, 566
anterior fossa, 572
base of, causes of, 571
clinical features of, 571
middle fossa, 573
posterior fossa, 573
treatment of, 573

Skull (*cont.*):
fractures of, vault of, depressed, compound, 570
pond-shaped, 570
simple, 569
elevated, 571
fissured, compound, 568
simple, 567
inflammation of, 565
new-growths of, 566
tuberculous disease of, 565
Sloughing in erysipelas, 12
in spinal cord injury, 604
Smith-Petersen's nail, in fracture of femur, 773
Smith's fracture, 760
Smoker's patch, 128
Snail track ulcers, 24, 131
Snake venom in haemophilia, 887
Snapping hip, 890
tendon, 819
Snuffles, 801
in syphilis, 30
Soap and water enema, 373
Sodium morrhuate injection of varicose veins, 87
of varicocele, 557
salicylate injection of varicose veins, 87
Sore, soft, of penis, 529
Souttar's tube in œsophageal carcinoma, 202
Spermatic cord, encysted hydrocele of, 534
Spermatocele, 537
Spina bifida:
embryology of, 612
occulta, 612
complication of, 615
treatment of, 614
types of, 612
Spinal canal, tumours in, cauda equina, features of, 629
clinical examination of, 628
diagnosis of, 629
electrical reactions of, 629
extradural, 627
extramedullary, 627
intramedullary, 628
lower cervical region, features of, 629
lower dorsal region, features of, 629
lumbar cord, features of, 629
recognition of level of, 628
upper cervical region, features of, 628
upper dorsal region, features of, 629
Spinal (*cont.*):
concussion, 610
cord injuries, 610
cauda equina, results of, 605
cervical region, results of, 604
concussion, 610
dorsal region, results of, 604
hæmorrhage in, 610
lumbar region, results of, 605
results of, reflexes, 603
motor, 603
sensory, 603
trophic, 604
visceral, 603
shock, period of, 607
Spine, 598–635
diseases of, inflammatory, 616
dislocations of, 599
bilateral, 600
treatment of, 601
dislocations of, treatment of, 600
true, 599
fracture-dislocation of, 602
fractures of, clinical features of, 605
complete, 602
complications of, 609
compression, 601
incomplete, 601
prognosis of, factors governing, 603
treatment of, 606
by immobilisation by plaster, 607
by laminectomy, indications for, 609
metastases in, 626
osteomyelitis of, acute, 616
sacralisation of, 626
sarcoma of primary, 626
secondary deposits in, 626
sprains of, 599
tuberculous disease of. *See* Pott's disease.
tumours of, 626
innocent, 626
malignant, 626
typhoid, 317
Spinocaine, composition and dosage of, 633
Spirochæta pallida, 21
Spleen, 236–249
abscess of, 241
cysts of, varieties of, 247
embolism of, 84
enlargement of, ascites in, 299
table of, 249
"hard-bake," 96, 164
infarction of, 240
miniature, 237

Spleen (*cont.*):
movable, 241
new-growths of, 247
pedicles of, 236
torsion of, 241
rupture of, in typhoid, 317
post-operative complications, 239
signs of, 238
spontaneous, 240
treatment of, 239
types of, 237
wandering, 241
Splenectomy, 236
effects of, 237
in chronic lympathic leukæmia, 96
in von Jaksch's anæmia, late results of, 244
indications for, 248
Splenic artery, aneurism of, 240
puncture, 241
Spleniculi, hypertrophy of, following splenectomy, 237
Splenomegaly, Egyptian, 244
Splints for fractured femur, 778
for fractured tibia, 785
Spondylitis, 624
deformans, 880
gonococcal, 624
osteoarthritic, 624
rheumatic, 624
Spondylolisthesis, 906
Sprains, 837
Sprengel's shoulder, 906
Staphylococci, varieties of, 1
Staphylococcus pyogenes, 1
Status lymphaticus, 183
Steatorrhœa in chronic pancreatitis, 282
Steinach's operation, 553
Steinmann's pin in fracture of femur, 777
Stenosis, pyloric:
complicating gastric ulcer, 222
congenital, 207
treatment by Rammstedt's operation, 208
Stercolith causing intestinal obstruction, 342
Sterility, male, causes of, 553
Sterno-clavicular joint, dislocation of, 840
Sternomastoid tumour, 160
Sternum, fractures of, 768
Stierlin's filling defect, 318
Stiles's incision in cervical rib, 159, 160
Still's disease, 879
lymphatic enlargement in, 96
Stomach and duodenum, 207–235
carcinoma of, 230
atrophic scirrhus, 231, 233
body of, clinical types, 232
clinical features of, 232
differential diagnosis of, 233
encephaloid, 231
following ulcer, 223, 232
modes of spread, 232
pathology of, 231
scirrhus, 231
treatment of, 233
cellulitis of, acute suppurative, 234
dilatation of, acute, 209
treatment of, 210
foreign bodies in, 209
hour-glass, complicating gastric ulcer, 222
lavage of, 211
leather-bottle, 233
neoplasms of, 230
benign, 234
sarcoma of, 234
ulcer of. *See* Gastric ulcer.
volvulus of, 235
Stomatitis, acute catarrhal, 122
aphthous, 122
Stools, red-currant jelly, in intussusception, 336
Strangury in renal colic, 459
Streptococci, 8
varieties of, 1
Streptococcus pyogenes, 5, 11
Student's elbow, 895
Stunning, theories of, 578
Styes, treatment of, 929
Subastragaloid, dislocation of, 851
Submaxillary gland, tumours of, 145
Subphrenic abscess, 291
Sullivan's operation, Walton's modification of, 275
Suprapubic:
catheterisation, technique of, 483
puncture with hollow needle, 483
Supra-renal:
body, extirpation of, 480
cortex, tumours of, 480
Sweating, excessive, sympathetic surgery in, 666
Syme's operation for tongue excision, 137
Symond's tube in œsophageal carcinoma, 202
Sympathetic nervous system. *See* Nervous system, sympathetic.
Sympathectomy, effect on circulation, 663
lumbar, in colonic stasis, 667
in Hirschsprung's disease, 667

Sympathectomy (*cont.*):
lumbar, in megacolon, 667
periarterial, in causalgia, 666
in hydronephrosis, 668
in hydroureter, 668
Syndactylism, 908
Synovial:
fluid as loose body in joint, 884
membrane in tuberculous disease, 867
injury of, 851
villous processes of, 884
Synovitis, 856
gummatous, 862
syphilitic, 861
traumatic, 851
Syphilis, 21
clinical features of, primary stage, 22
secondary stage, 23
tertiary stage, 25
congenital, 30
signs of, bones, 31
central nervous system, 32
ear, 31
eye, 31
joints, 31
mucous membranes, 30
skin, 30
teeth, 31
treatment of, 32
of larynx, 187
of liver, 255
of lymphatic glands, 95
of muscles, 891
of testicle, 547
of tongue, 130
precipitation tests in, 22
treatment of, 21, 27
general, 27
local, 27
specific, 28
Wassermann reaction in, 21
Syringomyelia, joint complications, 865
Syringo-myelocele, 613

Talipes:
acquired, 920
clinical features, 921
congenital, 920
clinical features, 921
treatment, 921
varieties of, 920
Talma-Morison operation for liver cirrhosis, 261
Tannahill's operation for liver cirrhosis, 261
Tannic acid treatment of burns, 69
Tarsectomy for talipes, 922
Taxis, contraindicated in strangulated femoral hernia, 427
in irreducible hernia, dangers of, 412
in strangulated inguinal hernia, 417
"Judgment of Solomon" method, 417, 418
Teeth, abscesses of, 106, 107
caries of, 106
Hutchinson's, 802
impacted, 105
Moon's, 31, 802
supernumerary, 105
Tendon sheaths, affections of, 891
tumours of, 894
Tendons, displacement of, 890
fixation in infantile paralysis, 925
injuries of, 890
of Achilles, affection of bursa under, 895
operations on, 894
shortening, 895
snapping, 819
transplantation, 895
in infantile paralysis, 924
in nerve injuries, 642
Tennis elbow, 889
leg, 888
Teno-synoviomata, 894
Teno-synovitis, acute infective, 892
simple, 891
suppurative, signs of, 941
treatment of, 942
incisions for, 942
tuberculous, 892
Tenotomy:
in infantile paralysis, 924
open and subcutaneous, 894
Teratomata, 39
Test meals in diagnosis:
of complications of gastric ulcer, 222, 223, 224
of duodenal ulcer, 225
of gastric ulcer, 214, 215
of gastroptosis, 228
Testes and their annexæ, 533–559
Testis:
abnormalities of congenital, 539
anterior inversion of, 539
anteverted, tuberculosis of, simulating malignant testis, 552
carcinoma of, 548
development of, 539
ectopic, 539, 543
fibrosis of, 548
fungus, 548
gumma of, 548

Testis (*cont.*):
hæmatocele of, 538, 552
imperfect descent of, 539
pathology, 539
inflammation of, 544
injuries of, 538
laceration of, 539
maldescended, 539
clinical features, 540
definition of, 541
in interstitial hernia, 420
symptoms and complications, 541
torsion of, 543
treatment of, surgical, 541
malignant disease of, clinical features, 548
conditions simulating, 552
physical signs, 552
treatment, palliative orchidectomy, 550
radical operation, 551
neoplasm of, and old clotted hæmatocele, differential diagnosis, 538, 550
sarcoma of, 97, 548
swellings of, differential diagnosis, 551
teratoma of, 548
torsion of, 541, 543
differential diagnosis, 543
recurrent, 544
treatment, 544
Tetanus, 15
acute, symptoms of, 16
and strychnine poisoning, differential diagnosis, 16
chronic, 17
clinical types of, 16
delayed, 17
head, 17
local, 17
neonatorum, 17
treatment of, curative, 18
prophylactic, 17
symptomatic, 17
Tetany, ætiology of, 183
following thyroid operation, 177
gastric, 210
Thiersch's method of skin grafting, 61
Thomas's knee splint, use of, in fractured femur, 778
splint, use of, in fractured tibia, 785
Thomson-Walker's method of prostatectomy, 504
urethrotome, 521
Thoracic duct, surgery of, 165
Thoracoplasty, technique of, 709
Thorax, 697–723
Thorburn's gravitation paraplegia, 610
Thrombo-angiitis obliterans, 64
lumbar ganglionectomy in, 664
Thrombo-phlebitis:
acute infective, injection treatment contraindicated, 88
of cavernous sinus, ætiology of, 104
Thrombosis:
causing gangrene, 64, 342
deep, injection treatment contraindicated, 88
venous, predisposition of, 85
results of, 85
Thrush, 122
Thymus, 183
tumours of, 183
Thyroglossal cyst, 182
fistula, 181
tract, anomalies of, 181
Thyroid gland:
adenoma of, clinical features, 177
treatment, 179
carcinoma of, secondary deposits in, 830
treatment, 180
varieties, 180
Crile's method of "stealing," 175
diseases of, 167
ectopic, 182
and aberrant, 167
inflammation of, 181
lingual, 133, 167
neoplasms of, 177
sarcoma of, 97
thyroglossal duct, parathyroid and thymus, 167–183
Thyroiditis, 181
acute and chronic, 181
ligneous, 181
Thyrotomy for laryngeal carcinoma, 189
Tibia and fibula, fractures of, 786
curvature of, 808, 916
fractures of lower end, 786
shaft, 785
upper end, 784
overgrowth and curvature of, syphilitic, 802
Tic douloureux, 644
Tillaux's triad, 305
Tissues, iron content of, following splenectomy, 237
Toldt's membrane, 314

Tongue, angioma of, 133
carcinoma of, clinical features, 133, 134
spread of, 135
symptoms of, 134
treatment of, 135
cervical glands in relation to, 137
excision of, operations for, 136
geographical, 130
inflammation of, 127
injuries of, 127
lymphangioma of, 132
neoplasms of, benign, 132
papilloma of, 132
precarcinomatous conditions of, 135
sarcoma of, 137
syphilis of, primary, 130
secondary, 130
tertiary, 131
tuberculosis of, 130
tumours of, malignant, 133
ulcers of, 131
malignant, 132
specific, 132
varieties of, 132
Tongue-tie, 127
Tonsillectomy, 190
Tonsils, carcinoma of, 193
hypertrophy of, 189
infection of, 1
sarcoma of, 193
Torek's operation, 542
Torticollis:
acquired, causes and varieties, 899
ætiology of, 161
congenital, 899
treatment of, 900
Tourniquet test in purpura, 246
Toxæmia, 8
Trachea, wounds of, 148
Tracheotomy, 185
indications for, 186
Transillumination of hydrocele, 535
Transurethral resection of prostate, 505
of prostatic bar, 506
of prostatic calculi, 510
Trauma in ætiology of hernia, 409
Trench mouth, 122
Trendelenburg's:
operation for pulmonary embolism, 721
for varicose veins, 88
test, 910
Trigger finger, 907
Trismus, impacted tooth causing, 106
Trochanters, fracture through, 775
Trophic changes in nerve division, 638
Truss for hernia, particulars required when ordering, 415
Tuberculosis, ano-rectal, 383
causing intestinal obstruction, 340
cutis ani, 383
endosteal, 805
of breast, 679
of bursæ, 896
of intestines, 317
of kidney, 470
of larynx, 187
of liver, 255
of lymphatic glands, 93
of mesenteric glands, 303
of muscles, 891
of peritoneum, 297
of seminal vesicles, 555
of skin, 932
of skull, 565
of tendon sheaths, 892
of testicle, 545, 546
of tongue, 130
periosteal, 806
pulmonary, 707
treatment of, by artificial pneumothorax, 707
by phrenic evulsion, 708
by pneumolysis, 710
by thoracoplasty, 709
Tuffier's tube, use of, 68, 78
Tumours, 38–59
alveolus, 110
blastomata, 40
causation of, 38
classification of, 39
Cock's peculiar, 561, 937
definition of, 38
Ewing's, 825
innocent, 40
malignant, 40
methods of spread of, by blood-stream, 41
by gravity, 42
by inoculation, 42
by local extension, 40
by lymphatics, 41
by physiological propulsion, 42
recurrence after operation, 42
of antrum, 113
of naso-pharynx, 114
of upper jaw, 112
teratomata, 39
"turban," 59
See also under names of organs and regions.

Tunica vaginalis, rare affection of, 536
Turpentine enema, 373
"Twisted wire operation" in salivary fistula, 143
Typhoid carriers, cholecystectomy in, 267
Typhoid fever and acute osteomyelitis, differential diagnosis of, 795
surgical complications of, 317

Ulcerations and gangrene, 60–70
Ulcer, anastomotic, 230
Curling's, 235
duodenal. *See* Duodenal ulcer.
gastric. *See* Gastric ulcer.
gastro-jejunal, 230
injection, 87
jejunal, 230
non-specific, 60
saddle-back, 213
stomach. *See* Gastric ulcer.
tuberculous, of ileum, 317
of rectum and anal canal, 383
Ulna and radius, fractures of, 764
fractures of, 762
Ultra-violet treatment of skin tuberculosis, 933
Umbilicus, adenoma of, 439
diseases of, 437
fistulæ of, 437
Urachus, patent, 438
Uræmia in prostatic enlargement, 503
Urea concentration test, 442
Ureter and kidneys, 440
carcinoma of, primary, 478
pain, 440
rupture of, 452
transplantation of, in ectopia vesicæ, 486
Urethra :
abnormalities of, congenital, 511
and penis, 511–532
bulbous, rupture of, 513
complications, 514
extravasation, treatment of, 517
treatment, 514
calculus of, 524
carcinoma of, 526
development of, 511
diverticula of, 525
effects of prostatic enlargement on, 501
false passages, 519
female, caruncle of, 526
stricture of, 526
Urethra (*cont.*) :
fistula of, 524
intrapelvic, rupture of, 515
complications, 517
treatment, 515
occlusion of, following rupture, 517
papilloma of, 525
prostatic, calculi in, 509
pseudo-stricture, 523
rupture of, 513
strictures and valves of, congenital, 511
strictures of, clinical features and diagnosis, 519
complications of, 523
congenital, 511
following rupture, 514
post-gonorrhœal, 518
post-operative, 523
post-prostatic, 523
rare, 523
traumatic, 523
treatment of, dilatation, 520
excision, 522
external urethrotomy, 523
internal urethrotomy, 521
varieties, 518, 523
Urethritis, 2
anterior, 33
treatment of, 36
chronic female, 526
granular, female, 526
posterior, 33
treatment of, 37
Urethroscopy in diagnosis of stricture, 519
Urethrotome, Thomson-Walker's, 521
Urethrotomy :
external, for strictures, 523
internal, for strictures, 521
technique, 522
Urinary :
affections, symptoms of, 440
investigation, 441
Urine :
acute retention, ætiology, 481
treatment, 482–484
antiseptics, 468
collection of, for examination, 473
examination of, 441, 473
extravasation of, deep, following rupture of urethra, 518
subcutaneous, following rupture of urethra, 514
superficial, following rupture of urethra, 517
in acute pancreatitis, 278

Urine (*cont.*):
in chronic pancreatitis, 282
incontinence of, 484
retention of, in prostatic enlargement, 503
presacral neurectomy in, 668
with overflow, 484
in prostatic enlargement, 503
Urotropine administration of:
in acute infective meningitis, 574
in head injuries, 574
Uterus, pain in, presacral neurectomy in, 666

Vaccine therapy:
of abscess fistula and sinus, 5
of actinomycosis, 21
of carbuncles, 930
of cystitis, 496
of gonococcal arthritis, 861
of pruritus ani, 394
of styes, 929
Vaginitis, gonorrhœal, 35
Varicocele:
clinical features, 555
injection treatment of, 556
treatment of, 556
Varicose ulcer, diagnosis from gummatous, 27
Varicose veins. *See* Veins, varicose.
Varix, aneurismal, 82
Vas, ligature and division of, in chronic tuberculous epididymo-orchitis, 547
Vasodilatation, tests for, heating the body, 664
tests for, protein shock, 663
Vasomotor changes in nerve division, 638
Vasotomy, 554
Veins, thrombosis of, 85
varicose, 85
of leg, 85
treatment of, palliative, 86
treatment of, injection, 86
complications, 87
contraindications, 88
sequelæ, 87
technique, 87
operative, Trendelenburg's operation, 88
Venereal wart, 529
Ventriculography in cerebral tumour, 588
Vermiform appendix, 347–372. *See also* Appendix.
Vertebræ. *See* Spine.
Vesico-intestinal fistulæ, 489
Vesiculæ seminales, 554
Vesiculectomy by inguinal route, 555
Vesiculitis, acute, 554
chronic, 554
tuberculous, 555
Vesiculography, seminal, 554
Vesiculotomy, 554
Vincent's angina, 122
Visceroptosis, general, 312
maternal, 312
virginal, 313
Vitelline duct, 309
Volkmann's ischæmic contracture complicating fracture, 735
Volvulus neonatorum, 333
Vomiting, vicious circle, after gastro-jejunostomy, 229
Von Jaksch's anæmia, 243
Voronoff's operation, 553

Walton's modification of Sullivan's operation, 275
operation for gastric ulcer, 217
Wardrop's operation in aneurism, 81
Wart, butcher's, 933
Hutchinson's, 24, 131
venereal, of penis, 529
Wassermann reaction, 73
in carcinoma of tongue, 132
in cerebral tumours, 588
in leukoplakia glossitis, 128
in syphilis, 21
Waugh's operation for ptosis, 314
Weaver's bottom, 895
Wens, 561
Wharton's duct, stone in, 139–141
"White swelling," 867
Whitehead's operation:
for hæmorrhoids, 401
for tongue excision, 136
Whitman's method in fracture of femur, 773, 775
operation for talipes, 922
Widal's test, 73
Wilm's operation in pulmonary tuberculosis, 710
tumour of kidney, 477
Winnett-Orr method of treating osteomyelitis, 799
Witch's milk, 676
Woody phlegmon of Réclus, 149
Woolsorter's disease, 14
Worms causing appendicitis, 351
intestinal obstruction, 342
Wounds, infection of, 7
local and general changes, 7
treatment of, 9

Wrist-joint, dislocation of, 846
injuries of, 658, 659
tuberculosis of, 878

X-ray diagnosis:
of bone tumours, 818, 821, 825, 826, 829, 830
of branchial fistula, 155
of bronchiectasis, 713
of calcified tuberculous gland, 304
of carcinoma of bronchus, 717
of lung, 717
of œsophagus 201
of stomach, 233
of cardiospasm, 204
of cerebral tumours, 587
of cervical rib, 158
of cholecystitis, 266
of chronic appendicitis, 370
gastric ulcer, 214, 215
of complications of gastric ulcer, 222, 223, 224
of diaphragmatic hernia, 434
of dislocation of hip-joint, 910
of duodenal ulcer, 225
of empyema, 700, 703, 705
of enlargement of sella turcica, 835
of foreign bodies in air passages, 187
in œsophagus, 199
in stomach, 209
of fractures, 567, 569, 601, 726, 727, 728, 729, 745, 764, 780
of Harris's lines, 836
of imperforate anus, 376
of intrathoracic neoplasms, 715
of kyphosis, 905
of leather-bottle stomach, 234
of loose bodies in joints, 885
of lung abscess, 711
of myositis ossificans, 735
of œsophageal stricture, 197, 205
of Osgood's disease, 832
of osteitis fibrosa, 814
of parasyphilis, 864
of parotid calculi, 141
of pelvi-rectal fistula, 387
of Perthes' disease, 831
of pharyngeal pouch, 195
of pituitary tumours, 597
of prostatic calculi, 510
of renal calculi, 460

X-ray diagnosis (*cont.*):
of salivary fistula, 142
of Schlatter's disease, 832
of scoliosis, 903
of secondary deposits in lung, 718
of spina bifida, 614
of spinal canal tumours, 630
of submaxillary calculi, 141
of subphrenic abscess, 294
of syphilitic osteomyelitis, 804
of thyroid adenoma, 178
of tuberculosis of cæcum, 318
of tuberculous arthritis, 869
joints, 875
osteitis, 806
of ulcerative colitis, 315
of urethral calculi, 525
of urinary calculi, 463, 464
disorders, 442
of vesical calculi, 494
treatment, deep, for carcinoma of bronchus, 718
of œsophagus, 203
for endosteal sarcoma, 825
for malignant testis, 551
for myeloma, 822
for pseudo-myxoma peritonei, 301
for retroperitoneal sarcomata, 307
for sarcoma of spine, 626
for sarcoma of tongue, 137
for secondary deposits in thorax, 718
in prophylaxis of breast carcinoma, 695
of carcinoma of thyroid, 180
of carotid tumour, 163
of cystic hygroma, 161
of desmoid, 44
of Graves's disease, 174
of keloid, 45
of leucocythæmia, 247
of lymphadenoma, 97, 164
of Mikulicz's disease, 146
of periosteal sarcoma, 828
of pruritus ani, 394
of rodent ulcer, 121, 935
of skin tuberculosis, 933

Young's method of prostatectomy, 504

Zygomatic arch, fracture of, 744

Printed for H. K. Lewis & Co. Ltd. by Hazell, Watson & Viney, Ltd., London and Aylesbury.